

### **Pseudomyxoma Peritoni From An Ovarian Mucinous Cystadenoma**

#### **Abstract**

Pseudomyxoma peritonei is an exceptionally rare clinical syndrome, with an estimated annual incidence of 1-2 cases per million. This condition is characterized by the extensive accumulation of gelatinous ascites within the peritoneal cavity, and while it typically originates from the appendix (in 80-90% of cases), it can uncommonly arise from the ovary (in 10-15% of cases). Mucinous neoplasms of the ovary constitute 10-15% of all ovarian neoplasms, with the majority being benign (80%) or borderline (15-17%).

Among ovarian mucinous neoplasms, mucinous cystadenoma is a benign tumor originating from the ovarian surface epithelium and represents the second most common type of epithelial ovarian tumor. These tumors have the potential to rupture spontaneously, leading to the development of mucinous ascites characterized by a yellowish-white jelly-like substance in the abdominal cavity, a condition colloquially referred to as "Jelly-Belly" abdomen.

This case report details a 50-year-old female who presented with a large ovarian mass on the right side accompanied by significant ascites, resulting in a Jelly-Belly abdomen. Surgical intervention revealed the mass to be a benign mucinous ovarian cystadenoma.

#### **Key words**

Pseudomyxoma peritoni, Mucinous ovarian cystadenoma, Jelly-Belly abdomen, Mucinous adenocarcinoma of appendix.

#### **Introduction.**

Pseudomyxoma peritonei is a complex medical condition characterized by the presence of mucin deposits in the peritoneal cavity, often resulting in a Jelly-Belly abdomen. This condition is primarily associated with the rupture of a mucocele containing low or high-grade appendiceal mucinous neoplasm, with appendiceal origin being the most common. Alternatively, ovarian mucinous cystadenoma or cystadenocarcinoma can also contribute to the development of Pseudomyxoma peritonei. [1,2,4]

This rare condition accounts for approximately 2 cases in 10,000 laparotomies, and it predominantly affects women aged between 45 and 75 years. The primary tumor sites are the ovary and appendix, and lymphatic or extraperitoneal spread is infrequent. Symptoms and signs of Pseudomyxoma peritonei include painless abdominal distension and the presence of an ovarian mass. Diagnosis is often confirmed during laparotomy or laparoscopy when a Jelly-like mucoid material is encountered. The spilled mucin and mucinous tumor cells continue to proliferate, contributing to the characteristic "Jelly-Belly" abdomen. Peritoneal fluid can lead to liver scalloping and the formation of an "omental cake." [1,2,4,7,]

In 2010, the World Health Organization (WHO) refined the grading system for Pseudomyxoma peritonei:

1. Acellular mucin: Mucin within the peritoneal cavity without neoplastic cells.
2. Low-grade mucinous carcinoma peritonei: Characterized by mucin pools with low cellularity.
3. High-grade mucinous carcinoma peritonei: Involves mucin pools with high cellularity.

4. High-grade mucinous carcinoma peritonei with signet ring cells, which typically carries a worse prognosis. [1,3,5]

Diagnosis is commonly aided by ultrasonography, CT, and MRI imaging, along with immunohistochemical markers. Cytoreductive surgery with intraperitoneal hyperthermic perfusion, represents the current effective treatment for Pseudomyxoma peritonei. [4,7]

### Case Report

On December 10, 2011, a 50-year-old female was admitted to our centre with a history of significant abdominal distension and abdominal pain over the past 12 months. Physical examination revealed abdominal distension extending from the pelvis to the epigastric region, accompanied by a weight gain of 4 kg within the last year. Ultrasonography of the pelvis and abdomen identified a large, multiseptated cystic mass and substantial abdominal thick ascites. A subsequent CT abdomen scan confirmed a sizable multilocular cystic mass on the right side of the pelvis, measuring 15x12x10 cm, along with the presence of thick ascites. Tumor marker CA 125 was measured at 25.5 U/ml, and other laboratory blood tests were within normal limits. The preoperative diagnosis confirmed pseudomyxoma peritonei originating from a large right ovarian mucinous cystadenoma.

During laparotomy, approximately five litres of yellowish jelly-like ascites were found, along with a large, well-circumscribed, There was a break in the cyst wall, leading to presence of the mucinous fluid ruptured right ovarian cyst measuring 15x12 cm. A normal uterus and left-sided ovary were also observed. The abdominal cavity was filled with yellowish jelly-like material, and a complete removal of mucoid jelly was performed. Total abdominal hysterectomy with bilateral salphingo-oophorectomy was carried out, and although the appendix and omentum appeared normal, an appendectomy was performed as a precaution.

Postoperatively, abdominal cavity lavage was administered using 5% dextrose and 5 litres of sterile distilled water. A 32 F drainage catheter was placed in the pelvis. The histopathological report of the large ovarian cyst revealed a benign mucinous cystadenoma of the ovary, and the pseudomyxoma peritonei removal was uneventful. The patient was discharged on the 10th postoperative day. Subsequent follow-up over five years showed no recurrence, and postoperative chemotherapy was deemed unnecessary due to the benign nature of the mucinous ovarian cystadenoma. (Fig 1-9)

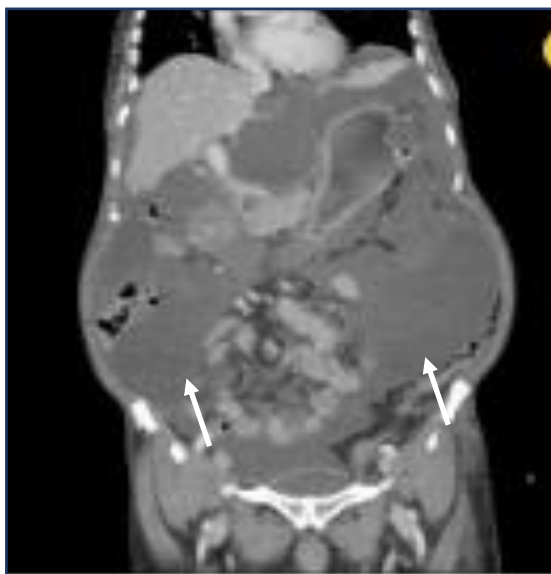


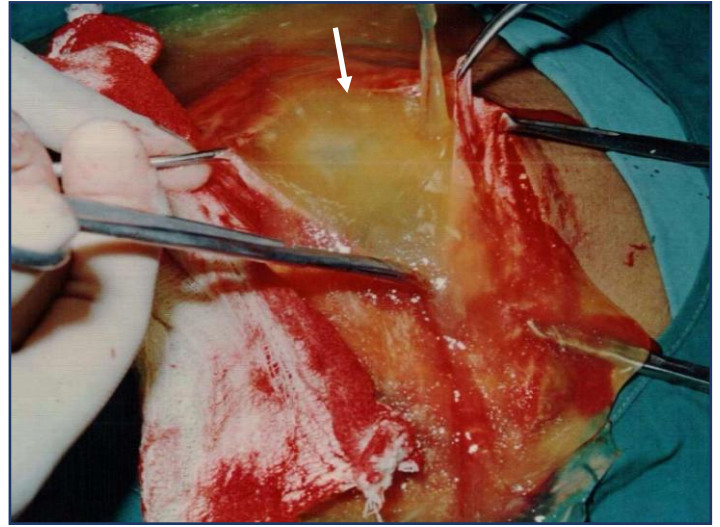
Fig-1 CT abdomen shows mucinous fluid in the abdomen "Jelly-belly"

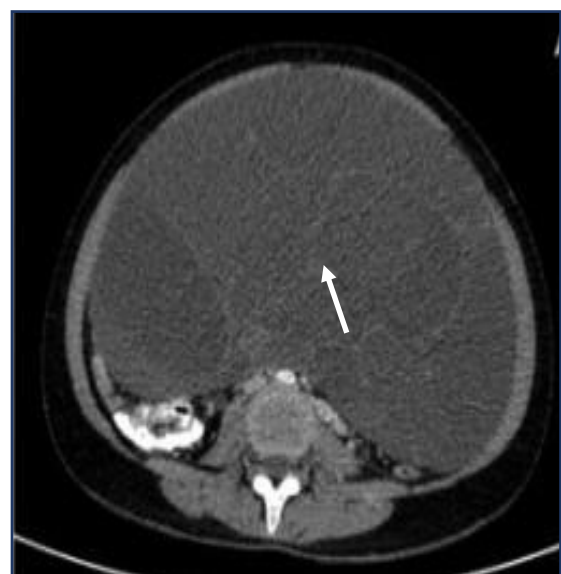
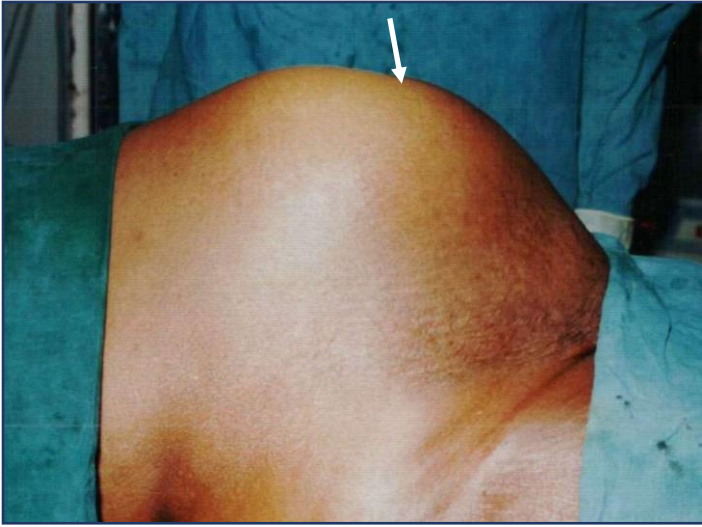
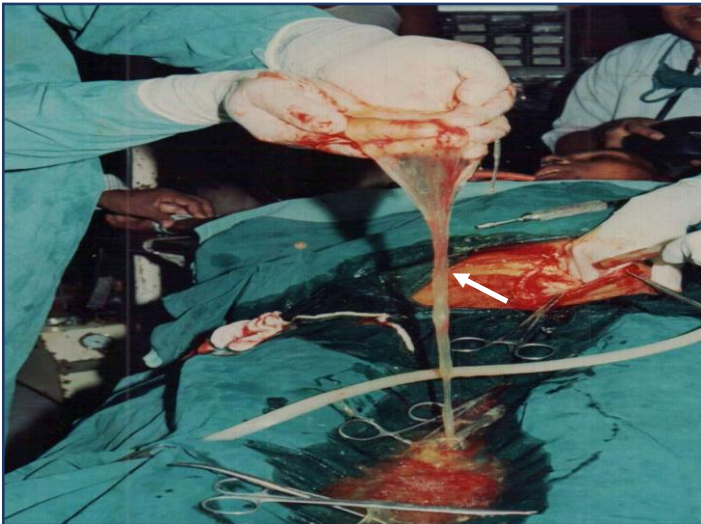
Fig-2 CT abdomen shows mucinous fluid in the abdomen



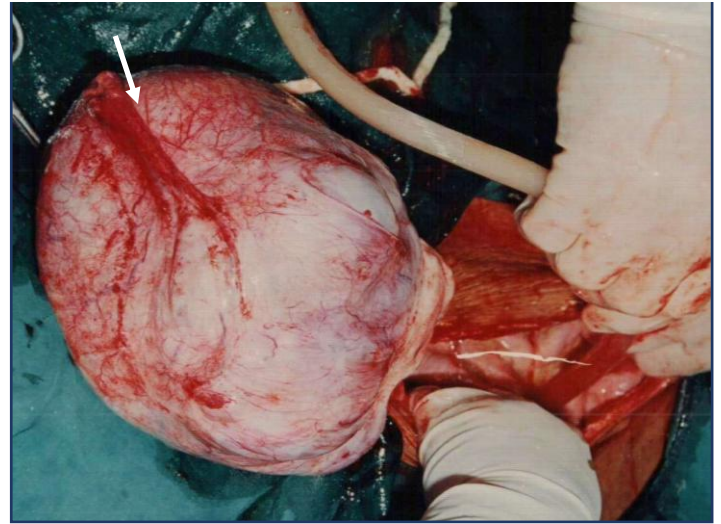
**Fig-3 Intraoperative photographs showing gross jelly ascites**



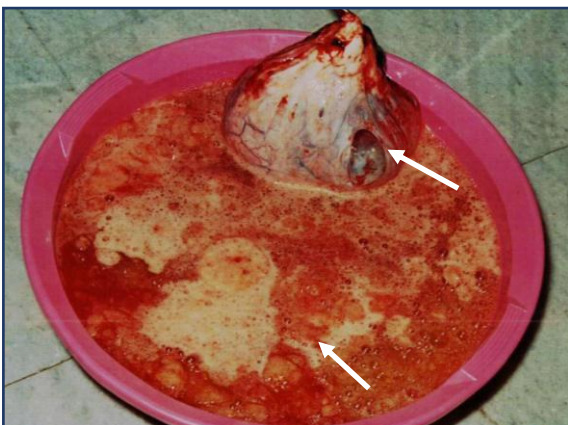
**Fig-4 Intraoperative photographs showing after explorative laparotomy yellowish jelly**



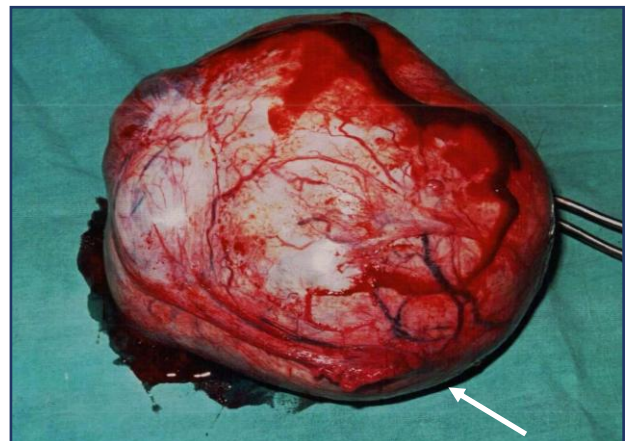
**Fig-5 Intraoperative photographs showing thick yellowish mucinous jelly**



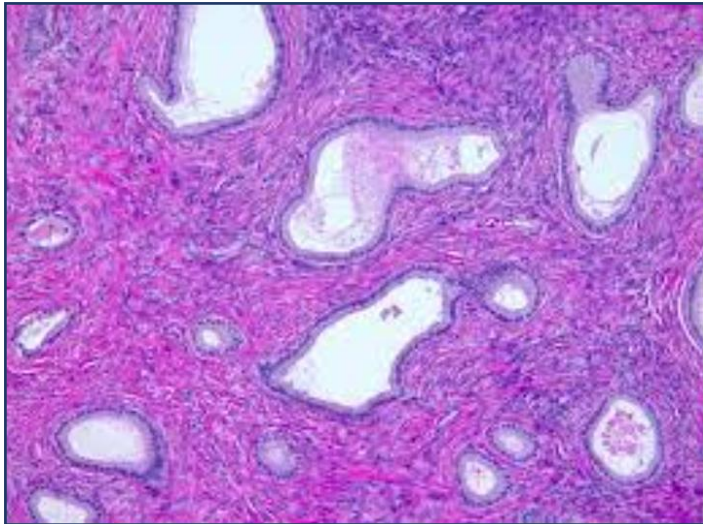
**Fig-6 Intraoperative photographs showing ovarian mucinous cystadenoma**



**Fig-7 photographs showing five litres of jelly fluid with ovarian cyst**



**Fig-8 photographs showing benign ovarian mucinous cystadenoma of size 15x12 cm**



**Fig-9 Histopathology photographs showing mucinous cystadenoma of ovary**

## **Discussion**

Pseudomyxoma peritonei is a rare and distinctive clinical condition characterized by the diffuse presence of gelatinous ascites throughout the abdominal cavity, often leading to the development of a "Jelly-Belly" abdomen, along with mucinous implants on the peritoneal surface. The term was first coined by Werth in 1884, initially linking it to a perforated mucinous cystadenoma of the appendix. However, it is now recognized to arise from mucin-producing neoplasms of various origins, including the ovary, stomach, large bowel, pancreas, and gallbladder. Considered a borderline malignancy, the primary sites are predominantly mucinous adenocarcinomas of the appendix (80-90%) and mucinous cystadenomas or adenocarcinomas of the ovary (10-15%). [1,3,5]

Pseudomyxoma peritonei originating from ovarian mucinous neoplasms is exceedingly rare, presenting with clinical manifestations such as abdominal mass, abdominal distension, weight changes, ascites, and abdominal and pelvic pain. Tumors often exhibit unilateral, cystic, and solid masses, with ruptured cysts leading to the development of jelly-like mucus and gelatinous ascites in the abdominal and pelvic cavities. Compared to appendix-origin mucus, ovarian-origin mucus is generally thinner. [1,2,7,8]

The majority of pseudomyxoma peritonei cases of ovarian origin are acellular mucin or low-grade mucinous carcinoma peritonei (75%), and the prognosis for ovarian origin is generally better than that for appendiceal origin. Immunohistochemical markers, including CA-125, ER, PR, Pax8, and WT1, are useful in diagnosing primary epithelial ovarian tumors, with high CA-125 levels associated with a poorer prognosis in pseudomyxoma peritonei patients. CT scans reveal mucinous ovarian tumors as large, unilateral, and complex cystic masses with fluid and internal calcifications within the cyst loculi. [3,5,7]

Treatment involves multidisciplinary therapy, including complete tumor resection with perioperative chemotherapy. Cytoreductive surgery with hyperthermic intraperitoneal chemotherapy (HIPEC) is the standard approach, aiming to remove as much tumor as possible. The recommended drugs for HIPEC include mitomycin-C, cisplatin, docetaxel, and gemcitabine, with mitomycin-C being the most commonly used. [1,2,3,7]

Prognosis has significantly improved with cytoreductive surgery and HIPEC, with reported 5-year and 10-year survival rates of 76% and 61%, respectively, for appendiceal lesions, and even better outcomes for ovarian lesions. Recurrence is rare with surgical therapy alone. Pseudomyxoma peritonei appears more frequently in women due to the trans-coelomic spread of ovarian tumors, and early symptoms include abdominal pain and swelling. Late-onset symptoms include abdominal distension, discomfort, and pain, along with complications like bowel obstruction and malnutrition. [2,3,4,8]

Our case of pseudomyxoma peritonei originated from a benign mucinous cystadenoma of the ovary, classified as acellular mucin or low-grade mucinous carcinoma peritonei. The prognosis has been favourable, with the patient remaining healthy for the past 10 years without recurrence. Ovarian tumors, in this context, are mostly benign or borderline, with a rare likelihood of malignancy.

### **Conclusion**

Pseudomyxoma peritonei is a rare condition, originated from ovarian mucinous cystadenoma and managed by cytoreductive surgery and if needed hypothermic intraperitoneal chemotherapy (HIPEC) agent Mitomycin -C.

### **Ethical Approval:**

As per international standards or university standards written ethical approval has been collected and preserved by the author(s).

### **Consent**

As per international standards or university standards, patient(s) written consent has been collected and preserved by the author(s).

### **COMPETING INTERESTS**

Authors have declared that they have no known competing financial interests OR non-financial interests OR personal relationships that could have appeared to influence the work reported in this paper.

### **References**

1. Liu L, Sun L, Wang J, Ji G, Chen B, Zhang H. Ovarian cystadenocarcinoma and pseudomyxoma peritonei. *BMJ Case Rep.* 2010 Jul 7;2010:bcr0620080137. doi: 10.1136/bcr.06.2008.0137. PMID: 22753161; PMCID: PMC3029120.
2. Joseph R, Sathiamoorthy, Gnanasekaran R, et al. (September 19, 2022) A Case Report of Pseudomyxoma Peritonei Arising From Primary Mucinous Ovarian Neoplasms. *Cureus* 14(9): e29309. doi:10.7759/cureus.29309

3. Gatot Purwoto, Tricia Dewi Anggraeni, Primariadewi Rustamadji, Ilham Utama Surya, Kelli Julianti, Nathaniel Herlambang, Histopathological discrepancy and variation of surgical management in mucinous ovarian cystadenoma and pseudomyxoma peritonei, *International Journal of Surgery Case Reports*, <https://doi.org/10.1016/j.ijscr.2022.107141>.
4. Fengcai Yan, Feng Shi, Xinbao , Chunkai Yu, Yulin Lin, Yan Li, Mulan Jin, Clinicopathological Characteristics of Pseudomyxoma Peritonei Originated from Ovaries, *Cancer Management and Research*. CMAR\_A\_264474 7569..7578 (dovepress.com)
5. Riho Yazawa, Hiroyuki Yazawa, Kaoru Fukuda, Miki Ohara, Fumihiko Osuka, Four cases of pseudomyxoma peritonei with ovarian tumors at our hospital, *FUKUSHIMA JOURNAL OF MEDICAL SCIENCE*, Online ISSN : 2185-4610, Print ISSN : 0016-2590 ISSN-L : 0016-2590
6. Oyeyemi N, Agbo OJ, Ohaeri OS, Kofa RI, Egberipou II. Huge ovarian mucinous cystadenoma and pseudomyxoma ovarii/peritonei: A case report. *Yen Med J*. 2019;1(1):46-48.
7. Gupta, Renuka & Bhatia, Shruti & Gupta, Amit & Bajaj, Sheena. (2018). Rare Case Report of Primary Pseudomyxoma Ovarii with Disseminated Peritoneal Adenomucinosi. *Indian Journal of Gynecologic Oncology*. 16. 10.1007/s40944-018-0230-9.
8. Moran BJ, Cecil TD. The etiology, clinical presentation, and management of pseudomyxoma peritonei. *Surg Oncol Clin N Am*. 2003 Jul;12(3):585-603. [PubMed]
9. Mittal R, Chandramohan A, Moran B. Pseudomyxoma peritonei: natural history and treatment. *Int J Hyperthermia*. 2017 Aug;33(5):511-519. [PubMed]
10. Ramaswamy V. Pathology of Mucinous Appendiceal Tumors and Pseudomyxoma Peritonei. *Indian J Surg Oncol*. 2016 Jun;7(2):258-67. [PMC free article] [PubMed]