

DIVERSE OCULAR AFFECTIONS IN BOVINES: A STUDY OF 33 CLINICAL CASES

Abstract: *The present clinical study on diagnosis and management of diverse ocular affections was conducted on 33 clinical cases of both cattle and buffaloes at College of Veterinary and Animal Sciences, Navania, Udaipur, Rajasthan. The aim of the study was to determine different ocular structures in bovines. All the findings like, incidence, case history, age, sex, breed, general body condition and clinical observations of various ocular affections were recorded with managerial practices and associated outcomes during the period from Feb. 2021 to Dec. 2021. More than 150 (presented in medicine, surgery and gynaecology department) bovines were screened for various eye disorders by a thorough clinical and feasible ophthalmological examinations (like menace reflex test, corneal reflex test, papillary light reflexes test, Schirmer's tear test, fluorescein dye test, obstacle course test, dazzle reflex test). Diverse ocular disorders like eyelid lacerations, conjunctivitis, adenexal growth, corneal ulcers/erosions, full thickness corneal defects, iris protrusion (lens protrusion with penetrating cornea), dermoids, cataract, etc. were diagnosed and managed with possible treatment available during study.*

Key words: Diverse ocular affections, Bovines, Medicine, Screening, Screening

INTRODUCTION

Eye disorders are commonly encountered in bovines. Owner ignorance, lack of scientific knowledge, low literacy, lack of awareness about effect of eye disorders on milk production and particular geographical region are the common factors favouring occurrence of diverse ocular affections. If they are not treated in time, the vision may be hampered (Slatter, 1990; Schulz and Anderson, 2010; Jhirwalet al., 2022). An essential precondition for treatment is the diagnosis and clinical evaluation of the animal's visual abnormalities. Various diagnostic tests like cotton ball, maze/obstacle and menace reflex tests and FDT (staining with fluorescein dye) are commonly used as ophthalmic diagnostic tests, which are feasible even at field level and usually inexpensive. Besides, ocular signs may also be helpful to the clinicians in diagnosing many systemic diseases (Johnson and Miller, 1990; Andrade et al., 2005; Edwards, 2010). With the exception of malignant carcinomas, ocular diseases do not directly endanger the lives of domesticated bovines; however, they greatly impair their productivity, working efficiency, ability to feed, and ability to be kept safe from harm. For these reasons, a farmer may choose to part with his cattle due to a lack of funds to feed an unproductive animal (Pratapet al., 2005). Goal of this article is evaluation of surgical treatment of diverse ocular affections in bovines and to standardize the diagnostic methods in limited resources.

MATERIALS AND METHODS

Total 33 cases (22 cattle (66.66%) and 11 buffaloes {33.33%}) were presented and operated at Veterinary Clinical Complex, Navania for various ocular problems. All cases

were examined for any other concurrent problem. However all animals were reported without recumbency and in alert mode. All essential (whatever possible) ophthalmological tests were conducted and mentioned in details in *Materials and Methods* portion of this article. Refer figures for pictorial presentation of diverse ocular affections in bovines (Fig.1 to Fig.16). Various parameters and clinical findings like body weight, heart rate, respiration rate and temperature of all cases were noted immediate after reporting of cases at clinic and further evaluated. Body weight ranged from 35 to 425 Kg measured through modified Shaeffer's formula (B.W. = Body length X {Chest girth}² divided by 300). Temperature was reported higher in recently parturated buffaloes might be due to travelling stress because of 40-50 km of distance of clinic in most of cases. Detailed findings of all cases are mentioned in **Table.1**

TABLE.1 DETAILED FINDINGS OF ALL CASES ARE MENTIONED

Total cases (on which study have been conducted)	Species				Details of each case and occurrence to time of surgery (in days) (Mean ± S.E.)			Look for percentages of affections	
33	C	M	3	22	C1	Upper eyelid laceration	1	24.89 ± 4.33	a. Cattle (66.66%)
					C2	Cataract (unilateral)	Nil		b. Buffaloes (33.33%)
					C3	Upper eyelid laceration	2		c. Males (9.09%)
					C4	Medial canthus growth	62		d. Females (90.91%)
					C5	OSCC	43		e. Adenexa(63.63%)
					C6	Lower eyelid growth	2		f. Globe(36.67)
					C7	Pthisis bulbi along with growth	43		g. Cornea (21.21%)
					C8	OSCC	60		h. Lens (3.03%)
					C9	Chronic conjunctivitis	35		i. Uvea (6.06%)
					C10	Bilateral conjunctivitis (Acute)	1		j. Growth(30.30%)
					C11	Unilateral chemosis	1		k. Traumatic: (36.36%)
					C12	Unilateral chemosis	1		
					C13	Bilateral chemosis	2		
									C14

					growth		<p>l. Congenital:(12 .12%)</p> <p>m. Aquired: (87.88%)</p> <p>n. Young (18.18%)</p> <p>o. Adult: (81.82%)</p> <p>p. Successful cases with visual outcomes (56.25%, n=18/32)</p> <p>q. Tectonic outcomes/failure (43.75%, n=14/32)</p> <p>r. Not attempted (3.03%, n=1/32)</p>
				C1 5	Upper eyelid growth	32	
				C1 6	Corneo-conjunctivaldermoid	32	
				C1 7	Medial canthus dermoid	60	
				C1 8	Corneal dermoid	18	
				C1 9	Corneal foreign body	2	
		F	19	C2 0	Eyelid laceration (upper)	1	
				C2 1	Orbital abscess	72	
				C2 2	Orbital abscess	64	
				B1	Hypopyon	13	
		M	0	B2	Corneal foreign body	1	
				B3	Orbital cellulitis	34	
				B4	Corneal dermoid	65	
				B5	Conjunctivitis	3	
	B		11	B6	Bilateral squint	12	
		F	11	B7	Corneal ulcers and erosions	1	
				B8	keratitis	14	
				B9	Eyelid growth	37	
				B1 0	Uveitis	6	
				B1 1	Iris prolapse	1	

C= cattle; B= Buffalo, M=Male, F=Female

Following a thorough clinical and ophthalmological examination of over 150 bovines, 33 bovines with a variety of ophthalmological disorders were selected and included in the present study. steps were i) screening bovines for growth, blepharospasm, cataract, etc. at the time of case presentation; ii) gross examination; iii) physical and chemical tests; vi) management of specific eye affections were included in this study. In order to identify the animals that might have blindness other than retinal causes, screening them without restraint (at the time of presentation) was the number one priority. A thorough inspection of the eye and surrounding areas was conducted to detect any signs of discharge, blepharitis, epiphora, redness, swelling, pain, entropion, or ectropion. In order to detect chemosis and potential foreign body presence in the fornix region, the conjunctiva was examined. Blepharospasm was countered with 4% lignocaine hydrochloride when needed. The cornea was checked for pigmentation, vascularization, ulceration, perforation, scar formation, and loss of transparency. Threatening reflex, corneal reflex, pupillary light reflex, dazzle response, and obstacle test were among the physical tests. In accordance to Gelatt (2000), the animal's reaction was watched when a sudden, threatening motion with the hand was made close to the eye under examination for the menace reflex test. An eye blinking along with a head movement backward was regarded as a positive response, which was rated as present, absent, or sluggish. A blink response was regarded as a positive corneal reflex when the cornea was touched with a cotton wisp in the lateral region, or away from the visual axis, during the corneal reflex test. When a strong light source was allowed to reach the retina during a pupillary light reflex, the pupil's reflexive constriction was regarded as positive. This test was graded as strong, moderate, mild, or absent, and it was conducted in a semi-dark to dark room. When an intensely bright light was shone into the eye during a dazzle response test, an involuntary blinking and closing of the eyelids was deemed positive. The animals were put through an obstacle course, such as a travis, the examination room door, or any blunt obstacle, among other things, during the obstacle test. If the animal avoided the obstacle without falling over it, the test result was considered negative, if not positively. The STT and FDT were two of the chemical tests carried out in this study. The Schirmer tear test was used to gauge the amount of tears produced, and sterile diagnostic strips measuring 5 mm by 40 mm were used. For one minute, the Schirmer tear strip was positioned medioventral to the lateral third of the palpebral conjunctival fornix. After removing the strip from the eye, the millimeter scale was used to measure the amount of tear wetting. An ophthalmic strip containing fluorescein sodium was placed in the lower cul-de-sac of the eyelid for the fluorescein dye test. The strip was taken off after one minute, and a large amount of regular saline solution was used to flush away any remaining stain. This was done in order to stain ulcerations and corneal epithelial defects, or CEDs. After that, the cornea was closely examined with a pen torch to determine its grade: not retained—normal; cornea stain retention—CEDs/ulcers.

HANDLING AND MANAGEMENT OF OCULAR AFFECTIONS

Using xylazine hydrochloride (0.05 mg/kg body weight, intramuscular) for deep sedation or medazolam premedication (0.25 mg/kg body weight, intravenous) for general anesthesia that was induced and maintained with ketamine (5 mg/kg body weight)

intravenously, all surgical interventions for eye affections were performed. The treatment for chemosis involved the use of eye drops: gatifloxacin (2 drops every 2 hours for 2 weeks), Flurbiprofen (3 drops once daily for 5 days), Triple eye ointment (5000 units of Polymyxin-B sulphate, 400 units of Bacitracin zinc, 3400 units of Neomycin sulphate), and 10 mg of Hydrocortisone ointment applied topically three times a day for a week in each case. On the first day of keratitis, a fluorescein dye test was performed to look for any corneal epithelial defects. For 14 days, use gatifloxacin eye drops (2 drops every 2 hours), flurbiprofen eye drops (3 drops daily) for 7 days, and polyvinyl alcohol and povidone eye drops to prevent eye dryness. Three doses of subconjunctival injections of gentamicin and dexamethasone were given on different days. The fluorescein dye test was used to confirm cases of corneal ulcers, and simple tarsorrhaphy, which created a physical barrier and reduced corneal damage exposure, was used to treat superficial corneal ulcers. On the other hand, deep corneal ulcers were treated by local infiltration of 2% lignocaine hydrochloride over the eyelids, temporary tarsorrhaphy under auriculopalpebral nerve block, and cauterization of the ulcer periphery using a microsurgical blade. For a period of two weeks, topical antibiotics were applied ten times a day and topical anti-inflammatory drops five times a day. In all affected cases, the tarsorrhaphy sutures were taken out on the tenth postoperative day. Auriculopalpebral and retrobulbar nerve blocks were used to retrieve corneal foreign bodies while the patient was standing. The third eyelid flap and temporary tarsorrhaphy were used to treat the superficial keratitis and corneal opacity caused by the foreign body, which were verified by a positive fluorescein dye test. Following surgery, topical eye drops were given to the animals for conditions akin to those previously stated. A regional nerve block was used to suture the corneal laceration using polyglactin 910 No. 5-0. After the corneal laceration was repaired, temporary tarsorrhaphy was performed to provide extra support. For two weeks, topical antibiotics and anti-inflammatory drops were administered. On the tenth day after surgery, the tarsorrhaphy sutures were taken out. All animals with dermoid were restrained in lateral recumbency with sedation and auriculopalpebral/retrobulbar nerve blocks. Surgical excision was performed by conjunctivectomy and superficial keratectomy was performed by surgical blade No. 15 by careful dissection to avoid injury to the anterior chamber of the eye. Postoperative treatment included topical application of eye drops gatifloxacin, eye drop flurbiprofen and Triple eye ointment for 2 weeks. Cases of eyelid laceration were treated by locally injecting 2% lignocaine hydrochloride to desensitize the eyelid. In order to close laceration wounds, two layers of buried sutures were positioned before the apposition of the eyelid margin, taking care not to pierce the palpebral conjunctiva. The wounds were cleaned with a 2% boric acid solution and minimally debrided with a No. 20 BP blade. Simple interrupted sutures using Polyglactin 910 No-2-0 were used to sew the inner layer. Skin sutures were made with No. 0-black braided silk. Following surgery, patients were given intramuscular injections of Meloxicam (0.3mg/kg, O.D.) or 5 days and topical gatifloxacin 2-drops every 2 hours for 2 weeks. The 14th day following surgery saw the removal of skin sutures. Eyelid Abscesses were opened at its most dependent part. Debris/pus was removed and cleaned with normal saline solution mixed with 5% povidone iodine. Parenteral antibiotic streptopenicillin (2.5 g/250 kg body wt, i.m.) and meloxicam (0.3 mg/kg body wt, i.m.) were given for 5 and 3 days respectively. Topically eye drops gatifloxacin (2-drops every 2-hours) was used for 7 days after cleaning the eye with normal saline. Surgical excision of growths (on

conjunctiva and sclera) was done in routine manner under xylazine sedation and regional anaesthesia. Enucleation in cases of chronic traumatic proptosis, orbital maggot infestation and exophthalmos was performed as per the standard technique for transpalpebral approach. Surgery was performed under xylazine sedation and regional anaesthesia using 2% lignocaine. In this study one cataract case has presented and surgery not done due to owner's willingness. This case was managed through topical corticosteroid and antibiotics to prevent further uveitis and retinitis ahead.

RESULTS AND DISCUSSION

More than 150 bovines (included cattle and buffaloes); those presented for concurrent issues in medicine and gynaecology department; were screened and 33 cases of various eye (or adnexa) disorders were managed through different invasive and non-invasive techniques according to case presented. Most of the animals had an unclear history of diseases occurrence and duration but findings were noted as per owner's statements regarding the case. Moreover, suggestive of being caused either due to metabolic disturbances or physical trauma by foreign bodies while few animals were suspected to have a genetic origin (like ocular dermoids). In the present study, congenital ocular affections were recorded in 4 animals (all were dermoid cases), while 29 bovines were affected with different acquired eye diseases as shown in table 1. Total 3- cases of eyelid laceration were managed successfully in this study. In old cases of eyelid lacerations, surgical debridement was performed to separate debris and to make active blood supply around wound margins, which ultimately favours healing of laceration. Suturing was done in accordance to Chawla *et al.*, (1993) and Irby, (2004). The corneal affections constituted 21.21% of all ophthalmic conditions. The mean value of (mean \pm SE) STT-1 was recorded as 31.43 ± 0.41 mm/min, significantly higher in accordance to findings of many researchers (Gelatt, 1981 and Slatter, 2001). Moreover, Gelatt, (1981) stated that corneal diseases like keratitis have been also reported in various systemic diseases. However in present study systemic diseases have not been reported for all 33 ocular affections. Few researchers like Joshi *et al.*, (2017) have reported *Theileria annulata* induced corneal opacity in a calf. The clinical symptoms noticed with keratitis and corneal ulcer included epiphora, episcleral hyperemia, and various degrees of corneal opacities ranging from mild to severe, as also reported by Abdullah *et al* (2013) and Alexander (2010). In addition to systemic treatments, a variety of topical antibiotics and corticosteroids, either alone or in combination, was applied during the acute phases of corneal affections. Most cases improved with repeated application of the appropriate topical medication. The best outcomes, however, were obtained with sub-conjunctival injection of corticosteroid and antibiotic (given in all cases of conjunctivitis after FDT), most likely due to the ability to maintain higher drug concentrations for longer periods of time. All cases of corneal affections underwent a fluorescein dye test, with the exception of penetrating corneal injuries, in order to keep the dye from penetrating the anterior chamber of the eye. The bovines that tested positive for fluorescein dye were given topical anti-inflammatory medications and broad-spectrum topical antibiotics free of

corticosteroids to encourage quick corneal healing. Nevertheless, topical antibiotics combined with corticosteroids were used when the fluorescein dye test came back negative. This combination produced better outcomes in terms of reducing corneal inflammation, preventing the formation of corneal scars, improving pigmentation, vascularization, and improving corneal transparency. According to Slatter (2001), corticosteroids can be used to restore corneal opacity caused by simple stromal wounds. The use of topical NSAID ophthalmic solutions successfully decreased corneal sensitivity, as demonstrated by Chen et al. (1997). All of the cases in the current study that received topical flurbiprofen plus antibiotics or an antibiotic-corticosteroid combination had successful pain and inflammation management. In addition to medical treatment, surgery may be beneficial for large corneal defects. In the current study, aggressive topical antibiotics and the use of anti-inflammatory eye drops improved the healing of a large superficial corneal epithelial defect/erosion treated with temporary tarsorrhaphy. According to Alio et al., (2007) patients with chronic non-healing ulcers that did not improve with conventional topical therapy were advised to undergo autologous serum therapy. However in this study instead of autologous serum only frequent administration of topical antibiotics and analgesics were found sufficient. In present case series, only single cataract case was reported and diagnosed during C-section of a cow. Owner has warned about the disease but he refused for surgery. In large ruminants, true senile cataracts that impair vision are rare (Severin, 1976). Every single case involved bilateral cataracts that resulted in total visual loss. One of the main reasons why animals lose their vision is cataracts (Gellat, 1971). But owner told about trauma to affected eye of cataract case presented in this study hence case has presented as unilaterally affected. As in other species, surgical lens removal is considered as standard management for cataracts; however, there is no medical treatment to completely eradicate cataracts in cattle (Gellat 1981). However due to owners sentiment of our study case, we prescribed few eye drops mentioned earlier. Phacoemulsification was the most effective surgical technique for removing cataracts among the various procedures used. In present study, 30.30% cases were reported as ocular growths. Many of them as cauliflower like growths. Ocular Squamous Cell Carcinoma (OSCC) was also listed by Tsujita (2010) as the most prevalent neoplasia in cattle. Cattle are more susceptible to OSCC in sunny and warm climates (Radostits et al., 2000). In this study, every tumor case was treated with surgical removal and postoperative care including topical antibiotic and anti-inflammatory ointments and drops for a week. Reoccurrence was reported in 3-cases and ultimately eye extirpation have been done in such cases. The dermoids in this study had appendages that resembled skin and hair. A conjunctivectomy (or superficial keratectomy) under local anaesthetic and sedation was used for surgical excision. Constant irritation of the hair follicle caused conjunctivitis and a loss of corneal transparency, but the pupillary light reflex remained normal. These results were consistent with previous researchers' research (Tunio et al., 2016). Topical and systemic injections of antihistaminics and non-steroidal anti-inflammatory medications (meloxicam) were effective in treating all cases of bulbar conjunctivitis. Gentamicine and dexamethasone injected subconjunctivally led to good healing

(Gelatt, 1981). Anti-inflammatory medications and systemic and local antibiotics were used to treat two cases of uveitis (Staricet *al.*, 2008). One animal made a full recovery, but the other case may have been treated too soon.

CONCLUSIONS

Ocular affections are very commonly reported under field practice. Such affections demands special skills and early management otherwise if inflammation starts within the or not treated (if started), may produce permanent blindness of affected eyeball. In conclusion, routine ophthalmic examinations in cows can aid in the early detection of numerous ocular conditions that over time may become vision-threatening.

REFERENCES

Abdullah, F.F.J., Adamu, L., Osman, A.Y., Haron, A.W. and Saharee, A.A. 2013.

Clinical management of stage iii infectious bovine keratoconjunctivitis associated with staphylococcus aureus in a dairy cow. IOSR J. Agri. Vet. Sci. 4: 69-73.

Alexander, D. 2010. Infectious bovine keratoconjunctivitis: a review of cases in clinical practice. Vet. Clin. North Am. Food Anim. Pract. 26: 487-503.

Alio, J.L., Abad, M., Artola, A., Rodriguez-Prats, J.L, Pastor, S. and Ruiz-Colecha, J. 2007.

Use of autologous platelet-rich plasma in the treatment of dormant corneal ulcer. Ophthalmol. 114: 1286- 1293. Andrade, S.F., Goncalves, I.N. and Junior, M.M.A. 2005.

Evaluation of Schirmer tear test with the use of meltitag filter paper prudente, S.P. Clinica- Veterinaria. 10(55): 34-36.

Brooks, D.E. 2009. Complications of ophthalmic surgery in the horse. Vet. Clin. North Am. Equine Pract. 24: 697-734.

Chawla, S.K., Panchbhai, V.S. and Gahlot, T.K. 1993. In: Ruminant Surgery, Tyagi, R.P.S. and Singh, J. (Eds). CBS Publishers and Distributors, New Delhi, India.

Chen, X., Gallar, J. and Belmont, C. 1997. Reduction by anti-inflammatory drugs of the response of corneal sensory nerve fibers to chemical irritation. Invest. Ophthalm. Vis. Sci. 38: 1944-1953.

Edward, R.S. 2010. Surgical treatment of the eye in farm animals. Vet. Clin. Food Anim. Pract. 26: 459- 476.

Gelatt, K.N. 1971. Cataracts in cattle. *J. Am. Vet. Med. Assoc.* 159: 195-200.

Gelatt, K.N. 1981, *Veterinary Ophthalmology*, 4th edn. Blackwell Publishing, Ames, Iowa, USA.

Gelatt, K.N. 2000. *Essentials of Veterinary Ophthalmology*, Lippincott Williams and Wilkins, Baltimore.

Irby, N.L. 2004. Surgical diseases of the eye in farm animals. In: *Farm Animal Surgery*, Saunders, St. Louis, USA. pp 429-459.

Jhirwal, S. K., Kumar, A., Sharma, G., Kumavat, N. K., Bishnoi, P., &Gahlot, T. K. (2022). Diagnosis and management of diverse ocular conditions in cattle. *Indian Journal of Veterinary Surgery*, 43(1), 35-39.

Johnson, B.C. and Miller, M.W. 1990. Recognising ocular signs of systemic disease in dogs. *Vet. Med.* 85: 1076-1090.

Joshi, V. Alam, S., Dimri, U., Bhanuprakash, A.G., Gopalakrishnan. A. and Ajith, Y. 2017. A rare case of *Theileriaannulata* induced corneal opacity in a calf. *J. Parasit. Dis.* 41: 442-445.

Matthews, A.G. 2004. The lens and cataracts. *Vet. Clin. North Am. Equine Pract.* 20: 393-415.

McLaughlin, S.A., Whitley, R.D. and Gilger, B.C. 1992. Diagnosis and treatment of lens diseases. *Vet. Clin. North Am. Equine Pract.* 8: 575-585.

Osorio, J., Moncada, L., Molano, A., Valderrama, S., Gualtero,S. and Franco-Paredes, C. 2006.

Role of Ivermectin in the treatment of severe orbital myiasis due to *Cochliomyiahomnivorax*. *Clin. Inf. Dis.* 43: 57-59.

Pratap, K., Amarpal, Aithal, H.P., Hoque, M., Kinjavdekar, P. and Pawde, A.M. 2005. Survey of eye disorders in domestic animals. *Indian J. Anim. Sci.* 75: 33-34.

Radostits, O.M., Gay, G.C. and Blood, D.C. 2000. *Veterinary Medicine, a Text Book of the Diseases of Cattle, Sheep, Pig, Goat and Horses*. 9th edn. WB Saunders, London. pp 1813-1815.

Schulz, K.L. and Anderson, D.E. 2010. Bovine enucleation: A retrospective study of 53 cases (1998–2006). *Can.Vet. J.* 51: 611-614.

Severin, G.A. 1976. Veterinary Ophthalmology Notes. Colorado State University, Fort Collins. pp 221- 242.

Slatter, D. 2001. Fundamentals of Veterinary Ophthalmology, 3rd edn. W.B. Saunders, Philadelphia, USA.

Slatter, D.H., Edward, M.E., Hawkins, C.D. and Wilcox, G.E. 2008. A national survey of the clinical features, treatment and importance of infectious bovine keratoconjunctivitis. Aust. Vet. J. 59: 69-72.

Staric, J., Krizanec, F. and Zadnik, T. 2008. Listeria monocytogenes keratoconjunctivitis and uveitis in dairy cattle. Bulletin of the Veterinary Institute in Pulawy 52: 51-355.

Tsujita, H. 2010. Bovine ocular squamous cell carcinoma. Vet. Clin. Food Anim. Pract. 26: 511- 529.

Tunio, A., Bughio, S., Abro, S.H., Kalhoro, D.H. and Memon, A.A. 2016. Eye dermoids in a Thari breed cattle calf and its surgical management: A case study. Pakistan J. Agri. Agri. Eng. Vet. Sci. 32: 295-299.

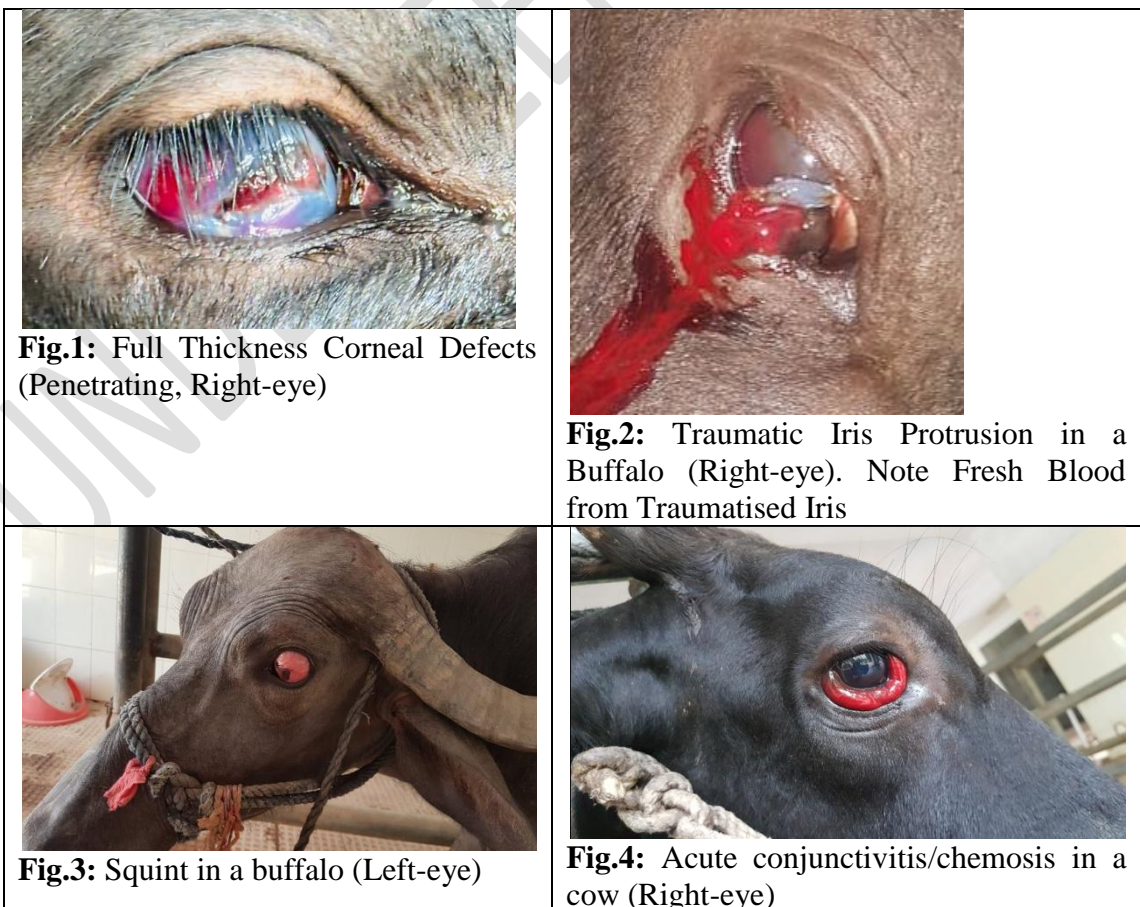

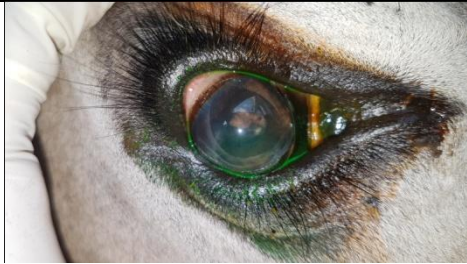


Fig.5: Uveitis in a cow. Note constricted pupil (Left-eye). Picture taken after FDT

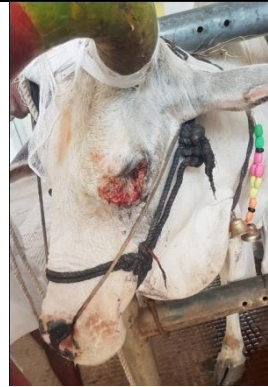


Fig.6: Ocular growth with cauliflower appearance in a cow(Left-eye).

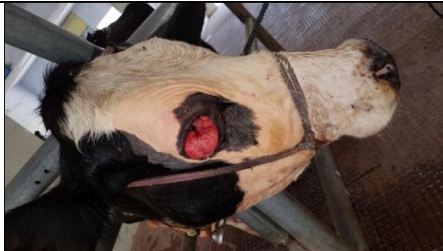

Fig.7: Ocular growth (upper eyelid and associated bulbar conjunctiva, Right-eye) in a HF.

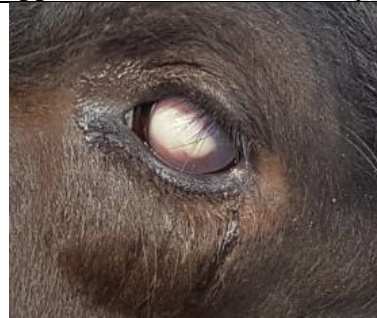

Fig.8: Hypopyon in a buffalo. (left-eye)

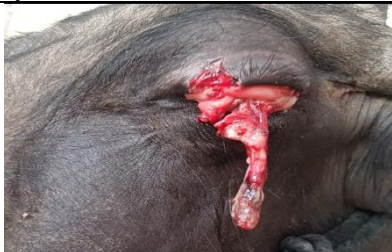

Fig.9: Upper eyelid laceration in a buffalo (left-eye involved).

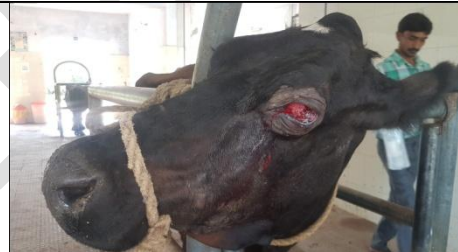

Fig.10: ocular growth with Pthisis bulbi in a cow. (Left-eye).

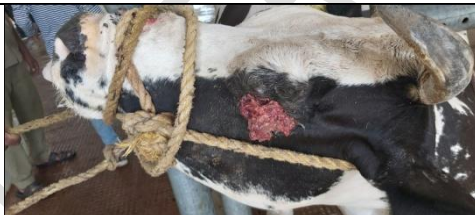

Fig.11: ocular growth with cauliflower appearance typically resembling OSCC in a cow. (Left-eye).

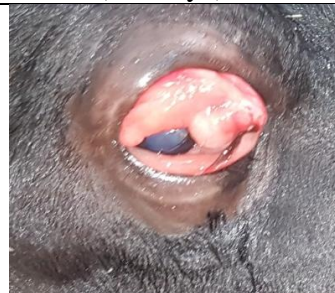

Fig.12: Chemosis and conjunctivitis in right-eye of a buffalo. Note globe is intact and cornea looks transparent.



Fig.13: Exophthalmos, Chemosis and conjunctivitis in right-eye of a buffalo. Note globe is almost proptosed.

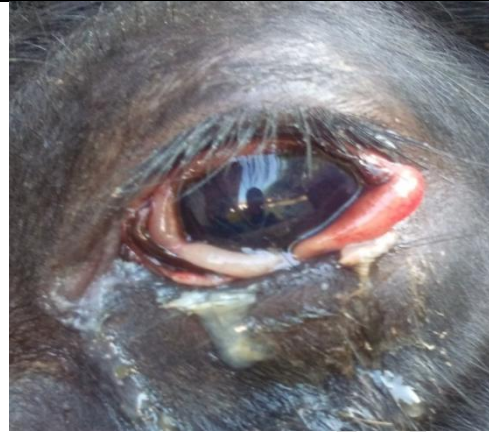

Fig.14: Conjunctivitis in left-eye of a buffalo. Note debris and discharge around the eyelids.

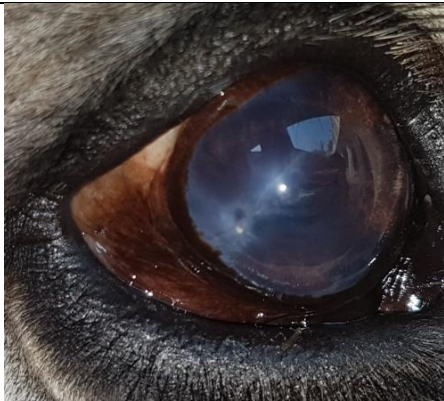

Fig.15: Corneal foreign body (Right-eye) in a cow, towards lateral canthus. Picture taken after retrieval of an embedded awn from corneal stroma. Note the lesion remained after treatment.

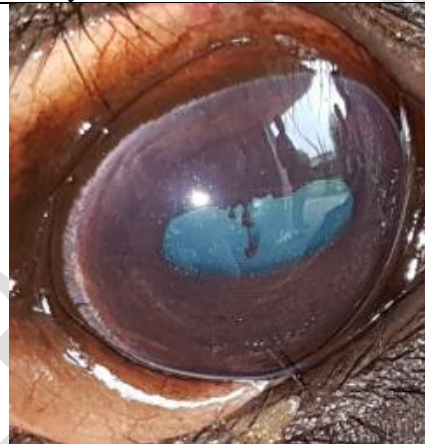

Fig.16: Mature cataract in right eye of bovine. (Note fundus is not visible).

UNDER REVIEW