

EVALUATION OF REQUIREMENT OF EXTRACTION OF MAXILLARY PRIMARY CANINE IN 3-5 YEAR OLD CHILDREN

Type of Study: Original Research Article

ABSTRACT

Dental extraction is the process of painlessly removing a whole tooth, or root, without majorly causing trauma to the adjacent tissues and tooth structure, so that the wound heals without causing any problem during postoperative prosthetic replacement. Primary teeth extraction is mainly due to long time unattended caries in most cases. As there is a decrease in the overall caries occurrence across the world, incidence of caries in developing countries are still lots in number. This is a single centered retrospective study done within a private dental hospital. Ethical approval was obtained from the institutional review board before the commencement of the study. The data was collected from the hospital management system. Cases sheets of children within the age of 3-5 years were selected. The data were then transferred to the latest version of SPSS software for statistical analysis. Frequency distribution and chi-square tests were done. The p value was set 0.05 as the level of significance. Within the limitation of the study it is concluded that the maxillary primary canine of 4 year olds is extracted more than that of 5 year olds. It is also evident that females children who have extracted their maxillary primary canine are more compared to male children. It is also proven that dental caries is the sole reason for extraction of maxillary primary canine.

KEYWORDS: Canine, Caries affected, Extraction, Innovative, Orthodontic, Primary teeth

INTRODUCTION

Dental extraction is the process of painlessly removing a whole tooth, or root, without majorly causing trauma to the adjacent tissues and tooth structure, so that the wound heals without causing any problem during postoperative phase. It is done for a various reasons like presence of abscess, periodontal diseases, necrosed pulp, over retained deciduous tooth, orthodontic purpose, prosthetic purpose, unrestorable tooth, impacted tooth, supernumerary tooth, and fractured tooth etc. In areas that have already been exposed to radiation, in local or systemic conditions that require correction or modification, etc., extraction is not advised.(1). Extraction of primary teeth is a common part of pediatric dental practice, as treatment for caries, trauma, and orthodontic considerations. Primary teeth extraction is mainly due to long time unattended caries in most cases(2). As there is a decrease in the overall caries occurrence across the world, incidence of caries in developing countries are still prevalent.

Primary teeth also known as the deciduous teeth are important through the process of growing. They play a major role in aesthetics, mastication, and normal occlusion of the permanent dentition. Premature, unintentional loss of primary teeth may lead to drifting, tilting, rotation, and malposition of the following permanent teeth. It also affects the feeding of the children and leads to serious health related conditions such as malnutrition due to inadequate chewing(3). Primary teeth also play a major role in the speech of the child. It maintains the arch shape, and maintains space for the following secondary teeth.

Dental caries is one of the predominant reasons for extraction of teeth. Dental caries are a common condition throughout the world. It is caused due to the imbalance in the demineralisation and remineralisation of the enamel matrix(4). Bacteria metabolize sugars, leading to the production of acids that, demineralize the tooth enamel and contribute to the formation of cavities. Progression of this leads to cases where the tooth cannot be restored and has to be extracted. Early childhood caries had been defined as the presence of visual caries on at least one primary tooth in children of age 3-5 years(5). The occurrence of early childhood caries has a significant relationship with the social background of the children. Evidential studies suggest brushing at least once a day, visible plaque formation, and frequent consumption of sugar is involved in the development of early childhood caries(6).

Malocclusion is another major reason extraction is considered in pediatric patients. It is necessary to provide proper arch shape for the succeeding permanent teeth. Children who suck their thumbs have a chance of developing malocclusion(7). Malocclusion changes development and growth that affect the position of teeth, which affects the aesthetics and function. Our team has extensive knowledge and research experience that has been translated into high quality publications(8)

The aim of this study is to find the requirement of extraction of maxillary primary canine in 3-5 year old children.

MATERIALS AND METHODS

This is a single centered retrospective study done within a private dental hospital. Ethical approval was obtained from the institutional review board before the commencement of the study. The data was collected from the hospital management system from 2019 - 2021. Cases sheets of children within the age of 3-5 years were selected. Data of children who had their maxillary primary canines were filtered. A total of 50 case sheets were segregated. The case sheets were verified. The data was tabulated in an excel sheet under the headings age, gender, tooth extracted, reason for extraction. The data were then transferred to the SPSS software

version 24 for statistical analysis. Frequency distribution and chi-square tests were done. The p value was set 0.05 as the level of significance.

RESULTS

Out of the total 50 children, 60% of the children were 4 year olds, and 40% of children were 5 year olds(Fig. 1). 60% of the children were female and 40% of the children were male(Fig. 2). 60% of the children had their maxillary right primary canine(53) extracted, while the remaining 40% had their maxillary left primary canine(63) extracted(Fig. 3).

When compared between age and the tooth extracted, it was found that 40% of 4 year olds and 20% of 5 year olds had their maxillary right primary canine(53) extracted respectively and 20% of both 4 year olds and 5 year olds each had their maxillary left primary canine(63) extracted(Fig. 4).

When compared between gender and the tooth extracted, it was concluded that 60% of female children had their maxillary right primary canine(53) extracted and 40% of male children had their maxillary left primary canine(63) extracted(Fig. 5).

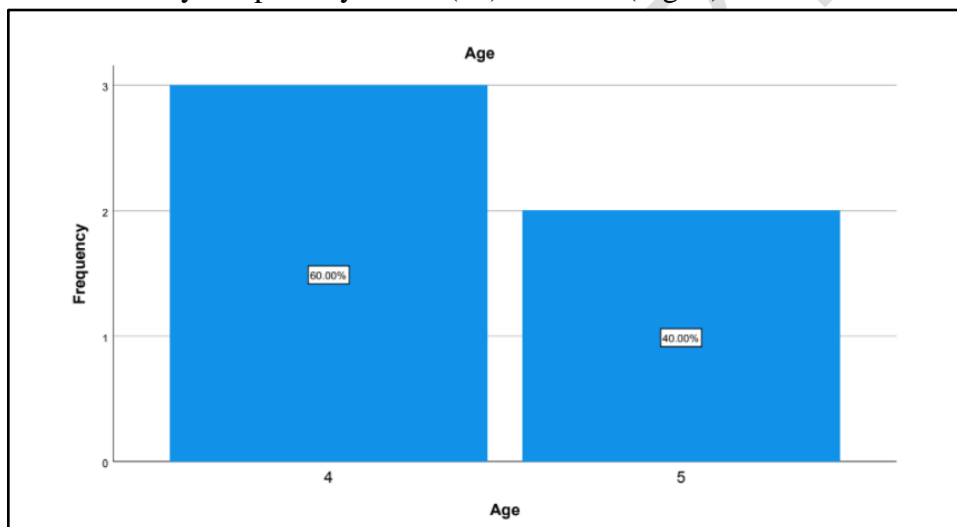


Fig. 1: The bar graph represents the total percentage distribution of children of different ages.

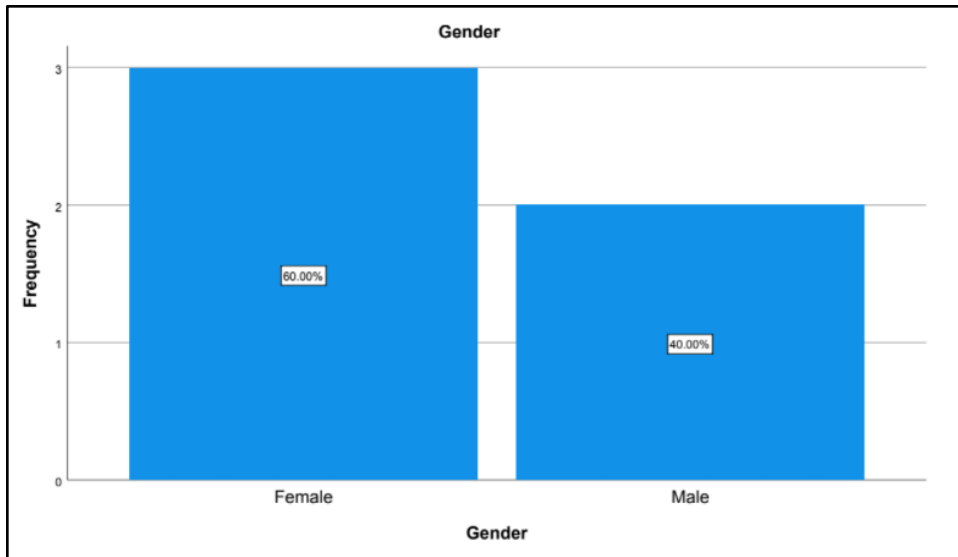


Fig. 2: The bar graph represents the total percentage distribution of children of different gender.

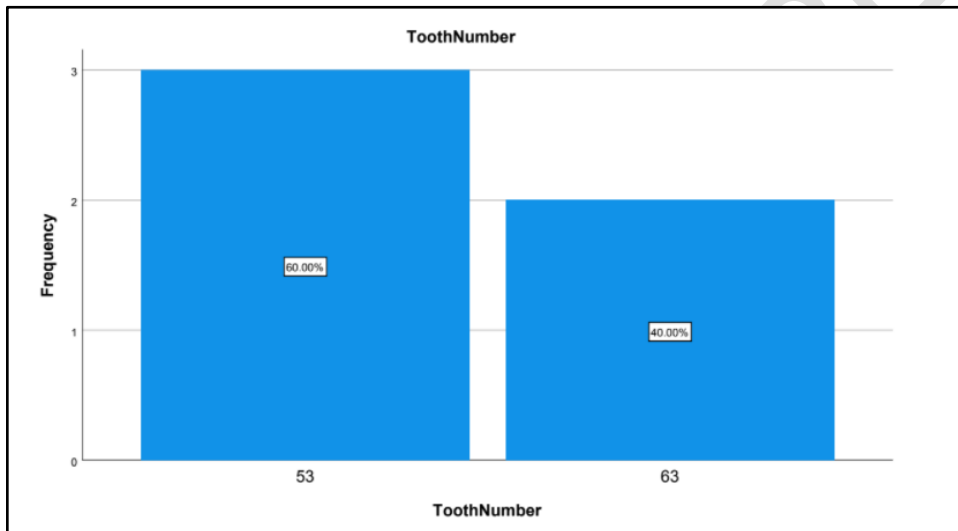


Fig. 3: The bar graph represents the total percentage distribution of the tooth extracted.

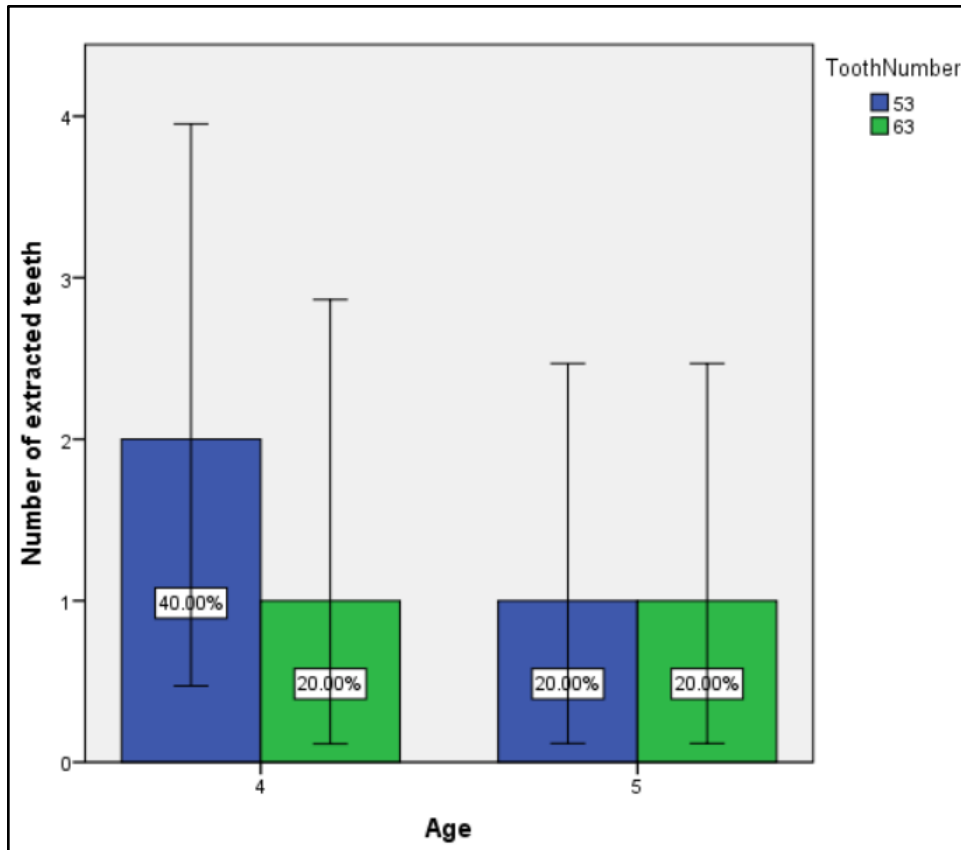


Fig. 4: The bar graph represents the age wise distribution of different teeth extracted. The p value was 0.709(>0.05) which was statistically insignificant.

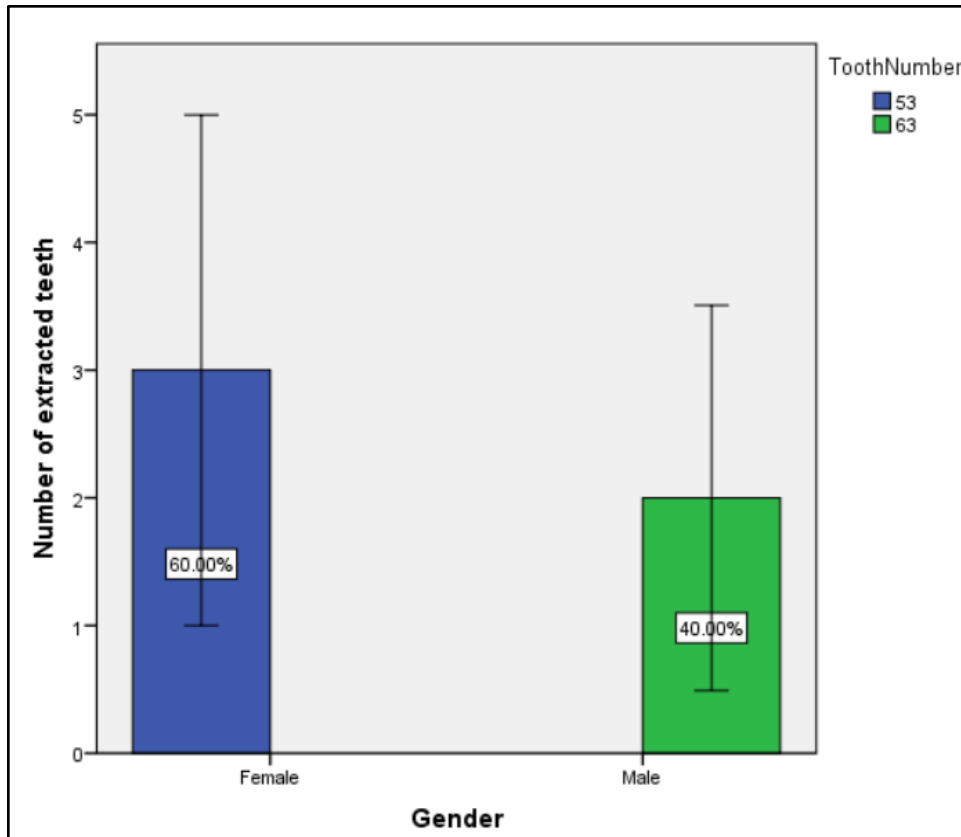


Fig. 5: The bar graph represents the gender wise distribution of different teeth extracted. The p value was 0.25(>0.05) which was statistically insignificant.

DISCUSSION

Though dental extraction is a frequent procedure followed in pediatric dentistry, a lot of investigation is done only on reasons for and pattern loss tooth in different parts of the world mainly focuses on permanent dentition(28). Research done on primary tooth mortality is very scarce in India, and other parts of the world. From this research we can see that not a lot of extraction is done for children within the age 3-5 years. It is also evident that the major reason for extraction of the tooth is caries. The behavior of children aging 3-5 years is very volatile and is a major difficulty to control eating habits(29). Children of this age are also exposed to a lot of carbohydrates in the form of chips, chocolates, candy etc. This is also an age where the brushing of teeth is also not done very properly to constrain the incidence of caries. Due to lack of knowledge among parents they don't tend to maintain a proper oral hygiene of the child which leads to unattended caries at early stage. Such unattended dental caries progress to severe stages where the tooth cannot be restored and hence need to be extracted(30). Primary canine is one of the most important teeth in the anteriors for tearing food. In a study done by Srivastava VK, it was found that prevalence of caries in mesial aspect maxillary right primary canine were seen most in 4 year olds followed by 3 years and 5 years. It was also found that caries in maxillary left primary canines were seen more in 3 year olds which is contradicting to our study as there

weren't any 3 year olds with caries. The study also states that it is not very common to get caries in maxillary primary canines unless for very poor oral hygiene. In an article published by Mukhopadhyay and Roy it was found that out of the total population of 121 between the age 0-5 years, 1.9% of children had maxillary primary canines extracted. Out of which 105 were due to incidence of caries(2).

The potential limitation of the study is small sample size, and lack of awareness among parents to bring their children to dentists for oral hygiene.

CONCLUSION

Within the limitation of the study it is concluded that the maxillary primary canine of 4 year olds is extracted more than that of 5 year olds. It is also evident that females children who have extracted their maxillary primary canine are more compared to male children. It is also proven that dental caries is the sole reason for extraction of maxillary primary canine.

ETHICAL CLEARANCE : Taken from Saveetha Institute Human Ethical Committee.

REFERENCE

1. Alsheneifi T, Hughes CV. Reasons for dental extractions in children. *Pediatr Dent*. 2001 Mar;23(2):109–12.
2. Mukhopadhyay S, Roy P. Extraction of primary teeth in children: An observational study. *J Craniomaxillofac Surg*. 2015;4(1):57–61.
3. Parkin N, Furness S, Shah A, Thind B, Marshman Z, Glenroy G, et al. WITHDRAWN: Extraction of primary (baby) teeth for unerupted palatally displaced permanent canine teeth in children. *Cochrane Database Syst Rev*. 2018 Mar 8;3:CD004621.
4. Stahl F, Grabowski R. Malocclusion and caries prevalence: is there a connection in the primary and mixed dentitions? *Clin Oral Investig*. 2004 Jun 1;8(2):86–90.

5. Selwitz RH, Ismail AI, Pitts NB. Dental caries. *Lancet*. 2007 Jan 6;369(9555):51–9.
6. Vanobbergen J, Martens L, Lesaffre E, Bogaerts K, Declerck D. Assessing risk indicators for dental caries in the primary dentition. *Community Dent Oral Epidemiol*. 2001 Dec;29(6):424–34.
7. Kabue MM, Moracha JK, Ng'ang'a PM. Malocclusion in children aged 3-6 years in Nairobi, Kenya. *East Afr Med J*. 1995 Apr;72(4):210–2.
8. Subramanyam D, Gurunathan D, Gaayathri R, Vishnu Priya V. Comparative evaluation of salivary malondialdehyde levels as a marker of lipid peroxidation in early childhood caries. *Eur J Dent*. 2018 Jan;12(1):67–70.
9. Ramadurai N, Gurunathan D, Samuel AV, Subramanian E, Rodrigues SJL. Effectiveness of 2% Articaine as an anesthetic agent in children: randomized controlled trial. *Clin Oral Investig*. 2019 Sep;23(9):3543–50.
10. Ramakrishnan M, Dhanalakshmi R, Subramanian EMG. Survival rate of different fixed posterior space maintainers used in Paediatric Dentistry – A systematic review [Internet]. Vol. 31, *The Saudi Dental Journal*. 2019. p. 165–72. Available from: <http://dx.doi.org/10.1016/j.sdentj.2019.02.037>
11. Jeevanandan G, Thomas E. Volumetric analysis of hand, reciprocating and rotary instrumentation techniques in primary molars using spiral computed tomography: An in vitro comparative study. *Eur J Dent*. 2018 Jan;12(1):21–6.
12. Princeton B, Santhakumar P, Prathap L. Awareness on Preventive Measures taken by Health Care Professionals Attending COVID-19 Patients among Dental Students. *Eur J Dent*. 2020 Dec;14(S 01):S105–9.
13. Saravanakumar K, Park S, Mariadoss AVA, Sathiyaseelan A, Veeraraghavan VP, Kim S, et al. Chemical composition, antioxidant, and anti-diabetic activities of ethyl acetate fraction of *Stachys riederi* var. *japonica* (Miq.) in streptozotocin-induced type 2 diabetic mice. *Food Chem Toxicol*. 2021 Jun 26;155:112374.
14. Wei W, Li R, Liu Q, Devanathadesikan Seshadri V, Veeraraghavan VP, Surapaneni KM, et al. Amelioration of oxidative stress, inflammation and tumor promotion by Tin oxide-Sodium alginate-Polyethylene glycol-Allyl isothiocyanate nanocomposites on the 1,2-Dimethylhydrazine induced colon carcinogenesis in rats. *Arabian Journal of Chemistry*. 2021 Aug 1;14(8):103238.
15. Gothandam K, Ganesan VS, Ayyasamy T, Ramalingam S. Antioxidant potential of theaflavin ameliorates the activities of key enzymes of glucose metabolism in high fat diet and streptozotocin - induced diabetic rats. *Redox Rep*. 2019 Dec;24(1):41–50.
16. Su P, Veeraraghavan VP, Krishna Mohan S, Lu W. A ginger derivative, zingerone-a phenolic compound-induces ROS-mediated apoptosis in colon cancer cells (HCT-116). *J Biochem Mol Toxicol*. 2019 Dec;33(12):e22403.

17. Mathew MG, Samuel SR, Soni AJ, Roopa KB. Evaluation of adhesion of Streptococcus mutans, plaque accumulation on zirconia and stainless steel crowns, and surrounding gingival inflammation in primary molars: randomized controlled trial [Internet]. Vol. 24, Clinical Oral Investigations. 2020. p. 3275–80. Available from: <http://dx.doi.org/10.1007/s00784-020-03204-9>
18. Sekar D, Johnson J, Biruntha M, Lakhmanan G, Gurunathan D, Ross K. Biological and Clinical Relevance of microRNAs in Mitochondrial Diseases/Dysfunctions. DNA Cell Biol. 2020 Aug;39(8):1379–84.
19. Velusamy R, Sakthinathan G, Vignesh R, Kumarasamy A, Sathishkumar D, Nithya Priya K, et al. Tribological and thermal characterization of electron beam physical vapor deposited single layer thin film for TBC application. Surf Topogr: Metrol Prop. 2021 Jun 24;9(2):025043.
20. Aldhuwayhi S, Mallineni SK, Sakhamuri S, Thakare AA, Mallineni S, Sajja R, et al. Covid-19 Knowledge and Perceptions Among Dental Specialists: A Cross-Sectional Online Questionnaire Survey. Risk Manag Healthc Policy. 2021 Jul 7;14:2851–61.
21. Sekar D, Nallaswamy D, Lakshmanan G. Decoding the functional role of long noncoding RNAs (lncRNAs) in hypertension progression. Hypertens Res. 2020 Jul;43(7):724–5.
22. Bai L, Li J, Panagal M, M B, Sekar D. Methylation dependent microRNA 1285-5p and sterol carrier proteins 2 in type 2 diabetes mellitus. Artif Cells Nanomed Biotechnol. 2019 Dec;47(1):3417–22.
23. Sekar D. Circular RNA: a new biomarker for different types of hypertension. Hypertens Res. 2019 Nov;42(11):1824–5.
24. Sekar D, Mani P, Biruntha M, Sivagurunathan P, Karthigeyan M. Dissecting the functional role of microRNA 21 in osteosarcoma. Cancer Gene Ther. 2019 Jul;26(7-8):179–82.
25. Duraisamy R, Krishnan CS, Ramasubramanian H, Sampathkumar J, Mariappan S, Navarasampatti Sivaprakasam A. Compatibility of Nonoriginal Abutments With Implants: Evaluation of Microgap at the Implant-Abutment Interface, With Original and Nonoriginal Abutments. Implant Dent. 2019 Jun;28(3):289–95.
26. Parimelazhagan R, Umapathy D, Sivakamasundari IR, Sethupathy S, Ali D, Kunka Mohanram R, et al. Association between Tumor Prognosis Marker Visfatin and Proinflammatory Cytokines in Hypertensive Patients. Biomed Res Int. 2021 Mar 16;2021:8568926.
27. Syed MH, Gnanakkan A, Pitchiah S. Exploration of acute toxicity, analgesic, anti-inflammatory, and anti-pyretic activities of the black tunicate, Phallusia nigra (Savigny, 1816) using mice model. Environ Sci Pollut Res Int. 2021 Feb;28(5):5809–21.
28. Gupta D, Momin RK, Mathur A, Srinivas KT, Jain A, Dommaraju N, et al. Dental caries and their treatment needs in 3-5 year old preschool children in a rural district of India. N

Am J Med Sci. 2015 Apr;7(4):143–50.

29. Kiwanuka SN, Astrøm AN, Trovik TA. Dental caries experience and its relationship to social and behavioural factors among 3-5-year-old children in Uganda. *Int J Paediatr Dent*. 2004 Sep;14(5):336–46.
30. Grewal H, Verma M, Kumar A. Prevalence of dental caries and treatment needs in the rural child population of Nainital District, Uttaranchal. *J Indian Soc Pedod Prev Dent*. 2009 Oct;27(4):224–6.

UNDER PEER REVIEW