

Ameliorative role of aqueous leaf extract of *Lawsonia Inermis* against cadmium mediated disruption of the Fallopian tube mucosal in adult female Wistar

ABSTRACT

Aim: Infertility, due to the disruption of the normal fertility milieu by ubiquitous environmental pollutants and chemicals, is a major call for public concern. For instance, tubal factor infertility is attributed to damage to the Fallopian tube lining. Herbal remedy in treatment of infertility is associated with its rich antioxidants potential. *Lawsonia inermis* (Lythraceae) leaf is studied to report its role in protecting the tubal mucosa from environmental pollutants such as cadmium chloride to provide evidence on the effect of cadmium on tubal mucosa and potential antioxidant role of *Lawsonia inermis* leaf extract (200mg/kg) to avert tubal factor infertility by evaluating changes in the histo-morphology of the tubal mucosa, biomarkers for oxidative stress and antioxidant enzymes

Methodology: Twenty (20) adult female Wistar rats of four (4) groups (n=5) used were divided into control, cadmium (2mg/kg), 200mg/kg *Lawsonia inermis* leaf extract, and 200 mg/kg *Lawsonia inermis* leaf extract treated cadmium-induced infertility model. The excised Fallopian tubes were processed, stained using Haematoxylin and Eosin, and Periodic Acid Schiff (PAS) in addition to spectrophotometric analysis for serum level of catalase (CAT) and malondialdehyde (MDA).

Results: Results indicate that cadmium caused distortions in the tubal mucosa, loss of mucin granules, elevation of lipid peroxidation marked by MDA and a decline in antioxidant enzyme- CAT activity. These aforementioned characteristics were reversed in the *Lawsonia inermis* leaf-treated infertility model attributed to an elevation in CAT that attenuated lipid peroxidation and oxidative damage in the tubal mucosal.

Conclusion: *Lawsonia inermis* averts the disruption of the tubal mucosa lining demonstrating its role to protect the tubal epithelial mucosa from toxin damage and tubal factor infertility.

Key words: *Lawsonia inermis*, infertility, mucin granules, malondialdehyde, catalase, cadmium, oxidative damage

1. INTRODUCTION

Infertility was defined according to WHO (World Health Organization) as a disease of the reproductive system which makes a woman unable to carry pregnancy to full term [1]. Epidemiological studies show that the average prevalence of infertility in the world is 10% [2] and Africa has the highest prevalence of infertility [3]. A number of heavy metal such as cadmium and lead are mostly studied for their potential in altering hormonal activity resulting in fertility problems [4]. They are described as toxins that acts by modulating endocrine activities in the female reproductive

system, however there are limited studies on the mechanism involved through which these metals induced various types of infertility in females [4-6]. However there are a some report explain the etiology of cadmium induced infertility to be characterized by alteration in ovulation, hormonal imbalance, and fertilization milieu [2,7]. Disruptions in female reproductive functions may lead to infertility, improper hormone production, estrous or menstrual cycle abnormalities, anovulation, and early reproductive ageing [8]. Traditional measures have been used to improve fertility rate [9,10]. Herbs have been proven to increase the fertility index in females due to phytochemicals content with strong antioxidant potentials, examples of such pro-fertility herbs include; red raspberry helps to reduce excessive bleeding and strengthens uterus, *trifoliumpratense* (red clover blossoms) and Nettles (*urticadioica*) maintains hormonal balance [9]. *Lawsonia Inermis* is a flowering plant and the sole species of the *Lawsonia* genus [11,12] and its medicinal properties include anti-inflammatory [13], ameliorative, antioxidant, antibacterial, among others [14,15]. The phytochemical screening on the dry leaves of *Lawsonia Inermis* revealed that it has about 0.5-1.5% lawsone aside from phenolic glycosides alkaloids, anthocyanins, phenols, sterols, xanthoproteins, flavonoids, tannins, quinones, glycosides and saponins [15] Infertility is a public concern because of human daily exposure to environmental pollutants or toxins that distort the normal fertility process resulting in reproductive disorders such as tubal factor infertility attributed to damage to the fallopian tube mucosal lining or ciliary activity that hinders propulsion of egg cells. *Lawsonia inermis* (*Lythraceae*) leaf is studied to report its role in protecting the tubal mucosa from cadmium induced tubal factor infertility by evaluating changes in tubal mucosa, mucin/glycogen granules, mucosal folds, antioxidant enzyme status and lipid peroxidation activity.

2. MATERIAL AND METHODS

2.1 Experimental animals:

Twenty (20) adult female Wistar rats with average weight of about 150g procured from the National Veterinary Research Institution (NVRI), Vom, Jos Plateau State, Nigeria and housed in the animal folding facility of the Department of Anatomy Bingham University Karu, Nasarawa State were used for this study. They were housed in well aerated metallic cages and acclimatized for two weeks, maintained at standard laboratory condition of 12-12h photoperiodicity, room temperature before the experiment commenced while being fed with water and pelleted rat feed (Vital feeds, Nasarawa, Nigeria) *ad libitum*. The animal care and use procedures in the research were performed in accordance with the Ethics Committee of the National Research Centre and the recommendations of the National Institutes of Health's Guide for Care and Use of Laboratory Animals [16].

2.2 Collection of the *Lawsonia Inermis* Leaves: The fresh *Lawsonia Inermis* leaves were harvested from Kastina-ala local government area in Benue State, Nigeria. The leaves were authenticated by a botanist in Ahmadu Bello University, Zaria, Kaduna State, Nigeria where voucher specimen number (900270) was cataloged in the herbarium.

2.3 Preparation of the *Lawsonia Inermis* Leaves: The collected *Lawsonia Inermis* leaves were air- dried as described by Sulaiman *et al.*, [17] in a clean open space at room temperature until completely dried. The dried leaves were checked to

remove any dirt before putting it in a blender (Electric blender, Philips) to get its fine powdered form thereafter stored in a dried air-tight bottled and kept in a clean cabinet [18].

2.4 Preparation of Aqueous Extract of *Lawsonia Inermis* Leaves: The aqueous extract of *Lawsonia Inermis* leaves was extracted using the method described by Handa *et al.*, [19]. The extraction was done using maceration method which involved soaking its powdered form in water (solvent) at room temperature for a period of time [19]. The process is intended to soften and break the leaves' cell wall to release the soluble phytochemicals. Thereafter, the mixture was drained by filtration using a filter paper [18]. A total of 1800mg of the blended *Lawsonia Inermis* leaf powder was measured and soaked in distilled water for 48hrs.

2.5 Chemical of Study and Dose of administration: Cadmium Chloride was obtained from Sigma-Aldrich (St. Louis, MO, USA) and dose of study was taken to be 2mg/kg per body weight according to previous study [20,21] and given orally for a period of 4 days.

2.6 Study dose of aqueous extract of *Lawsonia Inermis* Leaves: The study dose is 200mg/kg/day as demonstrated by Sravanthi *et al.*, [22] and given orally for 14 days.

2.7 Experimental Animal grouping

Group A: the control group given water, feed *ad libitum*

Group B: the infertility model due to administration of oral 2mg/kg/day of Cadmium

Group C: given oral 200mg/kg/day of *Lawsonia Inermis* leaves

Group D: pretreated with oral 2mg/kg/day of Cadmium for 4 days then post-treated with 200mg/kg/day *Lawsonia Inermis* leaves for 14 days.

2.8 Experimental design and protocol

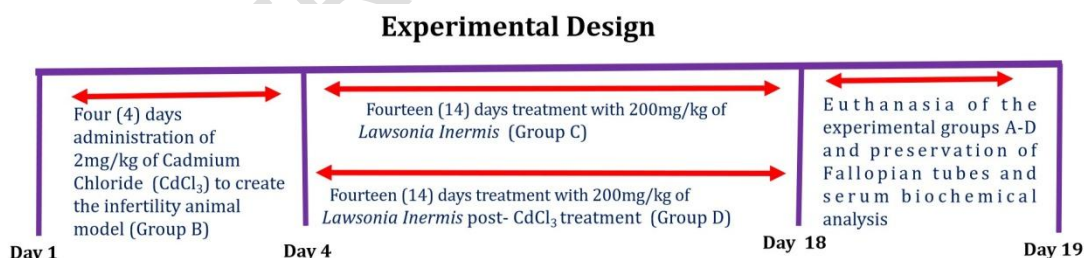


Figure 1: Illustration of experimental design for cadmium induction (infertility model) and *Lawsonia inermis* treatment. This shows the experimental designed illustrating a four (4) days pretreatment with 2mg/kg of cadmium (serves as the infertility model) group B, followed by the two groups which were respectively treated with 200mg/kg of *Lawsonia inermis* (Group B) and the 200mg/kg *Lawsonia inermis* post treated Cadmium induced infertility.

Duration of study: nineteen days (19 days)

2.9 Collection of Blood and preservation of Serum for biochemical analysis:

Blood samples, collected through cardiac puncture using a 5ml syringe, were transferred into labeled plain specimen bottles. Serum was obtained by centrifuging the blood at 3,000 revolutions for 15 minutes. The serum was aliquoted and transferred into labeled sample containers placed on ice ready for spectrophotometric biochemical enzyme analysis using commercial test kits specified for each enzymes: catalase (CAT) and malondialdehyde (MDA) using catalase spectrophotometric test kit (ab83464) and malondialdehyde ELISA Kit (ab287797) [23,24]

2.10 Experimental animal euthanasia and Fallopian tube collection: Twenty-four hours after the last dose administration the animals were euthanized, incision made in the lower abdominal region to expose the muscles and locate the Fallopian tubes. The excised Fallopian tubes were rapidly transferred into 10% formal saline for preservation, automated tissue processing and histological examination using Haematoxylin and Eosin (H and E) and Periodic Acid Schiff stain [23,25].

2.11 Catalase (CAT) Analysis: The difference in absorbance (ΔE_{240}) per unit time is measure of catalase activity taken on UV spectrophotometer at 520nm for 3minutes.

2.12 Estimation of Lipid Peroxidation: Lipid peroxidation was determined by measuring the thiobarbituric acid reactive substances (TBARS) produced during lipid peroxidation. This method is based on the reaction between 2-thiobarbituric acid (TBA) and malondialdehyde (end product of lipid peroxide during peroxidation). Lipid peroxidation was estimated according to the method of Memudu et al., (2020) determined by measuring thiobarbituric acid-reactive species, at peak of absorbance at 532 nm [23,24].

2.13 Histological processing and staining of the Fallopian tube: The tissues were processed according to method described by Memudu and Olutayo, (2021) method. The steps involved in tissue processing includes fixation, dehydration, clearing, infiltration, embedding, blocking, sectioning, sectioning, and staining. The tissues were fixed in 10% formal saline, and then transferred to a graded series of ethanol (50%, 70%, 90%, and absolute alcohol), then cleared in xylene. Once cleared, the tissues were infiltrated in molten paraffin wax in the oven at 58°C, then in three (3) changes of molten paraffin wax at one- hour intervals. Thereafter the tissues were embedded in paraffin wax using a Leica embedding machine to form the tissue blocks. Leica rotatory microtome set at 5 micron was used to section the block, and thin film of tissues sections were fixed on clean slides and later stained with Haematoxylin and Eosin (H and E), and Periodic Acid Schiff (PAS) stains [24,25]. Histochemical staining was done to demonstrate mucin granules of the epithelial cells' basement membrane (basal lamina) and glycogen granules using Periodic Acid Schiff (PAS) reaction. (Memudu and Dongo 2023).

2.14 Tissue Photomicrography: Photomicrographs of sections of the Fallopian tissue were captured using a digital camera (Amscope Inc., Irvine, CA, USA) attached to an Olympus binocular light microscope (Olympus Tokyo, Japan).

2.15 Statistical Analysis: All data were statistically evaluated using one – way ANOVA (Analysis of Variance) on SPSS/17.0 software (SPSS Inc, Chicago, USA) and the data were presented as mean \pm standard Deviation (SD). Student's t-tests were used for all paired comparisons and one-way ANOVA was used for all multiple comparisons followed by the post-hoc Tukey test. Statistics were significant when p-values were lower than 0.05 and significant effects are indicated by asterisks (* $p < 0.05$)

3. RESULTS

3.1 *Lawsonia inermis* leaf extract improves CAT antioxidant enzyme level which in turns attenuates lipid peroxidation: *Lawsonia inermis* leaf extract (C) caused a marked increase in antioxidant enzyme CAT level when compared with the control, cadmium treated and the *Lawsonia inermis* leaf extract treated cadmium induced infertility model at $P < 0.05$ (C* vs A,B,and D). However when comparing *Lawsonia inermis* treated cadmium induced infertility model with the cadmium treated group, it was observed that there was a marked decline in CAT activity in cadmium treated group as compared to the increased CAT level in the *Lawsonia inermis* treated cadmium induced infertility. Lipid peroxidation occur due to disruption of the cellular lipid membrane layer resulting in an increase in serum MDA concentration. In this study, cadmium induced infertility (B) had an increase in MDA activity when compared to other study group at $p < 0.05$ (Fig 2), however this increase was attenuated following treatment with aqueous leaf extract of *Lawsonia inermis*.

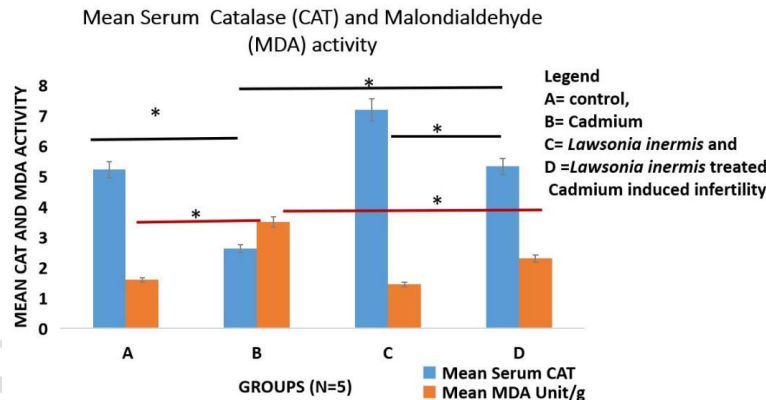


Figure 2: Graphical representation of serum catalase (CAT) and malondialdehyde (MDA) activity following administration of cadmium and aqueous leaf extracts of *Lawsonia inermis*. Legend A= control, B= cadmium C- *Lawsonia inermis* and D= *Lawsonia inermis* treated cadmium induced infertility. CAT activity (A* vs B; D* vs B; C* vs B @ $P < 0.05$). MDA activity (A* vs B; B* vs C; vs D @ $p < 0.05$).

3.2 *Lawsonia inermis* leaf extract averts disruption of the mucosal folds and loss of mucin/glycogen granules in the epithelial lining of the Fallopian tube amidst cadmium assault: This study, demonstrates histomorphological and histochemical changes in the tubal epithelium following cadmium intoxication and treatment with aqueous leaf extracts of *Lawsonia inermis*. Histological stain using Haematoxylin and Eosin (H and E) stain (Fig 3-A1-D1 at magnification of x4 while

Fig 3 (A2-D2) at magnification of x40 shows the appearance of the tubal mucosa simple columnar epithelium, underlying basal lamina, stroma cells and the basement membrane. The control group (A) has well stained epithelium with presence of mucosal folds and normal mucosal epithelium when compared with the cadmium treatment group (B) having sloughed off mucosal folds. The aqueous *Lawsonia inermis* leaf extract treatment group (C) and the infertility model treated with the *Lawsonia inermis* leaf extract (D) demonstrate preservation and gradual restoration of perturbed mucosal epithelial folds respectively. Figure 4 (A-D) demonstrates Periodic Acid Schiff (PAS) stain for mucin / glycogen granules. The PAS stain in the control group depicts the reddish purple or magenta coloration for being positive to glycogen or mucin granules in the epithelial mucosa basal lamina. The cadmium treated group has their mucosa epithelium vaguely or poorly stained to PAS as seen in the yellow arrows in addition to the presence of pericellular spaces within the epithelial cells of the tubal mucosa these pathological features were not seen in the mucosal of the experimental animals given the *Lawsonia inermis* aqueous leaf extract (C and D). The cadmium induced and post treated with aqueous leaf extracts of *Lawsonia inermis* depicts presence of moderate reaction to PAS as compared to the cadmium treated group (B).

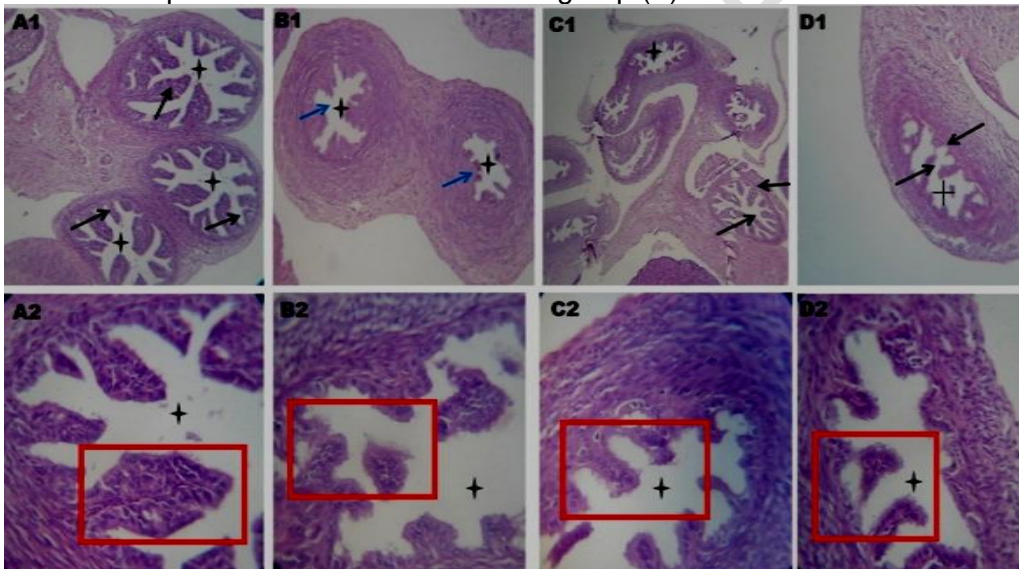


Figure 3: Photomicrograph of a transverse section of the Fallopian tubes of adult female Wistar rats stained using Haematoxylin and Eosin Stain. Magnification x10 (A1-D1) and Magnification of x40 (A2-D2). Legend A= control, B= cadmium C- *Lawsonia inermis* and D= *Lawsonia inermis* treated cadmium induced infertility. Dark arrows and red boxes: mucosal folds, blue arrows: ruptured mucosa folds, black cross: Fallopian tube lumen.

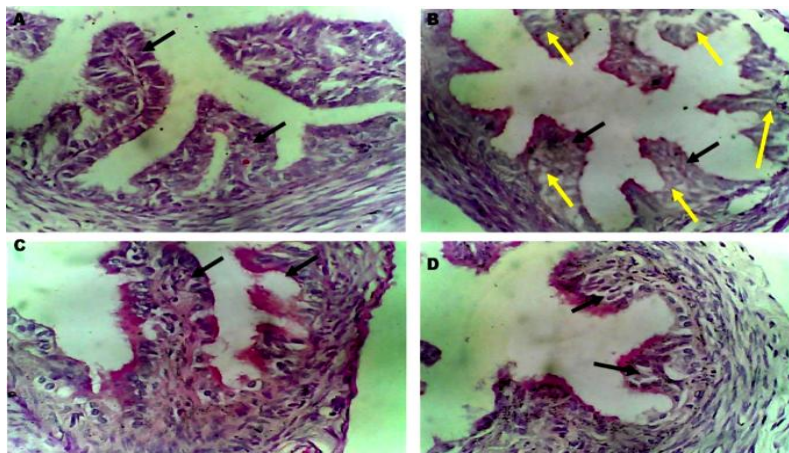


Figure 4: Photomicrograph of the transverse section of the Fallopian tube of adult female Wistar rats stained using Periodic Acid Schiff (PAS) stain Magnification of x40 Legend A= control, B= Cadmium C- *Lawsonia inermis*, and D- *Lawsonia inermis* treated cadmium induced infertility. Dark arrows- mucosal folds, Yellow arrows- poorly ruptured mucosa folds poorly stained for mucin/glycogen granules with marked vacuolations in the epithelial fold columnar cells.

4. DISCUSSION

Infertility has become global health issue due to the inability of couples to conceive after a year or more of regular unprotected intercourse [26]. There are various factors in female infertility one of which is the tubal factor risk in female infertility which accounts for 30%-40% of a woman's fertility attributed to disruption in the normal mucosa lining of the Fallopian tubes as a result of inflammation [27]. Scientific studies to provide therapeutics against female infertility using herbal remedies have gained a lot of popularity over the years owing to their potent diverse phytochemicals such as alkaloids, flavonoids, and essential oils with strong antioxidant properties [26]. The etiology of female infertility is complex as it involves various factor attributed to inflammation and oxidative tissue damage [28]. Cadmium has been reported to induced female infertility hence, mostly used to model female infertility due to its ability to disrupt endocrine activities [29] by disrupting chemical properties for hormone synthesis, secretion, and signaling [30]. Cadmium is an ubiquitous metal [31] that is found in drinking water, food, soils, and air [32]. *Lawsonia inermis* is an important plant in ayurvedic or natural herbal medicines attributed to its phytoconstituents with antioxidant and anti-inflammatory activities to avert oxidative stress mediated tissue damage [33,34]. This present study is to assess antioxidant and pro-fertility role of aqueous leaf extract of *Lawsonia inermis* on cadmium induces disruption of Fallopian tube by evaluating changes in tubal mucosa, mucin granules, antioxidant enzyme status and lipid peroxidation activity. Oxidative stress (OS), due to imbalance between the formation of reactive oxygen species (ROS) and antioxidant defenses is implicated in the pathophysiology of female infertility mediated by cadmium through lipid peroxidation,

DNA damage and mitochondrial dysfunction [35,36]. Lipid peroxidation, causes a weaken cell membrane and functions of the cells in the female reproductive organ, mediated by proinflammatory cytokines formation alters mitochondrial function resulting in a decline in energy production with a corresponding increase in ROS and lipid peroxidation [37,38]. The concentration of malondialdehyde (MDA) in the serum is an index of lipid peroxidation. Cadmium treatment caused an increase in MDA level. A number of reports has hinted that cadmium potentiates oxidative stress and lipid peroxidation in tissue marked by elevation in MDA activity [39-41]. This present study shows that cadmium increased lipid peroxidation seen in the elevation of MDA activity when compared with the control group while declining the production of antioxidant CAT. The decline in antioxidant enzyme due to cadmium intoxication is attributed to the depletion in antioxidant enzyme synthesized to combat the raging free radicals attacking the cells while disrupting cellular integrity to produce endogenous antioxidants. Cadmium mediated decline in CAT correlates with Ruslee et al., [42]; Maretta and Maretová, [43]. Ruslee et al., [42] demonstrated that cadmium induced oxidative stress with an increase in lipid peroxidation product, malondialdehyde (MDA) along with decreased levels of antioxidant enzyme, catalase. This present research shows that aqueous leaf extract of *Lawsonia inermis* caused a marked increase in CAT activity while decreasing the production of MDA implying a decline in reactive oxygen species (ROS) release from tissues due to oxidative tissue damage in response to inflammation. The potential of *Lawsonia inermis* leaf to averts lipid peroxidation while improving antioxidant enzyme synthesis is attributed to its property as a herbal medicinal plant with antioxidant and anti-inflammatory functions [44]. According to Massanyi et al., [45] cadmium mediate tubal factor infertility by influencing the normal appearance of the oviduct lining, perturbs the normal secretion of progesterone from the ovary resulting in dysfunctional oviduct epithelial cell transportation of oocytes and secretion in the lining that aid sperm fertilization of the oocytes [46]. This present study demonstrates changes in the mucin granules and histological appearance of the Fallopian tubes using PAS for mucin/ glycogen granules which indicates that cadmium caused distortion in the oviduct epithelial lining with loss of connective tissue integrity and mucin granules this supports reports on cadmium's ability to potentiate disruption of the columnar ciliated and secretory cells of the oviduct as well as the lamina propria membrane integrity of the epithelium resulting in loss of thickness and mucosa folds [47,48]. A study by Massányi, et al., [45,49] on rabbits oviduct showed that cadmium induced degeneration of the epithelium. Cadmium induced degeneration of Fallopian tube epithelium via oxidative tissue damage is associated with disruption of nuclear chromatin of the epithelial cells [45]. In this present study, we observed that cadmium caused the rupture of the tubal mucosal folds in the Fallopian tubes, perturbed the stroma and mucin granules. *Lawsonia inermis* leaf extract treated infertility model had a marked regeneration of the epithelial cells and protection of the mucosal folds. PAS is a histochemical stained for glycogen, acidic and neutral mucins [23,50-51]. Cell-associated mucins shield the epithelial surface from pathogens through their extracellular domains and regulate intracellular signaling through their cytoplasmic regions [Lillehoj et al., [52]. Glycosaminoglycan particles and mucins secreted by endometrial mucosal cells helps to protect the micro-environment of the Fallopian tubes for fertilization and oocytes survival [53]. Mucins

are fluidity gel on the surfaces of the secretory epithelium and helps to defend against harmful substances from the outside environment [54], aid hydration, lubrication, transport, and protection to the mucosa [55] and also stimulation of protective mechanisms, including promoting cell survival through their involvement in cell signaling regulating the processes of oocytes transport, implantation and maintaining pregnancy [56] Endometrial glycogen concentrations correlates with fertility indicating that glycogen is an essential source of glucose for maintaining oocytes and implantation [57]. Cadmium can deplete cellular level of glycogen [58,59]. This depletion of glycogen storage or mucin positive cells in the tubal mucosa of experimental animals treated with 2mg/kg of cadmium supports report by Pawar, [59], however it is important to mention that glycogen are rapidly utilized in reproductive tract in normal condition. According to Li, et al., (60) glycogen metabolism and storage in the Fallopian tubes is interlinked to the activation of the Wnt signaling pathway (a transduction mechanism) where he observed the presence of few cells in the epithelium and connective tissue with few glycogen stored in the cells. However the inflamed Fallopian tissue had a dramatic increase in PAS cells in the tubal epithelium and muscularis mucosae. The *Lawsonia inermis* leaves extract treated group were positive to the presence of glycogen and mucin on the surfaces of the tubal mucosal epithelium. There is paucity of information on the effects of *Lawsonia inermis* leaves on mucin and glycogen granules in the Fallopian tube. However from this present study one can document that PAS stain reveals that *Lawsonia inermis* leaves helps to moderately preserve glycogen store and ensure synthesis and release of mucin granules on the apical surface of the tubal mucosal. This present study demonstrates that *Lawsonia inermis* leaves can avert cadmium induced tubal factor disruption of fertility index through its potent antioxidant and anti-inflammatory ability to boost CAT antioxidant level, anti-inflammatory response to avert the distortion of the integrity of the tubal mucosal epithelial cell membrane, glycogen, secretion of mucin granules required to maintain the tubal mucosa milieu for oocytes transport and survival while mobbing off free radicals that can alter oocytes survival and transport.

5. CONCLUSION

Lawsonia inermis aqueous leaf extract demonstrates its notable antioxidant potential against cadmium induced tubal mucosal lining disruption by reducing lipid peroxidation (oxidative tissue damage) in the tubal epithelial mucosa.

ETHICAL APPROVAL

The animal care and use procedures in the research were performed in accordance with the ethics committee of the national research centre and the recommendations of the national institutes of health's guide for care and use of laboratory animals.

REFERENCES

1. Zegers-Hochschild F, Adamson, GD, Dyer, S, Racowsky C, de Mouzon J, Sokol, R, Rienzi L, Sunde A, Schmidt L, Cooke ID, Simpson, J, van der Poel. The International Glossary on Infertility and Fertility Care. Hum Reprod. 2017. 32(9):1786-1801.

2. Manouchehri A, Shokri S, Pirhadi M, Karimi M, Abbaszadeh S, Mirzaei G, Bahmani M...The Effects of Toxic Heavy Metals Lead, Cadmium and Copper on the Epidemiology of Male and Female Infertility. *JBRA Assist Reprod.* 2022. 926(4):627-630.
3. Direkvand M A, Delpisheh A, Sayehmiri K. An Investigation of the Worldwide Prevalence of Infertility as a Systematic Review. *Qom Univ Med Sci J.* 2016. 10:76–87.
4. Lee S, Min JY, Min KB. Female Infertility Associated with Blood Lead and Cadmium Levels. *Int J Environ Res Public Health.* 2020 10;17(5):1794.
5. Banu K, Senay, U, Atan A, Melike SM. Effects of cadmium on female fertility parameters: an experimental study. *Journal Studies on Ethno-Medicine.* 2017. 11(1).
6. Chen W, Lau SW, Fan Y, Wu RS, Ge W. Juvenile exposure to bisphenol A promotes ovarian differentiation but suppresses its growth - Potential involvement of pituitary follicle-stimulating hormone. *Journal NCBI.* 2017.
7. Sengupta P, Banerjee R, Nath S, Das S, Banerjee S. Metals and female reproductive toxicity. *Hum. Exp. Toxicol.* 2015;34:679–697.
8. Rattan S, Brehm E, Gao L, Flaws, JA. Di(2-ethylhexyl) phthalate exposure during prenatal development causes adverse transgenerational effects on female fertility in mice. *Toxicological science.* 2018. 163(2) :420-429
9. Akour A, Violet K, Fatma U, Afifi, Nailya, B. The use of medicinal herbs in gynecological and pregnancy-related disorders by Jordanian women: a review of folkloric practice vs. evidence-based pharmacology. *Journal Pharmaceutical Biology.* 2016. 54(9).
10. Kashani L, Akhondzadeh S. Female Infertility and Herbal Medicine. *Journal of Medical Plants,*1 (61) :3-7
11. Bhuiyan MA, Islam A, Ali AM, Isalam MN. Colour and chemical constitution of natural dye henna and its application in textiles. *Journal of Cleaner Production,*2017, 167: 14-22.
12. Charoensup R, Duangyod T, Palanuvej C, Ruangrunsi N. Pharmacognostic Specifications and Lawsonone Content of *Lawsonia inermis* Leaves. *Pharmacognosy Research,* 2017. 9(1): 60–64.
13. Borhani MS, Mohammad R, Etemadifar Z, Karamifard F. Assessment of the antimicrobial activity of *Melissa officinalis* and *Lawsonia inermis* extracts against some bacterial pathogens. *Comparative Clinical Pathology,* 2016 25(1) :59–65
14. Chuku LC, Chinaka NC, Damilola D. Phytochemical Screening and Anti-inflammatory Properties of Henna Leaves (*Lawsonia inermis*). *European Journal of Medicinal Plants,* 2020 31(18), 23–28. <https://doi.org/10.9734/ejmp/2020/v31i1830340>

15. Supian FNA, Osman NI. Phytochemical and Pharmacological Activities of Natural Dye Plant, Lawsonia inermis L. (Henna). *J Young Pharm.* 2023;15(2):201-11.
16. National Institutes of Health's Guide for Care and Use of Laboratory Animals, National Institutes of Health (NIH Publication No. 85-23, revised 1996)
17. Sulaiman SF, Sajak AAB, Ooi KL, Supriatno SEM. Effect of solvents in extracting polyphenols and antioxidants of selected raw vegetables. *J Food Compos. Anal.* 2011 24: 506-515
18. Azwanida NN. A Review on the Extraction Methods Use in Medicinal Plants, Principle, Strength and Limitation. *Med Aromat Plants*, 4 2015: 196.
19. Handa SS, Khanuja SPS, Longo G, Rakesh DD. Extraction Technologies for Medicinal and Aromatic Plants. Italy: United Nations Industrial Development Organization and the International Centre for Science and High Technology. 2008
20. Zhu Q, Li X, Ge RS. Toxicological Effects of Cadmium on Mammalian Testis. *Front Genet.* 2020 26;11:527.
21. Nofal, A. E., AboShabaan, H. S., Fayyad, R. M., Ereba, R. E., Omar, N. A., Elsharkawy, S. M., & Elberri, A. I. (2023). Immunostimulatory and anti-inflammatory impact of *Fragaria ananassa* methanol extract in a rat model of cadmium chloride-induced pulmonary toxicity. *Frontiers in immunology*, 14, 1297315. <https://doi.org/10.3389/fimmu.2023.1297315>
22. Sravanthi P, Kumar KM, Begum DT, Kumar SN, Ravindra reddy K, Khanhare RS (2011). Antiulcer activity of ethanolic extracts of Lawsonia inermis against cold stress induced ulceration in wistar rats. *Journal of Pharmacy research.* 4(6): 1872-1874.
23. Adejoke Elizabeth Memudu and Tayo Jane Oluwola (2021). The contraceptive potential of Carica papaya seed on oestrus cycle, progesterone, and histomorphology of the Utero-ovarian tissue of adult Wistar rat. *JBRA Assisted Reproduction* 2021;25(1):34-43 DOI: 10.5935/1518-0557.20200023
24. **Memudu, A.E and** Gambo A. Dongo (2023). A study to demonstrate the potential of Anabolic Androgen Steroid to activate oxidative tissue damage, nephrotoxicity and decline endogenous antioxidant system in renal tissue of Adult Wistar Rats. *Toxicology Reports*, 10: 320-326. <https://doi.org/10.1016/j.toxrep.2023.02.010>.
25. Bancroft and Gamble. (2008). Theory and practise of histological techniques. 6th edn. Churchill Livingstone, London
26. Chorosh SH, Malik N, Panesar G, Kumari P, Jangra S, Kaur R, Al-Ghamdi MS, Albishi TS, Chopra H, Singh R, Murthy HCA. Phytochemicals: Alternative for Infertility Treatment and Associated Conditions. *Oxid Med Cell Longev.* 2023 May

11;2023:1327562. doi: 10.1155/2023/1327562. PMID: 37215366; PMCID: PMC10195183.

27. Ambildhuke K, Pajai S, Chimegave A, Mundhada R, Kabra P. A Review of Tubal Factors Affecting Fertility and its Management. *Cureus*. 2022 Nov 1;14(11):e30990. doi: 10.7759/cureus.30990. PMID: 36475176; PMCID: PMC9717713.

28. :Cheng Y, Zhang J, Wu T, et al. Reproductive toxicity of acute Cd exposure in mouse: Resulting in oocyte defects and decreased female fertility. *Toxicol Appl Pharmacol*. 2019;379: 114684.

29. McClam, M., Liu, J., Fan, Y. et al. Associations between exposure to cadmium, lead, mercury and mixtures and women's infertility and long-term amenorrhea. *Arch Public Health* 81, 161 (2023). <https://doi.org/10.1186/s13690-023-01172-6>

30. Neblett MF, Curtis SW, Gerkowicz SA, et al. Examining reproductive health outcomes in females exposed to polychlorinated biphenyl and polybrominated biphenyl. *Sci Rep*. 2020;10(1):3314

31. : Bala R, Singh V, Rajender S, Singh K. Environment, lifestyle, and female infertility. *Reprod Sci*. 2021;28(3):617–38.

32. Okereafor U, Makhatha M, Mekuto L, Uche-Okereafor N, Sebola T, Mavumengwana V. Toxic metal implications on agricultural soils, plants, animals, aquatic life and human health. *Int J Environ Res Public Health*. 2020;17(7):2204.

33. :Manuja, A., Rathore, N., Choudhary, S., & Kumar, B. (2021). Phytochemical Screening, Cytotoxicity and Anti-inflammatory Activities of the Leaf Extracts from *Lawsonia inermis* of Indian Origin to Explore their Potential for Medicinal Uses. *Medicinal chemistry (Sharjah (United Arab Emirates))*, 17(6), 576–586. <https://doi.org/10.2174/1573406416666200221101953>

34. Khantamat, O., Dukaew, N., Karinchai, J., Chewonarin, T., Pitchakarn, P., & Temviriyankul, P. (2021). Safety and bioactivity assessment of aqueous extract of Thai Henna (*Lawsonia inermis* Linn.) Leaf. *Journal of toxicology and environmental health. Part A*, 84(7), 298–312. <https://doi.org/10.1080/15287394.2020.1866129>

35. Kaltsas A, Zikopoulos A, Moustakli E, Zachariou A, Tsirka G, Tsiampali C, Palapela N, Sofikitis N, Dimitriadis F. The Silent Threat to Women's Fertility: Uncovering the Devastating Effects of Oxidative Stress. *Antioxidants*. 2023; 12(8):1490. <https://doi.org/10.3390/antiox12081490>

36. Ra, K.; Park, S.C.; Lee, B.C. Female Reproductive Aging and Oxidative Stress: Mesenchymal Stem Cell Conditioned Medium as a Promising Antioxidant. *Int. J. Mol. Sci*. 2023, 24, 5053

37. Su, L.J.; Zhang, J.H.; Gomez, H.; Murugan, R.; Hong, X.; Xu, D.; Jiang, F.; Peng, Z.Y. Reactive Oxygen Species-Induced Lipid Peroxidation in Apoptosis, Autophagy, and Ferroptosis. *Oxidative Med. Cell. Longev.* 2019, 2019, 5080843.
38. Zhang, W.; Wu, F. Effects of adverse fertility-related factors on mitochondrial DNA in the oocyte: A comprehensive review. *Reprod. Biol. Endocrinol.* 2023, 21, 27
39. Dzobo, Kevin, & Naik, Yogeshkumar S.. (2013). Effect of selenium on cadmium-induced oxidative stress and esterase activity in rat organs. *South African Journal of Science*, 109(5-6), 01-08. Retrieved December 28, 2023, from http://www.scielo.org.za/scielo.php?script=sci_arttext&pid=S0038-23532013000300012&lng=en&tlng=en.
40. Massányi, P., Massányi, M., Madeddu, R., Stawarz, R., & Lukáč, N. (2020). Effects of cadmium, lead, and mercury on the structure and function of reproductive organs. *Toxics*, 8(4), 94.
41. Rotimi, D., Ojo, O. A., Emmanuel, B. A., Ojo, A. B., Elebiyo, T. C., Nwonuma, C. O., & Oluba, O. M. (2021). Protective impacts of gallic acid against cadmium-induced oxidative toxicity in the ovary of rats. *Comparative Clinical Pathology*, 30, 453-460.
42. Ruslee S.S., Zaid S.S.M., Bakrin I.H., Goh Y.M., Mustapha N.M. Protective effect of Tualang honey against cadmium-induced morphological abnormalities and oxidative stress in the ovary of rats. *BMC Complement. Med. Ther.* 2020;20:1–11. doi: 10.1186/s12906-020-02960-1.
43. Mareta, M., & Marettová, E. (2022). Toxic Effects of Cadmium on the Female Reproductive Organs a Review. *Folia Veterinaria*, 66(4), 56-66.
44. Nasiadek, M., Danilewicz, M., Klimczak, M., Stragierowicz, J., & Kilanowicz, A. (2019). Subchronic Exposure to Cadmium Causes Persistent Changes in the Reproductive System in Female Wistar Rats. *Oxidative medicine and cellular longevity*, 2019, 6490820. <https://doi.org/10.1155/2019/6490820>
45. Massányi, P. and Lukáč, N. and Uhrín, V. and Toman, R. and Pivko, J. and Rafay, J. and Forgács, Zs. and Somosy, Z. (2007) Female reproductive toxicology of cadmium. *Acta Biologica Hungarica*, 58 (3). pp. 287-299. ISSN 0236-5383
46. Paksy K., Varga B., Náray M., Olajos F., Folly G. Altered ovarian progesterone secretion induced by cadmium fails to interfere with embryo transport in the oviduct of the rat. *Reprod. Toxicol.* 1992;6:77–83. doi: 10.1016/0890-6238(92)90024-N.
47. Sarkar A.K., Maitra S.K., Midya T. (1976) Histological, histochemical and biochemical effects of cadmium chloride in female koel (*Eudynamys scolopacea*) *Acta Histochem.* 1976;57:205–211. doi: 10.1016/S0065-1281(76)80049-9.

48. Sapmaz-Metin M., Topcu-Tarlacalisir Y., Kurt-Omurlu I., Weller B.K., Unsal-Atan S. A morphological study of uterine alterations in mice due to exposure to cadmium. *Biotech. Histochem.* 2017;92:264–273. doi: 10.1080/10520295.2017.1305500.
49. Massányi, P., Uhrín, V., Toman, R., Kovácik, J., Bíro, D. (1999). Histological changes in the oviduct of rabbits after administration of cadmium. *Journal of Animal and Feed Sciences*, 8(2), 255-261. <https://doi.org/10.22358/jafs/68933/1999>
50. Meyerholz DK, Stoltz DA, Gansemer ND, Ernst SE, Cook DP, Strub MD, et al. Lack of cystic fibrosis transmembrane conductance regulator disrupts fetal airway development in pigs. *Lab Invest.* 2018;98(6):825–838. doi: 10.1038/s41374-018-0026-7.
51. Abouelela, Y.S., Shaker, N.A., El-Shahat, K.H. et al. Anatomical, histological, and histochemical alterations in portio vaginalis uteri with an evaluation of the vaginal artery vascularity during the luteal and early pregnant stages in domestic buffaloes (*Bubalus bubalis*). *BMC Vet Res* 19, 260 (2023). <https://doi.org/10.1186/s12917-023-03816-9>
52. Lillehoj EP, Kato K, Lu W, Kim KC. Cellular and molecular biology of airway mucins. *International Review of Cell and Molecular Biology.* 2013 ;303:139-202. DOI: 10.1016/b978-0-12-407697-6.00004-0. PMID: 23445810; PMCID: PMC5593132.
53. Lu D, Hu W, Tian T, Wang M, Zhou M, Wu C. The Mechanism of Lipopolysaccharide's Effect on Secretion of Endometrial Mucins in Female Mice during Pregnancy. *International Journal of Molecular Sciences.* 2022; 23(17):9972. <https://doi.org/10.3390/ijms23179972>
54. Dickinson, J.D.; Sweeter, J.M.; Staab, E.B.; Nelson, A.J.; Bailey, K.L.; Warren, K.J.; Jaramillo, A.M.; Dickey, B.F.; Poole, J.A. MyD88 controls airway epithelial Muc5ac expression during TLR activation conditions from agricultural organic dust exposure. *Am. J. Physiol. Lung Cell. Mol. Physiol.* 2019, 316, L334–L347.
55. Theodoropoulos, G.; Carraway, K.L. Molecular Signaling in the Regulation of Mucins. *J. Cell. Biochem.* **2007**, *102*, 1103–1116
56. Zhou, M., Tian, T., & Wu, C. (2023). Mechanism Underlying the Regulation of Mucin Secretion in the Uterus during Pregnancy. *International journal of molecular sciences*, 24(21), 15896. <https://doi.org/10.3390/ijms242115896>
57. Dean M. (2019). Glycogen in the uterus and fallopian tubes is an important source of glucose during early pregnancy†. *Biology of reproduction*, 101(2), 297–305. <https://doi.org/10.1093/biolre/iox102>
58. Lowe-Jinde, L., Niimi, A.J. Short-term and long-term effects of cadmium on glycogen reserves and liver size in rainbow trout (*Salmo gairdneri* Richardson). *Arch. Environ. Contam. Toxicol.* 13, 759–764 (1984). <https://doi.org/10.1007/BF01055940>

59. Pawar, Rajkumar. (2021). EFFECT OF CADMIUM CHLORIDE ON GLYCOGEN LEVEL IN SOME ORGANS OF FRESHWATER BIVALVE, LAMELLIDENS MARGINALIS. International Journal of Biological Innovations. 3. 367-372. 10.46505/IJBI.2021.3218.

60. Li, Ping & Zhu, Wei-Jie & Ma, Zheng-Lai & Wang, Guang & Peng, Hui & Chen, Yao & Lee, Kenneth & Yang, Xuesong. (2013). Enhanced beta-catenin expression and inflammation are associated with human ectopic tubal pregnancy. Human reproduction (Oxford, England). 28. 10.1093/humrep/det246.

UNDER PEER REVIEW