

## Incidentally Detected Malrotation in a Case of Traumatic Gastric Perforation

### Abstract

#### Introduction

Intestinal malrotation is defined as intestinal nonrotation or incomplete rotation around superior mesenteric artery and involving anomalies of intestinal fixation. The incidence of intestinal malrotation is estimated to be around 1 in 6000 live births. Most patients remain asymptomatic and are incidentally detected at a surgical procedure or during autopsy. Adult presentation accounts for 0.2 to 0.5% of all cases, of which only 15% present with midgut volvulus.

#### Case Presentation

A 36 year old male presented to casualty with blunt trauma to abdomen 2 days back. On examination, patient had BP 90/60mmHg and pulse 130bpm, respiratory rate of 32 breaths per minute and saturation of 78% in room air; with per-abdomen examination showing diffuse tenderness with guarding and rigidity and X-ray chest showing gas under diaphragm; which suggested perforation peritonitis with septic shock for which he underwent emergency laparotomy and there were presence of 4x4 cm size anterior gastric perforation with presence of transverse colon going below stomach and jejunum with small bowel loops present on the right. Antrocolicisoperistalticgastrojejunostomy was done. Postoperative period uneventful with patient discharged on POD 10 with him passing stool and on normal oral diet.

#### Conclusion

Intestinal malrotation is a rare developmental anomaly of embryonic gut. The most severe presentation is malrotation with bowel volvulus. 30% cases occur in the 1st month of life, 60% by one year of age, and over 75% percent by age of five. Adult presentation is only 0.2 to 0.5% , of which 15% present with midgut volvulus. Most common presentation is bilious vomiting in infants while in older children, there is presence of chronic and intermittent abdominal pain. The role of additional surgery especially in asymptomatic patients with malrotation is debated. Delayed presentation of malrotation shows varied symptoms. It needs high index of suspicion with relevant investigations (USG and CT) to avoid any further complications.

Keywords :Malrotation, Midgut Volvulus, Gastrojejunostomy, Ladd

## Introduction

Intestinal malrotation refers to an incomplete or complete lack of rotation around the superior mesenteric artery (SMA) axis, along with anomalies of intestinal fixation. The incidence is estimated to be 1 in 6,000 live births. Malrotation mostly presents with symptoms in the first year of life, with complaints of abdominal pain, acute bowel obstruction, and intestinal ischemia due to midgut or cecal volvulus. Delayed childhood or adult presentation of malrotation is rare, with most patients remaining asymptomatic and being detected incidentally at the time of surgery or during autopsy.<sup>1</sup> Delayed presentation of malrotation may present with volvulus and intestinal ischemia. It needs a high index of suspicion for a diagnosis to be obtained.<sup>2</sup>

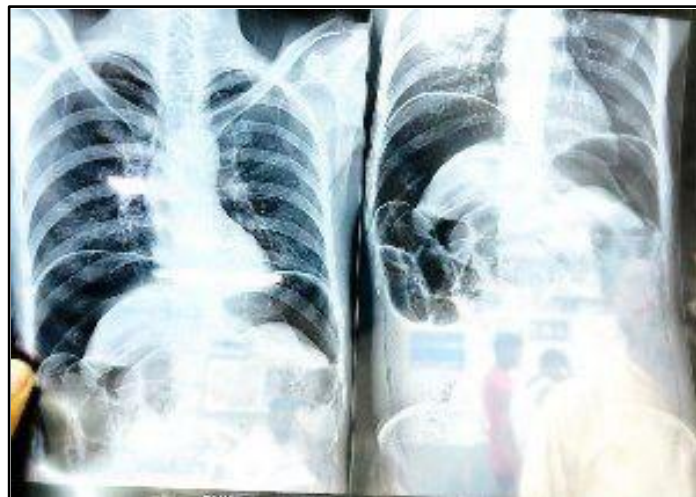Here is a case report of a 36-year-old male with blunt trauma to the abdomen following a road traffic accident, with an intraoperative finding of gastric perforation alongside an incidentally detected malrotation.

## Case Presentation

A 36-year-old Indian male came to the casualty with a complaint of abdominal pain and non-passage of the flatus and stool following a blunt trauma to the abdomen two days ago. After informed verbal and written consent, the patient was examined. On examination of patient vitals, he had a blood pressure of 90/60 mm Hg, a pulse rate of 130 beats per minute, a respiratory rate of 32 breaths per minute, a temperature of 99 °F, and a saturation of 78% in room air. On physical examination, the patient had abdominal distension, diffuse guarding, and rigidity.

An X-ray was done, which showed the presence of gas under the diaphragm, suggesting hollow viscus perforation.

Fig 1: X-ray: Gas under Diaphragm



The patient underwent an emergency laparotomy, and a perforation of size 4x4 cm was present over the anterior surface of the stomach. Also, the transverse colon passed below the stomach with small bowels to the right. The fourth part of the duodenum and the duodenojejunal junction were not present.

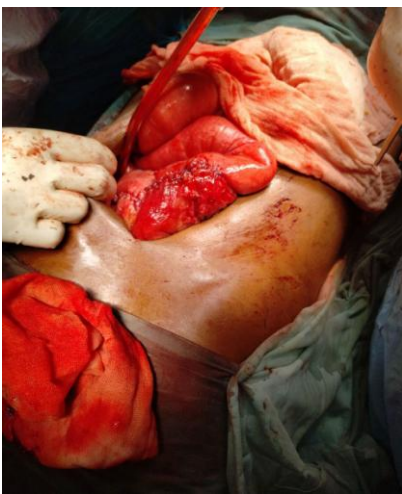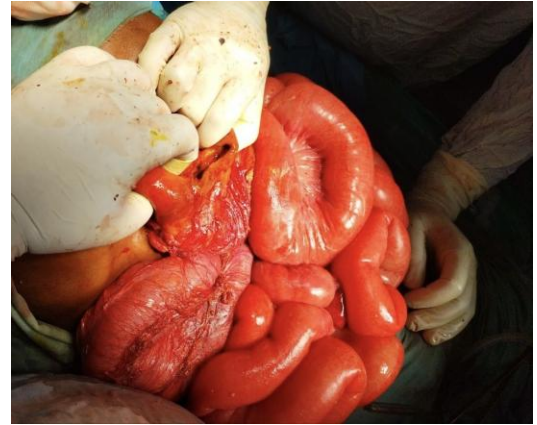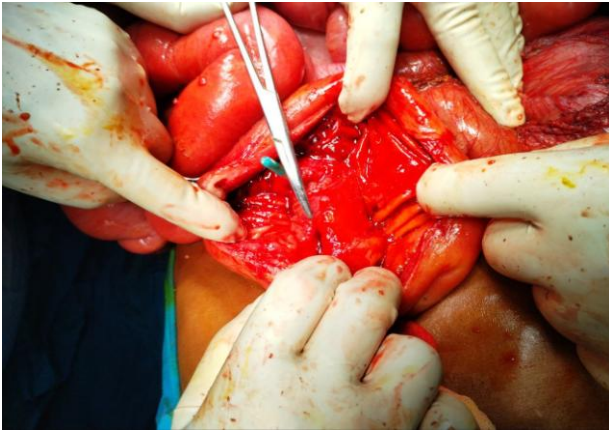


Fig 2: Dissection during Laparotomy

An antrocolicisoperistalticgastrojejunostomy was done. The post-operative period was uneventful. The patient was started on oral feeding on day 4. Drains were removed on post-operative day 5. Stitches were removed on day 10. The patient was discharged uneventfully.

### Discussion

At 6 weeks of gestation, the primitive bowel herniates into the umbilical cord and rotates anticlockwise  $90^\circ$  around the **Superior Mesenteric Artery (SMA) axis**. At 6th to 10th weeks of gestation, the bowel grows and undergoes further  $90^\circ$  anticlockwise rotation. By the 10th week of gestation, the bowel reenters into the abdomen, and then another  $90^\circ$  anticlockwise rotation places the proximal duodenum posterior to the SMA. The distal ileum and proximal large intestine follow and undergo a 180-degree counterclockwise rotation, placing the cecum in the right abdomen with its mesentery anterior to the SMA.<sup>3</sup>

From the 10th week on, the bowel undergoes a process of fixation, with the proximal duodenum becoming incorporated into the retroperitoneum with a sweeping C-shaped loop around the pancreas. This creates a duodenojejunal (DJJ) junction at the ligament of Treitz. The ascending and descending colons become fused to the lateral abdominal walls and retroperitoneum, and the cecum

descends into the right lower quadrant. The small bowel blood supply becomes part of a broad wide mesentery extending from the left upper abdomen to the right lower abdomen. These points of fixation, specifically the duodenal sweep, the ligament of Treitz, and the right and left colon, stabilise the intestines and prevent catastrophic volvulus.<sup>3</sup>

Nonrotation or malrotation of the bowel is usually accompanied by one or many Ladd bands; peritoneal attachments are formed, perhaps to fixate the bowel mesentery. These bands lead to the formation of volvulus, cause partial obstruction, and may entrap the duodenum and proximal jejunum.<sup>3</sup>

The most serious complication is the midgut volvulus, which involves the rotation of the root of a shortened bowel mesentery on its axis due to a lack of fixation. Most infants are involved and present with feeding intolerance and bilious vomiting.<sup>3</sup> Thirty percent of cases are seen in the first month of life, 60% by one year of age, and over 75% by the age of five. Adult patients are usually asymptomatic. Very rarely (0.2 to 0.5%), they present with chronic abdominal pain and, at times, with features of sudden obstruction due to the formation of midgut volvulus (15%).<sup>4</sup>

Malrotation is also associated with the cecal volvulus and the formation of paraduodenal hernias. The first line of investigation for malrotation is ultrasonography (USG). USG shows superior mesenteric to the left of the superior mesenteric vein at its origin, along with the whirlpool sign being positive if volvulus is also present. Midgut volvulus is managed by the Ladd procedure. It involves three goals-lysis of Ladd bands, inspection of the duodenum and proximal jejunum, and making a decision regarding the appendix.<sup>3</sup>

Surgery regarding any incidental finding of malrotation is still up to debate.<sup>5</sup> In a similar case of malrotation found incidentally in a patient of postoperative ectopic pregnancy with subacute intestinal obstruction due to band adhesion, only adhesiolysis was done with malrotation left as it is.<sup>6</sup>

According to Eduardo et al., there is need to modify surgical procedures for bariatric surgery according to the anatomy of each patient. Hence, the condition defines the modification of the procedure entailed.<sup>7</sup>

It is also essential to know any associated anomalies associated with malrotation, like asplenia, absence of an uncinate process of the pancreas, a short pancreas, and the preduodenal portal vein.<sup>8</sup>

## Conclusion

The adult presentation of malrotation is rare and difficult to diagnose. Malrotation can't be suspected due to its varied presentation. It may have a risk of volvulus and intestinal ischemia, and hence, a high index of suspicion is needed.<sup>4</sup> Most malrotation cases in adults are often incidental detections at the time of surgery for a different case or at the time of autopsy.<sup>1</sup> Malrotation would present with altered anatomical findings, and hence a modification of the existing surgical procedure will be needed according to the extent of trauma to the abdomen (in the case of trauma surgery).

In the case of an adult patient who is asymptomatic, just observation may be enough, as additional surgery doesn't bring any additional benefit to the patient.<sup>1</sup> Knowledge of malrotation is essential when planned abdominal surgery is performed in the future.<sup>8</sup>

## Consent

As per international standards or university standards, patient(s) written consent has been collected and preserved by the author(s).

## Ethical Approval:

As per international standard or university standards written ethical approval has been collected and preserved by the author(s).

## References

1. Vural, V., Türkoğlu, M. A., & Karatas, G. (2015, January 1). Incidental midgut malrotation detected during second laparotomy: Case report and literature review. *International Journal of Surgery Case Reports*. <https://doi.org/10.1016/j.ijscr.2014.12.004>
2. Menghwani, H., Piplani, R., Yhoshu, E., Jagdish, B., & Sree, B. S. (2023, January 1). Delayed presentation of malrotation: Case series and literature review. *Journal of Indian Association of Pediatric Surgeons*. [https://doi.org/10.4103/jiaps.jiaps\\_2\\_23](https://doi.org/10.4103/jiaps.jiaps_2_23)
3. van Leeuwen. (2023, September 12). Malrotation. In *Fischer's Mastery of Surgery* (8th ed., p. 2822). WolterKluwers Health. <https://bookshelf.vitalsource.com/books/9781975176457>
4. Alani, M. (2023, July 31). Midgut Malrotation. *StatPearls - NCBI Bookshelf*. <https://www.ncbi.nlm.nih.gov/books/NBK560888/>
5. Graziano, K., Islam, S., Dasgupta, R., Lopez, M. E., Austin, M., Chen, L. E., ... Abdullah, F. (2015). Asymptomatic malrotation: Diagnosis and surgical management. *Journal of Pediatric Surgery*, 50(10), 1783–1790. doi:10.1016/j.jpedsurg.2015.06
6. De Simone, V., Goglia, M., Litta, F., & Ratto, C. (2020, April 3). Incidental diagnosis of true intestinal malrotation. *Techniques in Coloproctology*. <https://doi.org/10.1007/s10151-020-02198-6>
7. Vidal, E. A., Rendón, F. A., Zambrano, T. A., García, Y. A., Viteri, M. F., Campos, J. M., Ramos, M. G., & Ramos, A. (2016, January 1). Intestinal Malrotation in Patients Undergoing Bariatric Surgery. *ABCD*. <https://doi.org/10.1590/0102-6720201600s10007>
8. Zissin, R., Rathaus, V., Oscadchy, A., Kots, E., Gayer, G., & Shapiro-Feinberg, M. (1999). Intestinal malrotation as an incidental finding on CT in adults. *Abdominal Imaging*, 24(6), 550–555. doi:10.1007/s002619900560