

Immunohistochemical expression of P63 in Ovarian Tumors among Sudanese Women

Abstract:

Background: Ovarian cancer is a highly lethal disease, and the underlying biology of the disease is poorly understood. The tumor suppressor p63 is a homolog gene of p53. P63 has an important role in the development and differentiation of reproductive epithelium and interacts with p53 in human tumorigenesis. **Objective:** The study was aimed at assessing the immunohistochemical expression of p63 in benign and malignant epithelial ovarian tumors. **Methods:** We evaluated the p63 immunoexpression in (80) formalin-fixed paraffin-embedded blocks from patients previously diagnosed with ovarian tumors; 40 (50%) samples were malignant, and 40 (50%) samples were benign. The histopathological subtypes of malignant samples include 32 (40%) samples of epithelial ovarian cancer and 8 (10%) samples of granulosa cell tumors. We utilized mouse monoclonal antibody against the p63 antigen which recognizes all p63 variants, (Dako), the tumors were considered p63 positive if 5% or more cells presented nuclear immunostaining. **Results:** We observed 90% positive immunoexpression of p63 expression in benign ovarian tumors, and 10% of the ovarian p. value was 0.000. Regarding the histopathological subtypes of malignant tumors, p63 expression was detected in 7.5% samples of epithelial ovarian tumors and 2.5% samples of granulosa cell tumors, the p. value was 0.792. **Conclusion:** The study suggests low expression of p63 in malignant ovarian tumors.

Keywords: Ovarian Tumor, Immunohistochemical, p63, Sudan.

Introduction:

Tumor protein 63 (p63) is a transcription factor of the p53 gene family, which is located at chromosome 3q28. P63 regulates the activity of many genes involved in the growth and development of the ectoderm and derived structures and tissues, such as basal layer keratins and cell cycle control genes [1], p63 is expressed in basal cell layers of various organs, squamous epithelial cells of many organs, and urothelium [1–4], p63 is used

Comment [ak1]: Please state the study design

Comment [ak2]: This sentence needs more explanation, how many samples expressed the p63? do you mean that 90% of sample expressing the gene were from benign group and the 10% were from malignant group?

Comment [ak3]: Please state what comparison method used in the study

routinely for tumor type determination and also differentiates squamous cell carcinoma from adenocarcinoma in lung biopsies, or urothelial carcinoma from renal cell carcinoma, as well as determining the tumor origin of metastases from unknown primary tumors, More than 2000 studies have evaluated p63 expression by IHC in various tumors, leading to quite discrepant p63 positivity rates in several tumor entities [2, 3–16]. For example, the proportion of p63 positive cases in small cell lung cancer ranged from 0 to 77% [6, 17], 50 to 100% in squamous cell lung cancer [7, 12], 0 to 84% in Merkel cell carcinoma [8, 13], 0 to 82% in papillary thyroid carcinoma [9, 14], 1.4 to 100% in colorectal adenocarcinoma [5, 11], 0 to 100% in urothelial carcinoma [10, 15],⁰ In 2016, it is estimated that there will be more than 22,200 new cases of ovarian cancer and more than 14,200 deaths from ovarian cancer in the United States [23]. In entire Sudan, the incidence rate of ovarian cancer has yet to be identified; however, in hospitals, National Cancer Institute and the Radiation Isotopes Center in Khartoum, according to a collected, data set (2009–2010), ovarian cancer ranked sixth among all cancers diagnosed and fourth among female cancers [24].

Comment [ak4]: Do we need to delete the 0 before the sentence In 2016? It is quite confusing

Materials and Methods:

This hospital-based analytical retrospective case-control study was carried out in Khartoum state at the Radiation & Isotopes –Center of Khartoum (RICK) and Elrahama medical center during the period from January 2016 to December 2019 (80) archival formalin fixed paraffin embedded tissue blocks from Sudanese women with ovarian tumors who attended RICK were enrolled. Forty (40) paraffin blocks were previously diagnosed as ovarian carcinomas as the case group, and forty (40) paraffin blocks were diagnosed as benign tumors as the control group. The histopathological subtypes of malignant samples include, 32(40%) samples were epithelial ovarian cancer, and 8 (10%) samples were granulosa cell tumors

Comment [ak5]: The case control study need explanation which group is case and which group is the control. Two groups in the study were having ovarian tumor. The case control study usually produced odds ratio, if this study result in difference, maybe it is a cross sectional study.

Histopathological tissue preparation:

From each tissue block, two paraffin sections were cut into 3µm thicknesses using a rotary microtome (Leica), sections were taken on glass slid and covered with diluted alcohol (30%) then the sections floated into a preheated floating water bath at 40c then sections were placed in coated glass slide for Immunohistochemistry, and other section

was placed in the clean microscopic slide for Hematoxylin and Eosin, then incubated in the oven at 58°C for overnight for partial deparaffinization,

Haematoxylin and Eosin:

Mounted samples were deparaffinized in xylene; slides were rehydrated through a graded series of alcohol and placed in distilled water for two minutes each. Then samples were stained with Mayer's hematoxylin (RAL-France) for 10 minutes, blued in running tap water for 10 minutes, and then stained with Eosin for 3 minutes, dehydrated through ascending ethanol, cleared in xylene, and mounted in DPX. The samples were confirmed for histological grade by an MD clinical pathologist.

Immunohistochemical staining:

Immunohistochemical staining was carried out as follows: Tissue sections (3µm) from formalin-fixed, paraffin-embedded tumors were cut and mounted onto salinized slides (Thermo – USA). Following deparaffinization in xylene, slides were rehydrated through a graded series of ethyl alcohol: 100% for 4 min, 90% for 2 min, 70% for 2 min, and water for 2 min. The antigens were retrieved using high PH (9) by water bath (histone-TEC 2601-Italy) at 95°C for 40 minutes. After washing with PBS for 3 min Endogenous peroxidase activity was blocked by a 3% peroxidase blocker (hydrogen peroxide and methanol) for 10 minutes (Dako, USA), and after washing with PBS for 3 minutes, the slides were then incubated with (100µL) of mouse monoclonal antibody (p63, Dako), against p63 antigen for 30 minutes at room temperature in a moisture chamber, then washed in phosphate buffer saline for 3 minutes. The binding of antibodies will be detected by incubating for 20 min with dextran labeled polymer (Dako - USA), then slides washed in three changes of phosphate buffer saline, then incubated in 3,3 diaminobenzidine tetrahydrochloride (DAB) as a chromogen to produce the characteristic brown stain for the visualization of the antigen-antibody complex for up to 5 minutes. After that washed in distilled water for 3 minutes, slides were counterstained in Mayer's hematoxylin (RAL-France) for one minute, then slides were washed in running tap water for several minutes (7–10) (bluing). After that, it was dehydrated, cleared, and mounted in DPX [28].

Result interpretation:

All quality control measures were adopted. Positive and negative control slides were used during immunohistochemical staining. Positive p63 staining should be identified in form of dark brown nuclear staining. The tumors were considered p63 positive if 5% or more cells presented nuclear immunostaining.

Statistics:

After examination of the sections, the results of the laboratory investigation as well as the demographic data from the patient's records were processed using Statistical Packages for Social Sciences (SPSS) computer program. Frequency, mean, and chi-square test values were calculated value <0.05 and considered statically significant.

Ethical Considerations:

Ethical approval for the study was obtained from the Board of the Faculty of medical laboratories sciences, at University of Al-Neelain. The written informed consent form was obtained from each guardian of the participant as well as from the subject himself before recruitment into the study. All protocols in this study were done according to the Declaration of Helsinki (1964).

Results:

The study includes eighty samples, of which 40 (50%) were malignant tumors and 40 (50%) were benign tumors. The age of the study population ranges between 30 and 79 years, with a mean age of 54 years. Most patients were older than 50 years, representing 48 patients (60%), and the remaining 32 (40%) were younger than 50 years (**Table1**). The histopathological diagnosis of the study population includes 32 (40%) epithelial ovarian cancer, 8 (10%) granulosa cell tumors, and 40 (50%) benign ovarian tumors (**Table2**). The tumor grade of study samples revealed 14 (35%) samples were grade I, 8 (20%) samples were Grade, II, and 18(45%) samples were grade III (**Table3**). P63 positive expression was found in (4/40) samples (10%) of malignant tumors and (36/40) samples (90%) showed negative expression, while in benign ovarian tumors, positive expression was found in (36/40) samples (90%) and (4/40) samples (10%) showed negative expression for P63. This result revealed showed significant association ($P. value = 0.000$) (**Table4**). The relation between p63 expression and types of the malignant tumor showed positive expression of p63 in 3 (7.5%) samples of epithelial

ovarian tumors, only one (2.5%) sample of granulosa cell tumor, with no association between p63 expression and type of malignant tumor ($P. value=0.792$) (Table5). p63 positive expression was found in 4 (10%) samples of grade I, while negative expression revealed 10 (25%) samples of grade I, 8 (20%) samples of grade II, and 18 (45%) samples of grade III. This result showed no significant association between p63 expression and tumor grade ($P. value = 0.06$) (Table6).

Table (1) Distribution of age among the study population.

| <i>Age group</i> | <i>Frequency</i> | <i>Percentage</i> |
|---------------------------|------------------|-------------------|
| 50 and more than 50 years | 48 | 60% |
| Less than 50 years | 32 | 40% |
| Total | 80 | 100% |

Table (2) Distribution of histopathological diagnosis among the study population.

| <i>Histopathological diagnosis</i> | <i>Type</i> | <i>Frequency</i> | <i>Percentage</i> |
|------------------------------------|---------------------------|------------------|-------------------|
| <i>Benign</i> | Benign ovarian tumor | 40 | 50% |
| <i>Malignant</i> | Epithelial ovarian cancer | 32 | 40% |
| | Granulosa cell tumor | 8 | 10% |
| Total | | 80 | 100% |

Table (3) Distribution of malignant tumor grade.

| <i>Grade</i> | <i>Frequency</i> | <i>Percentage</i> |
|--------------|------------------|-------------------|
| Grade I | 14 | 35% |
| Grade II | 8 | 20% |
| Grade III | 18 | 45% |
| Total | 40 | 100% |

Table (4) Relation between histopathological diagnosis and p63 expression.

| <i>Variables</i> | <i>P63 expression</i> | | <i>P. value</i> |
|------------------------------------|-----------------------|-------------------|-----------------|
| | Positive N (%) | Negative N (%) | |
| <i>Histopathological diagnosis</i> | | | 0.000 |
| <i>Benign</i> | 36 (90%) | 4 (10%) | |
| <i>Malignant</i> | 4 (10%) | 36 (90%) | |
| Total | 40(100%) | 40 (100%) | |

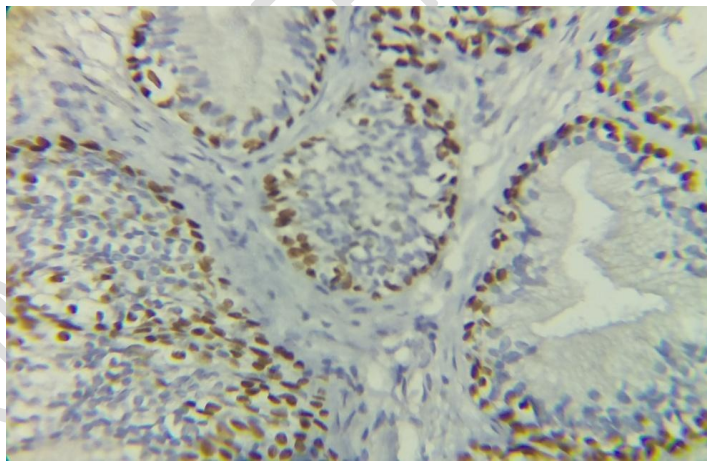
Table (5) Relation between p63 expression and types of malignant tumor.

| <i>Variables</i> | <i>Type of malignant tumor</i> | <i>Total</i> | <i>P. value</i> |
|------------------|--------------------------------|--------------|-----------------|
|------------------|--------------------------------|--------------|-----------------|

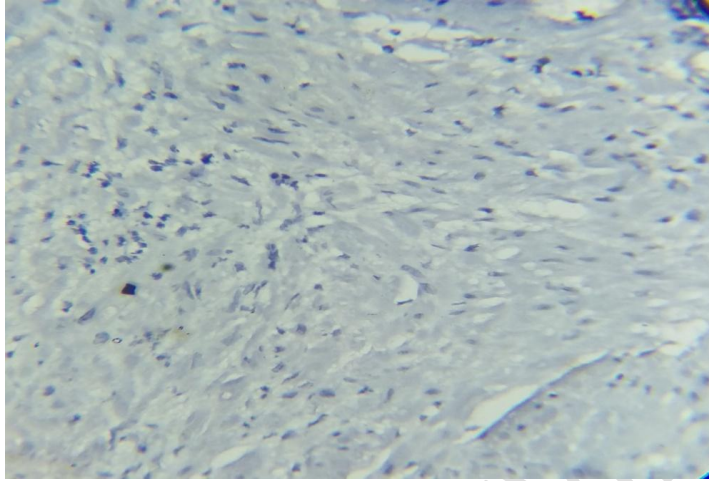
| <i>P63 expression</i> | <i>Epithelial ovarian cancer</i> | <i>Granulosa cell tumor</i> | | |
|-----------------------|----------------------------------|-----------------------------|-----------------|-------|
| <i>Positive</i> | 3 | 1 | 4(10%) | 0.792 |
| <i>Negative</i> | 29 | 7 | 36(90%) | |
| Total | 32 | 8 | 40(100%) | |

Table (6) Relation between p63 expression and ovarian cancer grade.

| <i>P63 expression</i> | <i>Tumor grade</i> | | | <i>Total</i> | <i>P. value</i> |
|-----------------------|--------------------|-----------------|------------------|------------------|-----------------|
| | <i>Grade I</i> | <i>Grade II</i> | <i>Grade III</i> | | |
| Positive | 4 (10%) | 0 (0.0%) | 0 (0.0%) | 4 (10%) | 0.06 |
| Negative | 10 (25%) | 8 (20%) | 18 (45%) | 36 (90%) | |
| Total | 14 (35%) | 8 (20%) | 18 (45%) | 40 (100%) | |



Microphotograph (1): serous cystadenoma showed positive expression of p63 (40X).



Microphotograph (2):serous cystadenocarcinoma showed negative expression of p63 (40X).

Discussion:

This study confirms and expands on earlier results showing that p63 expression follows a restricted pattern in normal tissues. The present study includes 80 samples of ovarian tumors stained by immunohistochemistry for p63, 40 of them were benign, and the remaining 40 samples were malignant. Concerning the age group of the study population, the study showed that the majority of patients were older than 50 years, indicating that women older than 50 are more affected by ovarian cancer. This result is compatible with DO Abuidris *et al.*, who reported that the incidence rate of ovarian cancer increased greatly in women aged 55 years or older. I also agree with Jermaine *et al.*, who reported that the risk of developing ovarian cancer increases with age [26]. While disagreeing with Dafalla, *et al.*, who reported that ovarian malignancies tend to occur at younger ages in Sudan [24]. The histopathological diagnosis of the study population showed that epithelial ovarian cancer was the more frequent type of ovarian cancer. This result is compatible with Poli Neto *et al.*, who reported that epithelial tumors represent more than 85% of all ovarian malignancies [3]. In this study, we observed strong p63 nuclear staining in 4 of malignant conditions compared to 36 of 40 benign conditions ($P = 0.000$), which suggests that p63 expression is more frequently expressed in benign conditions.

Comment [ak6]: Maybe the author can elaborate more the meaning of this finding for diagnostic of Ovarian tumor. Is the stain benefit the pathologist for benign or malignancy state differentiation? Is the stain benefit the pathologist for normal or pathological state differentiation?

This result agrees with that of Poli Neto, *et al.*, who reported that 85.7% of positivity was in benign tumors, 50% in borderline tumors, and 8.7% in invasive ovarian cancer ($P .0001$) [2]. A similar pattern of immunostaining has been reported by several groups [2, 27], whose results showed that most of the ovarian carcinomas were p63 negative. The present study revealed that there was no significant association between p63 expression and the type of malignant tumor. This finding was in agreement with Reis-Filho, *et al.*, who reported that no association was found between the histological type and the expression of p63 in ovarian neoplasm [27].

Conclusion:

The age of ovarian tumor patients in our samples is commonly greater than 50 years. The most histologically significant type of ovarian cancer is epithelial ovarian cancer. p63 had low expression in ovarian cancer, and there was no significant association between p63 expression and subtypes of ovarian tumors as well as tumor grade.

References:

1. Fisher ML, Balinth S, Mills AA. p63-related signaling at a glance. *J Cell Sci.* 2020;133(17):jcs228015. [PMC free article] [PubMed]
2. Di Como CJ, Urist MJ, Babayan I, Drobnjak M, Hedvat CV, Teruya-Feldstein J, et al. p63 expression profiles in human normal and tumor tissues. *Clin Cancer Res.* 2002;8(2):494–501. [PubMed] [Google Scholar]
3. Poli Neto OB, Candido dos Reis FJ, Zambelli Ramalho LN, Nogueira AA, de Andrade JM. p63 expression in epithelial ovarian tumors. *Int J Gynecol Cancer.* 2006;16(1):152–155. doi: 10.1111/j.1525-1438.2006.00290.x. [PubMed] [CrossRef] [Google Scholar]
4. Murray-Zmijewski F, Lane DP, Bourdon JC. p53/p63/p73 isoforms: an orchestra of isoforms to harmonise cell differentiation and response to stress. *Cell Death Differ.* 2006;13(6):962–972. doi: 10.1038/sj.cdd.4401914. [PubMed] [CrossRef] [Google Scholar]
5. Reis-Filho JS, Simpson PT, Fulford LG, Martins A, Schmitt FC. P63-driven nuclear accumulation of beta-catenin is not a frequent event in human neoplasms. *Pathol Res Pract.* 2003;199(12):785–793. doi: 10.1078/0344-0338-00497.

- [PubMed] [CrossRef] [Google Scholar]
6. Au NH, Gown AM, Cheang M, Huntsman D, Yorida E, Elliott WM, et al. P63 expression in lung carcinoma: a tissue microarray study of 408 cases. *Appl Immunohistochem Mol Morphol*. 2004;12(3):240–247. doi: 10.1097/00129039-200409000-00010. [PubMed] [CrossRef] [Google Scholar]
 7. Bishop JA, Teruya-Feldstein J, Westra WH, Pelosi G, Travis WD, Rekhtman N. p40 (DeltaNp63) is superior to p63 for the diagnosis of pulmonary squamous cell carcinoma. *Mod Pathol*. 2012;25(3):405–415. doi: 10.1038/modpathol.2011.173. [PubMed] [CrossRef] [Google Scholar]
 8. Kanitakis J, Chouvet B. Expression of p63 in cutaneous metastases. *Am J Clin Pathol*. 2007;128(5):753–758. doi: 10.1309/BD3K8U7KD969Y07U. [PubMed] [CrossRef] [Google Scholar]
 9. Kim YW, Do IG, Park YK. Expression of the GLUT1 glucose transporter, p63 and p53 in thyroid carcinomas. *Pathol Res Pract*. 2006;202(11):759–765. doi: 10.1016/j.prp.2006.07.006. [PubMed] [CrossRef] [Google Scholar]
 10. Lin X, Zhu B, Villa C, Zhong M, Kundu S, Rohan SM, et al. The utility of p63, p40, and GATA-binding protein 3 immunohistochemistry in diagnosing micropapillary urothelial carcinoma. *Hum Pathol*. 2014;45(9):1824–1829. doi: 10.1016/j.humpath.2014.04.015. [PubMed] [CrossRef] [Google Scholar]
 11. Guo HQ, Huang GL, Liu OF, Liu YY, Yao ZH, Yao SN, et al. p63 expression is a prognostic factor in colorectal cancer. *Int J Biol Markers*. 2012;27(3):e212–e218. doi: 10.5301/JBM.2012.9581. [PubMed] [CrossRef] [Google Scholar]
 12. Conde E, Angulo B, Redondo P, Toldos O, Garcia-Garcia E, Suarez-Gauthier A, et al. The use of P63 immunohistochemistry for the identification of squamous cell carcinoma of the lung. *PLoS One*. 2010;5(8):e12209. doi: 10.1371/journal.pone.0012209. [PMC free article] [PubMed] [CrossRef] [Google Scholar]
 13. Hall BJ, Pincus LB, Yu SS, Oh DH, Wilson AR, McCalmont TH. Immunohistochemical prognostication of Merkel cell carcinoma: p63 expression but not polyomavirus status correlates with outcome. *J CutanPathol*. 2012;39(10):911–917. doi: 10.1111/j.1600-0560.2012.01964.x. [PubMed]

[CrossRef] [Google Scholar]

14. Vrabie CD, Terzea D, Petrescu A, Waller M. The histopathology analysis of the diffuse sclerosing variant of the papillary carcinoma of the thyroid: a distinctive and rare form. *Romanian J MorpholEmbryol.* 2009;50(4):743–748. [PubMed] [Google Scholar]
15. Koyuncuer A. Immunohistochemical expression of p63, p53 in urinary bladder carcinoma. *Indian J PatholMicrobiol.* 2013;56(1):10–15. doi: 10.4103/0377-4929.116141. [PubMed] [CrossRef] [Google Scholar]
16. Carneiro FP, Ramalho LN, Britto-Garcia S, Ribeiro-Silva A, Zucoloto S. Immunohistochemical expression of p16, p53, and p63 in colorectal adenomas and adenocarcinomas. *Dis Colon Rectum.* 2006;49(5):588–594. doi: 10.1007/s10350-006-0515-4. [PubMed] [CrossRef] [Google Scholar]
17. Zhang N, Huo Q, Wang X, Chen X, Long L, Guan X, et al. A genetic variant in p63 (rs17506395) is associated with breast cancer susceptibility and prognosis. *Gene.* 2014;535(2):170–176. doi: 10.1016/j.gene.2013.11.038. [PubMed] [CrossRef] [Google Scholar]
18. Reis-Filho JS, Simpson PT, Martins A, Preto A, Gartner F, Schmitt FC. Distribution of p63, cytokeratins 5/6 and cytokeratin 14 in 51 normal and 400 neoplastic human tissue samples using TARP-4 multi-tumor tissue microarray. *Virchows Arch.* 2003;443(2):122–132. doi: 10.1007/s00428-003-0859-2. [PubMed] [CrossRef] [Google Scholar]
19. Tsoref, D., T. Panzarella, et al.. "Aspirin in prevention of ovarian cancer: are we at the tipping point?" *J Natl Cancer Inst.* 2014; 106(2): djt453.
20. Stachs, A., S. Hartmann, et al.. "Preservation of Fertility or Ovarian Function in Patients with Breast Cancer or Gynecologic and Internal Malignancies." *GeburtshilfeFrauenheilkd.* 2017;77(8): 861-869.
21. Boorjian, S. "Commentary on "Reproductive factors and kidney cancer risk in 2 US cohort studies, 1993-2010." Karami S, Daugherty SE, Schonfeld SJ, Park Y, Hollenbeck AR, Grubb RL 3rd, Hofmann JN, Chow WH, Purdue MP, Occupational and Environmental Epidemiology Branch, Division of Cancer Epidemiology and Genetics, Department of Health and Human Services, National

- Cancer Institute, National Institutes of Health, Bethesda, MD. *Am J Epidemiol* 2013; 177(12):1368-77. [Epub 2013 Apr 26]. Doi: 10.1093/aje/kws406." *Urol Oncol* 32(6): 932-933.
22. Jemal A, Siegel R, Ward E, Murray T, Xu J, Smigal C, et al . Cancer statistics, 2006. *CA Cancer J Clin* 2006;56:106-30.
 23. Doubeni, C; Doubeni, A; and Myers, A. Diagnosis and Mangement of Ovarian Cancer. *American Family Physician*. 2016;1:93(11):937-944.
 24. Dafalla, OA. Hsin-Yi, W., Ahmed, ME., Elgaylani, AE. Mohamed, E., SI. And Mohammed, IM . Incidence and survival rates of ovarian cancer in low-income women in Sudan. *Molecular and Clinical Oncology*. 2016 ;5: 823-828).
 25. DO Abuidris D, HY Weng, AM Elhaj, EA Eltayeb, M Elsanousi, RS Ibnoof, and SI Mohammed. Incidance and survival rates of ovarian cancer in low-income women in Sudan. *Molecular and Clinical Oncology*. 2016;5 (6):823-828.
 26. Jermaine, IGC. Kathryn, M. And Felicity, M. New perspectives on targeted therapy in ovarian cancer. *International Journal of Women's Health*. 2015;7:189-203.
 27. Reis-Filho JS, Simpson PT, Martins A, Preto A, Gartner F, Schmitt FC. Distribution of p63, cytokeratins 5/6 and cytokeratin 14 in 51 normal and 400 neoplastic human tissue samples using TARP-4 multi-tumor tissue microarray. *Virchows Arch*. 2003; 443:122–32.
 28. J. A. RAMOS-VARA. Technical Aspects of Immunohistochemistry *Vet Pathol* .2005;42:405–426