

Case study

Cross testicular ectopia – Two case report and review of literature

Abstract

Cross testicular ectopia is an exceptionally rare congenital urogenital anomaly where both gonads migrate towards the same hemiscrotum. This condition is typically accompanied by other abnormalities like persistent Mullerian duct syndrome, inguinal hernia, true hermaphroditism, hypospadias, and scrotal anomalies. While most reported cases involve children, there have been a few instances in adults. The incidence of cross testicular ectopia is extremely low, occurring in 1 in 4 million male children. In cross testicular ectopia, both testes migrate to the same hemiscrotum and descend through a single inguinal canal, often associated with inguinal hernia and an empty contralateral hemiscrotum. One or both testes may be ectopic in the abdomen, inguinal region, or descend to the hemiscrotum with the contralateral hemiscrotum remaining empty.

We present two cases of cross testicular ectopia in a 9-year-old and a 5-year-old boy, both presenting with right inguinal hernia and a non-palpable left testis. Ultrasound examination revealed both testes located in the right scrotum, with the hernia sac in the right inguinal area. A trans-septal orchidopexy was performed along with hernioplasty to address these cases.

Key words

Cross testicular ectopia, Cryptorchidism, Ectopia testis, Persistent Mullerian duct syndrome, Transvers testicular ectopia.

Introduction

Crossed testicular ectopia, also known as transverse testicular ectopia, testicular pseudo-duplication, unilateral double testis, or transverse aberrant testicular mal-descent, is an uncommon anatomical anomaly where both testes migrate towards the same hemiscrotum, leaving the contralateral hemiscrotum empty. Invariably, inguinal hernia is present on the affected side. [1,2,3]

Typically, most cases are diagnosed before the age of 4, and the clinical presentation includes signs of ipsilateral inguinal hernia with the absence of both testes. However, the final diagnosis is often made during surgery as an incidental discovery. Manifestations of crossed testicular ectopia can vary, ranging from one or both testicles being misplaced in the abdomen, at the deep internal ring, or within the inguinal canal, to their descent into the hemiscrotum with the contralateral hemiscrotum remaining empty. [4,5,]

Case Report

Case I – On May 15, 2017, a 5-year-old boy was admitted to our centre with complaints of right-sided inguinal scrotal swelling and an empty left scrotum. Physical examination by the doctor revealed a congenital hernia on the right side and an empty left scrotum. To confirm the diagnosis, an ultrasound of the inguinoscrotal region was performed, indicating two testes on the right side

with a congenital right hernia and an undescended right testis leading to an empty left scrotum. The diagnosis was confirmed as an extremely rare case of cross testicular ectopia on the right side. Additionally, two separated spermatic cords were observed in the right inguinal canal. All laboratory investigations yielded normal results, and the patient was scheduled for surgical reconstruction.

A right inguinal incision was made, and upon opening the layers and the hernial sac, two testicles were unexpectedly found within. The two spermatic cords were completely separated, and utmost care was taken to prevent any damage to them. The two testicles were delivered, and a trans-septal orchiopexy was necessary. Initially, a herniotomy was performed with a mid-raphhe incision. Through a hole in the middle of the raphe, one testicle was transferred to the left hemiscrotum and secured with absorbable mono-vicryl. Subsequently, a right-side testicle orchiopexy was performed in the right hemiscrotum. Special attention was paid to preserving the blood supply to the vas deferens and testis. The fascia, subcutaneous tissue, and skin were closed, and a sterile bandage was applied.

The patient's post-operative recovery was favourable, leading to discharge on the 5th post-operative day. Follow-up appointments occurred at one-year intervals to monitor for potential complications.

(Fig 1-6)

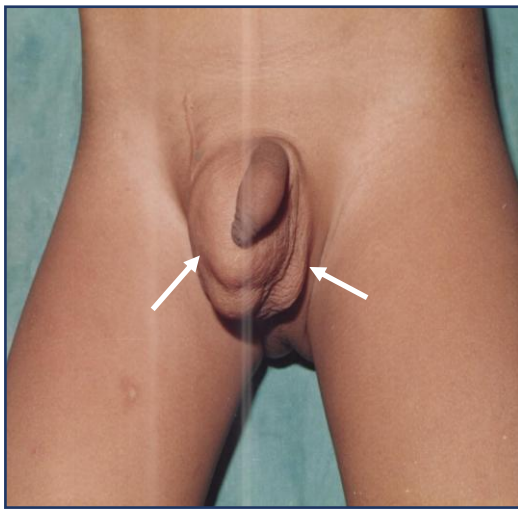


Fig-1 Photographs showing right inguinal hernia with empty left hemiscrotum

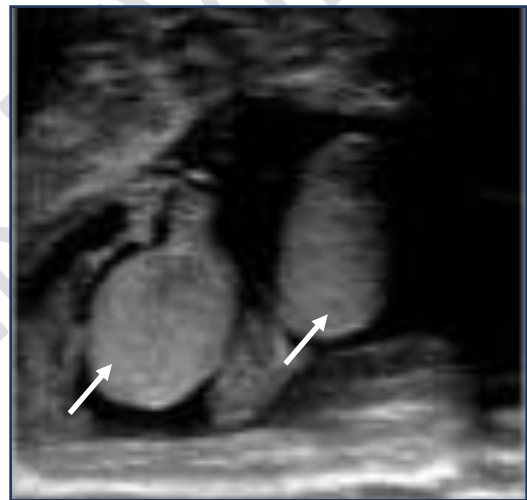


Fig-2 Ultrasonography showing two testes in right hemiscrotum

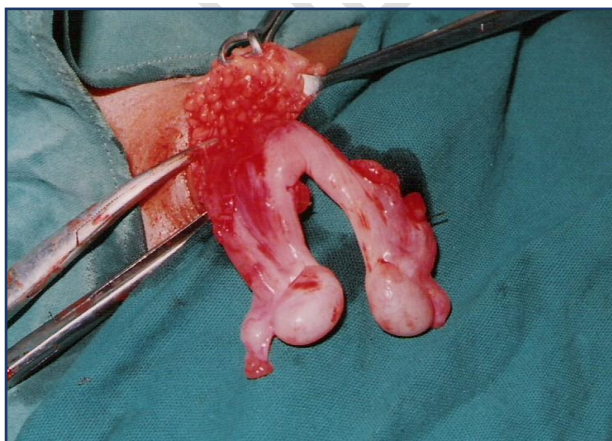

Fig-3 Intraoperative Photographs showing two testes on right side

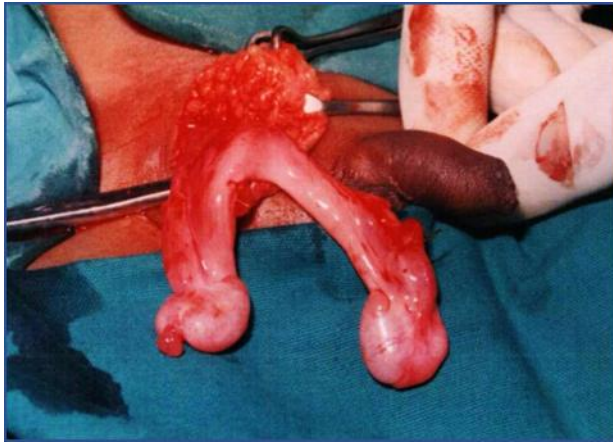

Fig-4 Intraoperative Photographs showing two testes with two separate vas deference

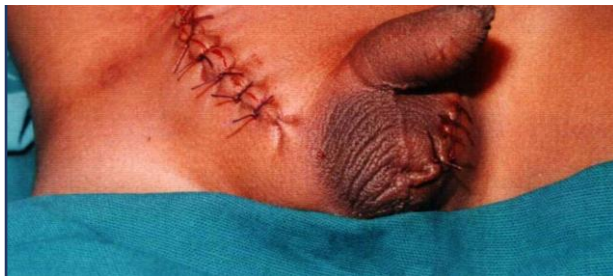

Fig-5 Intraoperative Photographs showing two testes with two separate vas deference

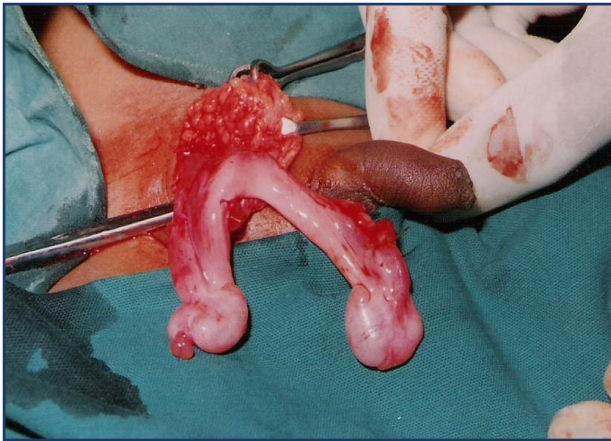

Fig-6 Photographs showing trans-septal orchiopexy with right herniotomy

Case II

On October 20, 2020, a 9-year-old boy was brought by his parents for a check-up due to right-sided inguinoscrotal swelling and an empty left scrotum. Clinical examination revealed a right inguinal hernia with an empty left scrotum. Palpation of the right scrotum confirmed the presence of two testicles, while the left scrotum remained empty. Ultrasound examination further confirmed the diagnosis of cross testicular ectopia with inguinal hernia on the same side. All laboratory investigations returned normal results.

A decision for exploration was made, and a right inguinal incision was performed. During the operation, two testes were discovered in the right scrotum with a single inguinal hernia sac. The initial step involved herniotomy, followed by placing and securing the right testicle in the right hemiscrotum using slowly absorbable mono vicryl sutures. The left testis was positioned in the left hemiscrotum through a trans-septal window and secured with absorbable mono-vicryl suture material. The patient experienced an uneventful post-operative recovery with no complications. Follow-up appointments were conducted for one year, revealing no complications during the post-operative period.**(Fig 7- 12)**

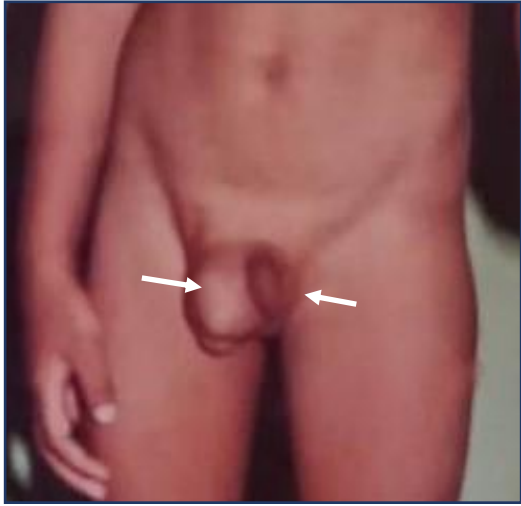

Fig-7 Photographs showing right inguinal hernia with empty left hemiscrotum

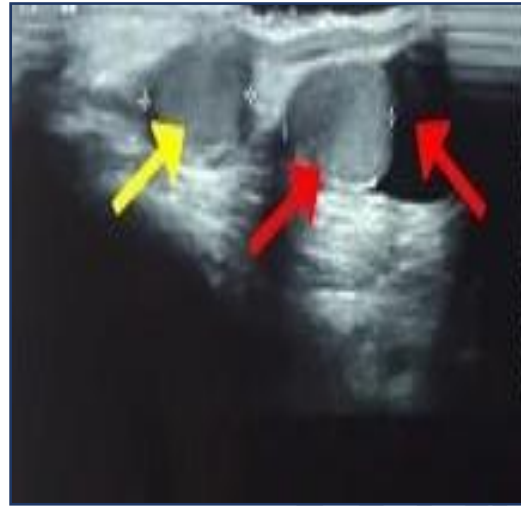

Fig-8 Ultrasonography showing two testes in right hemiscrotum

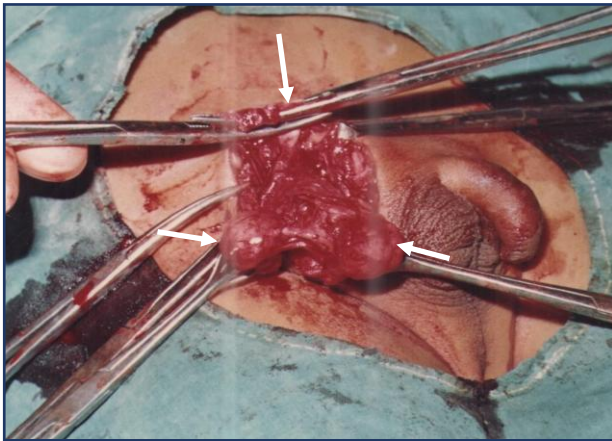


Fig-9 Intraoperative Photographs showing right herniotomy with two testes in right hemiscrotum

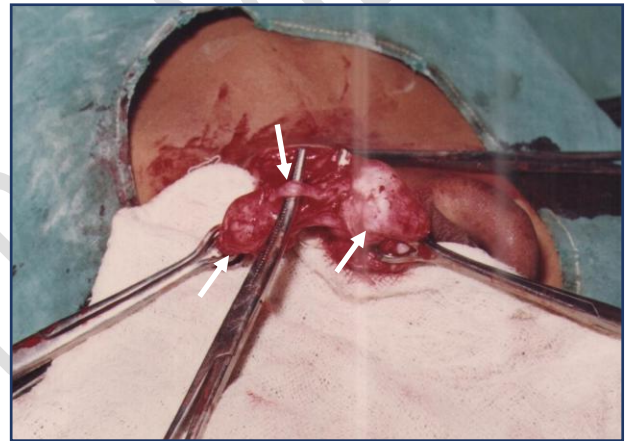


Fig-10 Intraoperative Photographs showing two testes with separate vas deference

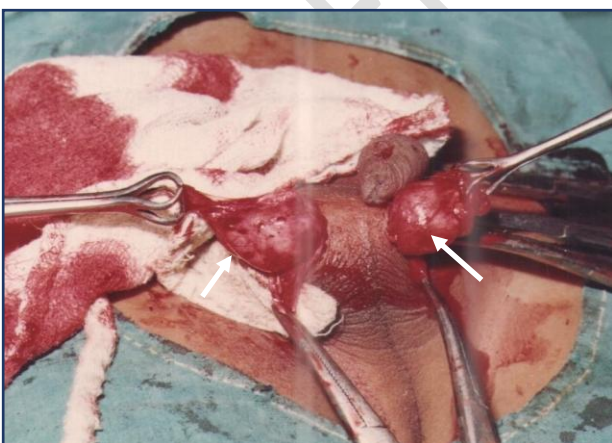


Fig-11 Intraoperative Photographs showing trans-septal orchiopexy

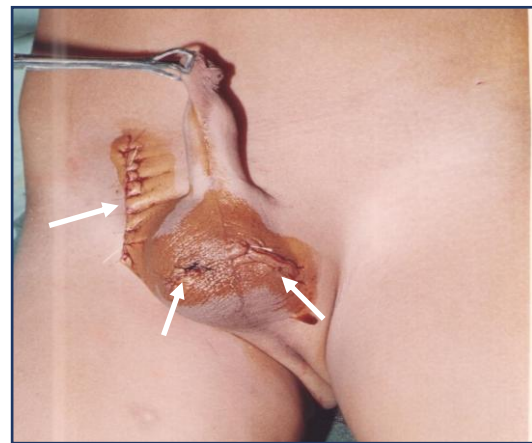


Fig-12 Photographs showing trans-septal orchiopexy with right herniotomy

Discussion

Crossed testicular ectopia is a rare congenital urogenital anomaly where both testes descend through a single inguinal canal and are located in the same hemiscrotum. The first documented case was described by Lenhossek in 1880, and since then, approximately 150 cases have been reported in the English literature. The incidence of crossed testicular ectopia in children is 1 in 4 million. Various theories attempt to explain its etiology; Beer et al. suggest that both testes develop from the same genital ridge, while Kimura et al. propose that the vas deferens may originate unilaterally or bilaterally, leading to crossed testicles if both originate from one side. Gupta et al. highlight that the wolffian duct's early connection causes the movement of one testicle to influence the opposite one. The presence of inguinal hernia is a consistent feature as the two testicles descend through the same inguinal canal. [1,2,4,5]

Gauderer et al. classified crossed testicular ectopia into three types:

Type I – Accompanied only by a congenital hernia (50%).

Type II – Accompanied by persistent or rudimentary Mullerian duct structure (30%)

Type III – Associated with disorders other than persistent Mullerian remnants, hypospadias, hermaphroditism, and scrotal anomalies. [2,3,4]

Persistent Mullerian duct syndrome, a rare condition characterized by the presence of uterus or fallopian tubes in phenotypically normal 46 XY males, can be associated with crossed testicular ectopia. The syndrome results from insufficient anti-Mullerian hormone release from Sertoli cells in the testes. Diagnosis involves ultrasound, MRI, diagnostic laparoscopy, testicular biopsy, and chromosomal study. [5,6,7]

Patients with crossed testicular ectopia face an increased risk of malignant transformation (18%), with reported cases of embryonal carcinoma, seminoma, yolk-sac tumor, and teratoma.

Management options include open inguinal exploration with trans-septal orchidopexy, laparoscopic-assisted orchidopexy, and diagnostic laparoscopy with trans-septal orchidopexy. Diagnostic laparoscopy, providing both diagnostic and therapeutic benefits, has become an integral part of the management approach, with reported cases of successful diagnosis and treatment through laparoscopy. [2,3,4]

In our cases, we observed two instances of Type I, associated with congenital hernias. Diagnosis should be considered in cases of unilateral inguinal hernia with an empty contralateral hemiscrotum. Preoperative confirmation can be achieved through ultrasound examination, CT, MRI, and laparoscopy.

Conclusion

Crossed testicular ectopia is a rare condition and the surgeon should suspect it in any patient presenting with an inguinal hernia on one side and empty contralateral hemiscrotum (cryptorchidism) it is recommended to do ultrasonography MRI and diagnostic laparoscopy and proceed with orchidopexy. Diagnostic laparoscopy is both helpful in diagnosis and managements. Trans-septal orchidopexy gives good tension free fixation of testes in the scrotum.

References

1. Gholizadeh, M., Fakhreyasseri, A.M. Unilateral transverse testicular ectopia with recurrence of inguinal hernia: a case report. *J Med Case Reports* 17, 69 (2023). <https://doi.org/10.1186/s13256-023-03782-8>

2. Pitchumani, S., Padmanaban, E., Achantani, Y.K. et al. Transverse testicular ectopia with inguinal hernia in an adult—a case report. *Egypt J RadiolNucl Med* 52, 154 (2021). <https://doi.org/10.1186/s43055-021-00531-z>
3. Nunna B, Parihar P, Gowda H, et al. (May 16, 2023) Ectopic Crossed Testis: A Rare Anomaly of Testicular Migration. *Cureus* 15(5): e39086. doi:10.7759/cureus.39086
4. Shakir Saleem Jabali, Ayad Ahmad Mohammed, Crossed testicular ectopia: Case report with review of literature, *International Journal of Surgery Case Reports*, <https://doi.org/10.1016/j.ijscr.2020.09.071>.
5. Shakir Saleem Jabali, Ayad Ahmad Mohammed, Crossed testicular ectopia: Case report with review of literature, *International Journal of Surgery Case Reports*, <https://doi.org/10.1016/j.ijscr.2020.09.071>.
6. Ben Dhaou M, Louati H, Kotti A, Zitouni H, Jalouli M, Mhiri R. Diagnosis and Treatment of Crossed Testicular Ectopia. *Iran J Public Health*. 2016 Sep;45(9):1232-1233. PMID: 27957472; PMCID: PMC5149481.
7. Muhammad Akram Malik, Zahid Iqbal, Khalid Mahmood Chaudri, Naveed Ashraf Malik, and Azhar Javed Ahmed, Crossed Testicular Ectopia, *UROLOGY* 71: 984.e5–984.e6, 2008. © 2008 Elsevier Inc
8. Prakash A, Jain S, Kela M, Yadav C, Lohiya R, Maheshwari T. Transverse testicular ectopia: What surgeons must know; Insights in embryology and management. *Arch Int Surg* 2016;6:191-4
9. Balaswad, Mohammed Rabea; Ghorab, Wael; and Mebed, Shrief (2023) "Crossed Testicular Ectopia (CTE), A rare anomaly: Case Report and Review of the Literature," *Journal of Medicine in Scientific Research*: Vol. 6: Iss. 4, Article 10. DOI: <https://doi.org/10.59299/2537-0928.1052>
10. Khatwa UA and Menon PS: Management of undescended testis. *Indian J Pediatr*. 6 49–454. 2000. PubMed/NCBI View Article : Google Scholar