

A CURRENT UPDATE ON NEOSPOROSIS CANINUM

Abstract

Neospora caninum is an apicomplexan protozoan parasite, which was first identified as a cause of canine paralysis. This parasite is now recognized as an important cause of reproductive problems and abortion in cows. Prior to its initial recognition in Norwegian dogs in 1984 and consequential classification as a distinct species in 1988, many *N. caninum* infections were misdiagnosed as toxoplasmosis. Neospora has a complex life cycle and transmission routes. Carnivores probably become infected by ingesting tissues, cysts containing bradyzoites, and herbivores probably become infected by the ingestion of food or drinking water contaminated by *N. caninum* sporulated oocysts ~~in~~ from the feces of carnivores. During pregnancy it becomes activated again, breaks out of the tissue cysts and migrates to the placenta. Infection of the placenta may lead to abortion, which would provide a source of contaminated meat for definitive hosts. In addition, the parasite may be transmitted to the foetus, which can lead to the birth of congenitally and persistently infected calves. Most reports of neosporosis outbreaks have occurred in cows that are intensively managed; thus, the incidence increases as larger cattle farms with intensive feeding practices become more common. Immunofluorescent antibody test (IFAT) and indirect enzyme-linked immunosorbent assay (ELISA) and histopathology of fetus are used for diagnosis. At present, there is no effective treatment for bovine neosporosis. Control of abortion in infected cattle depends on saving food and water sources and the grazing environment from feces of carnivores ~~any animal~~, properly discarding aborted foetus and control of dog.

Key words: Abortion, Dog, *Neospora caninum*, Neosporosis,

Comment [S1]: Title should be either
A CURRENT UPDATE ON NEOSPOROSIS
CANINUM

Or

A CURRENT UPDATE ON NEOSPOROSIS

Formatted: Font: Italic

Formatted: Font: Italic

1. INTRODUCTION

Neospora caninum is a microscopic apicomplexan protozoan parasite with worldwide distribution. Many domestic (eg, dogs, cattle, sheep, goats, water buffalo, horses, chickens) and wild and captive animals (eg, deer, rhinoceros, rodents, rabbits, coyotes, wolves, foxes) can be infected. However, neosporosis caused by *N. caninum* infection is one of the most common causes of bovine abortion, especially in intensively farmed cows. Neosporosis abortion also occurs in sheep, goats, water buffalo, and camelids, although they may be less susceptible than cattle [1].

Formatted: Font: (Default) Times New Roman, 12 pt, Italic, Font color: Auto

A second *Neospora* species, *N. hughesi*, is a cause of myelitis in horses and shares clinical features with equine protozoal myeloencephalitis, which in North and South America is usually caused by *Sarcocystis neurona*. The life cycle of *N. hughesi* is unknown. Discussion in this chapter deals only with *N. caninum* infection[2].

Formatted: Font: (Default) Times New Roman, 12 pt, Not Italic, Font color: Auto

Neospora caninum is a protozoan parasite, which was first identified first recognized in dogs in Norway as a cause of canine paralysis. It was first recognized in dogs in Norway [2]. This parasite is now recognized as an important cause of reproductive problems and abortion in cows. A later association with bovine abortions made the parasite a concern for the farming community worldwide. During the one and a half decades since the parasite was recognized, large steps have been taken towards understanding its biology and pathology [3]. Excretion of *N. caninum* oocysts could act as a risk factor when these are come out through feces, and finally mixed with environment of definitive hosts; these could cause stillbirths and miscarriages to cattle and other intermediate hosts [4].

Formatted: Font: (Default) Times New Roman, 12 pt, Italic, Font color: Auto

Most cases of clinical neosporosis reported were in young (<4 months old) dogs, presumably infected congenitally. However, dogs of all ages can get the infection and have died of neosporosis. The most consistent sign of canine neosporosis is paresis of limbs, especially hind limbs [14]. Neosporosis in cattle has been associated with endemic, epidemic and sporadic abortions causing huge economic loss worldwide [5]; [6]

In Africa, reports on neosporosis are limited; however, the available information is in line with global understanding of the protozoan that underscores the relevance of the *N. caninum* to the dairy sector. Information on neosporosis in Ethiopia was lacking until a recent case-control study of dairy

farms of central and southern Ethiopia demonstrated that bovine neosporosis was an important cause of reproductive disorders in dairy and breeding cattle [1]. The objective of this review is to gather recent information on nNeosporosis.

2. NEOSPOROSIS

2.1 Etiology

Neosporosis caused by *Neospora caninum* in cattle, sheep and goats. ~~*Neosporacanium*~~ ~~The protozoan parasite~~ is a heteroxenous cyst-forming apicomplexan and is a common cause of foetopathy and abortion in cattle worldwide [7]; [8]. ~~*Neosporacanium*~~ ~~The parasite~~ shares many morphologic and biologic features with its close relative *Toxoplasma gondii* [15]. Prior to its initial recognition in Norwegian dogs in 1984 and consequential classification as a distinct species in 1988, many *N. caninum* infections were misdiagnosed as toxoplasmosis. Key differences were subsequently identified that distinguish the two parasites with regard to their natural host range, antigenicity, virulence factors, and pathogenesis. Differences between *N. caninum* and *T. gondii* have also been described using comparative genomics and transcriptomics analyses [15].

Formatted: Font: Italic

Formatted: Font: Not Italic

When investigating *N. caninum* in canine feces, it is necessary to avoid confusion with the closely related parasite *Hammondia heydorni*, which has oocysts that appear similar to those of *N. caninum* [16]. Furthermore, the agents' tachyzoites and bradyzoites appear similar under a light microscope, but they can be distinguished under an electron microscope by the number, appearance, and location of their rhoptries [17]. There are few confirmed cases of neosporosis in wild animals; however, antibodies against *N. caninum* have been found in several wild mammalian species, suggesting that the parasite may be widely spread among wildlife

2.2 Life cycle and transmission

Neospora has a complex life cycle and transmission routes. As a definitive host, the dog sheds unsporulated oocysts in the environment for 5 to 17 d after the ingestion of tissue cysts [18]. These oocysts have a tough outer shell, are very stable in the environment and stay infective for 6 months or longer in temperate conditions. Intermediate hosts (cattle) ingest oocysts that are found in contaminated food and water. Sporozoites are released in the intestinal tract where they penetrate

cells and become tachyzoites (a rapidly dividing asexual phase). Tachyzoites divide and quickly spread to other host cells, which they invade and often destroy. Tachyzoites have been found in neural cells, macrophages, fibroblasts, vascular endothelial cells, hepatocytes, and muscular cells including those of myocardium and the placenta in pregnant cows. Once the immune system starts to recognize the tachyzoite, then the parasite changes tactics and tries to hide from the immune system by staying dormant inside tissue cysts, which may contain several hundred parasites. This slow multiplying stage of the parasite is called “bradyzoite”. Carnivores probably become infected by ingesting tissues cysts containing bradyzoites, and herbivores probably become infected by the ingestion of food or drinking water contaminated by *N. caninum* sporulated oocysts [15].

However, the parasite has developed a backup strategy; during pregnancy it becomes activated again, breaks out of the tissue cysts and migrates to the placenta. Infection of the placenta may lead to abortion, which would provide a source of contaminated meat for definitive hosts. In addition, the parasite may transmit to the foetus, which can lead to the birth of congenitally and persistently infected calves. As adults these animals may have abortions due to the parasite or they may transmit it to their offspring resulting in birth of infected although clinically normal calves. Congenital transmission of the parasite from dam to offspring allows *Neospora* to survive in herds for many generations and infection may stay undetected because the only clinical sign would be sporadic cases of abortions. However, contamination of animal feed and drinking water with oocysts produced by the definitive host may lead to abortion storms in naïve cattle herds [19].

Formatted: Font: Italic

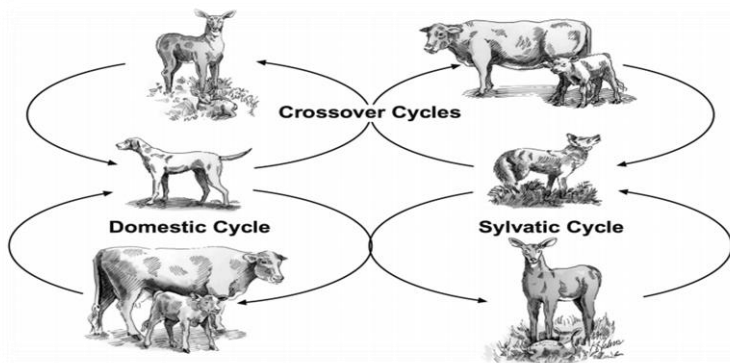


Figure 1: Transmission cycles of the protozoan *Neospora caninum* between wild and domestic animals.

The domestic cycle, transmission from cattle to coyotes, and transmission from deer to dogs have each been demonstrated. Transmission between coyotes and deer, from coyotes to cattle, and from dogs to deer are probable but as yet untested.

2.3 Epidemiology

Neosporosis in cattle herds manifests in both endemic and epidemic abortion patterns, but it is also possible for a herd to have a high infection prevalence without a noticeable abortion problem [2]; [20]. The majority of *N. caninum*- positive cattle prenatally infected via their dams. Transplacental transmission is considered the major route of transmission of *N. caninum* in cattle. In nonfatal infection in the fetus, the fetus is born with neurologic disorder [11]. *N. caninum* has a worldwide distribution, the prevalence of infection in cattle and sheep approaches 100% with a lower [12];[7].

2.4 Status of neosporosis in Ethiopia

Most reports of neosporosis outbreaks have occurred in cows that are intensively managed; thus, the incidence increases as larger farms with intensive feeding practices become more common. In Ethiopia many researches done on neosporosis of dairy farm on epidemiology of the diseases reported the overall prevalence of neosporosis to be 13.3% from 273 farms selected in Ethiopia. KassahunWondim's PhD research shows that the protozoan parasite, *N. caninum*, is a more frequent cause of miscarriage and stillbirth in intensive and semi-intensive dairy production in Ethiopia than the BVD virus and the *Brucella* bacterium[15]

Formatted: Font: Italic

Formatted: Font: Italic

2.4 Pathogenesis

Definitive host: Dogs are the final host and sexual phase occur in them but, they are also intermediate host in prenatal infections [12];[21]

Intermediate host: Cattle are the major intermediate hosts and asexual reproduction phase occur in them [21]. Infection can be transmitted from dam to calf *in utero* and lactogenically. Infection of cattle can also occur from the ingestion of food or water contaminated with dog feces

Formatted: Font: Italic

containing *Neospora caninum* oocysts [12]; [7]. *Neospora caninum* is a major cause of abortion in cattle, however, sporadic abortions can occur in beef cows that have been infected congenitally [14]; [12]; [7]; [8]. .

Asexual phase has 2 stages:

1. **Tachyzoites:** Tachyzoites penetrate host cell like central nervous system, muscles, macrophages and other cells, where they divide rapidly. Tachyzoites can also be transmitted either with contaminated food and water or transplacentally to the fetus in pregnant animals. Tissue cyst containing bradyzoites that these are found only in the nervous system. After the asexual phase, sexual phase occur in definite host. It results in production of oocysts, which is shed in the dog feces [12].
2. **Tissue cysts:** Infection in sheep and goats is infrequently [7].

2.5 Clinical findings

In cattle, *Neosporosis* causes stillbirth, fetal resorption, mummification, abortion and decreases in their milk production [20]; [7]. Abortions in cows are seen between 5-7 month gestations [20]. Fetus may born alive but congenitally diseased [20]; [7]. Neurological symptoms are different because of the widespread distribution of the parasite in the central nervous system. Calves are born with neurological symptoms, which these symptoms initially are mild but after birth become progress [22]. In calves with neurologic dysfunction clinical signs are included of unable to stand, unable to suckle, domed skull and torticollis [11].

2.6 Diagnosis

Because neosporosis is only one of many causes of abortion, diagnostic efforts should focus on an array of possible causes. Aborted fetuses should be submitted to a veterinary diagnostic laboratory, together with placenta and a serum sample from the aborting dam. Examination of multiple fetuses increases the odds of accurate diagnosis [2].

Immunofluorescent antibody test (IFAT) and indirect enzyme-linked immunosorbent assay (ELISA) are used for diagnosis.

Histopathology of fetus: In histopathological examination of brain characteristic nonsuppurative encephalitis is suggestive of *Neospora* infection and also the lesions in the heart are characteristic for *Neospora* infection [20]; [12]; [21].

Formatted: Font: Italic

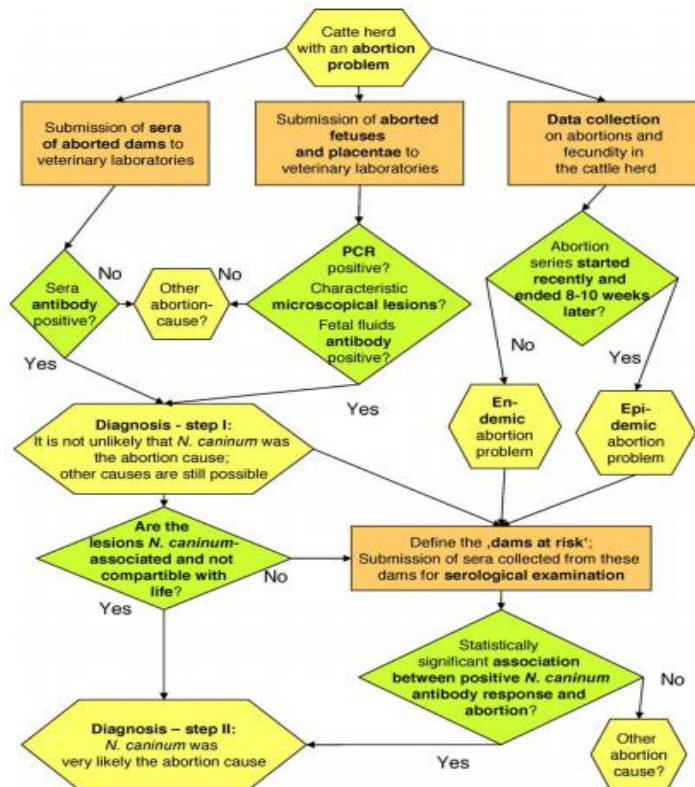


Figure 2: Diagnosis of *N. caninum* -associated abortion.

The serologic examination of maternal sera and fetal body fluids as well as the histological and the PCR analysis may provide first but not yet definitive evidence for a *N. caninum* -associated abortion (diagnosis—step I). If the lesions in fetal tissues are judged by a pathologist to be not compatible with life and if these lesions are immunohistochemically linked to *N. caninum* it may be justified to conclude that the abortion is caused by *N. caninum* (diagnosis—step II). The involvement of *N. caninum* in bovine abortion may also be confirmed by the observation of a statistically significant

Formatted: Font: Italic

Formatted: Font: Italic

Formatted: Font: Italic

Formatted: Font: Italic

association between seropositivity and abortion within the group of dams with an abortion risk ('dams at risk'). Definitions for 'dams at risk' are provided in the text [15].

2.7 Treatment and control

At present, there is no effective treatment and vaccine for bovine neosporosis [2]. Control of abortion in infected cattle depends on saving food and water sources and the grazing environment from feces of carnivore animal. Aborted fetuses and placentas should be removed or incinerated. The feces of dogs should be prevented from contaminating animal foodstuffs. Seropositive animals should be culling from a herd [12]; [7].

3. CONCLUSION AND RECOMMENDATION

Neosporosis is a common disease of cattle that is caused by the protozoan parasite, *Neospora caninum*. Infection of pregnant cows causes abortion. Dogs were discovered to be carriers of Neospora, capable of shedding environmentally resistant forms of the parasite, called oocysts, in their feces. Other animals become infected when they consume the Neospora oocysts. In turn, dogs obtain the parasite when they consume the carcass of an infected animal. The dog is the definitive host of Neospora, and cattle are intermediate hosts. Depending on the above conclusion the following recommendations are forwarded.

- Management of the interaction between dogs and cattle and breaking the cycle of disease transmission.
- Prevent fecal contamination of feed.
- Feedstuffs should be enclosed within dog-proof fences.
- Dogs should not be allowed to eat aborted fetuses or calves that die (from any cause).
- Stray dogs should be destroyed.

References

1. Asmare, K., F. Regassa, L.J. Robertson, A.D. Martin, E. Skjerve, 2012. Reproductive disorders in relation to *Neosporacanium*, *Brucella* spp. and bovine viral diarrhoea virus serostatus in breeding and dairy farms of central and southern Ethiopia. *Epidemiol. Infeciont.*
2. Merck Manual 2014. Veterinary Professionals > Generalized Conditions > Neosporosis,

3. Susanne Stenlund, 2000. *Neosporacanium* in cattle in Sweden Isolation of the parasite and studies of its transmission. Doctoral thesis, Swedish University of Agricultural Sciences, Uppsala.
4. Sharifdini M, Mohebbali M, Keshavarz H, Hosseininejad M, Hajjarian H, Akhondi B, Rahimi-Foroushani A, Zarei Z, Charehdar S 2011. *Neosporacanium* and *Leishmania infantum* co-infection in domestic dogs (*Canis familiaris*) in Meshkin-shahr District, Northwestern Iran. *Iranian Journal of Arthropod Borne Disease*, 5:60-68.
5. Salehi N, Haddadzadeh HR, Shayan P 2010. Serological study of *Neosporacanium* in pregnant cattle in Tehran, Iran. *International Journal of Veterinary Research*, 4:113-116.
6. Gharekhani J 2014. Seroprevalence of *Neosporacanium* and *Toxoplasma gondii* infections in aborted cattle in Hamedan, Iran. *Journal of Advanced Veterinary and Animal Research*, 1:32-35.
7. Radostits, O.M., Gay, C.C., Hinchcliff, K.W., and Constable, P.D., 2008. Diseases associated with protozoa. 10th Edn. In: *Veterinary Medicine: A Textbook of Diseases of cattle, horses, sheep, pigs, and goats*. Saunders Elsevier, 1483-1540
8. Matthewa, J., 2009. Abortion. 3th Edn. In: *Diseases of the goat*. Blackwell Publishing Ltd. 23- 41.
9. Dubey, J. P., 2003. Review of *Neosporacanium* and neosporosis in animals. *Korean Journal of Parasitology* 41: 1–16.
10. Schares, G., and Conraths, F.J., 2007. *Neosporacanium* as a cause of bovine abortion- news regarding pathogenesis, epidemiology and diagnosis. *Praktische Tierarzt*. 88 (9 Hannover: Schlütersche Verlagsgesellschaft mbH & Co. KG, 730-740.
11. Smith, M.O., George, L.W., 2009. Diseases of the nervous system. In: Smith, B.P. (Eds): *Large Animal Internal Medicine*. Mosby, Elsevier, St. Louis.
12. Taylor, M.A., Coop, R.L., and Wall, R.L., 2007. *Veterinary Parasitology*. Third Edn. Blackwell Publishing.
13. <http://phys.org/news/2013-10-neospora-caninum-underestimated-reproductive-disorders.html#jCp>
14. Dubey, J.P., Buxton, D., and Wouda, W., 2006. Pathogenesis of bovine neosporosis. *Journal of Comparative Pathology*. 134 (4), 267-289.

15. Dubey J and G. Schares, 2006. Review Diagnosis of bovine neosporosis. *J.Vet. Parasitology* 140; 1–34
16. Slapeta, J. R., B. Koudela, J. Votypka, D. Modry, R. Horejs, And J. Lukes. 2002. Coprodiagnosis of *Hammondia heydorni* in dogs by PCR based amplification of ITS 1 rRNA: Differentiation from morphologically indistinguishable oocysts of *Neosporacanium*. *Veterinary Journal* 163: 147–154.
17. Speer CA, Dubey JP, McAllister MM, Blixt JA. Comparative ultrastructure of tachyzoites, bradyzoites, and tissue cysts of *Neosporacanium* and *Toxoplasma gondii*. *Int J Parasitol* 1999;29:1509–1519.
18. João Paulo A. Haddad, Ian R. Dohoo, John A. VanLeewen 2005. A review of *Neosporacanium* in dairy and beef cattle — a Canadian perspective *Can Vet J* Volume 46: 230-243
19. Katzer, F., Elisabeth, A. and Welsh, L. 2013. Neospora - a major problem for the British dairy industry The farmer's guide to tackling the disease. The Moredun Research Institute. UK, British
20. Dubey, J.P., Schares, G., 2011. Neosporosis in animals—the last five years. *Vet. Parasitol.* 180, 90–108.
21. Bjerkas I, Mohn SF, Presthus J. 1984 Unidentified cyst-forming sporozoon causing encephalomyelitis and myositis in dogs. *Z Parasitenkd*, 70:271–274.
- 21-22. [Singla LD \(2005\) Cryptosporidiosis and neosporosis: the emerging protozoan infections in domestic animals. In: *Proceeding of Training Course on Advances in Animal Health and Production* held from February 25-March 27, 2005 at SKUAST, Jammu, pp 29-34.](#)

Formatted: Font: Not Bold