

# Visual and Anatomical Outcomes of Pars Plana Vitrectomy for Dropped Nucleus

## Abstract

**Objective:** To evaluate the visual and anatomical outcomes of pars plana vitrectomy (PPV) in patients with dropped nucleus following complicated phacoemulsification (PE).

**Material and Method:** A retrospective study was conducted at the Ophthalmology Department of Lahore General Hospital, Lahore between 2017 and 2022. The study included 51 patients (33 males and 18 females) between the age 35 to 85 years who were referred after a complicated phacoemulsification with dropped nucleus.

**Results:** This study included 51 patients in which 33 were males (64.71%) and 18 were females (35.29%). All patients underwent 23-gauge pars plana vitrectomy. Posterior chamber phacofragmentation was carried out in 32 (62.75%) eyes while in remaining 19 (37.25%) patients vitrectomy cutter was used for the dropped nucleus. Out of 51, 06 (11.76%) patients received an anterior chamber IOL at the time of cataract surgery, 21 (41.18%) eyes had IOL in the ciliary sulcus, 07 (13.73%) had a posterior chamber IOL, and the remaining 17 (33.33%) patients were aphakic. Of these 17 aphakic patients, an anterior chamber IOL was placed at the time of vitrectomy in 07 (41.18%) patients who were judged to have inadequate capsular support for a posterior chamber lens. In the remaining 10 (58.82%) eyes, where capsular support was deemed adequate, a posterior chamber IOL was inserted. Final visual acuity was 20/40 or better in 34 (66.67%) eyes and 20/50 in 06 (11.76%) patients.

## Conclusion:

Poor visual outcome after dropped nucleus at phacoemulsification cataract extraction can be avoided if managed by prompt pars plana vitrectomy as it offers the advantages of a closed system for vitrectomy and manipulation of the nucleus, an improved view of the posterior segment and facilitated recognition and management of intraoperative complications with better visual and anatomical outcomes with low rate of postoperative complications.

## Introduction

One of the most dreaded side effects of cataract surgery is a dropped nucleus, which all cataract surgeons will experience if they undertake a sizable number of operations. Therefore, while evaluating patients for cataract surgery, ophthalmologists should be aware of the clinical characteristics linked to a higher risk of a sunken nucleus. These risk factors include characteristics linked to weak zonules, such as pseudoexfoliation, prior ocular trauma, prior vitrectomy, high myopia, uveitis, and retinitis pigmentosa, as well as an increased risk of a posterior capsular tear, such as a small pupil, dense cataract, posterior polar cataract, prior intravitreal injection, a less experienced surgeon, and a patient with a learning disorder or condition like dementia who may be more likely to move

Dropped nucleus and retained lens fragment is a complication not so rare in clinical practice. In the era where cataract One serious intraoperative complication of cataract surgery occurs if the posterior capsule is damaged during phacoemulsification of the lens and the nucleus drops into the vitreous cavity. In such

cases, a vitreous cutter or phacofragmatome must be used to extirpate the fragments of nucleus that have dropped into the vitreous cavity [1,2].

The popularization of microincision vitreous surgery (MIVS) has led to the use of 25-, 23-, and even 27-gauge systems for vitreous surgery that would formerly have been performed with a 20-gauge system [3].

This means that even when the nucleus drops as a complication of cataract surgery, the dropped lens is also often extirpated by MIVS [4,5].

surgery is being performed for visual enhancement rather than visual rehabilitation, the management of a dropped nucleus saves the patient from unnecessary anxiety and hastens visual recovery.

Pars plana vitrectomy (PPV) and release of vitreous adhesions from the dropped nucleus, followed by removal of the dislocated lens fragments using a phacofragmatome or vitrectomy probe is the most effective solution.[4]

The final visual outcome after PPV for dropped nucleus has been reported to be  $\geq 20/40$  in 44%–71.3% of patients.[5,6,7] The aims of this study were to evaluate the visual and anatomic outcomes of PPV for dropped nucleus and if possible to determine the prognostic factors affecting the final visual outcome.

## **Materials and methods:**

### **Study design:**

A retrospective study was conducted at the Ophthalmology Department of Lahore General Hospital, Lahore between 2017 and 2022

### **SAMPLE SIZE**

Sample size of 51 patients is estimated by using 95% confidence level, 7% absolute precision with expected percentage as 7.0 %.<sup>13</sup>

### **Using the formula:**

$$n = \frac{Z_{1-\alpha/2}^2 \cdot p \cdot q}{d^2}$$

where

$Z_{1-\alpha/2}$  = confidence interval 95% = 1.96

p = prevalence = 7.0%

q = 1 - p

d = absolute precision = 7%

## **SAMPLING TECHNIQUE**

Non probability, purposive sampling

## **SAMPLE SELECTION:**

### **Inclusion Criteria:**

1. Either gender
2. Age 25-55 years
3. Patients having cataract surgery with dropped nucleus

### **Exclusion Criteria:**

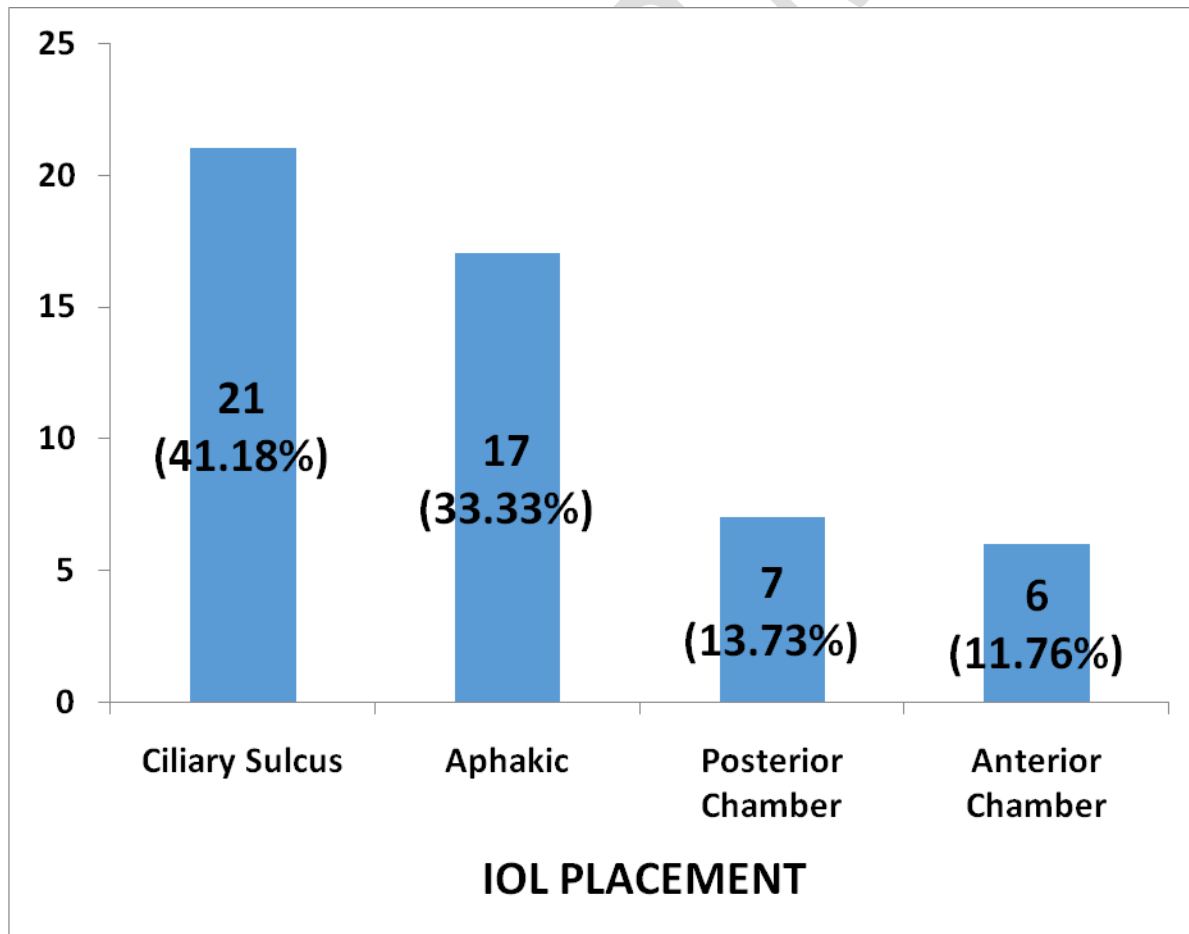
1. Patients who are on drugs like antimicrobials, sedatives, anticonvulsants, anti-inflammatory drugs, diuretics, gold salts and anti-diabetic drugs.
2. Patients having history of exposure to chemicals like ethanol, benzene and arsenic.
3. Known cases of liver disease (as per medical record).
4. Patients of human immunodeficiency virus infection (as per medical record).
5. Patients of autoimmune disorders e.g. systemic lupus erythematosus (as per medical record).
6. Patients who had been treated with H. pylori eradication therapy during past 4 weeks.
7. Patients with thrombotic thrombocytopenic purpura (as per medical record).
8. Gestational thrombocytopenia (as per medical record).
9. Patients of post transfusion thrombocytopenia (as per medical record).

The study included 51 patients (33 males and 18 females) between the age 35 to 85 years who were referred after a complicated phacoemulsification with dropped nucleus. After informed consent, patient's demographic characteristics, the interval between complicated PE and PPV, pre-and post-PPV visual acuity (VA), pre-and post-PPV intraocular inflammatory status, pre-and post-PPV IOP, the final intraocular lens (IOL) status and complications were recorded. The presence of retained lens fragments was confirmed by ophthalmoscopy or echography in all patients. All the patients underwent 23-gauge pars plana vitrectomy, removal of dropped nucleus with IOL implantation. The range of follow-up was 02 months to 05 years.

## Results:

This study included 51 patients in which 33 were males (64.71%) and 18 were females (35.29%). The mean age was 52.5 years. Mean interval between cataract surgery and PPV was 07 days. Nuclear fragments were found in 34 (66.67%) eyes, cortical matter in 03 (5.88%) eyes while entire nucleus was dropped in 14 (27.45%) patients. Five (35.71%) of the 14 patients, had retinal detachment at the time of presentation. All patients underwent 23-gauge pars plana vitrectomy. Posterior chamber phacofragmentation was carried out in 32 (62.75%) eyes while in remaining 19 (37.25%) patients vitrectomy cutter was used for the dropped nucleus. Out of 51, 06 (11.76%) patients received an anterior chamber IOL at the time of cataract surgery, 21 (41.18%) eyes had IOL in the ciliary sulcus, 07 (13.73%) had a posterior chamber IOL, and the remaining 17 (33.33%) patients were aphakic. Of these 17 aphakic patients, an anterior chamber IOL was placed at the time of vitrectomy in 07 (41.18%) patients who were judged to have inadequate capsular support for a posterior chamber lens. In the remaining 10 (58.82%) eyes, where capsular support was deemed adequate, a posterior chamber IOL was inserted. Final visual acuity was 20/40 or better in 34 (66.67%) eyes and 20/50 in 06 (11.76%) patients. Visual acuity was 20/70 or worse in 11 (21.57%) patients. The main cause of decreased final visual acuity was cystoid macular edema and bullous keratopathy due to AC-IOL.[Graph 1]

Patients were followed for weekly for a month and after that results were recorded and improvement of final visual acuity noted



## Graph 1. IOL PLACEMENT

### Discussion:

PPV is the preferred management for dropped nucleus after complicated cataract surgery. In most cases, removal of lens fragments leads to improvement in VA and reduces inflammation and IOP.

Many cases of posteriorly dislocated lens fragments may go undiagnosed, especially when they are well tolerated by the eye with little or no symptoms. In other instances, the lens fragments may stimulate a mild inflammatory reaction, which is easily controlled medically. Although PPV is considered the preferred surgical procedure in the management of posteriorly dislocated lens fragments following cataract surgery, a review of the literature indicates a lack of consensus regarding what effect the timing of this procedure has on the final visual outcome. According to several studies, patients undergoing PPV to manage retained lens fragments experienced a higher incidence of long-term complications (e.g., corneal edema, uveitis, glaucoma, and retinal detachment) when the performance of this procedure was delayed.<sup>[9]</sup> In contrast, other studies found that the timing of PPV in managing patients with posteriorly dislocated lens fragments after cataract surgery did not have an effect on the final visual outcome and the rate of complications.<sup>8,11,12</sup> Some have suggested that delaying vitrectomy for 2 or more weeks can facilitate the eventual procedure by allowing for softening of nuclear material, posterior vitreous detachment, and better control of intraocular inflammation and pressure. Al-Khaier and coauthors<sup>13</sup> found that a delay of vitrectomy for more than 4 weeks correlated with poor visual outcome. Other large series have failed to demonstrate a statistically significant association between the timing of vitrectomy and chronic glaucoma or visual outcome.<sup>11</sup>

### Intraoperative complications

The most frequent consequence, miosis, was more frequently seen with phaco sandwich and irrigating vectis methods, which are associated with more instrumental AC manipulations. Because engaging the nucleus was a blind procedure in thick nucleus sclerosis, there was less visibility of the hook behind the nucleus, which resulted in the iris becoming entangled in the hook. However, Sambarey et al.'s study<sup>[14]</sup> found that ACM cases had a higher rate of pupillary constriction.

Because of iris damage and tunnel bleeding, irrigating vectis and fishhook procedures occasionally resulted in intraoperative hyphema. Iridodialysis and tunnel bleeding were the distinguishable causes in viscoexpression method. All cases involving phaco sandwich and ACM methods were brought on by tunnel bleed. In their research, Novak and Grybowski<sup>[15]</sup> and Schroeder<sup>[16]</sup> both noted the incidence of hyphema. Despite the fact that our data suggests that the surgical procedure has no effect on its incidence

### Postoperative complications

Injuries to the iris, striate keratopathy, and posterior capsular rent can result from instrument handling inside the AC during nucleus administration.<sup>[4]</sup> Striate keratopathy, transitory postoperative corneal

edoema, and AC inflammatory response were the most frequent postoperative complications. Other issues included hyphema, retained cortical tissue, and uneven pupil size.

Instrumental approaches produced considerably more striate keratopathy at the incision site. When compared to the irrigating vectis, viscoexpression, and ACM groups, the incidence and severity of transient corneal edoema were considerably higher in the phacosandwich and fishhook groups. On the seventh POD, however, edoema cleared in all groups, and corneal edoema outcomes were equivalent across groups.

When compared to phacoemulsification, Gogate et al.[17] observed that there is no appreciable loss of endothelial cells in MSICS. Transient corneal edoema that resolves during the first week has been documented in numerous other MSICS studies.[18,19] This variation in corneal edoema occurrence between groups is brought on by the fact that endothelial damage in MSICS can, in part, be linked to the method used to deliver the nucleus because certain methods are, in theory, more sound than others. Since the chamber is maintained during all surgical procedures (and the endothelium is preserved), the Blumenthal technique of MSICS has less of an impact on the endothelium[19]. Additionally, the viscosurgical instrument used in viscoexpression provides adequate endothelium protection.

### **Conclusion:**

Poor visual outcome after dropped nucleus at phacoemulsification cataract extraction can be avoided if managed by prompt pars plana vitrectomy as it offers the advantages of a closed system for vitrectomy and manipulation of the nucleus, an improved view of the posterior segment and facilitated recognition and management of intraoperative complications with better visual and anatomical outcomes with low rate of postoperative complications

### **Ethical committee:**

Ethical committee of Lahore general hospital gave approval for this study

### **References:**

1.Sihota R, Tandon R, editors. Parson's diseases of the eye. 20th ed. Elsevier; New Delhi: 2007. p. 264. [Google Scholar]

2. Steinert RF. Complications of cataract surgery. In: Albert DM, Jakobiec FA, editors. Principles and Practice of Ophthalmology. 2nd ed. WB Saunders; Philadelphia: 2000. pp. 1551–1598. [[Google Scholar](#)]
3. Pande N, Dabbs TR. Incidence of lens matter dislocation during phacosurgery. *J Cataract Refract Surg*. 1996;22:737–742. [[PubMed](#)] [[Google Scholar](#)]
4. Rofagha S, Bhisitkul RB. Management of retained lens fragments in complicated cataract surgery. *Curr Opin Ophthalmol*. 2011;22:137–140. [[PubMed](#)] [[Google Scholar](#)]
5. Margherio RR, Margherio AR, Pendergast SD, Williams GA, Garretson BR, Strong LE, et al. Vitrectomy for retained lens fragments after phacoemulsification. *Ophthalmology*. 1997;104:1426–1432. [[PubMed](#)] [[Google Scholar](#)]
6. Hanson LJ, Larsson J. Vitrectomy for retained lens fragments in the vitreous after phacoemulsification. *J Cataract Refract Surg*. 2002;28:1007–1011. [[PubMed](#)] [[Google Scholar](#)]
7. Salam GA, Greene JM, Deramo VA, Tibrewala RK, Ferrone PJ, Fastenberg DM. Retinal tears and retinal detachment as factors affecting visual outcome after cataract extraction complicated by posteriorly dislocated lens material. *Retina*. 2005;25:570–575. [[PubMed](#)] [[Google Scholar](#)]
8. Stilma JS, van der Sluijs FA, van Meurs JC, Mertens DA. Occurrence of retained lens fragments after phacoemulsification in the Netherlands. *J Cataract Refract Surg* 1997;23:1177-1182.
9. Margherio RR, Margherio AR, Pendergast SD, et al. Vitrectomy for retained lens fragments after phacoemulsification. *Ophthalmology* 1997;104:1426-1432.
10. Movshovich A, Berrocal M, Chang S. The protective properties of liquid perfluorocarbons in phacofragmentation of dislocated lenses. *Retina* 1994;14:457-462.
11. Borne MJ, Tasman W, Regillo C, et al. Outcomes of vitrectomy for retained lens fragments. *Ophthalmology* 1996;103:971-976.
12. Kim JE, Flynn HW Jr, Smiddy WE, et al. Retained lens fragments after phacoemulsification.
13. Al-Khaier A, Wong D, Lois N, et al. Determinants of visual outcome after pars plana vitrectomy for posteriorly dislocated lens fragments in phacoemulsification.
14. Sambarey P, Maithil P, Vabale V, Bandhu S, Kambale B, Barhate V. Anterior chamber maintainer (ACM): A useful aid in small incision cataract surgery. *Internet J Ophthalmol Vis Sci*. 2009;7:2. [[Google Scholar](#)]
15. Novak R, Grybowski A. Outcome of an outreach microsurgical project in rural Nepal. *Saudi J Ophthalmol*. 2013;27:3–9. [[PMC free article](#)] [[PubMed](#)] [[Google Scholar](#)]
16. Schroeder B. Sutureless cataract extraction: Complications and management; learning curves. *Community Eye Health*. 2013;16:48. [[PMC free article](#)] [[PubMed](#)] [[Google Scholar](#)]
17. Gogate P, Ambardekar P, Kulkarni S, Deshpande R, Joshi S, Deshpande M. Comparison of endothelial cell loss after cataract surgery: Phacoemulsification versus manual small incision cataract surgery: Six weeks results of a randomized controlled trial. *J Cataract Refract Surg*. 2010;36:247–53. [[PubMed](#)] [[Google Scholar](#)]

18. George R, Rupauliha P, Sripriya AV, Rajesh PS, Vahan PV, Praveen S. Comparison of endothelial cell loss and surgically induced astigmatism following conventional extra capsular cataract surgery, manual small-incision surgery and phacoemulsification. *Ophthalmic Epidemiol.* 2005;12:293–7. [[PubMed](#)] [[Google Scholar](#)]
19. Thomas R. Role of small incision cataract surgery in the Indian scenario. *Indian J Ophthalmol.* 2009;57:1–2. [[PMC free article](#)] [[PubMed](#)] [[Google Scholar](#)]
20. Patil P, Lune A, Radhakrishnan K. Evaluation and comparison of surgically induced astigmatism between phacoemulsification and small incision cataract surgery. *Sudanese J Ophthalmol.* 2013;5:67–72. [[Google Scholar](#)]
- 21 Zeng Y, Deng JW, Gao J. A novel nucleus extraction technique using a vectis in a sutureless, manual, small incision cataract surgery. *Nepal J Ophthalmol.* 2014;6:140–4. [[PubMed](#)] [[Google Scholar](#)]

UNDER PEER REVIEW