

Cardiac Thyrotoxicosis Mimicking an Acute Coronary Syndrome

ABSTRACT

This case report details the clinical presentation, diagnosis, and multidisciplinary management of a 68-year-old man with cardiac thyrotoxicosis mimicking an acute coronary syndrome (ACS). The patient presented with persistent anginal chest pain, systemic symptoms, and electrocardiographic abnormalities suggestive of ACS. Despite presenting with persistent chest pain and ACS-like symptoms, a thorough examination, including the calculation of the thyrotoxicosis storm (StPRM) score, revealed thyrotoxicosis-induced dilated cardiomyopathy, challenging the initial diagnosis. This specific scoring for thyrotoxicosis severity played a crucial role in accurately identifying the thyrotoxic crisis. The case highlights the intricate relationship between thyroid dysfunction and cardiovascular manifestations, emphasizing the need for a multidisciplinary approach. Management included standard ACS protocols, careful titration of antithyroid medications, and the transition from intravenous to oral heart failure medications. Follow-up assessments demonstrated the success of personalized treatment strategies, with the normalization of thyroid function and complete resolution of the patient's symptoms. Nevertheless, the enduring impairment of left ventricular function following treatment prompts intriguing inquiries into the lasting impact of cardiac thyrotoxicosis on myocardial recovery. However, the persistence of impaired left ventricular function post-treatment raises intriguing questions about the lingering effects of cardiac thyrotoxicosis on myocardial recovery. This case underscores the importance of considering diverse cardiac presentations in hyperthyroid patients and the effectiveness of individualized management approaches in navigating the complexities of thyroid-cardiac interactions.

Keywords: Cardiac thyrotoxicosis, Acute coronary syndrome, Heart failure, Dilated cardiomyopathy

INTRODUCTION

An acute coronary syndrome (ACS) is a constellation of signs and symptoms associated with insufficient flow through the coronary tree and the resultant acute ischemia of the myocardium. The cardinal sign of a patient with ACS is chest pain that is usually described as central, substernal, like a pressure, and it can be nonradiating or can radiate to the left shoulder, to the jaw, or to the left arm (1)(2). We present a case report about cardiac thyrotoxicosis mimicking an acute coronary syndrome. Despite presenting with persistent chest pain and ACS-like symptoms, a thorough examination, including the calculation of the thyrotoxicosis storm (StPRM) score, revealed thyrotoxicosis-induced dilated cardiomyopathy, challenging the initial diagnosis.

CASE PRESENTATION

We present the case of a 68-year-old man, hypertensive and chronic smoker, who sought emergency care for persistent anginal chest pain evolving over 10 days and worsening over the last 14 hours. The patient's medical history revealed no particular pathological antecedents or coronary heredity, and no other modifiable cardiovascular risk factors. The retrosternal, constrictive pain irradiating to the jaw and interscapular region occurred at rest, was prolonged, nitrate-resistant, and worsened 14 hours before admission to the emergency department, accompanied by concurrent

palpitations. The comprehensive history revealed a generalized feeling of asthenia with excessive sweating and diarrhea over the past 10 days, without abdominal pain, vomiting, or fever.

On general clinical examination, the patient was conscious, hemodynamically stable with a blood pressure of 141/82 mmHg, a heart rate of 140 bpm, eupneic at rest, and a saturation of 98% in ambient air. Auscultation revealed bilateral symmetric crepitant rales at the lung bases, with no signs of right heart failure. The patient was afebrile at 37.1°C. Thyroid palpation yielded normal results. The admission ECG (Figure 1) showed a regular sinus rhythm at 140 bpm, a fixed and constant PR interval at 160 ms, left-axis deviation, complete left bundle branch block (LBBB) with secondary repolarization abnormalities (negative Sgarbossa criteria). Serial laboratory tests revealed elevated troponins at 429.3 ng/L (30 times the upper limit of normal), a suppressed TSH below 0.01 mIU/L with increased free T3 and T4 levels at 20 ng/L and 3.6 ng/dL, respectively. Inflammatory markers were elevated. Echocardiography demonstrated features of dilated cardiomyopathy with global severe hypokinesis and left ventricular dysfunction (left ventricular ejection fraction: 25%), elevated left ventricular filling pressures, and no mitral or aortic valve pathologies. The probability of pulmonary hypertension was low.

This case underscores the clinical complexity, combining acute coronary syndrome, dilated cardiomyopathy, and thyrotoxicosis. A multidisciplinary approach is crucial for effective management of these diverse components.

The patient was admitted to the cardiology intensive care unit and closely monitored. He has received the loading dose of clopidogrel 300 mg and aspirin 300 mg, along with heparin therapy. The gradual introduction of the rest of the heart failure management regimen is underway.

The patient's case was discussed in a multidisciplinary meeting, during which endocrinologists did not authorize performing a coronary angiography due to the context of thyrotoxic crisis. **The diagnosis of thyrotoxic crisis was made by calculating thyrotoxicosis storm score "Burch-Wartofsky Point Scale (BWPS)".** Treatment with synthetic antithyroid drugs and corticosteroids was initiated, showing a significant improvement in both clinical and biological aspects. Coronary angiography was authorized 10 days after the initiation of the treatment, revealing no abnormalities (figure 2).

Cardiac magnetic resonance imaging (MRI) was performed to rule out myocarditis associated with hyperthyroidism, which is the primary differential diagnosis. The cardiac (figure 3) revealed a dilated cardiomyopathy without specific signs and no evidence supporting myocarditis.

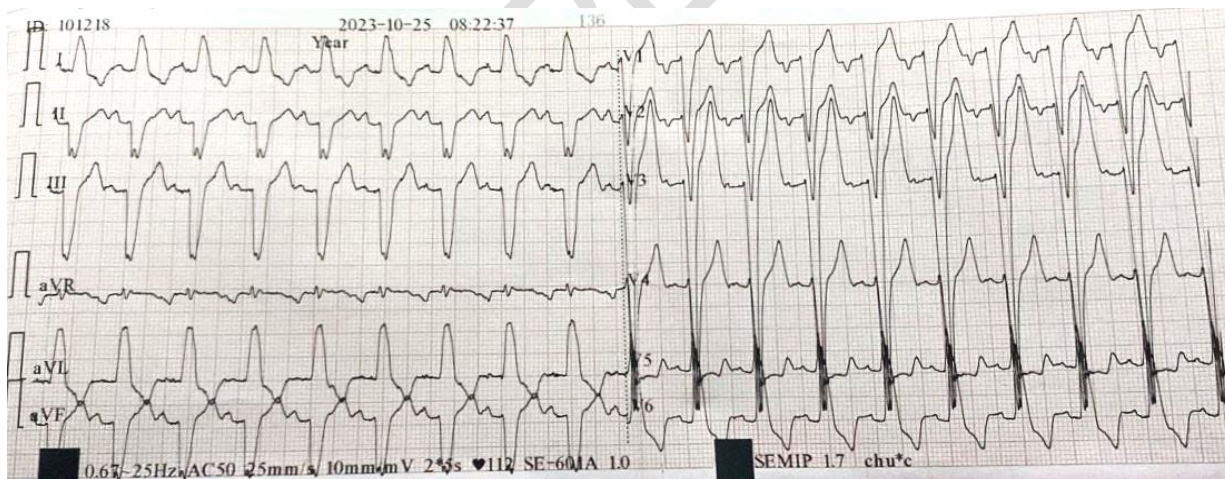


Figure 1. EKG at admission showing a complete LBBB

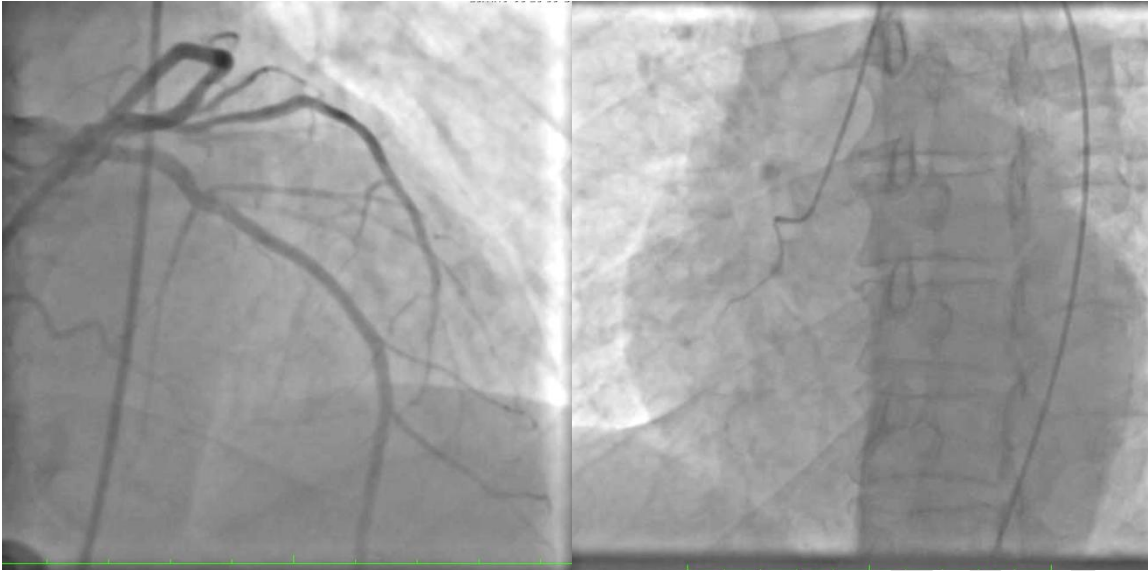


Figure 2. The coronary angiography showing a left dominance network with no significant atheromatous lesions.

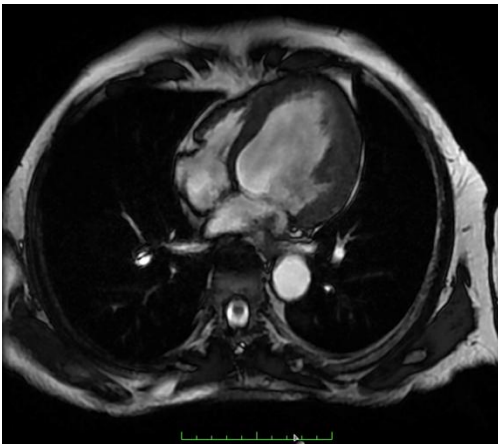


Figure 3. Cardiac MRI showing dilated cardiomyopathy without specific pattern

2. DISCUSSION

The presented case of a 68-year-old hypertensive and chronic smoker reveals a complex interplay between cardiac thyrotoxicosis and symptoms mimicking acute coronary syndrome (ACS). The patient presented an atypical clinical presentation, characterized by persistent anginal chest pain, systemic symptoms, and electrocardiographic abnormalities, prompted a comprehensive diagnostic and therapeutic approach.

The diagnostic challenges in this case stemmed from the overlapping features of cardiac thyrotoxicosis and ACS. The coexistence of palpitations, excessive sweating, diarrhea, and asthenia, raised suspicion for an alternative etiology. **A**

comprehensive assessment was requested, including a thyroid panel, which returned highly disturbed results indicative of overt hyperthyroidism. Thyroid storm, also known as thyrotoxic crisis, is an acute, life-threatening complication of hyperthyroidism. It is an exaggerated presentation of thyrotoxicosis. It comes with sudden multisystem involvement(3)(4). The identification of thyroid storm requires clinical suspicion based on the clinical presentation in a patient with hyperthyroidism or suspected hyperthyroidism. It is crucial not to delay treatment until receiving lab results. Thyroid function tests, typically revealing elevated FT4/FT3 and reduced TSH levels, can be obtained. Importantly, a significantly high level of thyroid hormone is not necessary to trigger thyroid storm(5). Additional lab abnormalities may encompass hypercalcemia, hyperglycemia (due to insulin release inhibition and increased glycogenolysis), abnormal liver function tests (LFTs), and variations in white blood cell (WBC) count.

The Burch-Wartofsky Point Scale (BWPS) (6), introduced in 1993, serves as a scoring system for thyroid storm diagnosis.

The scale includes:

- Temperature
- Central nervous system dysfunction
- Tachycardia
- Atrial fibrillation
- Heart failure
- Gastrointestinal dysfunction
- Presence of a Precipitating factor

A total score exceeding 45, is strongly suggesting thyroid storm.

The admission ECG, indicative of sinus tachycardia, left bundle branch block (LBBB), and repolarization abnormalities, along with elevated troponin levels, complicated the diagnostic landscape. The subsequent revelation of thyrotoxicosis, in conjunction with echocardiographic evidence of dilated cardiomyopathy, highlighted the intricate relationship between thyroid dysfunction and cardiovascular manifestations.

The phenomenon of thyrotoxicosis-induced dilated cardiomyopathy is a rare but recognized manifestation of hyperthyroidism(7). Thyroid hormones influence myocardial contractility, heart rate, and peripheral vascular resistance, and the hyperadrenergic state induced by thyrotoxicosis can lead to dilated cardiomyopathy in severe cases (8)(9). The unique combination of dilated cardiomyopathy, ACS-like symptoms, and thyrotoxicosis in this case aligns with existing literature emphasizing diverse cardiac presentations in hyperthyroid patients(10)(11).

The multidisciplinary approach employed in the management of this case was crucial. Admission to the cardiology intensive care unit, initiation of antiplatelet therapy, and anticoagulation followed standard ACS protocols. However, the disturbed thyroid profile warranted caution, leading to the postponement of coronary angiography. The subsequent introduction of antithyroid medications and corticosteroids, coupled with careful titration of beta-blockers and the transition from intravenous to oral diuretics, reflected the dynamic nature of the treatment strategy.

The successful outcomes observed, including the normalization of thyroid function and the gradual introduction of heart failure medications, support the individualized treatment approach in complex clinical scenarios. Follow-up assessments, encompassing thyroid function tests and electrocardiography, played a pivotal role in monitoring the patient's progress. The detection of atrial fibrillation on follow-up ECG underscored the dynamic nature of the relationship between thyroid dysfunction and cardiac manifestations(12).

The predominant manifestation of cardiothyrotoxicosis is heart failure rather than acute coronary syndrome(13)(14). While both conditions may share some clinical features, the underlying pathophysiological mechanisms differ significantly. In cardiothyrotoxicosis, the excessive levels of thyroid hormones, particularly triiodothyronine (T3), can lead to a hyperdynamic circulatory state. This state is characterized by increased heart rate, elevated cardiac output, and reduced systemic vascular resistance.

The impact of thyroid hormone excess on the cardiovascular system includes direct effects on myocardial contractility and relaxation, as well as alterations in peripheral vascular resistance(15). These changes collectively contribute to the development of a high-output heart failure syndrome. The increased demand on the heart, coupled with potential structural changes such as myocardial hypertrophy, can result in dilated cardiomyopathy and compromised cardiac function over time.

In contrast, acute coronary syndrome primarily involves a disruption in coronary blood flow, leading to myocardial ischemia or infarction. The clinical presentation often includes chest pain or discomfort, shortness of breath, and other symptoms related to insufficient blood supply to the heart muscle. This condition is commonly associated with atherosclerotic plaque rupture, thrombus formation, and subsequent coronary artery obstruction.

While there can be overlapping symptoms between cardio-thyrotoxicosis and acute coronary syndrome, distinguishing between the two is crucial for appropriate management. The characteristic feature of heart failure in cardio-thyrotoxicosis, in the absence of significant coronary artery disease, highlights the importance of considering thyroid function evaluation in patients presenting with heart failure symptoms. This differentiation is vital to tailor the treatment approach, with a focus on addressing the underlying thyroid dysfunction in cardio-thyrotoxicosis rather than the coronary artery pathology seen in acute coronary syndrome.

4. CONCLUSION

In conclusion, this case illustrates the intricate interplay between cardiac thyrotoxicosis and ACS-like symptoms, emphasizing the challenges in diagnosis and the significance of a multidisciplinary approach. The successful management, guided by a nuanced understanding of thyroid function and cardiovascular dynamics, reinforces the importance of individualized treatment strategies in complex clinical scenarios.

Consent

As per international standards or university standards, patientwritten consent has been collected and preserved by the authors.

Ethical approval

As per international standards or university standards written ethical approval has been collected and preserved by the author(s).

UNDER PEER REVIEW

REFERENCES

1. Bergmark BA, Mathenge N, Merlini PA, Lawrence-Wright MB, Giugliano RP. Acute coronary syndromes. *The Lancet*. avr 2022;399(10332):1347- 58.
2. Santos-Gallego CG, Picatoste B, Badimón JJ. Pathophysiology of Acute Coronary Syndrome. *Curr Atheroscler Rep*. avr 2014;16(4):401.
3. Galindo RJ, Hurtado CR, Pasquel FJ, García Tome R, Peng L, Umpierrez GE. National Trends in Incidence, Mortality, and Clinical Outcomes of Patients Hospitalized for Thyrotoxicosis With and Without Thyroid Storm in the United States, 2004–2013. *Thyroid*. janv 2019;29(1):36- 43.
4. Swee DS, Chng CL, Lim A. Clinical Characteristics and Outcome of Thyroid Storm: A Case Series and Review of Neuropsychiatric Derangements in Thyrotoxicosis. *Endocrine Practice*. févr 2015;21(2):182- 9.
5. Ross DS, Burch HB, Cooper DS, Greenlee MC, Laurberg P, Maia AL, et al. 2016 American Thyroid Association Guidelines for Diagnosis and Management of Hyperthyroidism and Other Causes of Thyrotoxicosis. *Thyroid*. oct 2016;26(10):1343- 421.
6. Burch HB, Wartofsky L. Life-threatening thyrotoxicosis. Thyroid storm. *Endocrinol Metab Clin North Am*. juin 1993;22(2):263- 77.
7. Khalil Y, Dube MD, Woods L. Thyrotoxicosis-Induced Cardiomyopathy With Systolic Dysfunction. *Cureus*. janv 2023;15(1):e33988.
8. Biondi B, Palmieri EA, Lombardi G, Fazio S. Effects of Thyroid Hormone on Cardiac Function - The Relative Importance of Heart Rate, Loading Conditions, and Myocardial Contractility in the Regulation of Cardiac Performance in Human Hyperthyroidism. *The Journal of Clinical Endocrinology & Metabolism*. mars 2002;87(3):968- 74.
9. Klein I, Danzi S. Thyroid Disease and the Heart. *Circulation*. 9 oct 2007;116(15):1725- 35.
10. Molinaro G, De Vecchis R, Badolati E, Giannattasio R. Thyrotoxic dilated cardiomyopathy: personal experience and case collection from the literature. *Endocrinology, Diabetes & Metabolism Case Reports* [Internet]. 24 déc 2020 [cité 2 janv 2024];2020. Disponible sur: <https://edm.bioscientifica.com/view/journals/edm/2020/1/EDM20-0068.xml>
11. Fiorilli R, Del Prete G, Fasano ML, Sacco I. [Dilated thyrotoxic cardiomyopathy]. *Ital Heart J Suppl*. juill 2000;1(7):931- 4.
12. Sayin I, Ertek S, Cesur M. Complications of Hyperthyroidism. In: Diaz-Soto G, éditeur. *Thyroid Disorders - Focus on Hyperthyroidism* [Internet]. InTech; 2014 [cité 2 janv 2024]. Disponible sur: <http://www.intechopen.com/books/thyroid-disorders-focus-on-hyperthyroidism/complications-of-hyperthyroidism>
13. Yaméogo AA, Yaméogo NV, Compaoré YD, Ouédraogo TL, Zabsonré P. [Cardiothyreosis at the University Hospital of Bobo-Dioulasso, Burkina Faso]. *Pan Afr Med J*. 2012;11:38.
14. Hajar R. Congestive Heart Failure: A History. *Heart Views*. 2019;20(3):129- 32.
15. Osman F. Thyroid disease and its treatment: short-term and long-term cardiovascular consequences. *Current Opinion in Pharmacology*. 1 déc 2001;1(6):626- 31.

UNDER PEER REVIEW