

## A CASE REPORT ON ENDODONTIC MANAGEMENT OF MAXILLARY FIRST MOLAR WITH TWO PALATAL CANALS

### ABSTRACT:

Endodontic therapy of maxillary first molars can be difficult, especially when root canal morphology varies unexpectedly. The presence of two palatal canals is unusual in maxillary first molars.

The presence of two palatal canals must be correctly diagnosed for appropriate treatment. CBCT (Cone Beam Computed Tomography) and other diagnostic tools can help for the detection of the exact position and form of the canals. To address both the conventional canals and the extra palatal canals, an ineffective treatment planning is required.

The preparation of the access cavity is critical in identifying the palatal canals. A conservative access cavity design that preserves tooth structure and structural integrity is advantageous. For the detection of the canals, magnification, illumination, and careful examination with small sized endodontic files are required.

Because of their complicated and difficult nature, palatal canal instrumentation needs specialized procedures. To adequately prepare the canals, a combination of manual files, rotary files, and ultrasonic tips may be used. To ensure adequate disinfection and removal of bacteria and debris from the complex canal anatomy, careful shaping and cleaning are required.

Canal obturation should aim for a three-dimensional sealing, ensuring complete filling of the root canal system. The use of proper obturation procedures can improve the quality of root canal therapy.

This paper provides an overview of the endodontic management of a maxillary first molar with two palatal canals, discussing the diagnosis, treatment planning, access cavity preparation, and the use of appropriate instrumentation and obturation techniques.

Key word: Endodontic therapy, Buccal Canal root canals

### INTRODUCTION:

When a tooth has been damaged by pathosis, the main objective of the endodontic treatment is to prevent and intercept pulpal/periradicular pathosis so that natural dentition can be retained. (1) Among the most common reasons for endodontic therapy failure is the inability to negotiate, clean, or obturate all existing root canals. (2,3) The main concept of root canal treatment is complete mechanical cleaning and comprehensive debridement, followed by three-dimensional obturation to establish a tight closure. (4) While the most studies of the maxillary first molar focus on the frequency of a fourth canal (MB2) in the mesiobuccal root, this case study looks into the likelihood of a second palatal canal and the associated endodontic therapy options. A

maxillary first molar with two palatal canals was described by Aggarwal et al., whereas documented by Tomazinto et al. (5)

**AIM:**

The purpose of this case study is to show how a maxillary first molar with two palatal canals can be managed.

**CASE HISTORY**

A 40-year-old man presented to the Department of Conservative Dentistry and Endodontics at DA Pandu Memorial RV Dental College in Bangalore with a chief complaint of pain in the upper left posterior region that was exacerbated by drinking cold drinks for more than a month.

For six months, the patient complained periodic pain in the upper left region.

Two months before visiting our department, he had previous restorative treatment for his maxillary left molar in another clinic, which had promptly cracked.

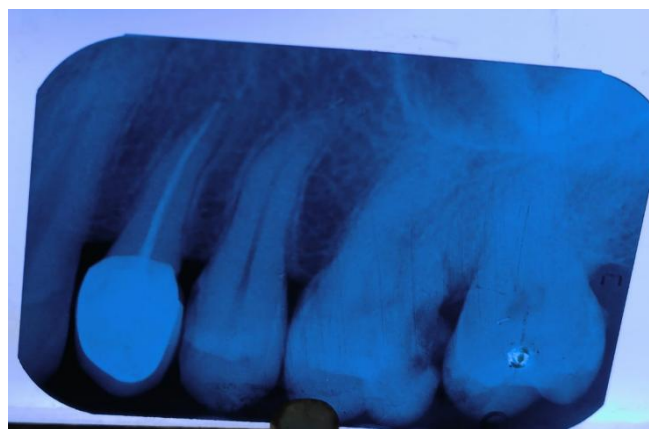
Recently, the patient suffered acute pain, which was exacerbated by cold stimulation.

The patient also complained of food bloating in the same area.

Restorative therapy had been provided for the patient's left maxillary first molar and maxillary first premolar.

The patient denied having any systemic disorders or allergies. There was no relevant family history.

A clinical examination indicated a disto-occlusal deterioration of class II (figure 1) with no periapical abscess or sinus tract.



**fig.1: preoperative radiograph of 26 showing radiolucency extending into pulp**

A periodontal examination was also performed using a williams's graduated probe, which demonstrated a normal probing depth.

Percussion on the teeth caused it to be sore. Periapical radiographs( Vision Medicaid Equipment Private Limited, India) revealed that disto-occlusal caries had progressed to pulp chamber, without any periapical changes.

### **DIAGNOSIS:**

The left maxillary first molar was diagnosed with irreversible pulpitis and apical periodontitis.

Following the treatment advice of root canal treatment and follow-up crown restoration, the treatment regimen was explained to the patient and agreement was acquired.

### **TREATMENT:**

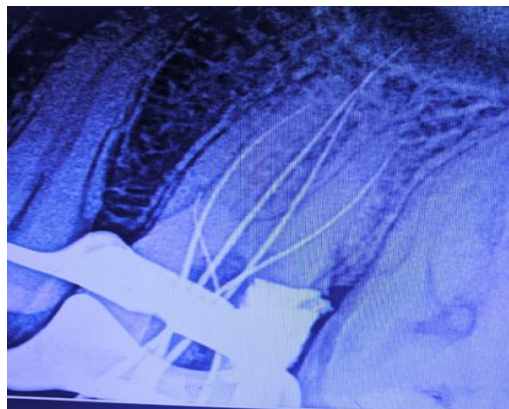The root canal therapy was initiated with the patient's informed consent after discussing the treatment plan and its consequences. One cartridge infiltration was used to provide local anesthesia, and a rubber barrier was used to isolate the tooth. (2% lidocaine in a 1:80,000 epinephrine solution).

All soft caries were removed using a round bur(Mani diamond bur); endo-access bur (Dentsply), was used to create access cavity. All canals were mesiobuccally, distobuccally, and palatally situated.

Clinically, a tiny hemorrhagic spot was observed next to the palatal orifice and mesiobuccal aspect .Using DG16 to gain access to both canals.

A smaller k-file #10 (Mani k files) was used to check the canal's patency before negotiating the canal and increased to k file #15(Mani k files).

The working length was determined using the CanalPro apex locator (Coltene) and validated with aperiapical radiograph( Vision Medicaid Equipment Private Limited, India)(Figure 2).



**fig.2: working length radiograph of 26 with two palatal canals, mesiobuccal and distobuccal canals**

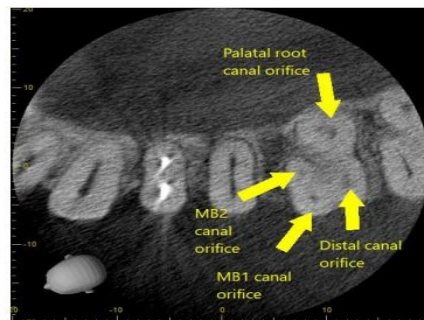
Irrigation with sodium hypochlorite (3%) and normal saline (0.9%) was extensive. The access cavity was subsequently sealed with zinc oxide eugenol (Perfection Plus LTD, UK).

The patient was asymptomatic on the second appointment. The patient was advised to undergo **CBCT(Carestream Cs9300,INDIA)** so that we could analyze the root canal anatomy in three dimensions.

After being told about the complex and atypical anatomy of root canal, the patient was eager to have the teeth evaluated with **CBCT(Carestream Cs9300,INDIA)**. The patient provided informed consent to have the CBCT checkup done on those specific teeth.

**CBCT IMPRESSION:**

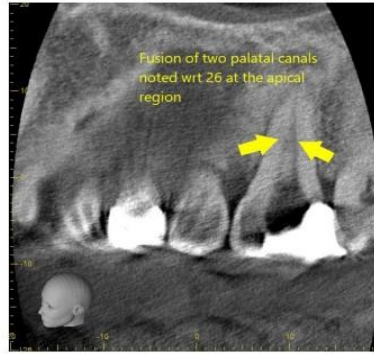
According to the CBCT report, the maxillary first molar showed three roots with five canals (MB1, MB2, DB, MP, DP) (figure 3).



**fig.3: cbct image showing 5 canal orifices at the junction of cervical and middle third**

Two palatal orifices were discovered at the junction of the cervical and middle third portions of the root with respect to 26.

Both palatal canals are fusing in the apical area, as revealed by the CBCT data (Figure:4)



**fig.4: cbct image showing fusion of two palatal canals at apical third**

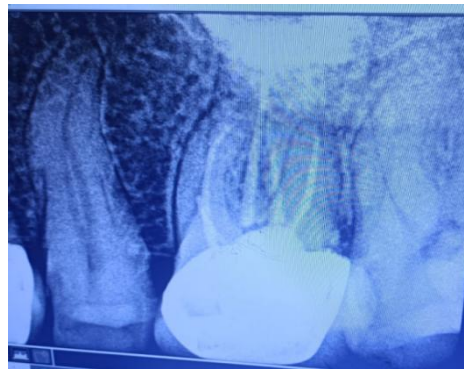Initial instrumentation was completed with profuse NaOCl irrigation (3%) and normal saline (0.9%) up to #25k manual file (Mani k file) to full working length. The final instrumentation was carried out with a 25/0.04 (NiTi file) with 17% EDTA (Dia Pre Pro, Dia Dent, Korea) and abundant irrigation of sodium hypochlorite (NaOCl) (3%). The last irrigation used a large amount of saline (0.9%).

The master cone periapical radiograph was obtained. The canals were dried using paper points (METABIOMED, Cheonaju, Korea) and obturated with 25/0.04 gutta-percha (META BIOMED, Cheonaju, Korea) using single cone technique with zinc oxide eugenol sealer (Perfection Plus LTD, UK)

Final restoration was done using composite ( IVOCLAR TE-ECONOM PLUS) and the patient was recalled for further treatment.

#### **OUTCOME AND FOLLOWUP:**

The maxillary first molar was entirely asymptomatic after one month of follow-up. Following that, tooth preparation and the final ceramic crown cementation was completed (Figure:5)



**fig 5: post operative radiograph after crown cementation**

After three months, there was no clinical symptom and radiographs showed the tooth to be in good condition.

## **DISCUSSION:**

Endodontic treatment of the maxillary first molar can be challenging, particularly if it has several canals.

The presence of two palatal canals in the maxillary first molar is a rare anatomical defect that is found only in a small percentage of people. A recent study found only one specimen with four roots among 1365 maxillary first molars, yielding a 0.07% incidence, while the incidence in maxillary second molars was 0.98%.<sup>(6)</sup>

Diagnosis of a maxillary first molar with two palatal canals might be difficult due to the complicated anatomy and the possibility of overlapping or fused canals.

Various diagnostic tools, such as periapical radiography, cone-beam computed tomography (CBCT), dental operating microscopes, and dental loupes, can aid in the detection and visualization of these additional canals.<sup>(7)</sup>

CBCT scans have been demonstrated to be more accurate than conventional radiography in terms of root canal anatomy.

Once the presence of two palatal canals is confirmed, proper access cavity preparation is required to locate and traverse these canals.

A modified triangular-shaped access chamber with two palatal orifices can aid in appropriately viewing and accessing the canals. <sup>(8)</sup>

Magnification devices, such as dental operating microscopes, considerably improve the clinician's ability to locate and navigate these canals.

NiTi rotary files have proven to be effective in shaping complex root canal systems, including molars with two palatal canals. However, given the variability in canal anatomy, hand instrumentation is also required to achieve the desired results.<sup>(9)</sup>

The use of chelating agents, such as EDTA, along with effective irrigation protocols, can aid in disinfecting and removing debris from these complex canals.

## **CONCLUSION**

Accurate diagnosis, appropriate access cavity design, effective cleaning and shaping, and meticulous obturation techniques are essential for the long-term success of endodontic therapy in complex clinical conditions.

Implementing modern diagnostic aids, advanced instrumentation techniques, and magnification can improve the clinicians' ability to manage these complex anatomical variations successfully.

### **ACKNOWLEDGMENT**

I would like to thank my guide and my head of the department for guiding and supporting me throughout the procedure and I would also like to thank department of oral medicine and radiology for helping me with the cbct scans.

### **CONFLICT OF INTEREST**

No conflict of interest

### **AUTHORS CONTRIBUTION**

Author A had done the case, author b and author c had extended guidance throughout the case and helped in writing the paper.

#### **Ethical Approval:**

**As per international standard or university standards written ethical approval has been collected and preserved by the author(s).**

#### **Consent**

**As per international standards or university standards, patient(s) written consent has been collected and preserved by the author(s).**

### **REFERENCES**

1. Sahib AM, Ghabraei S. Endodontic Management of a Maxillary First Molar with Taurodontia and Two Palatal Canals: A Case Report. *Iran Endod J.* 2021;16(2):114-117
2. Chen K, Ran X, Wang Y. Endodontic treatment of the maxillary first molar with palatal canal variations: A case report and review of literature. *World J Clin Cases.* 2022 Nov 16;10(32):12036-12044.
3. Schryvers A, Govaerts D, Politis C, Lambrechts P. Endodontic management of a maxillary first molar with two palatal roots: A case report. *AustEndod J.* 2019 Dec;45(3):420-425
4. Sriganesh A, SaravanaPriyan G L. Endodontic management of maxillary first molar with an anatomical variation of two palatal canals: A case report. *Indian J Dent Res* 2019;30:478-480.
5. Vertucci FJ. Root canal anatomy of the human permanent teeth. *Oral Surg Oral Med Oral Pathol.* 1984;58(5):589-599.
6. Khan S, Yousuf W, Ahmed N. Endodontic management of maxillary first molar with two palatal canals. *Case Rep Dent.* 2015;2015:580-594.

7. Patel S, Dawood A, Ford TP, Whaites E. The potential applications of cone beam computed tomography in the management of endodontic problems. *IntEndod J.* 2007;40(10):818-830.
8. Plotino G, Grande NM, Isufi A, et al. Prevalence and characteristics of 2-rooted maxillary canines by cone-beam computed tomography analysis. *J Endod.* 2019;45(5):530-537.
9. Karapinar-Kazandag M, Tanalp J. A new method for locating the second palatal canal in maxillary first molars: Preliminary report. *AustEndod J.* 2019;45(2):154-159.

