

A case report on beaded jejunum in a post kidney transplant recipient

Abstract

A 39 year old male with a history of left donor kidney transplant (donor - mother, underwent transplant in 2014) in view of Chronic Kidney Disease since 2009, presented with complaints of Malena and burning type of abdominal pain in the upper abdominal region for 10 days. He has a history of loss of appetite with weight loss of around 2 kgs over the past 2 months. Ultrasonography was suggestive of colonic wall thickening, Computer Tomography was likely suggestive of tuberculosis and no significant findings in upper OesophagoGastroDuodenoscopy (OGD Scopy) and colonoscopy. Diagnostic laparoscopy was performed to find beaded appearance of proximal jejunum

Keywords: Malena, beaded jejunum, post kidney transplant, post transplant lymphoproliferative disorder, EBV associated non Hodgkin lymphoma

Introduction

“The gold standard treatment in patients affected by end-stage renal disease is kidney transplantation as it significantly improves the quality of life and patient survival compared to dialysis” [1]. “The success of a kidney transplant is related to the prevention of acute rejection, and newer immunosuppressive therapy provides a

significant improvement in transplant outcomes. However, chronic immunosuppression may increase the risk of various complications, including chronic allograft nephropathy and post-transplant infections and cancers”. [2, 3]

“Kidney transplant recipients are at increased risk of gastrointestinal complications, which represent a major cause of morbidity and mortality after transplantation” [2,3]. “They have a wide clinical spectrum, varying from diarrhoea to post-transplant inflammatory bowel disease (IBD)”. [2,3] Hence diagnosis becomes challenging in post kidney transplant patients with vague presenting symptoms. Here’s a case report of a 39 year old, post kidney transplant male who presented to us with abdominal pain, malena and weight loss.

Case Report

A 39 year old male , case of left donor kidney transplant (donor - mother, underwent transplant in 2014) in view of Chronic Kidney Disease since 2009.He was on Tacrolimus , Azathioprine and Prednisolone post renal transplant. After kidney transplant, the patient manifested recurrent urinary tract infections (UTIs) requiring intravenous antibiotic therapy twice for which he was admitted. He has been on regular medication post transplant. He has received blood transfusion in view of low hemoglobin levels three months ago in may 2023.

Currently he presented with complaints of Malena and burning type of abdominal pain in the upper abdominal region for 10 days.He has a history of loss of appetite with weight loss of around 2 kgs over

the past 2 months . There is no history of fever, nausea or urinary complaints. His bladder and bowel habits were normal.

On Examination

Patient is averagely built, afebrile with stable vitals. On per abdominal examination he has a scaphoid abdomen, and on palpation is soft with tenderness in the left hypochondriac and epigastric regions; bowel sounds present. Per rectal examination has no significant findings. Scar of previous transplant surgery is noted.

Investigations

Ultrasonography suggestive of Diffuse colonic wall thickening is seen involving splenic flexure and descending colon measuring 10-11 mm with few enlarged hypoechoic vascular lymph node masses

noted at left paraaortic, paracolic region

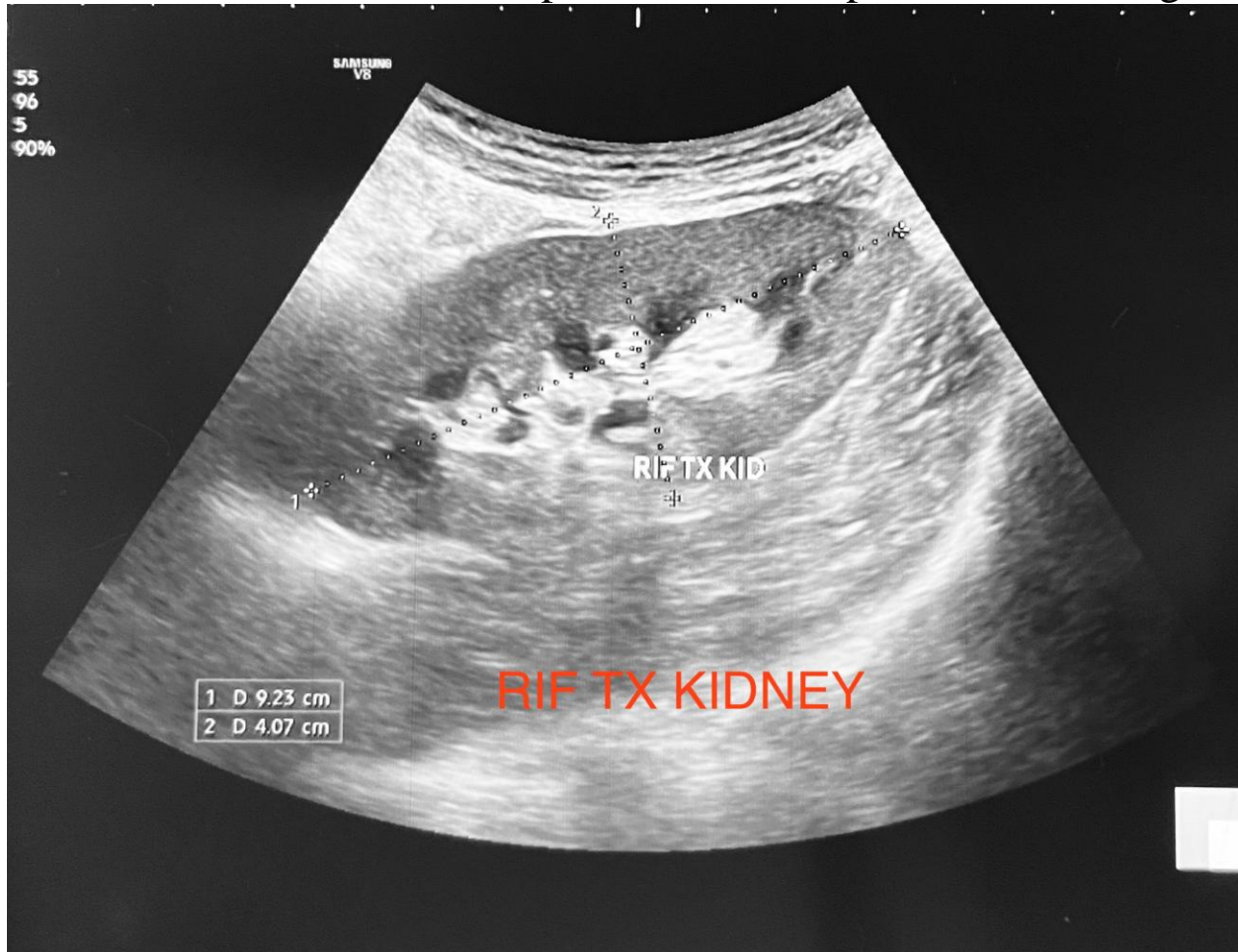


Fig 1 :- USG showing Transplanted Kidney in RIF.

Computer Tomography scan was suggestive Multiple segments of concentric mural thickening with maximum wall thickness measuring about 1.7 cm., involving the jejunum most marked in the left lumbar region with perilesional lymphadenopathy which could

be suggestive of an infective process like tuberculosis.

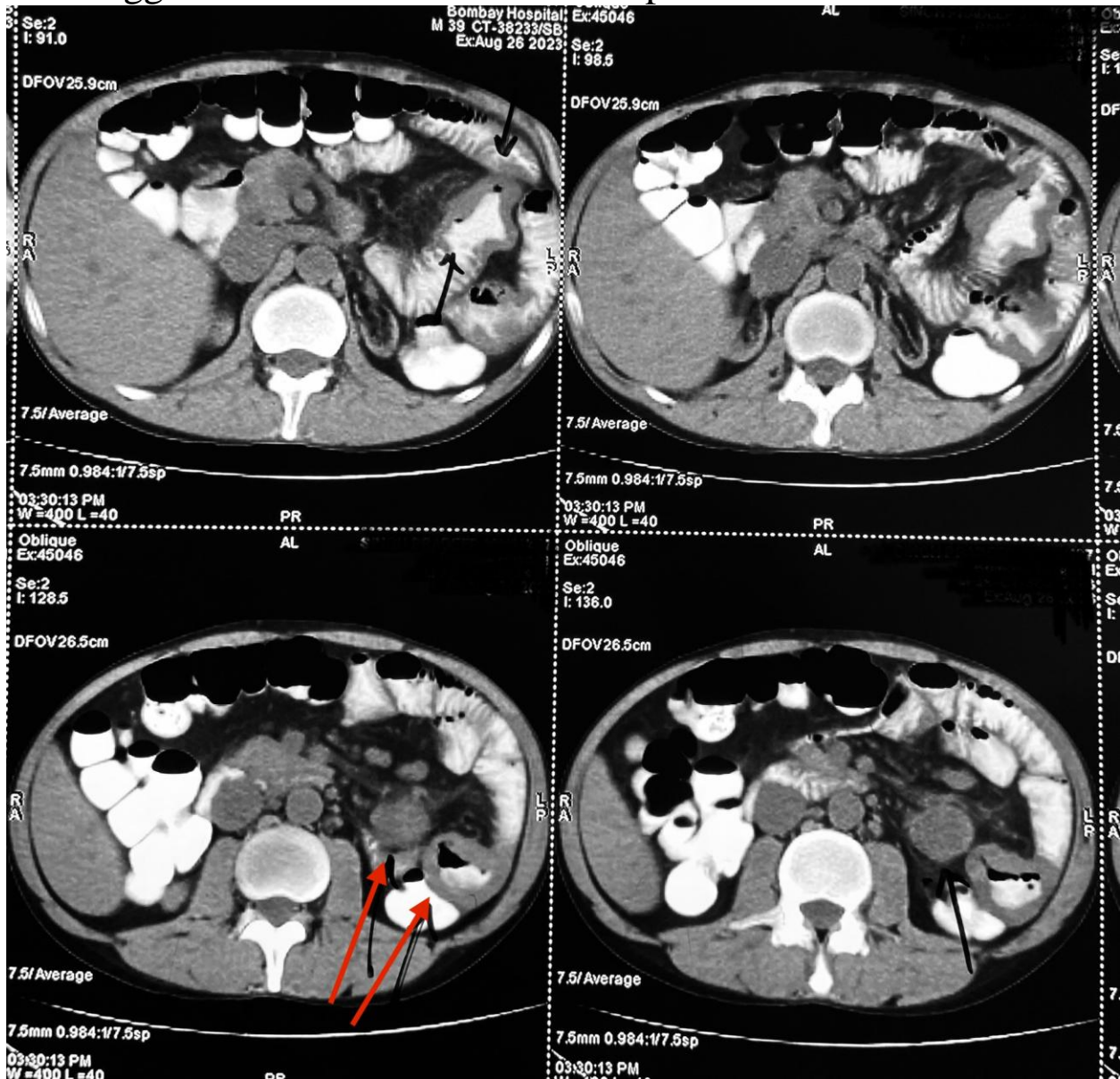


Fig 2:- CT scan showing concentric mural thickening in jejunum.

Transplanted kidney noted in right iliac fossa with few cortical cysts

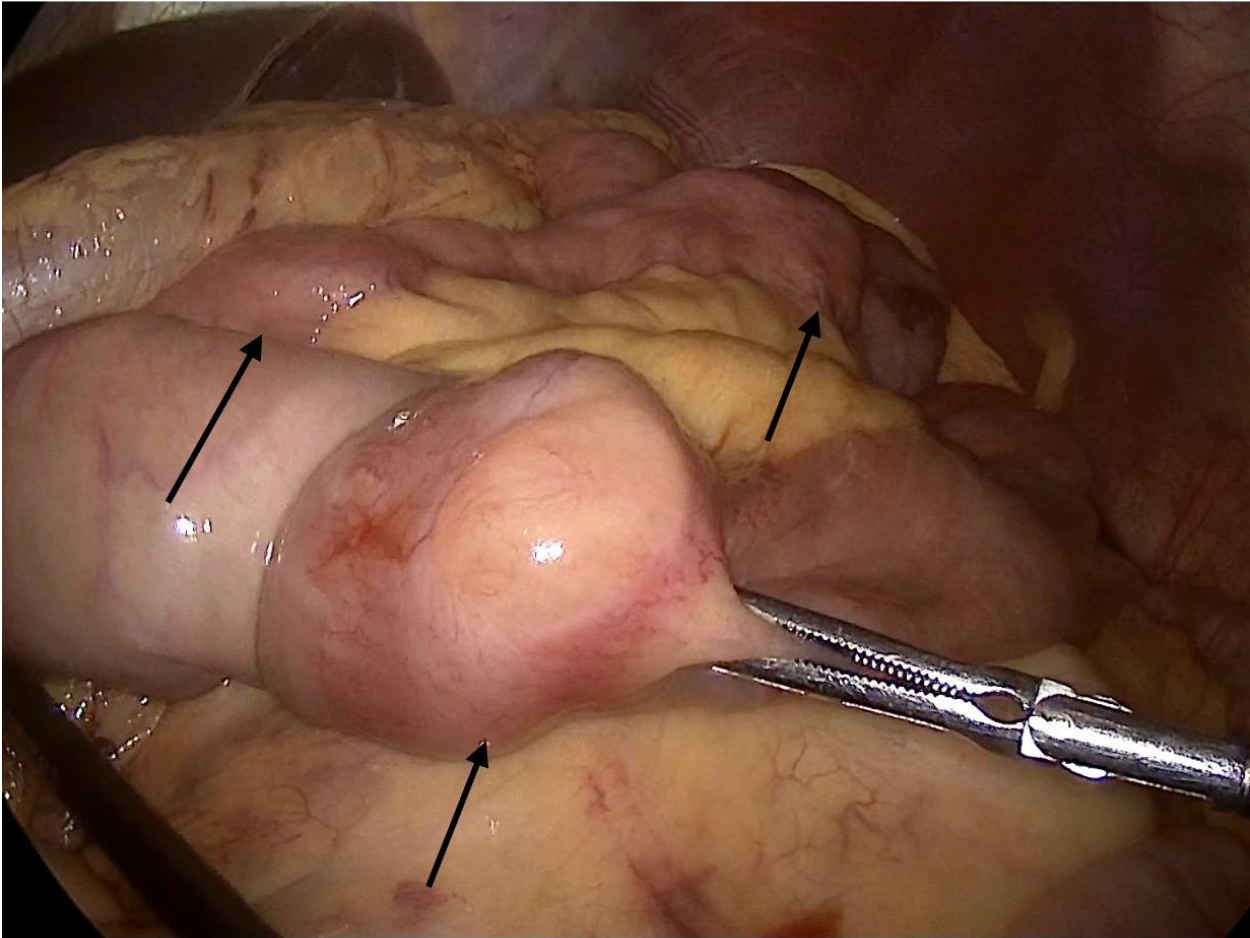
Upper GI scopy and colonoscopy showed no abnormalities

Complete Blood Count reported hemoglobin levels of 10 g/dl, White Blood Cell count of 4500 WBCs per micro liter and Platelet count of 2.1 billion/liter.

Serum Creatinine levels were 1.1 mg/dl.

Surgery

A diagnostic laparoscopy was performed, which revealed irregularly thickened multiple beaded appearance of the proximal jejunum with omental adhesions over it



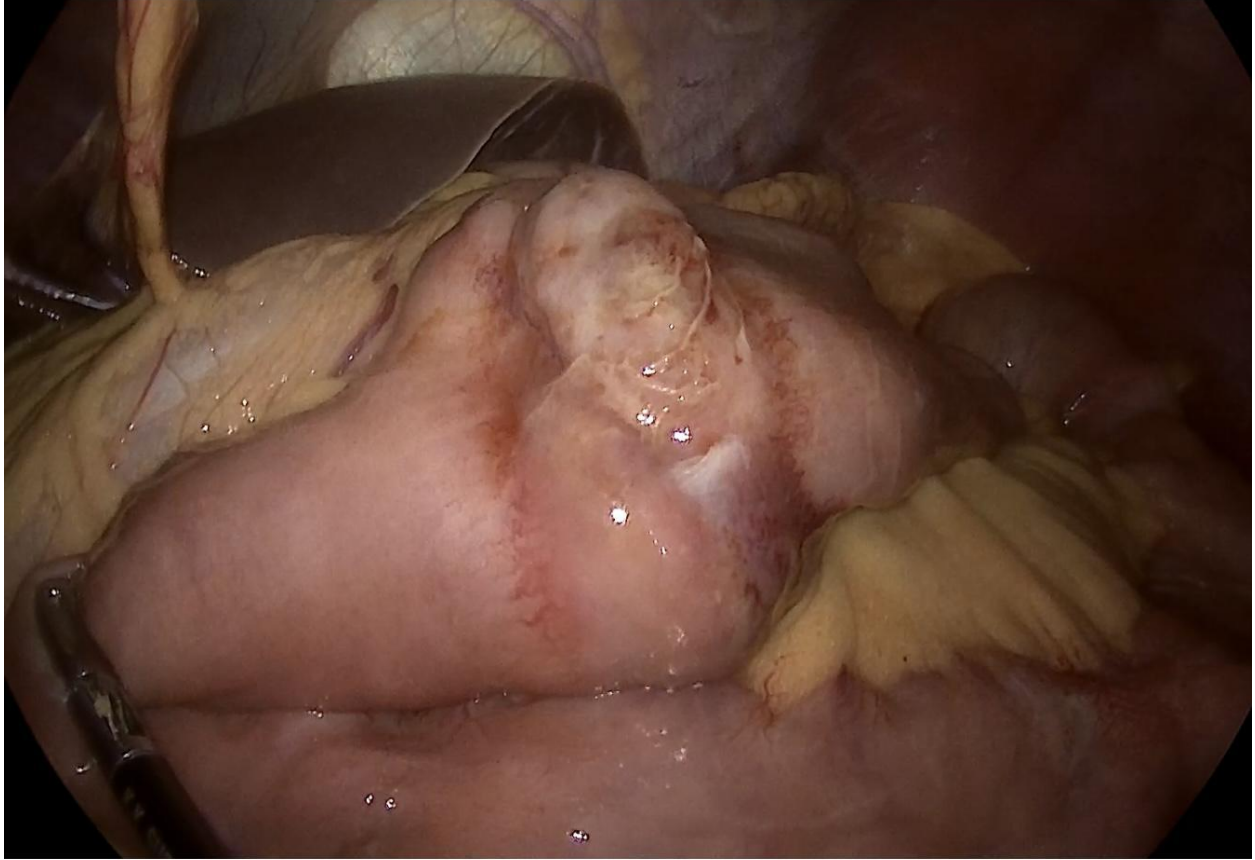


Fig 3 and 4 :- Laproscopic view showing beaded proximal jejunum.

A large necrotic mesenteric lymph node was noted , biopsy taken and sent for histopathology

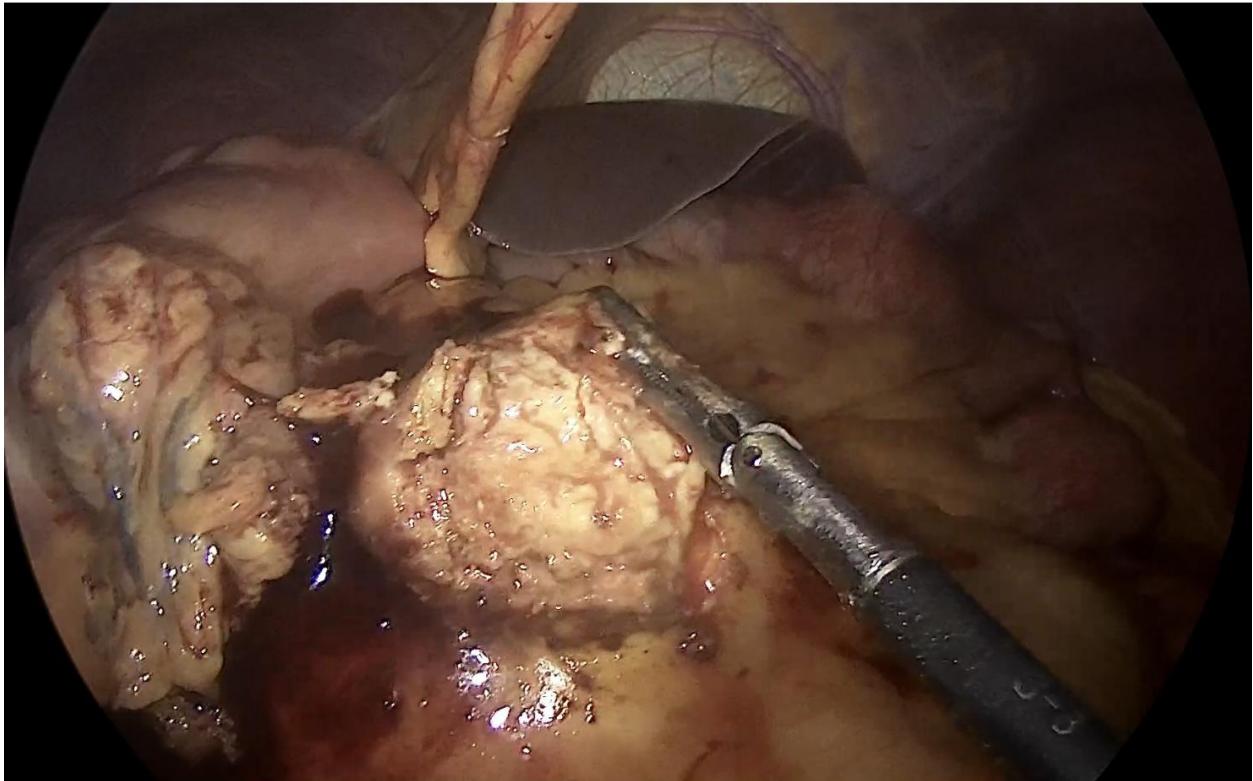


Fig 5:- Laproscopicview showing necrotic mesenteric LN.

A surgical challenge was to decide if resection anastomosis of the entire beaded segment of jejunum was necessary. With the differential diagnosis of intestinal tuberculosis and post transplantlymphoproliferative disorder and it's implications of risk of anastomotic leak, decision was taken to await for hpe report of mesenteric lymph node

Histopathology Examination (HPE)

HPE report of Mesenteric lymph node was suggestive of Post transplant EB associated 'B' cell non-Hodgkin lymphoma.

The tumor cells express CD30, Pax5, CD20 (weak), OCT2, Bob1, MUM1, CD19 & CD79a.

They do not express cytokeratin.

In situ hybridization for EBV RNA is positive.

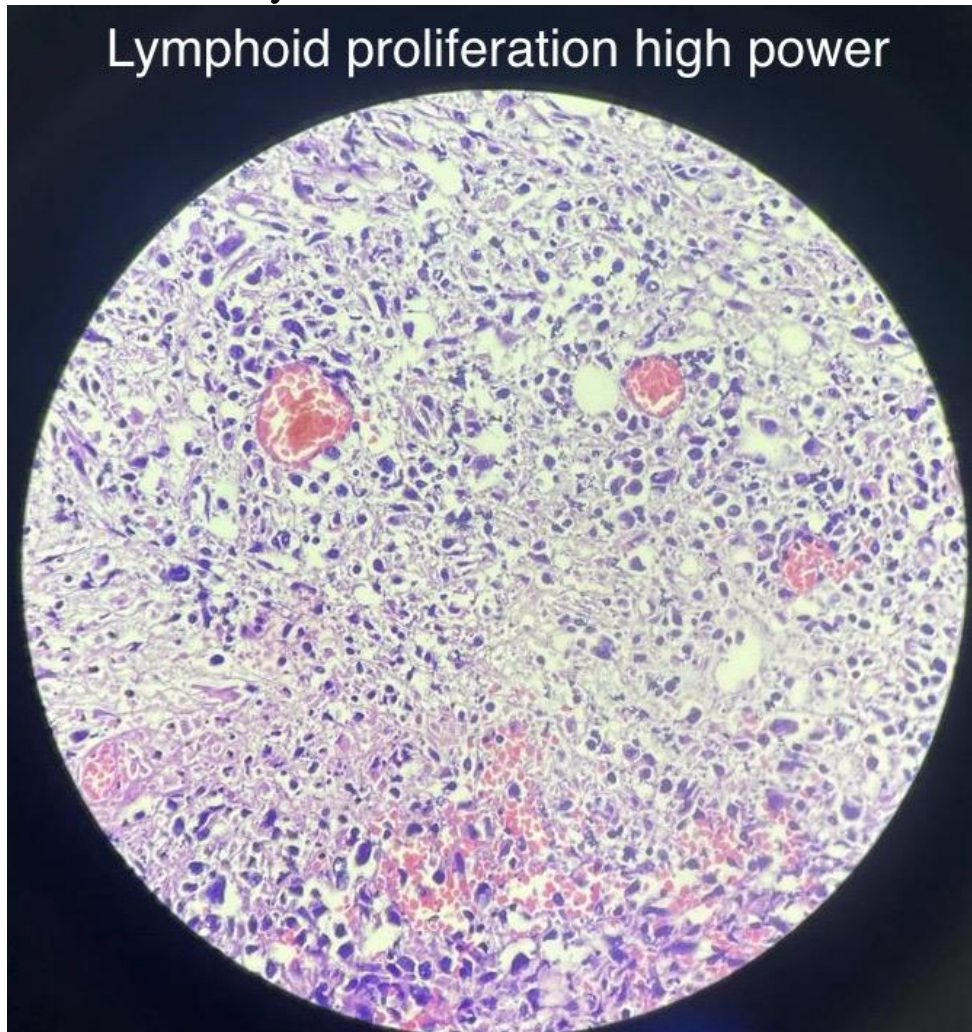


Fig 6:- HPE slide showing lymphoid proliferation in mesenteric LN.

Discussion

“Post transplant lymphoproliferative disorder (PTLD) is a spectrum of major, life-threatening lymphoproliferative diseases occurring in

the post transplant setting. The majority of PTLD is of B-cell origin and is associated with several risk factors, the most significant being EBV infection. The term EBV-associated PTLD includes all clinical syndromes of EBV-associated lymphoproliferation, ranging from uncomplicated post transplant infectious mononucleosis to true malignancies that contain Clonal chromosomal abnormalities”.[4,5]

“PTLD is most often seen after heart-lung transplant the incidence of which is 5%-10%; The incidence is less often seen after kidney transplant 0.3-3% [6,7,8].Opelz and Dohler reported a 0.3% incidence after 1 year and a 1.6% incidence after 10 years”[9].In our patient the incidence was noted 9 years after the transplant.

“The incidence of PTLD reaches 1–2% in kidney recipients, up to 20-fold higher than in the non-transplanted population” [10,11].

“There is a bimodal distribution of timing of occurrence after transplantation, with a peak of Cases occurring in the first 2 years and a second peak Occurring between 5 and 10 years after transplantation. However, the incidence of non-EBV-positive PTLD remains far higher than the incidence of lymphoma in non-immunocompromised subjects. In our patient PTLD occurred around a decade after renal transplantation”. [20]

“It is now generally believed that PTLD and malignant lymphomas are an inevitable consequence of effective immunosuppressive therapy regardless of the particular immunosuppressive agents used. The effect of EBV infection, whether as a primary event or as a reactivation of a previous infection, is thought to be mediated by B-lymphocyte proliferation secondary to inhibition of the T-cell-dominated immune responses produced by powerful immunosuppression”[12]. “Our patient was on regular Immunosuppressive medication with Tacrolimus, Azathioprine and Prednisolone. The stronger the immunosuppression and the higher

its cumulative dose, the greater risk the patient has of developing lymphoproliferative disorders”[13].

“EBV is ubiquitous, with 95% of the adult population in most countries having serological evidence of prior exposure. The possibility of reactivation is high if immunosuppression is excessive. In children who undergo transplantation, approximately 50% are likely to be EBV-negative at the time, resulting in susceptibility to primary infection from a virus-positive graft or blood transfusion”[14].

“EBV is a DNA virus which belongs to the gamma herpes family. Normally individuals are immunocompetent and acquire subclinical infection at some point prior to adulthood. The virus has a longstanding latency period in reticuloendothelial cells, and remains dormant. An important reservoir for EBV are the B lymphocytes. The pathophysiology suggests, the virus will insert its own genome into the B cell and this causes uncontrolled B cell proliferation. However, in individuals who are immunocompetent, they can keep the infected B cells in check through EBV-specific CD8+ cytotoxic T lymphocytes (CTLs). In case of transplant recipients, like in our patient, they receive immunosuppression to prevent rejection, an important consequence of such non-specific immunosuppression is the inhibition of the EBV-specific CTLs. Thus, in such case scenarios, EBV-infected B cells may proliferate unchecked. This proliferation is particularly marked when the transplant recipient is EBV seronegative and acquires a primary infection when immunosuppressed” [15,16,17]. Tissue diagnosis (histopathology) is crucial for PTLN diagnosis, along with a clear evidence of EBV DNA, RNA, or protein material.

“The treatment of PTLN is an evolving area and management varies significantly according to

the type of lymphoproliferative disease present. In general, reduction of immunosuppression on diagnosis is instituted, but the optimal immunosuppression reduction to ensure regression of disease is unknown, and decisions are usually based on the severity of the disease in combination with the health risk associated with possible loss of the allograft. Although there is currently no evidence of the efficacy of antiviral therapy for treatment of PTLD, antiviral agents such as ganciclovir are commonly used for EBV-associated PTLD. Patients with monoclonal malignancies can be treated with chemotherapy, commonly CHOP (cyclophosphamide, doxorubicin, vincristine, prednisolone). For patients who have PTLD that expresses CD20, chemotherapy is usually administered in conjunction with rituximab". [20] "Treatment involves mainly immunosuppression reduction among other measures, however, mortality rate remains ~40% in kidney recipients" [18]. A combination of various therapeutic options like surgical clearance, anti-viral agents, local radiotherapy, intravenous immunoglobulin (IVIG), chemotherapeutic agents, monoclonal antibodies and cytotoxic T lymphocytes are used with variable success rather than a single therapy.

On confirmation of diagnosis, treatment was started with a 1100mg dose of Rituximab which was given one dose per week for 3 weeks. During the course of treatment with Rituximab the patient developed a fever. Symptomatic treatment was given until the fever subsided and then Rituximab was restarted and given once every three weeks for a total period of 6 months.

“In immunocompetent EBV-infected individuals, the virus is latent in cells of the reticuloendothelial system. Transplant immunosuppression may allow activation, proliferation and spread of the virus among B lymphocytes increasing the chance of developing PTLD. By contrast, primary EBV infection after a solid organ transplant is likely to result in higher viral loads when compared to EBV reactivation and an increased chance of developing PTLD”[19]

“Seronegative recipients who receive a seronegative organ may remain uninfected but may be infected post-transplant”.[19]

Conflict of interest

None

Conclusion

PTLD may have a different clinical course varying from symptomless lesions to fulminating disease with multi-organ failure and hence should be considered in the differential diagnosis of patients after organ transplant

Ethical Approval:

As per international standard or university standards written ethical approval has been collected and preserved by the author(s).

Consent

As per international standards or university standards, patient(s) written consent has been collected and preserved by the author(s).

References

1. Veroux M, Corona D, Veroux P. Kidney transplantation: future challenges. *Minerva Chir.* 2009;64:75–100.
2. Pittman ME, Jessurun J, Yantiss RK. Differentiating Post Transplant Inflammatory Bowel Disease and Other Colitides in Renal Transplant Patients. *Am J SurgPathol.* 2017;41:1666–1674.
3. de Andrade LG, Rodrigues MA, Romeiro FG, Garcia PD, Contti MM, de Carvalho MF. Clinicopathologic features and outcome of mycophenolate-induced colitis in renal transplant recipients. *Clin Transplant.* 2014;28:1244–1248.
4. Nourse JP, Jones K, Gandhi MK. Epstein-Barr virus-related post-transplant lymphoproliferative disorders: pathogenetic insights for targeted therapy. *Am J Transplant* 2011;11:888.
5. Preiksaitis JK, Keay S. Diagnosis and management of posttransplant lymphoproliferative disorder in solid-organ transplant recipients. *Clin Infect Dis* 2001;33(Suppl. 1): S38.
6. Caillard S, Dharnidharka V, Agodoa L, Bohlen E, Abbott K. Posttransplant lymphoproliferative disorders after renal transplantation in the United States in era of modern immunosuppression. *Transplantation* 2005;80:1233e43
7. Lewin KJ. Post-transplant lymphoproliferative disorders. *PatholOncol Res* 1997;3:177e82.
8. Wasson S, Zafar MN, Best J, Reddy HK. Post-transplantation lymphoproliferative disorder in heart and kidney transplant patients: a single-center experience. *J CardiovascPharmacolTher* 2006;11:77e83.
9. Opelz G, Dohler B. Lymphomas after solid organ transplantation: A collaborative transplant study report. *Am J Transplant* 2004; 4: 222–230.
10. Trofe J, Buell JF, Beebe TM et al. Analysis of factors that influence survival with post-transplant lymphoproliferative disorder in renal transplant recipients: the Israel Penn International Transplant Tumor Registry experience. *Am J Transplant* 2005; 5(4 Pt 1): 775–780.

11. Parker A, Bowles K, Bradley JA et al. Diagnosis of post-transplant lymphoproliferative disorder in solid organ transplant recipients - BCSH and BTS Guidelines. *Br J Haematol* 2010; 149: 675–692.
12. Hanto DW, Frizzera G, Gajl-Peczalska KJ, et al. The Epstein-Barr virus (EBV) in the pathogenesis of posttransplant lymphoma. *Transplant Proc* 1981;13:756.
13. Dharnidharka, V.R., Araya, C.E. Post-transplant lymphoproliferative disease. *PediatrNephrol* 24, 731–736 (2009).
14. Johnson LR, Nalesnik MA, Swerdlow SH. Impact of Epstein-Barr virus in monomorphic B cell posttransplantlymphoproliferative disorders: a histogenetic study. *Am J SurgPathol*. 2006;30(12):1604–1612.
15. Green M, Webber S (2003) Posttransplantationlymphoproliferative disorders. *PediatrClin North Am* 50(6):1471–1491
16. LaCasce AS (2006) Post-transplant lymphoproliferative disorders. *Oncologist* 11(6):674–680
17. Gottschalk S, Rooney CM, Heslop HE (2005) Post-transplant lymphoproliferative disorders. *Annu Rev Med* 56:29–44
18. Trofe J, Buell JF, Beebe TM et al. Analysis of factors that influence survival with post-transplant lymphoproliferative disorder in renal transplant recipients: the Israel Penn International Transplant Tumor Registry experience. *Am J Transplant* 2005; 5(4 Pt 1): 775–780.
19. Allen U, Preiksaitis J. Epstein-barr virus and posttransplant lympho- proliferative disorder in solid organ transplant recipients. *Am J Transplant* 2009; 9 (Suppl 4): S87–S96.
20. Thompson JF, Webster AC. Cancer in Dialysis and Kidney Transplant Patients. In *Kidney Transplantation–Principles and Practice* 2014 Jan 1 (pp. 569-583). WB Saunders.