

Metastatic adenocarcinoma of the rectum revealed by bilateral occlusion of the central retinal vein: A case report

ABSTRACT

Central retinal vein occlusion (CRVO) is caused by the formation of a thrombus in the central retinal vein, and constitutes an extreme diagnostic and therapeutic emergency, as it is visually life-threatening. The most frequent cause of CRVO is related to cardiovascular risk factors, although neoplasia is a very rare cause of CRVO. A few cases of CRVO secondary to cancer have been reported in the literature, the imputability of malignant pathology may be explained by the systemic procoagulant state observed during the latter.

We report the case of a patient who suddenly presented with CRVO and whose etiological work-up was in favor of metastatic rectal adenocarcinoma. This original observation underlines the importance of an exhaustive work-up in the case of bilateral CRVO.

keywords:

Central retinal vein occlusion, thromboembolic disease, rectal cancer

Abbreviations :

Central retinal vein occlusion (CRVO)

1. INTRODUCTION

Central retinal vein occlusion (CRVO) is the second most common cause of ocular vascular disease after diabetic retinopathy, and is often secondary to classic thromboembolic risk factors (2). The association of cancer and CRVO is a very rare situation, hence the originality of our observation.

We report the case of a patient with a metastatic rectal malignancy revealed by bilateral CRVO.

2. CASE PRESENTATION

The patient was 54 years old, male, with no particular pathological history, notably no diabetes, hypertension or atherosclerosis, who suddenly presented with a profound bilateral decrease in visual acuity. Ophthalmological examination revealed near-finger-count visual acuity in both eyes, with no abnormalities in the anterior and intermediate segments. Fundus and retinal angiography (Fig. 1 and Fig. 2) showed bilateral CRVO with stage 2 papilledema, retinal hemorrhages in the form of flares and a few areas of retinal ischemia. The etiological assessment of this CRVO showed no cardiovascular cause and no signs of acquired or constitutional thrombophilia. Therapeutic measures included laser photocoagulation to destroy areas of retinal ischemia.

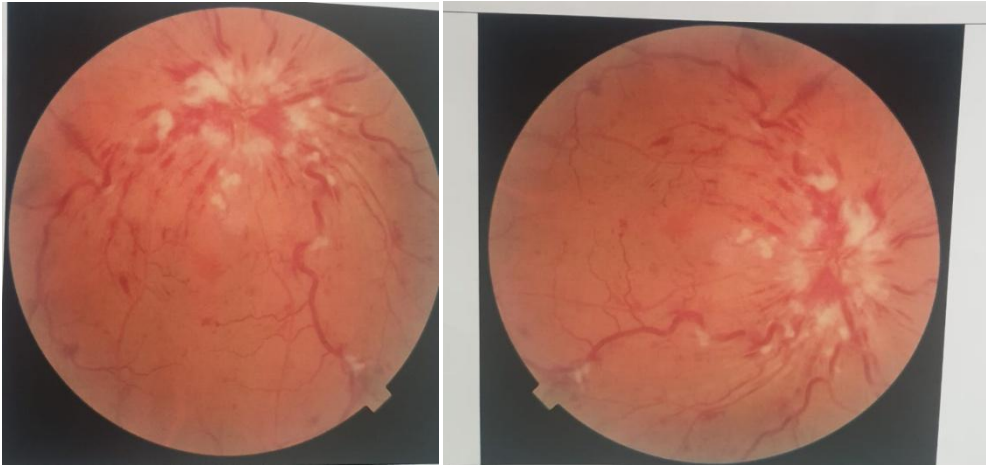


Fig 1 et Fig2: bilateral retinal angiography demonstrating bilateral CRVO with stage 2 papilledema and flame-shaped hemorrhages

A review of the patient's history revealed intermittent abdominal pain associated with episodes of low-grade rectal discharge and profound changes in general condition. Abdominal-pelvic CT (Fig 3) showed a circumferential, irregular, stenosing rectal digestive parietal thickening, complemented by abdominal-pelvic MRI (Fig 4 and Fig 5), which showed a locally advanced tumoral process of the middle and upper rectum with sacral involvement, associated with deep abdominal and pelvic adenopathies and secondary liver lesions. Colonoscopy with biopsy confirmed the diagnosis of a rectal adenocarcinoma.

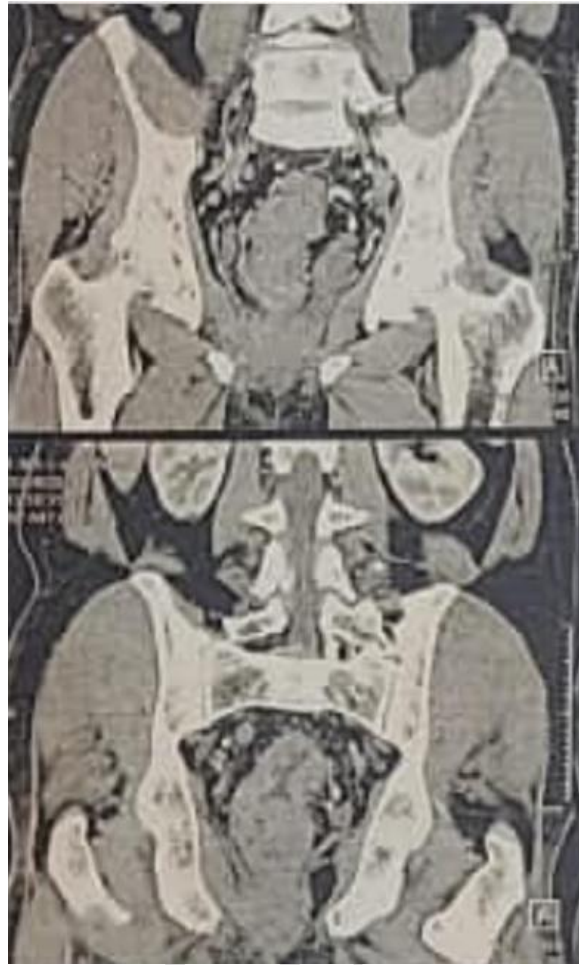

Fig 3 : Coronal section CT scan showing circumferential, irregular, stenosing rectal parietal thickening

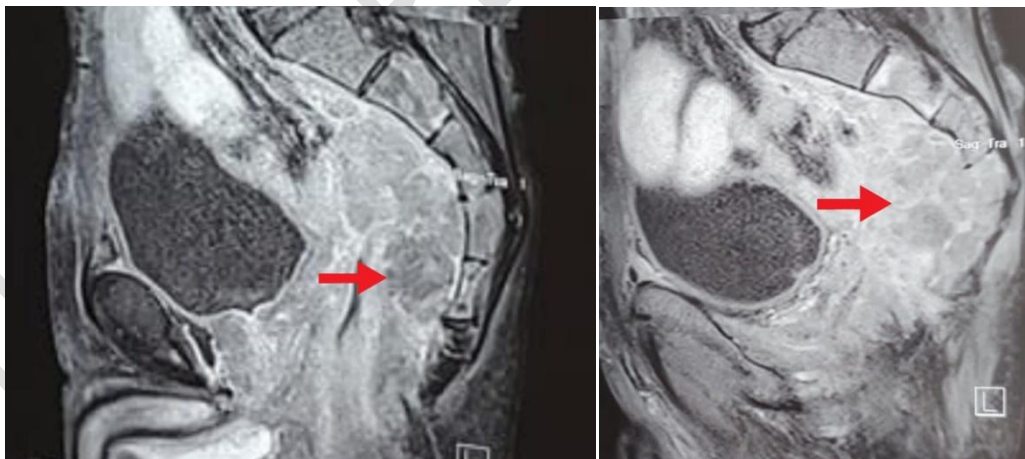


Fig 4 et Fig5 : Sagittal-section MRI of the middle and upper rectum reveals an endo- and exophytic tissue process with heterogeneous T2 hypersignals, extending to the sigmoid loop, presacral space and sacrum.

In all, the diagnosis of CRVO of neoplastic origin was retained. Therapeutically, the patient was referred to surgeons and oncologists for appropriate management.

3. DISCUSSION

CRVO corresponds to the formation of a thrombus in the central retinal vein, and is a serious accident involving immediate visual prognosis due to macular damage or complications (1). It is the second most common cause of retinal vascular disease after diabetic retinopathy, with rates ranging from 0.3% to 1.6% according to six epidemiological studies (2).

The classic risk factors for CRVO are multiple, including advanced age, hypertension, diabetes, sleep apnea syndrome, plasma hyperhomocysteinemia, ocular hypertension, thrombophilia, blood hyperviscosity, and a few cases of familial CRVO have been reported, suggesting the imputability of genetic anticipation phenomena (3). Bilateral CRVO is rare, and should prompt the clinician to carry out an exhaustive work-up in search of a general disease, notably an underlying cancer (4).

The association of CRVO with neoplasia is rare, with only a handful of cases reported in the literature, in particular haematological malignancies complicated by CRVO, although the rate of solid cancers associated with retinal vascular involvement is rarer (5). Cases of CRVO associated with malignant tumors of the breast, lung, prostate, rectum, ovary and brain have been described (1-5-10-11). This association may be explained by shared pathophysiological mechanisms between thromboembolic disease and carcinogenesis, and several hypotheses have been suggested to clarify the cause-and-effect relationship between the two pathologies. The hypothesized mechanisms involve direct neoplastic infiltration leading to impaired drainage and retinal vein obstruction, as well as cancer-induced dehydration and hyperviscosity (6-7), all of which contribute to the formation of a systemic pro-coagulant state that increases the risk of venous thromboembolism (8-9).

Our patient had no cardiovascular risk factors that might explain the central retinal vein thrombosis, but coagulation abnormalities caused by rectal adenocarcinoma may be responsible for the CRVO observed in our case report.

4. CONCLUSION

In this case report, we illustrated the various pathophysiological mechanisms responsible for CRVO in patients with cancer.

CONSENT

As per international standard or university standard, patient(s) written consent has been collected and preserved by the author(s).

ETHICAL APPROVAL

As per international standard or university standard written ethical approval has been collected and preserved by the author(s).

REFERENCES

1. A. Rhizlane, Occlusion bilatérale de la veine centrale de la rétine comme première manifestation d'un cancer de poumon, *Journal français d'ophtalmologie* (2020) 43, 805—808
2. Wong TY, Larsen EKM, Klein R, et al. Cardiovascular risk factors for retinal vein occlusion and arteriolar emboli: the Atherosclerosis Risk in Communities & Cardiovascular Health Studies. *Ophthalmology* 2005 ; 112 : 540-7
3. Catherine creuzot-Garcher , Pascale Massin. Rapport SFO 2016 ; œdème maculaire des occlusions veineuses.
4. Klein R, Moss SE, Meuer SM et al. L'incidence cumulée sur 15 ans de l'occlusion de la veine rétinienne : l'étude sur les yeux de Beaver Dam . *Arch Ophthalmol* 2008 ; 126 : 513–18. 10.1001/archophth.126.4.513
5. Ozkaya A, Ozkaya HM, Alkin Z et al. Incidental 'early' diagnosis of colorectal carcinoma by way of central retinal vein occlusion. *J Fr Ophthalmol* 2014 ; 37 :e73–4. 10.1016/j.jfo.2013.06.010
6. Jaulim A, Ahmed B, Khanam T, Chatziralli IP. Branch retinal vein occlusion: epidemiology, pathogenesis, risk factors, clinical features, diagnosis, and complications
7. Oisseiev E, Ling J, Morse LS. Leukemic optic nerve infiltration complicated by retinal artery and vein occlusions. *Retina*. 2017;37(2):e10.
8. Lip GY, Chin BS, Blann AD. Cancer and the prothrombotic state. *Lancet Oncol*. 2002;3(1):27-34.
9. Caine GJ, Stonelake PS, Lip GY, Kehoe ST. The hypercoagulable state of malignancy: pathogenesis and current debate. *Neoplasia*. 2002;4(6):465-473.
10. Szczepanik S, Kęćik D. Bilateral central retinal vein occlusion in a patient with disseminated metastatic renal cell carcinoma treated with sorafenib. *Retin Cases Brief Rep* 2012;6:148–50. 10.1097/ICB.0b013e3182160965.
11. Veronica Castro-Navarro. Bilateral BRVO in a patient with recurrent prostate cancer. *BMJ Case Reports*. 2015: bcr2015212463.