

Heart and Brain Crisis: The Unseen Drama of Acute Cardio-cerebral Infarction Type 1

Abstract:

Background

Cardio-cerebral infarction (CCI) type 1 is a rare condition where acute myocardial infarction (AMI) and acute ischemic stroke (AIS) occur at the same time. The optimal method for diagnosing and treating AMI in patients with AIS remains uncertain. This publication aims to delineate the obstacles associated with the treatment of CCI.

Case Illustration

A 69-year-old man with the risk factors hypertension, active smoker, and history of cerebral infarction presented with atypical angina at rest and left hemiparesis. The patient's electrocardiography revealed sinus rhythm and ST elevation with pathological Q wave in the inferoposterior and RV region. The cardiac enzyme level was increased while hs-troponin I was 23.091 ng/L and CKMB was 387 U/L. The Brain CT Scan demonstrated acute infarct at lentiformis nucleus dextra and corona radiata dextra. Patient was decided to get loading dual anti-platelet and anticoagulant and performed Primary PCI after bleeding risk assessment. Coronary angiography showed CAD three-vessel disease and left main coronary artery disease with acute total occlusion at mid-RCA with thrombus appearance. The patient underwent coronary stenting in the proximal-mid RCA using DES Cre8 3.0 x 46 mm. Cineangiography evaluation showed TIMI Flow 3 and no residual stenosis. Patient also was joined care with Neurology department to treat AIS simultaneously. Patient improved and was discharged on the 7th day of hospitalization.

Conclusion

Effectively managing CCI poses a significant challenge for professionals. PCI strategy for AMI as the first strategy due to high mortality remains the preferred choice despite the risk of hemorrhagic transformation in AIS.

Keyword: *cardio-cerebral infarction, acute myocardial infarction, acute ischemic stroke*

1. Introduction

Cardio-cerebral infarction (CCI) type 1, the simultaneous occurrence of acute ischemic stroke (AIS) and acute myocardial infarction (AMI), remain the leading cause of morbidity and mortality worldwide.¹ They both possess shared vascular risk factors that contribute to the development of atherosclerotic disease. The occurrence rate of acute cardio-cerebral infarction is as low as 0.009%.^{2,3} Multiple investigations have found a higher occurrence of ischemic stroke following a prior myocardial infarction, both in the immediate and extended periods.⁴ This particular form of infarction is rare and poses a significant challenge for cardiologists and neurologists. Additionally, it has an elevated risk of mortality for the patient. Both illnesses have a limited range of effective treatment; therefore, prioritizing the immediate therapy of one over the other may lead to a permanent handicap in the affected area due to delayed intervention. Furthermore, the administration of anti-platelet and anticoagulant medications before percutaneous coronary intervention (PCI) in the treatment of AMI may heighten the likelihood of hemorrhagic conversion.⁵ Additionally, the use of a thrombolytic agent in an acute inferior wall myocardial infarction raises the risk of cardiac wall rupture in AMI.⁶

This case report is very important

2. Case Illustration

A 69-year-old male patient with the risk factors hypertension, active smoker, and history of cerebral infarction complained of atypical angina at rest accompanied by nausea, vomiting, and cold sweating for 13 hours prior to admission. He also felt weakness in both his legs, especially the left one. Because of these complaints, his family brought him to the nearest Hospital. **Patient with stable hemodynamics and also there is no sign of congestion.** The doctor in charge performed Brain Computed Tomography (CT) Scan examination and it showed acute infarct at lentiformis nucleus dextra and corona radiata dextra, chronic infarct at caudatus nucleus dextra and sinistra, and senile brain atrophy. The patient then was diagnosed with recurrent cerebral infarction and treated by a neurologist. Then the ECG examination was performed, and it showed ST elevation with pathological Q wave in leads II, III, aVF, V9, and V4R so a neurologist was consulted to a cardiologist for join-care due to inferoposterior STEMI and right ventricle (RV) infarction. **Cardio-cerebral infarction is treated with a multi-disciplinary approach between the cardiologist and neurologist.** Laboratory findings showed hs-troponin I level increased to 23.091 ng/L and CKMB level increased to 387 U/L. For initial treatment, the patient got a loading of dual antiplatelet, and high-intensity statin, and then was transferred to a referral Hospital for further management.

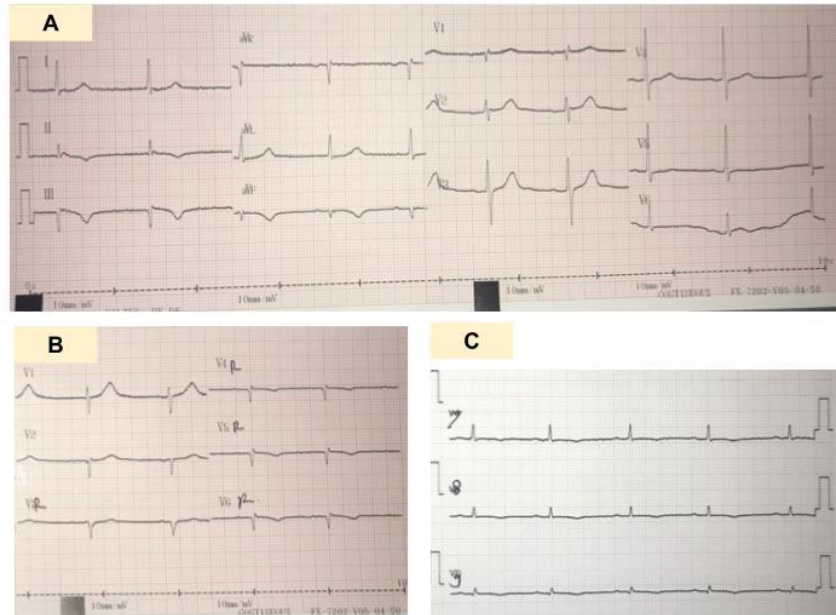


Figure 1. Patient was performed ECG examination. (A) left ECG showed pathological Q wave with ST-segment elevation at lead II, III, aVF. (B) Right ECG showed no ST elevation. (C) Posterior ECG showed pathological Q wave with ST-segment elevation at lead **V9**, V7, V8, V9.

Patient underwent primary percutaneous coronary intervention (PCI) on the first day of treatment. Coronary angiography showed acute total occlusion at mid-RCA with thrombus appearance. Patient also had stenosis 40% at distal left main coronary artery (LMCA) with Medina 1-1-1, diffuse calcified stenosis from ostial to distal left anterior descending (LAD) artery with maximum stenosis 80% at proximal LAD, and diffuse calcified stenosis from ostial to distal left circumflex (LCx) artery with maximum stenosis 90% at distal LCx after OM2 branch. Patient was diagnosed with CAD three-vessel disease with left main coronary artery disease with the culprit lesion at RCA. **The guide wire penetrated the acute total occlusion lesion, it appeared that the flow of the coronary artery was until distal RCA with significant stenosis appearance at proximal RCA.** The patient underwent coronary stenting in the proximal-mid RCA using Drug Eluting Stents (DES) Cre8 3.0 x 46 mm. Cineangiography evaluation showed TIMI Flow 3 and no residual stenosis. The patient remains without any symptoms throughout the procedure and maintains stable vital signs.

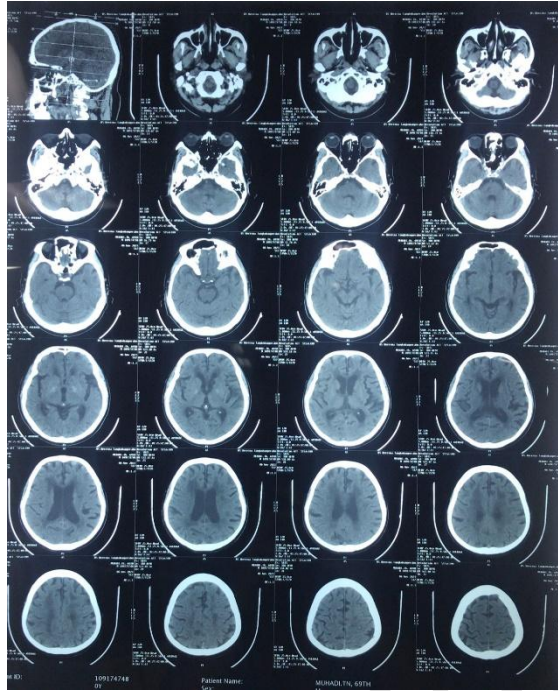


Figure 2. Head CT Scan showed acute infraction at lentiformis nucleus dextra and corona radiata dextra, chronic infraction at caudatus nucleus dextra et sinistra, and senile brain atrophy.

During this interval, the observation indicates that the vital signs are within normal limits. Our assessment utilizing ECG did not indicate any alterations in the anterolateral leads. Patient also was performed echocardiography during hospitalization. Echocardiography showed normal left ventricle (LV) ejection fraction 56% by Biplane, diastolic dysfunction grade 1 without increase of left atrial (LA) pressure, regional wall motion abnormality (RWMA) at LV with hypokinetic at basal-mid inferoseptal and inferior and normokinetic at other segments, and no intracardiac thrombus or vegetation.

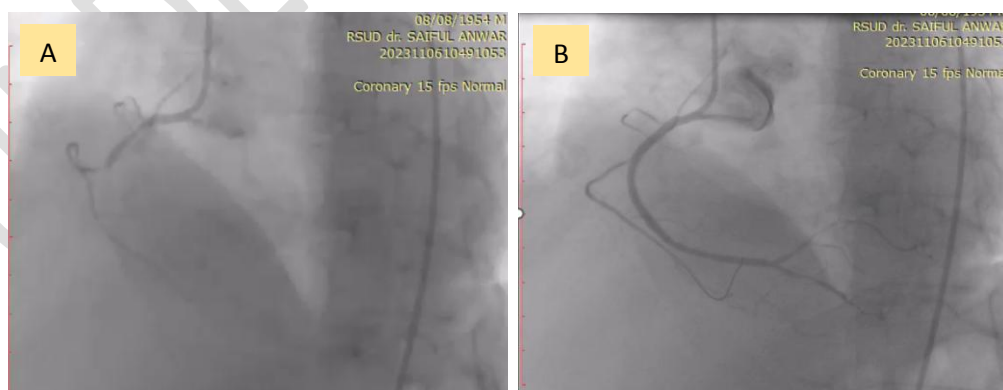


Figure 3. Primary PCI procedure. (A) Diagnostic coronary angiography showed acute total occlusion at mid-RCA. (B) Cineangiography evaluation post stenting using DES Cre8 3.0 x 46 mm at proximal-mid RCA showed TIMI Flow 3 and no residual stenosis.

The patient was discharged from the hospital after 7 days of hospitalization, exhibiting no symptoms of atypical chest pain or shortness of breath, and improved right hemiparesis condition. Patient then continued treatment in clinic with a cardiologist and neurologist.

3. Discussion

A 69-year-old man with the risk factors hypertension, active smoker, and history of cerebral infarction presented with atypical angina at rest and left hemiparesis. The patient's electrocardiography revealed sinus rhythm and ST elevation with pathological Q wave in the inferoposterior and RV region. The cardiac enzyme level was increased while hs-troponin I was 23.091 ng/L and CKMB was 387 U/L. Patient was diagnosed with STEMI in the inferoposterior and RV region and acute cerebral infarction. The Brain CT Scan demonstrated acute ischemic stroke. Patient was diagnosed with CAD three-vessel disease with left main coronary artery disease with the culprit lesion at RCA. Coronary angiography showed acute total occlusion at mid-RCA with thrombus appearance. The patient underwent coronary stenting in the proximal-mid RCA using DES Cre8 3.0 x 46 mm. Cineangiography evaluation showed TIMI Flow 3 and no residual stenosis.

Cardio-cerebral infarction (CCI) type 1 refers to the simultaneous occurrence of Acute ischemic stroke (AIS) and Acute Myocardial Infarction (AMI).³ AIS and AMI that coincide are typically referred to CCI type 1. The incidence of stroke in patients with AMI is markedly elevated as compared to the whole population.⁷ The occurrence of stroke among survivors of AMI can reach approximately 1.2% within one month of observation.^{8,9} The occurrence rate of acute cardio-cerebral infarction is as low as 0.009%.²

The optimal method for diagnosing and treating AMI in patients with AIS remains uncertain.¹⁰ The manifestation of signs and symptoms in patients with AIS may vary due to cognitive, communication, sensory, and perceptual impairments.¹¹ AMI may also be asymptomatic in patients with AIS. Current guidelines advocate for the measurement of troponin in patients with AIS, but the specific diagnostic and therapeutic implications are still unclear.^{12,13} The management of stroke after a myocardial infarction continues to be a difficult task and might result in severe consequences.^{8,14,15} In addition, strokes that occur during the early period after heart attack are linked to higher mortality rates compared to those that occur later.¹

The therapy for a concurrent occurrence of both AIS and AMI is ambiguous.^{12,16} Failure to promptly intervene in one area affected by an infarction in favor of another may lead to long-lasting and irreversible health problems or disability and potentially even death.^{17,18} Both illnesses have a limited therapeutic time frame, meaning that prioritizing the immediate treatment of one ailment over the other could lead to permanent and irreversible handicaps in the affected area that did not receive timely care.⁸

There is a lack of evidence-based guidelines or clinical research on how to handle the simultaneous occurrence of AIS and AMI, particularly in terms of treatment priority.¹⁹ The agents responsible for managing each area can potentially complicate the scope of the other territory affected by an infarction. The use of antiplatelet therapy, GPIIa/IIIb inhibitors, and

anticoagulants in coronary intervention for AMI raise the likelihood of hemorrhagic conversion of AIS associated with thrombolytic treatment.^{20,21} Similarly, the use of a thrombolytic in AIS increases the risk of cardiac wall rupture in the context of AMI. An optimal approach to managing concurrent CCI involves a therapeutic strategy that provides advantages to both vascular regions. Intravenous thrombolysis, authorized for the immediate treatment of both conditions, has been proposed as the optimal approach for managing simultaneous CCI, provided there are no contraindications and both presentations fall within the appropriate time window for thrombolytic administration.^{22,23} However, it is important to note that this approach has not been investigated in clinical trials nor endorsed by any societal guidelines. The management approach faces a problem due to the varying dosage and duration of thrombolytic and anticoagulant medication that is advised for treating acute infarction in these vascular areas.²⁴ PCI strategy for AMI as the first strategy due to high mortality remains the preferred choice despite the risk of hemorrhagic transformation in AIS.

4. Conclusion

Effectively managing CCI poses a significant challenge for professionals. Currently, there are no clinical trials or consensus guidelines available for the simultaneous care of AMI and AIS. It is important to determine the appropriate dosage of intravenous thrombolytic, the ideal period of administration, and the significance of anti-platelet and anti-coagulant medications. PCI strategy for AMI as the first strategy due to high mortality remains the preferred choice despite the risk of hemorrhagic transformation in AIS.

Consent

As per international standards or university standards, patient(s) written consent has been collected and preserved by the author(s).

References

1. Virani SS, Alonso A, Benjamin EJ, Bittencourt MS, Callaway CW, Carson AP, et al. Heart disease and stroke statistics—2020 update a report from the American Heart Association. *Circulation*. 2020;141(9):E139–596.
2. Yeo LLL, Andersson T, Yee KW, Tan BYQ, Paliwal P, Gopinathan A, et al. Synchronous cardiocerebral infarction in the era of endovascular therapy: which to treat first? *J Thromb Thrombolysis*. 2017 Jul 1;44(1):104–11.
3. Podolecki TS, Lenarczyk RK, Kowalczyk JP, Mazurek MH, Świątkowski AM, Chodór PK, et al. The risk of stroke in patients with acute myocardial infarction treated invasively. *Coron Artery Dis*. 2012 Jan;23(1):9–15.
4. Omar HR, Fathy A, Rashad R, Helal E. Concomitant acute right ventricular infarction and ischemic cerebrovascular stroke; Possible explanations. *Int Arch Med*. 2010;3(1).

5. Zinkstok SM, Roos YB. Early administration of aspirin in patients treated with alteplase for acute ischaemic stroke: A randomised controlled trial. *The Lancet*. 2012;380(9843):731–7.
6. Patel MR, Meine TJ, Lindblad L, Griffin J, Granger CB, Becker RC, et al. Cardiac tamponade in the fibrinolytic era: Analysis of >100 000 patients with ST-segment elevation myocardial infarction. *Am Heart J*. 2006 Feb;151(2):316–22.
7. Alqahtani F, Aljohani S, Tarabishy A, Busu T, Adcock A, Alkhouli M. Incidence and outcomes of myocardial infarction in patients admitted with acute ischemic stroke. *Stroke*. 2017 Nov 1;48(11):2931–8.
8. Powers WJ, Rabinstein AA, Ackerson T, Adeoye OM, Bambakidis NC, Becker K, et al. Guidelines for the early management of patients with acute ischemic stroke: 2019 update to the 2018 guidelines for the early management of acute ischemic stroke a guideline for healthcare professionals from the American Heart Association/American Stroke Association. Vol. 50, *Stroke*. Lippincott Williams and Wilkins; 2019. p. E344–418.
9. Dutta M, Hanna E, Das P, Steinhubl SR. Incidence and prevention of ischemic stroke following myocardial infarction: Review of current literature. Vol. 22, *Cerebrovascular Diseases*. 2006. p. 331–9.
10. Kijpaisalratana N, Chutinet A, Suwanwela NC. Hyperacute simultaneous cardiocerebral infarction: Rescuing the brain or the heart first? *Front Neurol*. 2017 Dec 7;8(DEC).
11. Ay H, Koroshetz ; W J, Benner ; T, Vangel ; M G, Melinosky ; C, Arsava ; E M, et al. Neuroanatomic correlates of stroke-related myocardial injury [Internet]. 2006. Available from: www.neurology.org.
12. Nolte CH, Von Rennenberg R, Litmeier S, Scheitz JF, Leistner DM, Blankenberg S, et al. PRediction of acute coronary syndrome in acute ischemic StrokeE (PRAISE)-protocol of a prospective, multicenter trial with central reading and predefined endpoints. *BMC Neurol*. 2020 Aug 27;20(1).
13. Scheitz JF, Nolte CH, Doehner W, Hachinski V, Endres M. Stroke–heart syndrome: clinical presentation and underlying mechanisms. Vol. 17, *The Lancet Neurology*. Lancet Publishing Group; 2018. p. 1109–20.
14. Ibekwe E, Kamdar HA, Strohm T. Cardio-cerebral infarction in left MCA strokes: a case series and literature review. *Neurological Sciences*. 2022 Apr 1;43(4):2413–22.
15. Van E, Oh L, Artin M, Ohn STJ, Utton S, Huan HC, et al. VENTRICULAR DYSFUNCTION AND THE RISK OF STROKE AFTER MYOCARDIAL INFARCTION A BSTRACT. Vol. 336. 1997.
16. Kijpaisalratana N, Chutinet A, Suwanwela NC. Hyperacute simultaneous cardiocerebral infarction: Rescuing the brain or the heart first? *Front Neurol*. 2017 Dec 7;8(DEC).
17. Gungoren F, Besli F, Tanriverdi Z, Kocaturk O. Optimal treatment modality for coexisting acute myocardial infarction and ischemic stroke. *American Journal of Emergency Medicine*. 2019 Apr 1;37(4):795.e1-795.e4.

18. Gungoren F, Besli F, Tanriverdi Z, Kocaturk O. Optimal treatment modality for coexisting acute myocardial infarction and ischemic stroke. *American Journal of Emergency Medicine*. 2019 Apr 1;37(4):795.e1-795.e4.
19. Lee K, Park W, Seo KD, Kim H. Which one to do first?: a case report of simultaneous acute ischemic stroke and myocardial infarction. *Journal of Neurocritical Care*. 2021 Dec 1;14(2):109–12.
20. Ciccone A, Abraha I, Santilli I. Glycoprotein IIb-IIIa inhibitors for acute ischemic stroke. *Vol. 38, Stroke*. 2007. p. 1113–4.
21. Lee M, Saver JL, Hong KS, Rao NM, Wu YL, Ovbiagele B. Risk-Benefit Profile of Long-Term Dual-Versus Single-Antiplatelet Therapy Among Patients With Ischemic Stroke A Systematic Review and Meta-analysis [Internet]. 2013. Available from: www.annals.org
22. Akinseye OA, Shahreyar M, Heckle MR, Khouzam RN. Simultaneous acute cardio-cerebral infarction: is there a consensus for management? *Ann Transl Med*. 2018 Jan;6(1):7–7.
23. Mannino M, Ascitutto S, Terruso V, Gammino M, Cellura MG, Monaco S. Myocardial Infarction Following Intravenous Thrombolysis for Acute Ischemic Stroke: Case Report and Literature Review. *Journal of Stroke and Cerebrovascular Diseases*. 2017 Jun 1;26(6):e105–7.
24. Sandercock PAG, Counsell C, Kane EJ. Anticoagulants for acute ischaemic stroke. *Vol. 2015, Cochrane Database of Systematic Reviews*. John Wiley and Sons Ltd; 2015.