

Case report

# Orthodontic Treatment for Congenitally Missing Bilateral Maxillary Lateral Incisors :A Case Report

---

## ABSTRACT

This case report showed the orthodontic treatment for a 14-year-old male patient who has Angle's Class III malocclusion with bilateral maxillary lateral incisors missing and convex profile. Owing to the profile of the patient, patient's age, the result of space analysis and the colour and shape of canine, these above factors favored canine substitution for this case. The maxillary anterior teeth esthetics was achieved by orthodontic space closure of the lateral incisors. The patient and his family were satisfied with the treatment outcome.

*Keywords: Congenital missing tooth, maxillary lateral incisors, canine substitution, orthodontic space closure*

## 1. INTRODUCTION

Orthodontic treatment for congenital missing lateral incisors was always challenging. Maxillary lateral incisor agenesis (MLIA) is one of the most common agenesis anomalies.[1] The prevalence rate in the orthodontic adolescent population aged 12 to 18 years was found to be 3.77% and greater in females (2.8%) as compared to the males (0.9%). [1] The investigated prevalence rates of MLIA were 2.7% and 4.8% for lower lateral incisors [2].

The etiology of MLIA is multifactorial, may be resulted from a combination of environmental and genetic factors. It might contribute to factors including trauma, infection, medication and a group of gene related syndromes (such as ectodermal dysplasia, cleft lip & cleft palate, and Down, Rieger and Book syndromes). [3] Mutations in MSX1, PAX9, and AXIN2 in families with multiple missing teeth have been proven by several studies in molecular genetics. [4, 5]

Three categories of treatment plan have been proposed for MLIA, i.e.: canine substitution, space opening for tooth supported restorations or single-tooth implant. For a balanced dentition, factors like: optimal aesthetics outcomes, patient age, initial malocclusion and profile; periodontal, occlusal and joint health; smile analysis, the color and size of canine, should be taken into consideration in treatment plans.[6] Among the above three treatment options, space closure with canine substitution is the least invasive option to achieve satisfying function and aesthetics. Different approaches after orthodontic treatment, such as implant or tooth-supported prosthetic restoration, demand proper interaction between dental specialties to have predictable results.[6]

## 2. PRESENTATION OF CASE

A 14-year-old male patient presented with a chief complaint of "many spaces over upper teeth and protrusive lips". The extraoral examination showed good facial proportion without facial asymmetry. The nasolabial angle was acute (90°) with both upper and lower lip protrusion. The intraoral examination revealed an Angle 's Class III molar relationship with bilateral maxillary lateral incisors missing. The space analysis showed that 12mm space in upper dentition and 2mm space deficiency in lower dentition. The upper arch was square shape and lower arch was ovoid, and both arches were symmetric. Cephalometric analysis indicated that the facial pattern was skeletal class II malocclusion (ANB = 6.3°; Wits = -1 mm) with proclined mandibular incisors as compared to norms (Figure1 & 2, table 1).

The treatment objectives were addressed as : 1). space closure with canine substitution and recontouring it into lateral incisor after orthodontic therapy, 2). to establish group function; 3).to achieve straight profile and avoiding over- retraction of maxillary anterior teeth.

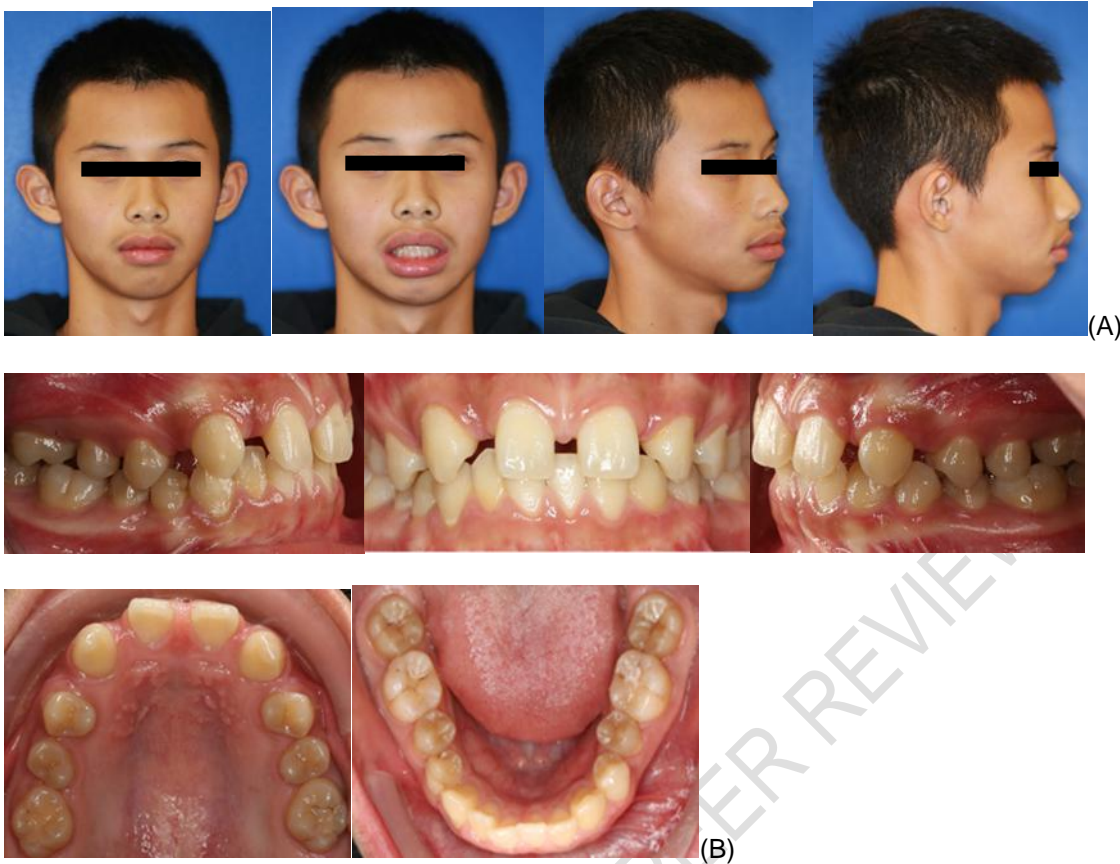

Fig. 1. Initial record at Jul-2020, 13.5 years old. (A) profile photographs, (B) intra-oral photographs.

The extra-oral photographs showed patient had a convex profile with protrusive upper and lower lips. The intra-oral photographs showed multiple spacing on upper arch due to missing bilateral lateral incisors, and mild crowding on lower arch. The skeletal pattern was Angle's Class II malocclusion, but the molar relationship before treatment was Angle's Class III.

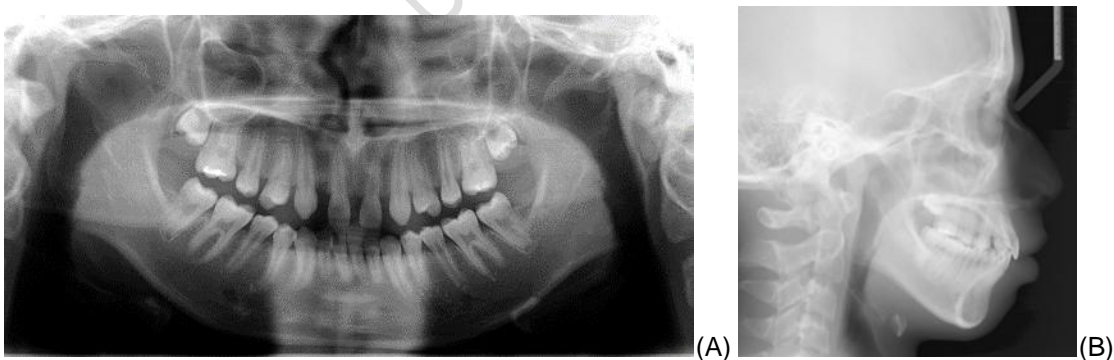


Fig. 2. Initial radiograph. (A) panoramic x-ray. (B) Cephalometric x-ray.

## 2.1 Treatment plans

Based on the patient's chief complaint, and the family wished no crowns or any other prosthesis in the future; the treatment plans were made as followed: (1) extraction of teeth #34, #44 to achieve Angle's class I molar relation; (2) maxillary lateral incisor space closure with canine substitution; (3) full mouth orthodontic treatment with fixed appliance;

(4)TADs (temporary anchorage device) for incisors intrusion and maxillary molar protraction; (5)recontour the canines with composite resin

## 2.2 Treatment Progress

The patient had no known food or drug allergy or any past medical history. Fixed Orthodontic treatment for both arches was consented by his parents. After extraction of bilateral lower first premolars, the initial leveling and alignment were performed for 8 months, followed by loop mechanism for space closure. Inter-maxillary class III elastics were employed during maxillary space closure. TADs (temporary anchorage device) were inserted at maxillary canines for incisors intrusion and maxillary molar protraction by 18th month. After three years of orthodontic treatment, all the space of both arches was closed and class I molar relationship achieved.

## 3. RESULTS AND DISCUSSION

### 3.1 RESULT

The cephalometric treatment changes showed —SNA: 87.7 °to 87.2°; SNB: 81.4 °to 80.3°; ANB: from 6.3°to 6.9°; N-Me: 110.3 mm to 119.7 mm; Co-Po: 98.4 mm to 100.1 mm; UL-E line 3mm to 2 mm; LL-E line 6 mm to 2 mm, nasolabial angle from 90° to 95°. The post treatment change revealed a more vertical than horizontal growth change, so the mandible showed a CW rotation growth pattern. The lip protrusion also improved. The patient and his parents were satisfied with the final dental occlusion and facial profile (Figure 3, 4 & 5, table 1).

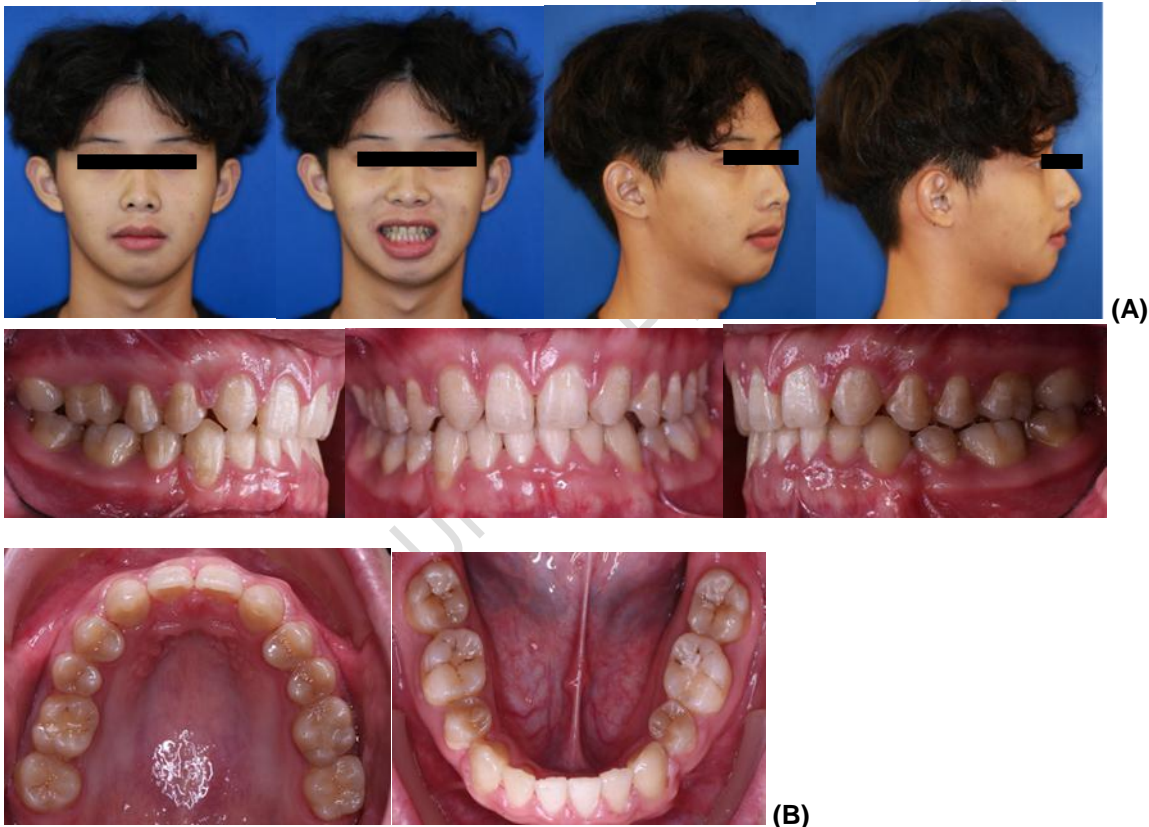


Fig. 3. Final record at Jul-2023, 16.5 years old. (A) profile photographs, (B) intra-oral photographs. Normal overjet, overbite and molar Class I occlusion achieved after 3 years of fixed orthodontic treatment.

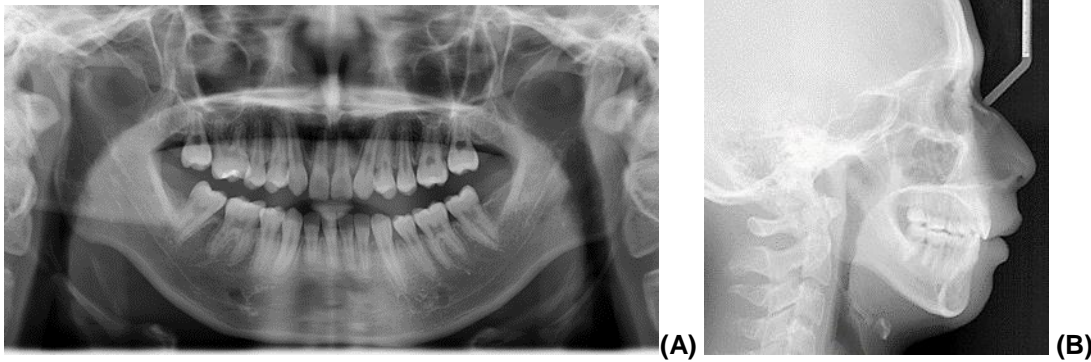


Fig. 4. Final radiograph. (A) panoramic x-ray. (B) Cephalometric x-ray. radiographic films.

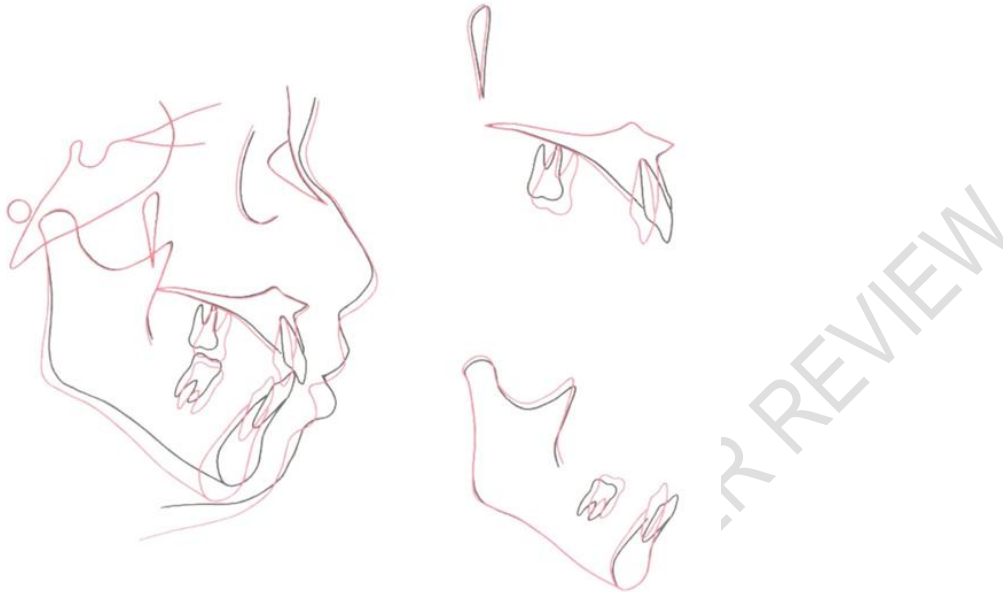


Fig. 5. Cephalometric superimposition (black: initial; red: final)

**Table 1. Cephalometric Analysis of initial and final record.**

Skeletal	Norm	Initial	Final
SNA	82°	87.7°	88.2°
SNB	80 °	81.4°	82.3°
ANB	2 °	6.3°	5.9°
Nv-A	0.4mm	6.9 mm	7.6mm
Nv-Pog	-4mm	0 mm	-4.5mm
Occl-SN	14 °	19°	19°
GoGn-SN	32 °	32.7°	36.3°
FMA	31 ° ± 5 °	27°	30.8°

Wits	-1.4 ± 2.6	-1 mm	2.7mm
UFH:LFH	45:55	46:54	44.7: 55.3
N-Me	113 mm	110.3 mm	119.7 mm
Co-Po	97.7mm	98.4 mm	100.1 mm
Dental	Norm	Initial	Final
U1-SN	104 °	103°	86.3°
U1-NA	4mm	2.2 mm	-5 mm
U1-NA	22 °	15.3°	2°
U1-L1	130 °	126.6°	152.4°
L1-NB	4mm	7.8 mm	3.5mm
L1-NB	25 °	32°	20.6°
IMPA	94 ° ± 6	94°	81°
Soft tissue	Norm	Initial	Final
Nasolabial angle	95 ° ± 5	90°	95°
UL-E line	±2 mm	3 mm	2mm
LL-E line	±2 mm	6 mm	2 mm

### 3.2 DISCUSSION

Patient age is a relevant and maybe the main factor in decision making for MLIA case. When patients with absence of maxillary lateral incisors at a very young age, the impaired esthetics may result in psychological pressure. The psychological impact is also a matter of concern for parents and orthodontists, and influences the decision for the space management.

Current treatment options for anterior maxillary anodontia (MLIA) include: fixed or removable partial dentures, orthodontic closure of interdental spaces, and dental implant.

#### 3.2.1 Treatment option 1. Implant supported restorations

“Dental implants do not move with the dento-alveolar complex during the growth period of the maxilla. It is generally recommended to wait until the jawbone has fully developed before considering dental implants, in order to prevent complications such as infra-occlusion. This typically occurs around the age of 18 for females and 21 for males”. [7]

Research showed that continuous facial skeletal growth and teeth eruption are evident in the second and third decades. It was reported that those with long faces may undergo an average of 5 mm of vertical tooth movement between the ages of

15 and 25. Consequently, if an implant is placed at the age of 18 for patient with this growth pattern, it may end up much shorter than the surrounding teeth by the age of 25. [8,9]  
Therefore, it is advisable to delay placement of an anterior maxillary implant in the adolescent patient, as in this case. Waiting until the age of 25 or 30 may offer better aesthetic outcomes in the long run for some patients.

### 3.2.2 Treatment option 2: canine substitution.

For this adolescent patient, the treatment of choice is either canine substitution or space opening for tooth supported restoration, not implant.

The indication for canine substitution including [10]:

- 1.Angle Class II malocclusion with no crowding in the mandibular arch, or
- 2.Angle Class I malocclusion with sufficient crowding to necessitate mandibular extraction; the patient should also have
- 3.Balanced, straight or mild convex profile, and
- 4.Similar size and shape of canines and premolars

According to Zachrisson et al. [11], there are six steps to properly achieve optimal space closure.

Step 1: space closure with orthodontic appliances

Step 2: orthodontic finishing in the maxillary anterior region

Step 3: Gingivaplasty

Step 4: Esthetic Restorations

Step 5: Vital Bleaching of canine (if needed)

Step 6: Occlusal Finishing, Final Restorations, and Long-Term Stability.

The orthodontic treatment should aim to reach these points as below:

1. Do not over expansion of lower arch and maintain the initial arch form
2. Fixed retainer appliance is indicated in both anterior teeth 9-10
3. To achieve lip competence after treatment
4. Treatment without CO-CR discrepancy.
5. Group function is better than pure canine protected occlusion

Above all, a balanced and attractive exposure of the upper anterior teeth is essential for an esthetic smile. Lombardi (1973) was the first to propose the use of the Golden Proportion in human dentition[12]. He proposed that, transversally, the width of maxillary incisors and canine should follow the golden proportion as about 1.618 to 1, and a "high low high" gingival contour. However, it was found out that this proportion does not conform to the natural dentition by other researches [13]. Brough et al (2010) found that canine gingival height 0.5 mm below the gingival margin of the maxillary central incisor was the most attractive and progressively less attractive with increasing gingival height. A brighter than normal shades of canines were preferred. Narrow canine crowns were frequently ranked as the most attractive; 1.5 mm narrower was preferred by the dental profession, and 3.0 mm narrower was preferred by the laypeople[14].

To build up a canine-like morphology for first premolar, orthodontic intrusion and a wider restoration is needed. If composite recontouring is not satisfactory, veneers is indicated in adulthood. With regard to functional aspects, group function after space closure is indicated.

"Both upper and lower anterior teeth are potential to shift after orthodontic treatment. For the purpose of maintaining the space closed, it is suggested to use fixed retainers". [15]

### 3.2.3 Treatment option 3. Tooth-Supported Restorations.

When treatment plan includes space opening, Zachrisson et al. [11] suggested "at the posterior regions, preferably in premolars region. One disadvantage of this type of approach is the possible reopening of spaces in lateral incisors after treatment completion. To avoid this, it is recommended to use a fixed retainer bonded on the palatal aspect of maxillary anterior teeth, after restorative esthetic recontouring of the anterior teeth".

"There are three ways to establish the appropriate space: golden proportion, contralateral lateral incisor width and Bolton analysis. The restorations can be divided into three methods: (1) resin-bonded fixed partial denture, (2) cantilever fixed partial denture, (3) conventional full-coverage fixed partial denture. The success rate depends on several factors: position, mobility, thickness, and translucency of the abutment teeth as well as the overall occlusion. We should choose appropriate prosthesis according to the patient's occlusion and oral condition". [16]

## 4. CONCLUSION

Congenitally missing maxillary lateral incisor is one of the most common agenesis anomalies. Treatment plans are classified into three types: canine substitution, single-tooth implant and tooth supported restorations. We should determine the treatment plan based on the patient's chief complaint, age, initial malocclusion and profile; periodontal, occlusal and joint health, smile analysis, the color and size of canine,

The TADs frequently applied for molar anchorage in orthodontic practice. In this case, the TADs were used at canine site for incisor intrusion to prevent lingual tipping and extrusion of upper incisors during orthodontic anterior retraction. TADs were also assisted in protraction of upper molars for posterior segment space closure. In summary, this case report demonstrates that orthodontic treatment with canine substitution is a practical approach to treat lateral incisor agenesis for adolescent patients instead of open the space for restoration after adulthood. And space closure with canine substitution is truly the least invasive option to achieve satisfactory function and aesthetics for the teens.

## CONSENT

All authors declare that 'written informed consent' was obtained from the patient for publication of this case report and accompanying images.

## ETHICAL APPROVAL

As per international standards or university standards written ethical approval has been collected and preserved by the authors.

## REFERENCES

1. Swarnalatha C, Paruchuri U, Babu JS, Alquraishi MA, et al. Prevalence of congenitally missing upper lateral incisors in an orthodontic adolescent population. *Journal of Orthodontic Science* 2020 Nov 2;9:15. doi: 10.4103/jos.JOS\_28\_19.
2. Fujita Y, Hidaka A, Nishida I, Morikawa K, et al. Developmental anomalies of permanent lateral incisors in young patients. *J Clin Pediatr Dent*. 2009 Spring;33(3):211-5. doi:10.17796/jcpd.33.3.c74j49r738676671.
3. Rakhshan V. Congenitally missing teeth (hypodontia): A review of the literature concerning the etiology, prevalence, risk factors, patterns and treatment. *Dent Res J (Isfahan)*. 2015 Jan-Feb;12(1):1-13. doi: 10.4103/1735-3327.150286.
4. Nieminen P. Genetic basis of tooth agenesis. *J Exp Zool B Mol Dev Evol*. 2009;312B:320-42.
5. Mostowska A. Novel mutation in the paired box sequence of PAX9 gene in a sporadic form of oligodontia. *Eur J Oral Sci*. 2003 Jun;111(3):272-6. <https://doi.org/10.1034/j.1600-0722.2003.00036.x>
6. Schroeder DK, Schroeder MA, Vasconcello V. Agenesis of maxillary lateral incisors: diagnosis and treatment options. *Dental Press J. Orthod*. 27 (01) • 2022 • <https://doi.org/10.1590/2177-6709.27.1.e22spe1>
7. Mijiritsky E, Badran M, Kleinman S, Manor Y, Peleg O. Continuous tooth eruption adjacent to single-implant restorations in the anterior maxilla: aetiology, mechanism and outcomes – A review of the literature. *International Dental Journal*. 2020 Jun;70(3):155-160. doi: 10.1111/idj.12549. PMID: 32149398
8. Heij DG, Opdebeeck H, van Steenberghe D, Kokich VG, et al. Facial development, continuous tooth eruption, and mesial drift as compromising factors for implant placement. *Int J Oral Maxillofac Implants*. 2006 Nov-Dec;21(6):867-78. PMID: 17190296.
9. Fudalej P, Kokich VG, Leroux B. Determining the cessation of vertical growth of the craniofacial structures to facilitate placement of single-tooth implants. *Am J Orthod Dentofacial Orthop*. 2007 Apr;131(4 Suppl): S59-67. doi: 10.1016/j.ajodo.2006.07.022.
10. Kokich VO Jr, Kinzer GA. Managing congenitally missing lateral incisors. Part I: Canine substitution. *J Esthet Restor Dent* 2005; 17(1): 5-10. doi: 10.1111/j.1708-8240.2005.tb00076.x. PMID: 15934680
11. Zachrisson BU, Rosa M, Sverker T. Congenitally missing maxillary lateral incisors: canine substitution. *Am J Orthod Dentofacial Orthop* 2011; Apr;139(4):434, 436, 438 passim. doi: 10.1016/j.ajodo.2011.02.003. PMID: 21457853.
12. Lombardi RE. The principles of visual perception and their clinical application to denture esthetics. *J Prosthet Dent*. 1973 Apr;29(4):358-82. doi: 10.1016/s0022-3913(73)80013-7.
13. Parnia F, Hafezeqoran A, Mahboub F, Moslehifard E, et al. Proportions of maxillary anterior teeth relative to each other and to golden standard in tabriz dental faculty students. *J Dent Res Dent Clin Dent Prospects*. 2010 Summer;4(3):83-6.
14. Brough E, Donaldson AN, and Naini FB. Canine substitution for missing maxillary lateral incisors: The influence of canine morphology, size, and shade on perceptions of smile attractiveness. *Am J Orthod Dentofacial Orthop* 2010; 138:705-7. doi:10.1016/j.ajodo.2010.08.004
15. Lyros I, Tsolakis IA, Maroulakos MP, Fora E, et al. Orthodontic Retainers --A Critical Review. *Children (Basel)*. 2023 Jan 28;10(2):230. doi: 10.3390/children10020230.
16. Kokich VO, Jr, Kinzer GA. Managing congenitally missing lateral incisors. Part II: Tooth-supported restorations. *J Esthet Restor Dent*. 2005;17(2):76-84. doi: 10.1111/j.1708-8240.2005.tb00089.x. PMID: 16036123.