

Case study

Esophageal Cytomegalovirus and Herpes Simplex virus co-infection in an immunocompromised patient: Case report

Abstract

Infectious esophagitis is a rare disease that usually affects immunocompromised patients. Diagnosis is made by upper endoscopy showing esophagitis and confirmed by histological examination and sometimes PCR on biopsies. We present a case of Esophageal Cytomegalovirus and Herpes Simplex virus co-infection in an immunocompromised patient.

The abstract section should be showed the method of study and the diagnosis of study also in brief the conclusion.

Case report

A 50-year-old male patient from with no past history of medical importance. He presented to our department with a recent onset of dysphagia, a fever of 40°C, and chills. Upper endoscopy revealed an erythematous oesophageal mucosa and circumferential and confluent superficial ulcers bleeding spontaneously, located mostly in the lower 1/3 of the esophageous. PCR for CMV and HSV on oesophageal biopsies was positive confirming the diagnosis. Primary immune deficiency was excluded. Human Immunodeficiency Virus (HIV) test was negative. He was treated with Ganciclovir and showed clinical improvement. Repeat upper endoscopy after hospital discharge showed complete healing of esophageal mucosa.

Keywords: Esophageal Cytomegalovirus and Herpes Simplex virus co-infection immunocompetent, CMV PCR, HSV PCR, Ganciclovir

Introduction

Infectious esophagitis is a rare disease, representing the second most common cause of oesophagitis after those associated with gastroesophageal reflux, and it usually occurs in immunocompromised patients. There are few reported cases of multiple viral infections, and even extremely rare in immunocompetent individuals. We present a case of esophageal cytomegalovirus and herpes simplex virus co-infection occurring in an immunocompetent individual.

Case report

A 50-year-old male patient with no past history of medical importance, presenting to our gastroenterology department with dysphagia, high fever at 40°C and chills. Upper endoscopy revealed an erythematous oesophageal mucosa and circumferential and confluent ulcers, predominantly in the lower 1/3, spontaneously bleeding upon (figure 1). Esophageal biopsies were taken and PCR for CMV and HSV on these biopsies were positive at 1.28 log

copies, and 366,347 copies/mL respectively. Accordingly, the diagnosis of esophageal (CMV) and (HSV) co-infection was made. CMV serology showed negative anti-CMV IgM antibodies and positive anti-CMV IgG antibodies (>250 IU/ml). HSV serology indicated negative anti-HSV I and II IgM antibodies and positive IgG antibodies. Human Immunodeficiency Virus (HIV) testing was negative. The level of immunoglobulins and lymphocyte were normal ruling out primary immune deficiency. The patient was treated with Ganciclovir at 5 mg/kg/12h for 21 days. He was treated with Ganciclovir and showed clinical improvement. Repeat upper endoscopy after hospital discharge showed complete healing of esophageal mucosa.

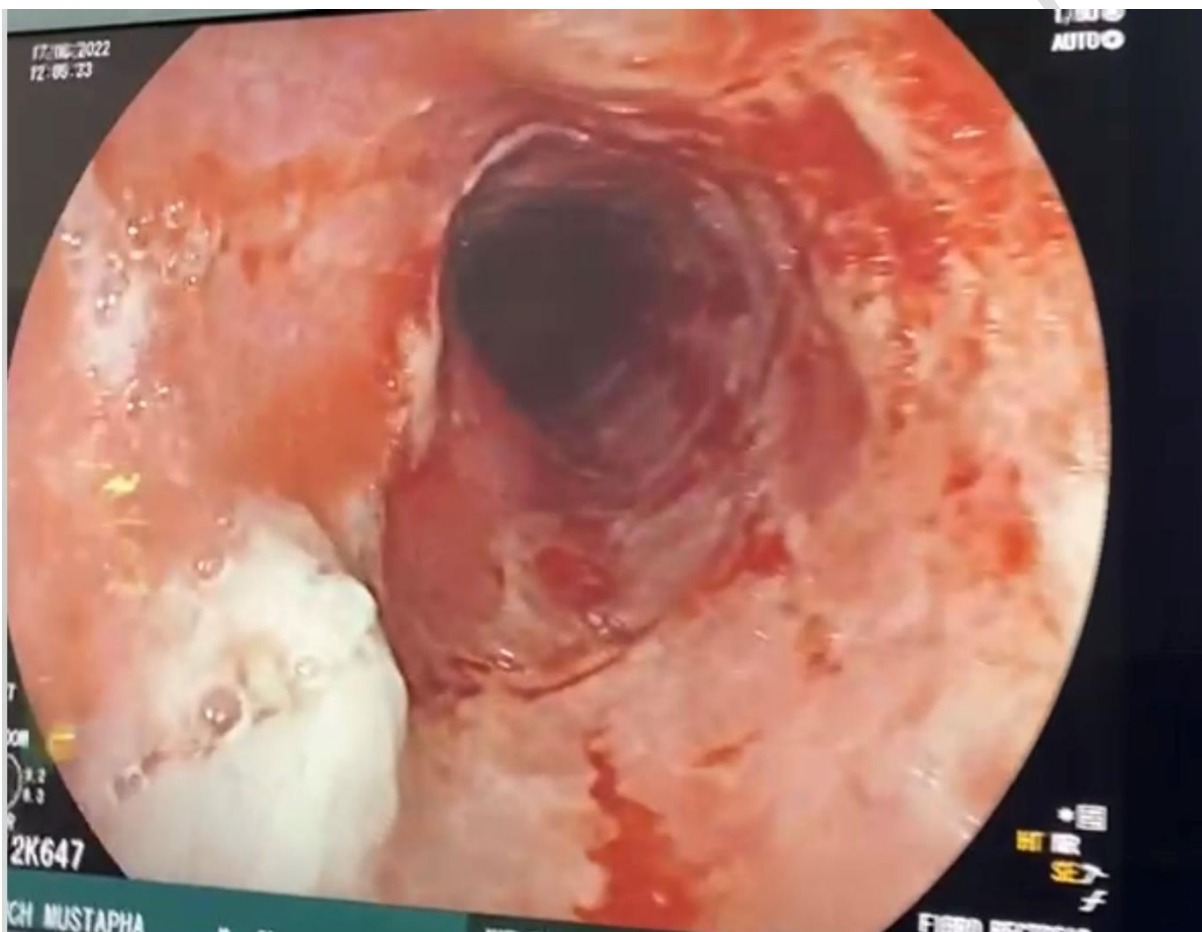


Figure 1: Erythematous Oesophageal Mucosa, characterized by Circumferential and Confluent Ulcers

Discussion

Viral co-infection of the oesophagus is exceedingly rare. In the literature, we found twelve cases of esophageal CMV and HSV co-infection. All these patients were recipients of immunosuppressive transplants or had acquired immunodeficiency syndrome [1-2-3]. In our patient, negative HIV test and normal level of immunoglobulins and lymphocyte ruled out immune deficiency.

Clinically, patients with viral esophagitis present by dysphagia and odynophagia, but they can also be associated with epigastric pain, as in our case [4-5].

Ulceration due to CMV and/or HSV can be seen by upper endoscopy, typically appearing as well-defined ulcers located in the middle and lower thirds of the oesophagus [6]. A definitive diagnosis relies on multiple deep biopsies taken from the edges of the ulcer for microbiological and histopathological analysis. Microbiological analysis (immunohistochemistry and PCR searching for CMV and HSV antigens on biopsy fragments) is crucial. According to several authors [4-7-8-9-10-11], the presence of large cells with nuclear inclusions in fibroblasts and endothelial cells in the histology of oesophageal ulcer biopsies is sufficient to confirm cytomegalovirus infection. In our patient, CMV and HSV PCR on esophageal biopsies confirmed the diagnosis of co-infection esophagitis.

Treatment recommendations for CMV/HSV infection involves oral administration of valganciclovir for mild conditions and intravenous ganciclovir for severe conditions. The duration of treatment depends on the resolution of all symptoms and the absence of virus detection by polymerase chain reaction (PCR) in two consecutive blood samples within a week [12]. Our patient received ganciclovir at 5 mg/kg/12h for 21 days, with good clinical and endoscopic outcome.

The discussion section need to add more new references

Conclusion

The diagnosis of herpetic and/or CMV oesophagitis should be considered in any patient presenting with dysphagia without an apparent cause, including immunocompetent individuals....the conclusion should be consent in the what the interest report of the study

Références

- 1- Bonacini M, Young T, Laine L. The causes of esophageal symptoms in human immunodeficiency virus infection. A prospective study of 110 patients. Arch Intern Med 1991; 151: 1567–72
- 2- Spencer GD, Hackman RC, McDonald GB et al. A prospective study of unexplained nausea and vomiting after marrow transplantation. Transplantation 1986; 42: 602–7
- 3- Wilcox CM, Schwartz DA, Clark WS. Esophageal ulceration in human immunodeficiency virus infection. Ann Intern Med 1995; 122: 1
- 4- Wang HW, Kuo CJ, Lin WR, et al. The clinical characteristics and manifestations of cytomegalovirus esophagitis. Dis Esophagus 2016;29:392-9.
- 5- - Sheth A, Boktor M, Diamond K, et al. Complete esophageal obliteration secondary to cytomegalovirus in AIDS patient. Dis Esophagus 2010;23:E32- E34
- 6- - Demir D, Doganavsargil B, Sarsik B, et al. Is it possible to diagnose infectious oesophagitis without seeing the causative organism? A histopathological study. Turk J Gastroenterol 2014; 25:481-7
- 7- - Maiorana A, Baccarini P, Foroni M, et al. Human cytomegalovirus infection of the gastrointestinal tract in apparently immunocompetent patients. Hum path 2003;34:1331-6.

- 8- Peter A, Telkes G, Varga M, et al. Endoscopic diagnosis of cytomegalovirus infection upper gastro-intestinal tract in solid organ transplant recipients: hungarian single center experience. Clin Transplant 2004;18:580-584
- 9- Peter A, Telkes G, Varga M, et al. Endoscopic diagnosis of cytomegalovirus infection upper gastro-intestinal tract in solid organ transplant recipients: hungarian single center experience. Clin Transplant 2004;18:580-584
- 10- Wilcox CM, Rodgers W, Lazenby A. Prospective comparison of brush cytology, viral culture, and histology for the diagnosis of ulcerative esophagitis in AIDS. Clin Gastroenterol Hepatol 2004;2:564-7
- 11- Featherstone R, Cameron L, Khatib R, et al. Massive oesophageal bleeding in achalasia complicated by cytomegalovirus oesophagitis. Ann Thorac Surg 1995;59:1021-2
- 12- Medizinische Klinik et al, Complications gastro-intestinales sous immunosuppression swiss medical forum 2019

The references should be add with new journals < 5 years

UNDER PEER REVIEW