

Pulmonary involvement during varicella in a patient with sickle cell disease: what diagnosis should we make?

Abstract

Introduction: Pulmonary involvement during chickenpox is one of the most serious complications. However, it can be difficult to distinguish between varicella pneumonia, bacterial superinfection and an acute chest syndrome. We report a case of varicella complicated by pneumonia in a young adult with sickle cell disease.

Observation: It was a 24-year-old woman with sickle cell disease. Examination on admission revealed generalized skin lesions of varying ages, associated with scratching lesions. On day 3 of hospitalization, she presented an acute respiratory failure associated with fever (40°C). Thoracic CT angiography revealed diffuse pulmonary nodules and micronodules in both lung fields. Blood culture isolated *Staphylococcus spp.* The patient was put on oxygen therapy combined with antiviral treatment and antibiotic therapy. The course was marked by a regression of symptoms, with disappearance of respiratory distress on day 2 and apyrexia on day 3 of treatment. The follow-up chest CT scan carried out at 4 months came back normal.

Conclusion: Although pneumonia is one of the most common complications of varicella, it can be difficult to diagnose in patients with sickle cell disease, considering the frequency of pulmonary involvement of various etiologies

Introduction

Chickenpox is an infection caused by the varicella zoster virus (VZV), representing its primary infection [1,2]. It remains the most common eruptive fever, is extremely contagious, and mainly affects school-age children, with a prevalence up to 90%. Typically, it manifests itself as a vesicular rash with fever, which usually has a benign outcome [1, 3, 4]. However, in adults, pregnant women and immunocompromised patients, varicella can be severe, as the infection can lead to many complications. Pulmonary involvement during chickenpox is one of the most serious, its frequency is increasing in recent years, with an estimated incidence in Europe and the United States of 5% and 50% respectively, and its mortality rate of up to 20%. However, the epidemiology of varicella and its complications is still poorly described in low-income countries [5, 6, 7, 8].

Sickle cell disease, a genetic hemoglobin disorder with autosomal recessive inheritance, is a frequent cause of immunosuppression in sub-Saharan Africa. It leads to increased susceptibility to infections, of multifactorial origin, mainly found in homozygous sickle cell patients [9].

When pulmonary involvement occurs during chickenpox in a patient with sickle cell disease, it can be challenging to distinguish between varicella pneumonia, bacterial

superinfection and an acute chest syndrome. We report a case of varicella complicated by pneumonia in a young adult with sickle cell disease.

Observation

It was a 24-year-old woman with sickle cell disease, on folic acid 5 mg/day, reporting 2 to 3 mild vaso-occlusive attacks per year and a baseline hemoglobin level of 8 g/dl, with no other specific pathological history. Her vaccinations against pneumococcus, meningococcus, hepatitis B and Covid-19 were up to date. Her symptoms began by a skin rash, made up of pruritic vesicles and papules. These lesions started on the neck and then extended to the face, and were associated with fever, headaches and insomnia linked to the pruritus. She went to the dermatology department 3 days after and was diagnosed with varicella, a symptomatic treatment was then initiated with cetirizine 10 mg, paracetamol (1000 mg x 3/day) and local care (eosin 2% and emollient gel).

Despite this treatment, the skin lesions became generalized, with a worsening of the initial symptoms, and the patient consult our clinic. Initial examination revealed generalized skin lesions of varying ages (vesicles, pustules, umbilicated papules and crusts), associated with scratching lesions (**Figures 1 and 2**). The initial treatment was pursued. Biological tests revealed a hemoglobin level of 8.8 g/dl, thrombocytopenia of 43,500/mm³, and a biological inflammatory syndrome with hyperleukocytosis of 12,600, predominantly neutrophils, and a positive C-reactive protein of 160 mg/l. The other tests (serum electrolyte test, renal function) were unremarkable. On day 3 of hospitalization, the patient presented an acute respiratory failure with shortness of breath, signs of struggle and desaturation to 80% on room air, associated with fever (40°C). Thoracic CT angiography showed pulmonary nodules and micronodules in both lung fields (**Figure 4**). Other laboratory tests revealed microcytic hypochromic anemia (hemoglobin at 6.8 g/dl), hyperleukocytosis (WBC = 12,430/mm³), severe thrombocytopenia at 26,000, C-reactive protein at 160.35 mg/l, procalcitonin at 0.67 ng/ml and hepatic cytolysis with ASAT: 131 u/l and ALAT: 67 u/l. Blood culture isolated *Staphylococcus spp.* The patient received oxygen therapy at a rate of 5 l/minute, combined with antiviral treatment based on oral aciclovir 1000 mg/day, antibiotic therapy based on ceftriaxone 2 g/day and preventive anticoagulation (Enoxaparin 0.4 ml/day). Other etiological tests were negative (TB PCR and Covid test). The course was marked by a regression of symptoms, with disappearance of respiratory distress on day 2 and apyrexia on day 3 of treatment. The follow-up chest CT scan carried out at 4 months came back normal (**figure 5**).

Discussion

The clinical presentation of chickenpox is a papulovesicular rash with intense pruritus and fever, most often occurring in early childhood [10]. Adults are affected in 20% of cases, with a 20-fold increase in the risk of complications compared with children [11]. One of the major complications of chickenpox is varicella pneumonia, which has an

incidence of 16-33% and a mortality rate of over 20% [8]. Pulmonary involvement follows visceral dissemination of VZV and usually occurs in 1 to 7 days after rash onset. Symptoms include dry cough with occasional hemoptysis, chest pain, shortness of breath, fever, and sometimes a quickly evolving acute respiratory distress [12,13]. Chest imaging usually reveals well-limited nodules scattered over both lung fields, more rarely unsystematized hiliform opacities or heterogeneous infiltrates, which may or may not be associated with "ground-glass" images around these nodules or scattered in a mosaic pattern [14,15].

The risk factors identified for varicella pneumonia are smoking (due to its harmful effects on bronchial mucociliary clearance and the altered activity of alveolar macrophages), immunosuppression, chronic lung diseases, pregnancy, and a skin involvement with more than 100 elements [6, 8, 16].

Sickle cell patients have an increased susceptibility to infections, particularly pulmonary infections, which are mainly due to encapsulated bacteria [17]. Pulmonary involvement during chickenpox may also be caused by a bacterial superinfection, mainly due to *Pneumococcus*, *Streptococcus* and *Staphylococcus*. Furthermore, sickle cell disease is itself a source of another pulmonary complication, the acute chest syndrome (ACS), which is defined by the association of any new chest radiological image with one or more of the following symptoms: fever, chest pain and respiratory signs (cough, dyspnea, wheezing, intercostal draught or nasal flaring, hemoptysis, etc.) [19, 20]. Several clinical circumstances may cause ACS, either alone or in combination (hypoventilation, pulmonary infection or vascular occlusion), leading to reduced alveolar exchanges [21].

Therefore, it can be difficult to diagnose varicella pneumonia in patients with sickle cell disease, considering the diverse and sometimes intricate etiologies of pulmonary involvement. In our patient, even though the chest CT scan strongly reinforced the suspicion of varicella pneumonia, the isolation of a staphylococcal strain on blood culture raised doubts about the bacterial origin of the pulmonary involvement. An acute chest syndrome cannot be formally ruled out, given the acute infection that may have triggered it.

In any case, the diagnosis of varicella pneumonia remains highly probable when respiratory symptoms occur after a skin rash suggestive of chickenpox, associated with the bilateral interstitial lung disease, in high-risk patients. VZV polymerase chain reaction (PCR) and more rarely bronchial endoscopy (which may reveal vesicular lesions in the bronchial mucosa) can help confirm the diagnosis. Other complications due to the viral dissemination have been described, including hepatic cytolysis, which was also found in our patient [14].

Treatment for chickenpox pneumonia is intravenous acyclovir (10mg/kg every 8 hours) in severe cases, or valaciclovir or ganciclovir for seven to ten days [6, 8, 15, 22]. This treatment is often combined with local care, high-flow oxygen therapy and antibiotic therapy if superinfection is suspected. Clinical and radiological outcome is favourable

when treatment is initiated early [15]. Our patient was treated with oral acyclovir (due to the unavailability of the injectable form in our country), antibiotic therapy and oxygen therapy, with a good clinical course and disappearance of radiological lesions at 4 months follow-up (**Figure 5**). Cases of death with lesional oedema and multi-organfailure have been reported in the literature, more frequently in immunocompromised patients and pregnant women, and usually, they are due to delayed management and no use of antiviral drugs [8, 22].

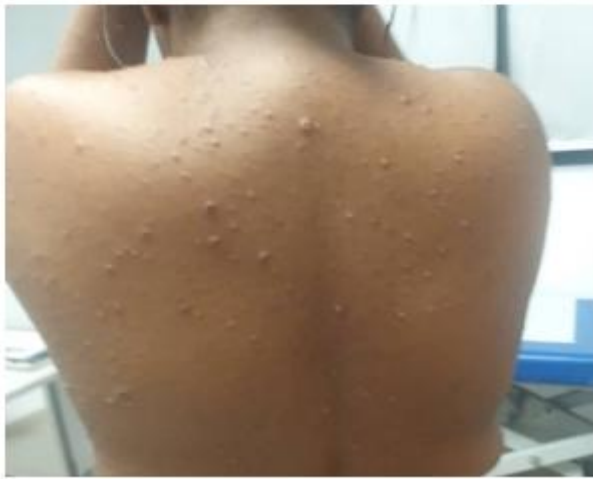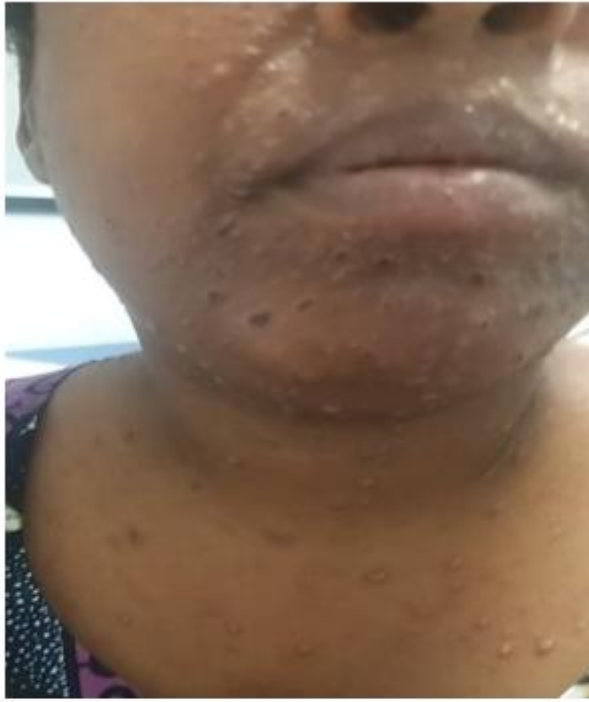The preventive measures, recommended for non-immune subjects, involve isolation and preventive treatment with immunoglobulins or acyclovir. The indications differ depending on whether prevention is envisaged before or after exposure to the virus, and on the subject exposed (immunocompetent, immunocompromised, or pregnant woman) [6].

Conclusion

Varicella pneumonia is one of the most frequent complications of chickenpox in adults, and requires searching for an underlying condition in those patients. In sickle cell disease, which is a frequent cause of immunodepression in our context, pulmonary varicella can be difficult to diagnose, given the frequency of lung involvement of various etiologies. Its treatment involves early use of antiviral therapy such as acyclovir, which reduces mortality.

CONSENT AND ETHICAL APPROVAL

the patient's consent has been obtained.



Figures 1 & 2: Lesions of different ages (vesicles, pustules, umbilicated papules and crusts).

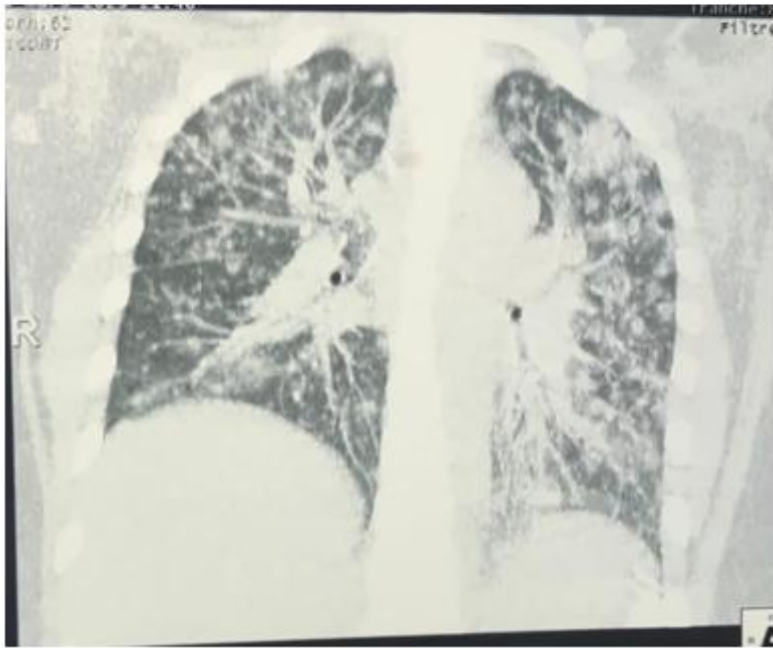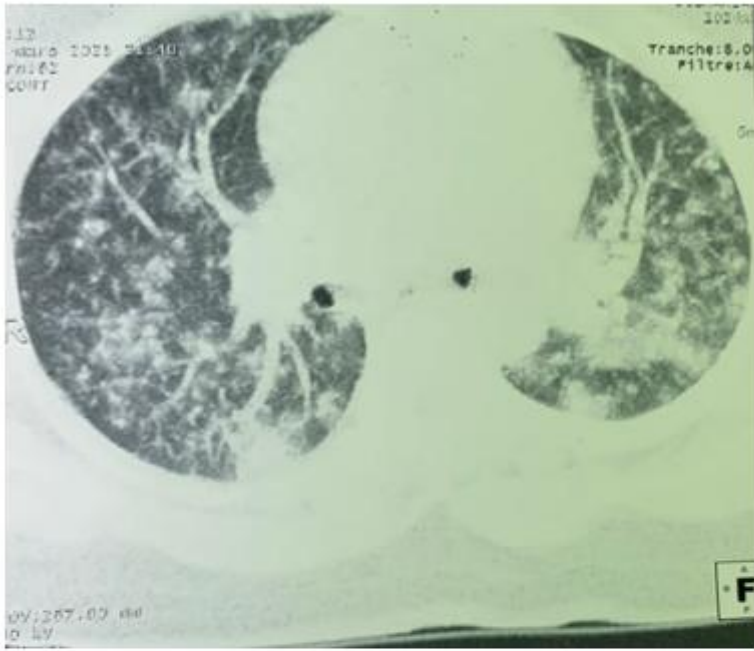


Figure 3 and 4: Thoracic CT scan showing diffuse pulmonary nodules and micronodules in both lung fields.

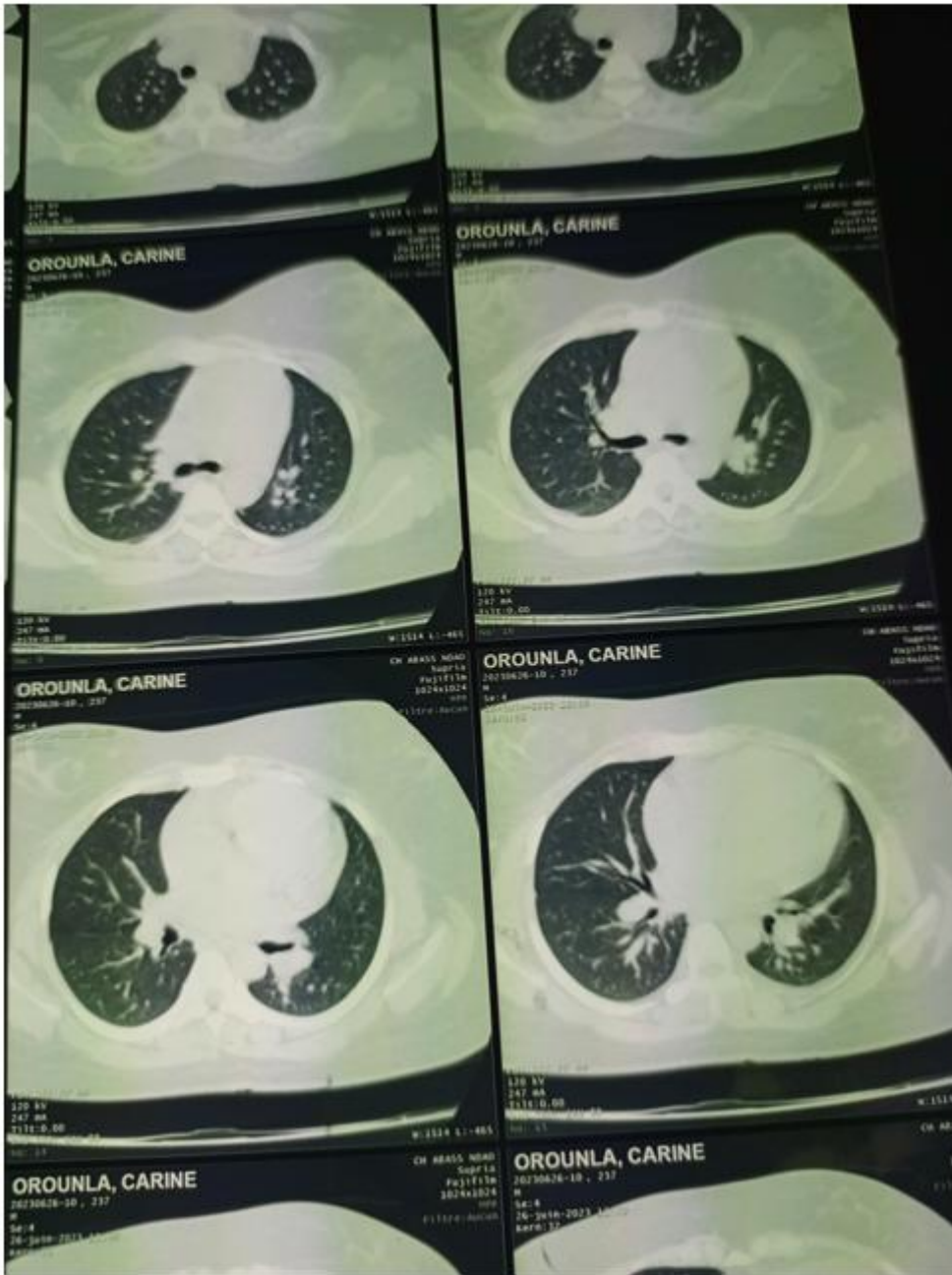


Figure 5. Normal CT scan at month 4

REFERENCES

1. UniversityCollege of Infectious and ParasiticDiseases. Chickenpox, Shingles. Dance. PILLY Toomuch. 2022. 3rd web edition. Updated June 2022. www.infectiologie.com page 716-719.
2. Laurent, R. Varicella-Zonas. EMC-Medicine. 2005; 2(3): 276-283.

3. University College of Infectious and Parasitic Diseases. Varicella-zoster virus infection: Infectious and tropical diseases. In: E Pilly. 26th ed. 2017; 421-424
4. World Health Organization. Varicella and herpes zoster vaccines: WHO position paper, June 2014. Weekly Epidemiological Record. 2014 ; 89(25): 265-287.
5. Meyer, Pamela A., Seward, Jane F., Jumaan, Aisha O., et al. Varicella mortality: trends before vaccine licensure in the United States, 1970–1994. The Journal of infectious diseases, 2000, vol. 182, no. 2, p. 383-390.
6. Benjelloun, H., Zaghba, N., Yassine, N., et al. Varicella pneumonia associated with bilateral pleurisy in an immunocompetent adult. Rev Pneumol Clin. 2013; 69(5):287-290.
7. De Wals - Marc Brisson, N. Burden of chickenpox and shingles in Quebec, 1990-2008: impact of the universal vaccination program, National Institute of Public Health of Quebec. Canada. Retrieved from <https://policycommons.net/artifacts/2060762/fardeau-de-la-varicelle-et-du-zona-au-quebec-1990-2008/2813853/> on 04 Feb 2024. CID: 20.500.12592/gfr86s .
8. Mohsen A, Peck R, Mason Z, et al. Lung function tests and risk factors for pneumonia in adults with chickenpox. Thorax. 2001; 56 (10): 796.
9. MATTIONI, Sarah, STOJANOVIC, Katia Stankovic, GIROT, Robert, et al. Sick cell anemia in France. Rev Franc Lab. 2016; 2016 (481): 61-66.
10. Floret D. Chickenpox and shingles in children. Journal of Pediatrics and Childcare. 2020; 33 (2): 52-68.
11. Asse KV., REKIK, H., ROPERT, J.-C., et al. Fulminant pneumonia during chickenpox in an immunocompetent 16-month-old girl. Arch Ped. 2012; 19 (10): 1074-1078.
12. Ovetchkine P, and Reinertn P. Chickenpox. Encycl Med Chir (Infectious Diseases), 2007
13. Aissa I, Darouaz S, Khattab A, et al. Pleural and lung complications of chickenpox in the immunocompetent adult. Rev Tun Infect. 2009; 3(1): 33 – 36.

14. Senneville E, Rivaud E, Valette M, et al. Non-pulmonary parameters associated with varicella pneumonia in healthy adults. *Med and Mal Infect.* 2000; 30(4): 211-216.
15. Richaud C, Ngo MT, Agbessi, CA, et al. Bronchial involvement during varicella pneumonia in an immunocompetent adult. *Rev Mal Resp.* 2008; 25 (1): 59 - 62.
16. Mohsen, A. H. And Mckendrick, M. Varicella pneumonia in adults. *European Respiratory Journal.* 2003; 21(5): 886-891.
17. Goodnight, William H. and Soper, David E. Pneumonia in pregnancy. *Critical care medicine.* 2005; 33(10): 390-397.
18. L'esprit Emmanuelle and Lesprit Philippe. Bacterial infections in sickle cell disease: Sickle cell disease. *The Practitioner's Review.* 2004; 54 (14): 1574-1577.
19. Castro, Oswaldo, Brambilla, Donald J, Thorington, Bruce, et al. The acute chest syndrome in sickle cell disease: incidence and risk factors. *The Cooperative Study of Sickle Cell Disease. Blood.* 1994; 84 (2): 643-649.
20. Vichinsky Elliott P, Neumayr Lynne D, Earles Ann N, et al. Causes and outcomes of the acute chest syndrome in sickle cell disease. *NEJM.* 2000; 342 (25): 1855-1865.
21. Richaud C, Ngo MT, Agbessi CA, et al. Bronchial involvement during varicella pneumonia in an immunocompetent adult. *Rev Mal Resp.* 2008; 25(1): 59-62.
22. Abdelghani A, Slama S, Hayouni A, et al. Varicella pneumonia: a serious complication of chickenpox in adults. *Rev Pneumol Clin.* 2009; 65(1): 9-12.