

Case study

Spontaneous cerebrospinal fluid leak and idiopathic intracranial hypertension: A CASE REPORT and literature review

Abstract

Nowadays, ENT surgeons perform surgical treatment of spontaneous cerebrospinal fluid (CSF) leak, with endonasal endoscopy being preferred to craniotomy as less invasive. Nevertheless, it is frequently the sign of the underlying idiopathic intracranial hypertension, which is outside the conventional domain of competence in ENT. Toutefois, surgery is a necessary step, it should not hide the importance of treating the underlying disease. This therapy is complex and requires interdisciplinary collaboration between specialists such as an otolaryngologist, an ophthalmologist, a neurologist, a neurosurgeon, a radiologist, a nutritionist, an endocrinologist and a psychotherapist. Sudden leakage of lower cerebral fluid (CSF) due to idiopathic intracranial hypertension (IIH) is rare. Patients frequently suffer from CSF rhinorrhea, recurrent meningitis, chronic headaches, and visual disturbances. However, few patients have been diagnosed with neuroendocrine disorders. First-line treatment is endonasal endoscopy. **Keywords** idiopathic intracranial hypertension, CSF rhinorrhea, multidisciplinary management, case report

Introduction

Idiopathic intracranial hypertension (IIH) causes spontaneous cerebrospinal fluid (CSF) leaks, which are a relatively uncommon but dangerous condition. Patients typically present with CSF liquor fistula, which can cause meningitis, persistent headaches, and visual impairments, among other serious consequences. Neuroendocrine changes have been reported in a small number of patients (3). Once the diagnosis is confirmed, the first course of treatment is endoscopic surgical repair. The ability to treat spontaneous cerebrospinal fluid (CSF) leaks has been made possible by the growth of endonasal endoscopic surgery during the 1990s. Because of the complications from the craniotomy, this has decreased morbidity such as cerebral edema or hemorrhage, anosmia, convulsions, memory loss, etc. (1).

The primary reason for reoperation, however, is still the comparatively high risk of recurrence, which varies from 25 to 87% (4). This is due to the elevated intracranial pressure (ICP) following endoscopic surgery and the lack of postoperative ICP management. In complicated cases, some surgeons have tried endoscopic endonasal repair, which is followed by a high pressure shunting procedure that may stop the CSF leakage or relieve the symptoms.

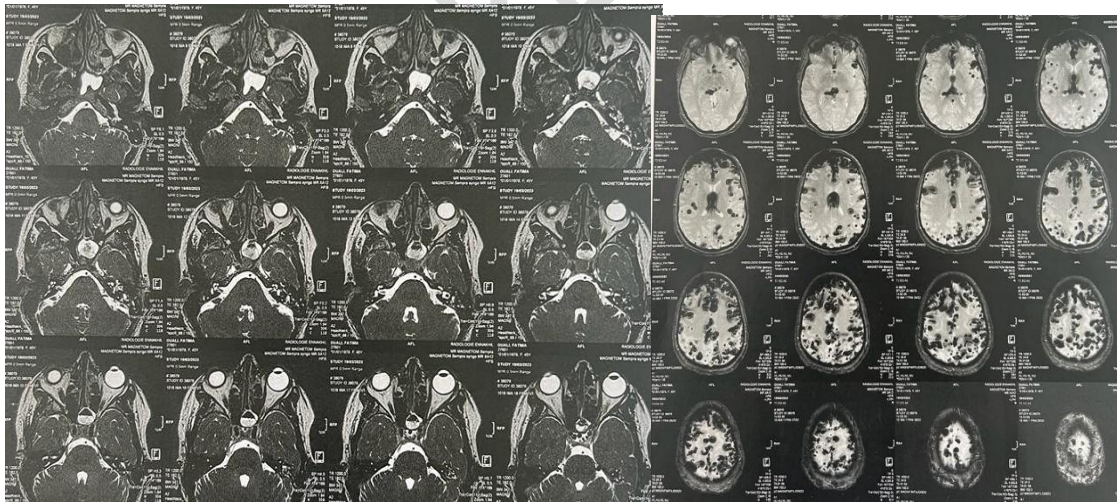
- ✓ IICHT and spontaneous CSF leak have been suggested to be associated (2), assimilar demographic profiles
- ✓ intracranial pressure (ICP) increases after spontaneous CSF leakrepair in some cases (3); ICP elevation is associated with elevated risk of recurrent leak;
- ✓ A higher risk of CSF leak is linked to IICHT secondary to tumor.

Case report

A 49-year-old woman presented to the emergency department 9 months ago with spontaneous chronic intermittent left rhinorrhea. Patient without any particular pathological history, the history of her illness goes back to 15 years, with the onset of intense headaches, followed 3 days later by chronic intermittent left rock water rhinorrhea, accentuated by exertion and complicated by recurrent meningitis, with the notion of a spectacular improvement in these rhinorrheas once the rhinorrhea had set in. In addition, the patient reported the notion of homolateral otalgia without otorrhea and without other associated otological, rhinological, neurological or ophthalmological signs. With left seromucous otitis on initial examination, beta 2 transferrin was not performed because the quantity of CSF was insufficient, CT scan of the temporal bone and sinuses (DONE ON MONTH 5) did not reveal the defects in the skull base.

6 months later, the patient came to us for a consultation because of persistent symptoms and recurrence of meningitis. On examination, no rhinorrhea, no posterior jetage BMI 26 kg/m² otoscopy and rhinoscopy were normal, and the rest of the oral examination was unremarkable. neurological examination normal, but on general examination palpation of a deep left mammary nodule measuring approximately 2 cm, well defined and hard in relation to the deep plane, with no signs of inflammation opposite, for which the breast ultrasound was requested.

In the magnetic resonance imaging of the brain, performed during an episode of meningitis, we note the presence of diffuse pneumocephalus bubbles in the supratentorial region, with filling of the sphenoidal sinus. The latter is the site of a hydroaeroid level, and there is doubt about the presence the defect in the upper wall of the left sphenoid. [FIGURE 1]



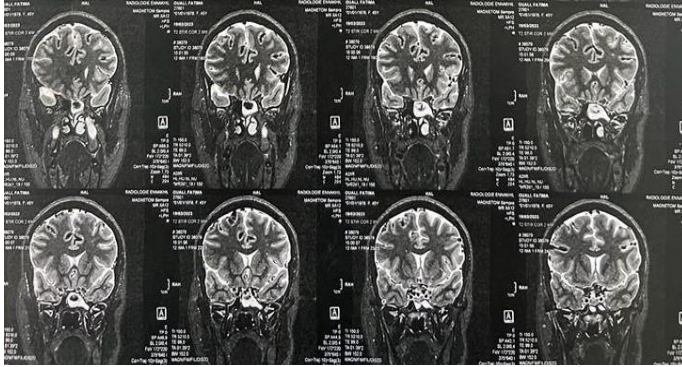
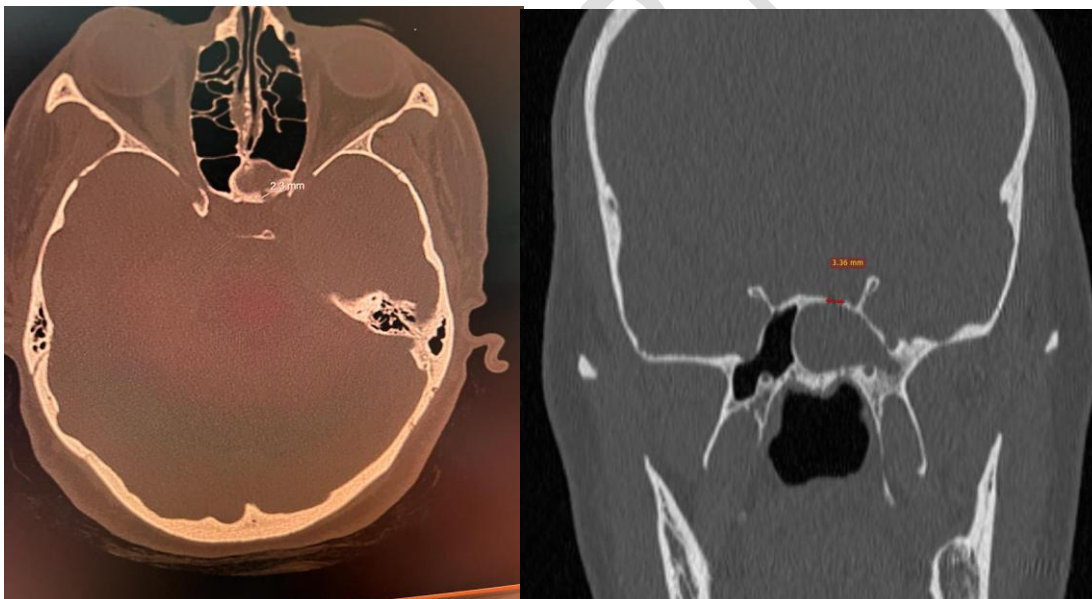


Figure 1: the axial and sagittal images in the magnetic resonance imaging of the brain revealed the presence of diffuse pneumocephalus at the level of the supratentorial region, with filling of the sphenoidal sinus.

On the CT scan of the temporal bone, there is a 13 mm defect at the expense of the antero-lateral part of the left tegmen tympani, with no filling of the middle ear and no CSF flow at this level.

The CT scan of the sinuses revealed the presence of a 2 mm defect on the upper wall of the sphenoid, lateralized to the left, but since this did not explain the former volume of the pneumocephaly. The sinus CT scan was reread, revealing the presence of another defect in the upper wall of the sphenoid, lateralized to the left and measuring 9 mm. Hence the importance of thin-slice CT with multiplanar reconstructions. [FIGURE 2]



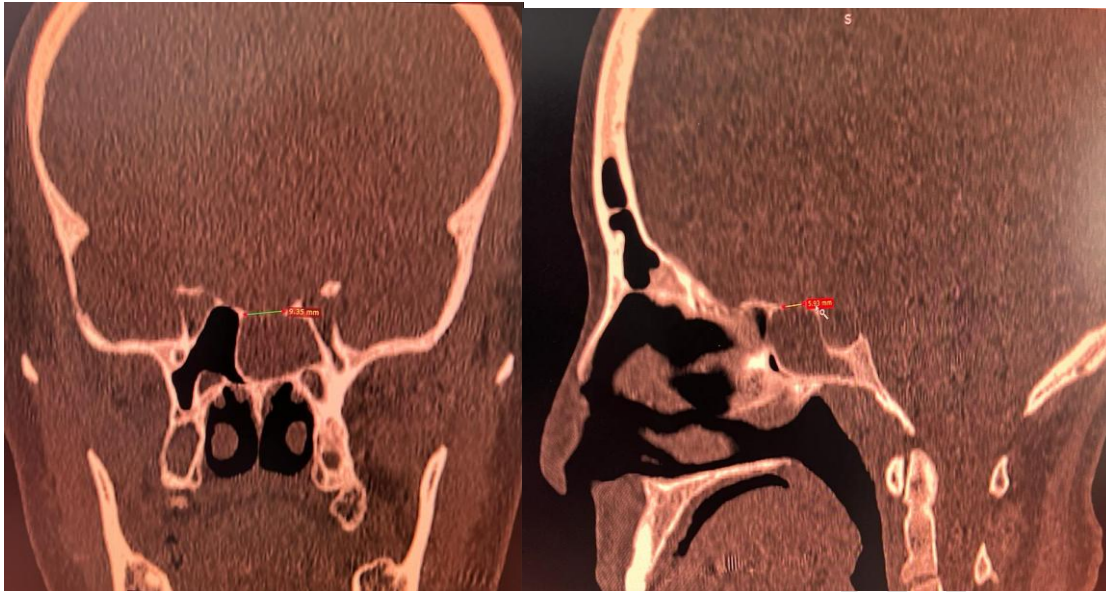


FIGURE 2: the axial and sagittal images of CT scan of the sinuses revealing the presence of 2 defects at the expense of the upper wall of the sphenoid lateralized to the left

Management was stopped because the breast ultrasound was revealed a nodular lesion with irregular contours measuring 16.5*12.5 mm in diameter, in the superior-internal quadrant of the left breast. A cytopunction was performed, revealing the presence of an infiltrating carcinoma, and the patient underwent a lumpectomy of the left breast. She is currently undergoing radiotherapy.. Our therapeutic attitude was as follows in order to provide the most appropriate treatment for this patient:

First of all, we need to start with dietary and psychological management, focusing on weight loss, which is the first objective to be achieved in order to improve the symptoms. A cerebral MRI should also be repeated for 2 purposes: firstly to determine the nature of the filling, whether it is meningocele or meningoencephalocele, and also to look for indirect signs of idiopathic intracranial hypertension, provided that it is performed outside an episode of meningitis. Subsequently, endoscopic surgical repair is required, with a minimum interval of 4 weeks, which seems reasonable, to ensure closure of the leak and physiological equilibrium between excretion and absorption of CSF. Between 4 and 8 weeks, rigorous questioning should be carried out, in search of clinical signs of idiopathic intracranial hypertension, and an ophthalmological examination with fundus and assessment of the visual field should be requested. A maximum interval of 8 weeks seems reasonable, to avoid recurrences thanks to early detection of the underlying HTIC, which must be managed.

However, if we do not have the necessary criteria for a definite diagnosis of HITCI, we should think about spontaneous normotensive rhinorrhoea, which is generally consecutive to the existence of HITCI. We should consider spontaneous normotensive rhinorrhoea, which is generally due to the existence of a congenital malformation or a tumour eroding the base of the skull. Congenital malformations include the persistence of embryonic ducts. Whatever the diagnosis, clinical, endoscopic and radiological monitoring is essential.

Discussion

IIH is increasingly recognized as a cause of primary spontaneous CSF leaks. Over the past 2 decades, several articles on this topic have been published mostly in the otolaryngological and neurosurgical literature (5–14). These reports highlight the similarities between the demographics of patients with IIH and those with spontaneous CSF leaks suggesting a causal relationship between IIH and the so-called spontaneous CSF leak. Similar to IIH patients, reported cases of spontaneous CSF leak are often young or middle-age obese women, with a mean body mass index (BMI) greater than 30 kg/m². Patients with spontaneous CSF leaks are frequently middle-aged or younger, obese women, just like IIH patients (7, 13). Based on an analysis of documented cases, most patients who experience spontaneous CSF leakage are female and have a mean body mass index (BMI) greater than 30 kg/m². The primary empty sella syndrome, an endocrinologic condition in which chronically elevated ICP may be involved, also shares this demographic overlap (14, 15). Seventy-two percent of the patients in a retrospective analysis of eleven patients with spontaneous CSF leaks confirmed by β -2 transferrin had IIH (8).

The location and intensity of the leak, as well as the existence of concomitant elevated intracranial pressure (ICP) signs, all influence the presenting symptoms of spontaneous CSF leaks, which can differ significantly. Orthostatic headaches and stiff neck may be signs of intracranial hypotension if the leak is active (11). Patients with bone defects in the posterior fossa may present with CSF otorrhea and conductive hypoacusia, depending on where the CSF leak occurred. Patients with cribriform plate defects typically develop CSF rhinorrhea (9, 10, 16). Sometimes the initial presentation that leads to the identification of the CSF leak is bacterial meningitis. Even when the leak is active, some patients may still experience symptoms of elevated ICP, such as headache, tinnitus, visual abnormalities, but most often, patients develop symptoms and signs of intracranial hypertension only after the CSF leak has been repaired (11), likely because the leak acts as a route of spontaneous CSF diversion (17).

To find the skull base defects causing CSF leaks, computed tomography and magnetic resonance imaging (MRI) of the brain and skull base are always conducted; surprisingly, these imaging studies also frequently reveal radiologic indicators linked to elevated ICP (18). In contrast to 11% of patients with non-spontaneous CSF leaks and 5% to 6% of the general population without CSF leaks, 100% of patients with spontaneous CSF leaks had an entirely or partially empty sella turcica on imaging, according to a retrospective study assessing the prevalence of empty sella in patients with CSF leaks (12). The CSF-OP of every patient in the group with spontaneous CSF leakage was elevated. Other radiological findings frequently seen in IIH include dural ectasias, arachnoid pits, tortuosity of the optic nerves, and increased CSF surrounding the optic nerves. Skull base defects are the most frequent location for spontaneous CSF leaks in patients with clinical and/or radiologic findings of raised ICP, with the ethmoid and the lateral wall of the sphenoid sinus being the most common locations (6). However, there are reports of increased ICP after the repair of spinal spontaneous CSF leaks, suggesting that even spinal CSF leak might be associated with increased ICP (11). Although there aren't any specific studies that address the radiologic findings of the intracranial venous system in patients who have spontaneous CSF leaks, one could expect similar venous changes to those observed in patients with IIH, such as transverse venous sinus stenosis, based on extrapolating the available imaging data. Some authors have even speculated that patients with primary spontaneous CSF leaks may have a variant of IIH (8) due to the similarities in the clinical and radiological presentations of IIH and primary spontaneous CSF leaks.

Despite the conservative management with acetazolamide could have an effect on primary spontaneous CSF rhinorrhea (20), endonasal endoscopic repair still remains as the first-line or gold standard treatment for these leaks at present (21). Due to the potential mechanism of spontaneous CSF rhinorrhea in patients with IIH, it has been established that intermittent spontaneous CSF leaks through the arachnoid pits in the skull base dura was considered as a pressure release (22). When CSF leakage is closed by successful surgical repair, the ICP tends to increase because of blockage of CSF drainage into the nasal cavity, leading to long-term elevated ICP (23).

Untreated elevated ICP would increase the likelihood of recurrence at the same or different site, even after a successful surgical repair (24). There is growing evidence to suggest that in this patient population, adjuvant treatment such as medication or shunting procedures can be beneficial for managing intracranial pressure (22). In patients with evidence of IIH symptoms, the lower ICP may lower the rate of leak recurrence following nasal endoscopic repair (21, 25). Additionally, a recent study revealed that in patients undergoing surgical repair for CSF leakage, postoperative permanent CSF diversion through LPS or VPS can reduce the recurrence rate by 11% (92.82 vs. 81.87%, $P < 0.001$) (26).

It is probably best to advise weight loss in this patient population because elevated BMI is associated with an increased risk of both IIH and primary spontaneous CSF leaks. While there are a few case reports detailing the resolution of spontaneous CSF leaks following bariatric surgery, the data are not yet strong enough to justify treating patients with spontaneous CSF leaks exclusively using this strategy (19, 13).

Our illustrative case report supports the strong literature-supported association between IIH and spontaneous CSF leaks, which further justifies systematic screening for symptoms and signs of increased ICP within weeks following surgical repair of a suspected spontaneous CSF leak. It is necessary to identify these patients as soon as possible in order to avoid papilledema-related visual loss and the failure of the CSF leak repair. Furthermore, IIH patients with consistently elevated ICP probably need to be closely monitored in case a CSF leak develops.

Following repair, therapy to reduce ICP is crucial. Therefore, in all cases of preoperative obesity, we advocate for first-line dietetic, psychological, and endocrine management, if feasible, without delaying surgery, as well as postoperatively. If a patient has severe obesity (BMI greater than 35 kg/m²), postoperative acetazolamide may be started for the first month and continued based on reevaluation. A thorough interview, specific screening for headache and tinnitus, a brain MRI that looks into the venous sinuses, and an ophthalmic examination with fundus and visual field assessment determine the suspicion of ICHT at 4-6 weeks. The assessment's timing is still to be determined, but it seems reasonable to space it out at least 4 weeks to ensure leak closure and physiological CSF excretion/absorption balance, and at most 8 weeks to prevent recurrence through early screening for underlying ICHT without losing track of follow-up.

It seems unnecessary to measure opening pressure on lumbar puncture before repair, as it is generally normalized by the safety-valve effect. To determine a medium- and long-term strategy, it is more crucial to measure it after repair; however, there is currently no conclusive evidence regarding timing. Opening pressure following lumbar puncture has occasionally been determined using a lumboperitoneal shunt implanted during leak closure. However, this early measurement likely underestimates the true opening pressure because of two factors: first, meningeal reaction following recent surgery, which causes CSF to be secreted excessively; and second, a lack of time to adjust to and regularize the new CSF secretion and circulation regime. It seems more reasonable to measure 7-8 weeks after closure since CSF secretion and regulation are stable and endonasal healing is usually accomplished. However, in the event of a severe headache or visual impairment, early measurement may nevertheless be indicated in case of intense headache or visual disorder. Studies are needed to guide the modalities of this monitoring. For ICHT resistant to medical treatment, neurosurgical treatment with a lumboperitoneal or ventriculoperitoneal shunt should be considered. This includes ophthalmic complications with or without chronic headaches, as well as persistently high opening pressure on lumbar punctures. The patient's preference, the neurosurgical experience of the team, potential complications, and the appropriate revision rates based on patient morphotype all play a role in the decision between ventriculoperitoneal and lumboperitoneal drainage. International consensus statements on endoscopic skull-base surgery do not consider perioperative lumbar drainage in endoscopic endonasal repair to be mandatory, despite its controversy (27). There is disagreement over the use of cerebral intravenous stents; the decision is made based on imaging in each individual case. In the event that dietary interventions prove ineffective, bariatric surgery should be assessed.

Conclusion

Although the connection between IIH and spontaneous CSF leak is becoming more and more clear, it is still not entirely understood. It seems reasonable for practitioners to be aware of and counsel patients regarding the possibility of CSF leak in those IIH patients presenting initially to ophthalmology. Additionally, patients who present to otorhinolaryngologists with spontaneous CSF leaks should be considered for ophthalmic evaluation. Pre- and postoperative multidisciplinary teamwork is necessary for the management of spontaneous CSF leaks. Surgery is a necessary but insufficient step because, in addition to treating the leak, the etiologic approach involves treating the underlying cause of the leak. IICHT must not be disregarded in order to prevent recurrence. Consensual terminology and harmonization of procedures before and after leak repair would support multidisciplinary teamwork.

Highlights

- Describe and study the case of a relationship between spontaneous cerebrospinal fluid leak and idiopathic intracranial hypertension
- Highlight the role of the magnetic resonance imaging of the brain in screening for idiopathic intracranial hypertension
- Highlight the role of early detection of idiopathic intracranial hypertension in the overall management of spontaneous defects of the skull base

References

1. Wise SK, Schlosser RJ. Evaluation of spontaneous nasal cerebrospinal fluid leaks. *Curr Opin Otolaryngol Head Neck Surg* 2007; 15:28–34.
2. Pérez MA, Bialer OY, Bruce BB, Newman NJ, Biousse V. Primary spontaneous cerebrospinal fluid leaks and idiopathic intracranial hypertension. *J Neuro Ophthalmol* 2013; 33:330–7.
3. Tam EK, Gilbert AL. Spontaneous cerebrospinal fluid leak and idiopathic intracranial hypertension. *Curr Opin Ophthalmol.* (2019) 30:467–71. doi: 10.1097/ICU.0000000000000603
4. Tang C, Zhu J, Feng K, Yang J, Cong Z, Cai X, et al. Successful treatment of spontaneous cerebrospinal fluid rhinorrhea with endoscopic third ventriculostomy and lumboperitoneal shunt: a case report. *Front Neurosci.* (2020) 14:57. doi: 10.3389/fnins.2020.00057
5. Clark D, Bullock P, Hui T, et al. Benign intracranial hypertension: a cause of CSF rhinorrhoea. *J Neurol Neurosurg Psych.* 1994;57:847–849.
6. Yang Z, Wang B, Wang C, et al. Primary spontaneous cerebrospinal fluid rhinorrhea: a symptom of idiopathic intracranial hypertension? *J Neurosurg.* 2011;115:165–170.
7. Schlosser RJ, Wilensky EM, Grady MS, et al. Elevated intracranial pressures in spontaneous cerebrospinal fluid leaks. *Am J Rhinol.* 2003;17:191–195.
8. Schlosser RJ, Woodworth BA, Wilensky EM, et al. Spontaneous cerebrospinal fluid leaks: a variant of benign intracranial hypertension. *Ann Otol Rhinol Laryngol.* 2006;115:495–500.
9. Suryadevara AC, Fattal M, Woods CI. Nontraumatic cerebrospinal fluid rhinorrhea as a result of pseudotumor cerebri. *Am J Otol.* 2007;28:242–246.
10. Rudnick E, Sismanis A. Pulsatile tinnitus and spontaneous cerebrospinal fluid rhinorrhea: indicators of benign intracranial hypertension syndrome. *Otol & Neurotol.* 2005;26:166–168.
11. Mokri B. Intracranial hypertension after treatment of spontaneous cerebrospinal fluid leaks. *Mayo Clin Proc.* 2002;77:1241–1246.
12. Schlosser RJ, Bolger WE. Significance of empty sella in cerebrospinal fluid leaks. *Otolaryngology--head and neck surgery.* 2003;128:32–38.
13. Wang EW, Vandergrift WA., 3rd Schlosser RJ. Spontaneous CSF Leaks. *Otolaryngol Clinics North Am.* 2011;44:845–856.

14. De Marinis L, Bonadonna S, Bianchi A, et al. Primary empty sella. *J Clin Endocrinol Metab*. 2005;90:5471–5477.
15. Guitelman M, Garcia Basavilbaso N, Vitale M, et al. Primary empty sella (PES): a review of 175 cases. *Pituitary*. 2012 Aug 9;
16. Jindal M, Hiam L, Raman A, et al. Idiopathic intracranial hypertension in otolaryngology. *Eur Arch Oto-Rhino-Laryngol*. 2009;266:803–806
17. Schlosser RJ, Wilensky EM, Grady MS, et al. Cerebrospinal fluid pressure monitoring after repair of cerebrospinal fluid leaks. *Otolaryngology--head and neck surgery*. 2004;130:443–448.
18. Wise SK, Schlosser RJ. Evaluation of spontaneous nasal cerebrospinal fluid leaks. *Curr Opin Otolaryngol & Head and Neck Surg*. 2007;15:28–34.
19. Seth R, Rajasekaran K, 3rd, Luong A, et al. Spontaneous CSF leaks: factors predictive of additional interventions. *Laryngoscope*. 2010;120:2141–2146.
20. Tilak AM, Koehn H, Mattos J, Payne SC. Preoperative management of spontaneous cerebrospinal fluid rhinorrhea with acetazolamide: acetazolamide for spontaneous CSF leaks. *Int Forum Allergy Rhinol*. (2019) 9:265–9. doi: 10.1002/alr.22245
21. Kreatsoulas DC, Shah VS, Otto BA, Carrau RL, Prevedello DM, Hardesty DA. Surgical outcomes of the endonasal endoscopic approach within a standardized management protocol for repair of spontaneous cerebrospinal fluid rhinorrhea. *J Neurosurg*. (2021) 134:780–6. doi: 10.3171/2019.12.JNS192891
22. Tam EK, Gilbert AL. Spontaneous cerebrospinal fluid leak and idiopathic intracranial hypertension. *Curr Opin Ophthalmol*. (2019) 30:467–71. doi: 10.1097/ICU.0000000000000603
23. Tang C, Zhu J, Feng K, Yang J, Cong Z, Cai X, et al. Successful treatment of spontaneous cerebrospinal fluid rhinorrhea with endoscopic third ventriculostomy and lumboperitoneal shunt: a case report. *Front Neurosci*. (2020) 14:57. doi: 10.3389/fnins.2020.00057
24. Campbell RG, Farquhar D, Zhao N, Chiu AG, Adappa ND, Palmer JN. Cerebrospinal fluid rhinorrhea secondary to idiopathic intracranial hypertension: Long-term outcomes of endoscopic repairs. *Am J Rhinol Allergy*. (2016) 30:294–300. doi: 10.2500/ajra.2016.4319
25. Workman AD, Carey RM, Parasher AK, Kuan EC, Godovchik J, Glicksman JT, et al. The fate of the bone graft in cerebrospinal fluid rhinorrhea endoscopic repair for idiopathic intracranial hypertension: a retrospective case series analysis. *Rhinology*. (2017) 55:376–81. doi: 10.4193/Rhino17.147
26. Teachey W, Grayson J, Cho D-Y, Riley KO, Woodworth BA. Intervention for elevated intracranial pressure improves success rate after repair of spontaneous cerebrospinal fluid leaks: Intervention for Elevated ICP. *Laryngoscope*. (2017) 127:2011–6. doi: 10.1002/lary.26612
27. Wang EW, Zanation AM, Gardner PA, et al. ICAR: endoscopic skull-base surgery. *Int Forum Allergy Rhinol* 2019;9:S145–365.