

Original Research Article

**WOUND HEALING POTENTIAL OF DICHLOROMETHANE LEAVE EXTRACT OF
Heterotis rotundifolia LEAVES IN FEMALE WISTAR RATS**

ABSTRACT

*This study was conducted to evaluate the effect of topical application of dichloromethane extract of *Heterotis rotundifolia* leaves on the iron, estrogen levels, haematology parameters and rate of wound healing closure. Excision wound (2cm) was induced on the dorsal skin of 75 wistar rats (176-308g) divided into five groups: control, 0.1g Vaseline, 0.1g gentamicin (reference drug), 0.1g extract+0.1g Vaseline (HRE1) and 0.2g extract+0.1g Vaseline (HRE2). At the end of days 1, 7, 14 and 21, rats were sacrificed and blood were collected for wound healing parameters. The iron level of HRE1 significantly decreased from days 1-21 with a significant difference ($p<0.05$) on day 14 compared to control and day 21 compared to gentamicin. Estrogen level showed a significant decrease with higher levels observed on day 7 for control and vaseline groups and on day 14 for gentamicin, HRE1 and HRE2. The haematological profile revealed an increase in PCV, Hb and RBC levels +and significant decrease in the Neutrophil concentration. Rate of wound healing (%) in HRE1 showed a higher value with complete healing compared to control and gentamicin. *Heterotis rotundifolia* leaves promotes dermal wound healing with blood boosting properties.*

Keywords: *Heterotis rotundifolia* leaves, wound healing, estrogen and haematology.

INTRODUCTION

A wound is a disruption of cellular and anatomic continuity in a tissue, accompanied or unaccompanied by microbial infection. Wounds may be created by physical, chemical, thermal, microbial, or immunological damage to the tissues [1][2][3]. Wound healing is the integration of a complex cascade of biological processes occurring in a sequential overlapping manner characterized by four phases; homeostasis, inflammation, proliferation and remodelling towards the regeneration and repair of lost tissue [4][5]. Homeostasis begins when the injury occurs in skin or tissues leading to the damage of blood

vessels. The damaged blood vessels and adjacent arteries initiate the vasoconstriction process. Homeostasis usually lasts for few hours [5]. Inflammatory phase begins the healing process after bleeding has been controlled and usually occurs from hours to days. It is depicted by *rubor* (redness), *calor* (warmth), *tumor* (swelling), *dolor* (pain), and *functio laesa* (loss of function). [4]. Inflammatory phase involves the recruitment of neutrophils and monocytes for the removal of foreign materials, bacteria and non-functional host cells. The proliferative phase usually lasts between 4 days through three weeks. During this phase, endothelial cells, keratinocytes, fibroblast, granulation tissue formation, and collagen III deposition, angiogenesis, epidermal resurfacing, wound closure and contraction take place and are regulated by FGF, TGF- and vascular endothelial growth factor (VEGF) [5]. The last phase which is remodeling occurs eight days to two years and represented by scar tissue. It comprises the remodelling and alignment of collagen tissue to yield a greater tensile strength. The major cell involved is the fibroblast [5]. Wound healing is the integration of a complex cascade of cellular and biochemical process in which the normal structure and function of the damaged tissue is restored. The process of healing is a natural event by which the body itself overcomes the damage to its tissue [1].

The synthetic drugs currently used to treat wounds are not only expensive but also have problems such as allergies and drug resistance, leading scientists to explore alternative treatments [6]. As a result, researchers are making efforts to discover effective pro-healing agents that could reduce cost, eliminate prolonged treatment and prevent the patient from undergoing amputation or severe complications. Most drug formulations and ointments employed in wound care are products of medicinal plants. Medicinal plants are still used by over 80% of the world's population to treat ailments [7], especially when managing wounds [8]. By providing a moist environment, they foster the development of appropriate wound healing conditions.

Heterotis rotundifolia, commonly known as pink lady is employed in folkloric medicine in most parts of East and West Africa [9]. Traditionally, different parts of the plant are utilized in the treatment of various ailments. The leaves are used in the treatment of diarrhoea, dysentery, stomach ache, cough, stop abortion, conjunctivitis, circulatory problems [10][11][12] whole plant is used for treating trypanosomiasis by Nupe people of Nigeria [13].

In Nigeria, the wound healing potentials of most herbal plants are yet to be discovered. Thus, people are still ignorant on some of the health benefits of medicinal plants grown in rural areas. These herbal plants

utilized in wound healing are most times safe, cheap and affordable. Thus, the problem of this study is to determine the wound healing potentials of *Heterotisrotundifolia* leaves on female wistar rats.

MATERIALS AND METHODS

Preparation of plant samples

Freshly harvested leaves of *Heterotis rotundifolia* were gotten from within Abuja campus, University of Port Harcourt. Samples were identified and authenticated by a botanist at the Department of Plant Science and Biotechnology, University of Port Harcourt Herbarium with voucher number UPH/V/1323. The detached leaves from the collected plant materials were washed carefully under running tap water and air-dried for 28 days at room temperature. The dried leaves ground into powder using a grinding mill.

Chemicals and reagents

All chemicals and reagents used were of standard analytical grade

Drug used

Gentamicin ointment (Drugfield Pharmaceuticals Limited, Ogun state, Nigeria)

Preparation of extract

The powdered leaves (477.12g) were placed in a maceration flask and 1000ml of 70% dichloromethane solvent was added. The mixture was left for 3 days at room temperature and stirred 2-3 times a day. The mixture was filtered with Whatman No. 1 filter paper and the clear solution was concentrated with rotary evaporator at 45°C and later transferred to evaporating dish placed on a water bath. The final extract obtained was weighed (26.14g dry weight), stored, labeled in screw-capped bottle and kept at room temperature for further studies.

Experimental animals and design

75 wistar albino rats weighing between 176-307g were purchased from the Department of Pharmacology and Toxicology animal house. Animals were divided into five groups of five rats and were acclimatized for one week. The animals were fed standard pellet diet and water *ad libitum*. Topical administration of animals in each group was as follows:

| Group | Treatment |
|----------------|---|
| Control | Untreated animals (natural healing) |
| Vaseline | Animals treated with Vaseline (vehicle control) |
| Gentami cin | Animals treated with gentamicin (reference drug) |
| HRE1 | Animals treated with 0.1g extract + 0.1g Vaseline |

Wound creation

Partial thickness excision wound (2cm) was induced on the dorsal skin of each animal, according to [4] with little modifications.

Determination of Iron

Estrogen level was determined using Nitro-Paps Method-Monoreagent.

Determination of Estrogen

Iron level was determined using Estradiol AccBind™ Microplate ELISA Test system.

Haematology

Blood samples were taken from these animals on the 1st, 7th, 14th and 21st day into EDTA bottles for haematological analysis such as packed cell volume (PCV), Haemoglobin (Hb), red blood cells (RBC), white blood cells (WBC), Platelet count (PLT), Neutrophil (Neu), Eosinophil (Eosi), Lymphocytes (Lym) and Monocytes (Mono). The PCV was determined by microhaematocrit method, Hb concentration was measured calorimetrically by cyanmethaemoglobin method, RBC count was done by haemocytometry, WBC and PLT were determined using Neubauer counting chamber while Neut, Eosi, Lym and Mono were determined by manual differential count.

Rate of wound healing

The rate of wound healing, that is, percentage of wound reduction from the original wound was calculated using the formula [14] with little modification.

$$\% \text{ Rate of wound healing} = \frac{\text{initial wound area} - \text{wound area } n\text{th day (7,14,21)}}{\text{initial wound area}} \times 100\%$$

STATISTICAL ANALYSIS

Values were expressed as means ± standard Error Mean (SEM). One way ANOVA was used to test for differences between treatment groups using statistical package for social sciences (SPSS) version 22. The results were considered significant at $p < 0.05$.

RESULTS

Iron level

Comparison of the iron level of vaseline, gentamicin, HRE1 and HRE2 with control revealed a significant difference ($p < 0.05$) in vaseline, gentamicin and HRE1 on day 1, all groups were statistically significant ($p < 0.05$) on day 7 and day 14, while on day 21, there was a statistical difference ($p < 0.05$) in gentamicin

and HRE2. For comparison of vaseline, HRE1 and HRE2 with gentamicin, there was a significant difference ($p < 0.05$) in HRE2 on day 1, significant difference ($p < 0.05$) in Vaseline and HRE2 on days 7 and 14, and on day 21, a significant difference occurred in all groups.

Table 1: Effect of dichloromethane extract of *H. rotundifolia* leaves on Iron level (g/L) of wound treated wistar albino rats

| Group | Day 1 | Day 7 | Day 14 | Day 21 |
|------------|-------------------------|---------------------------|---------------------------|---------------------------|
| Control | 31.57±0.35 ^b | 31.33±0.48 ^b | 41.33±0.88 ^b | 27.33±1.20 ^b |
| Vaseline | 37.80±0.46 ^a | 28.40±0.31 ^{a,b} | 37.33±0.88 ^{a,b} | 22.67±1.45 ^b |
| Gentamicin | 37.27±0.67 ^a | 33.10±0.38 ^a | 30.33±0.88 ^a | 40.00±0.58 ^a |
| HRE1 | 37.90±0.21 | 31.77±0.59 | 29.00±0.58 ^a | 24.33±1.20 ^b |
| HRE2 | 31.07±0.88 ^b | 38.70±0.67 ^{a,b} | 25.67±0.33 ^{a,b} | 36.67±0.88 ^{a,b} |

Data expressed as mean ± SEM (n=5). Values with different superscripts are statistically different at $p < 0.05$. Values without superscripts are not statistically significant at $p < 0.05$. Superscript a is statistically different ($p < 0.05$) when control was compared with Vaseline, gentamicin and HRE 1 and HRE 2 on 1, 7 14, and 21 days. Superscript b is statistically different ($p < 0.05$) when gentamicin was compared with Vaseline, HRE 1 and HRE 2 on 1, 7, 14 and 21 days.

Estrogen level

Comparison of the estrogen level of rats in Vaseline, gentamicin, HRE1 and HRE2 with control group revealed a significant difference ($p < 0.05$) in Vaseline, gentamicin and HRE2 for all days and a significant difference ($p < 0.05$) in HRE1 for all days except on day 21. For comparison of vaseline, HRE1 and HRE2 with gentamicin, there was a significant difference ($p < 0.05$) in HRE1 and HRE2 on all days and on days 1 to 14 in vaseline.

Table 2: Effect of dichloromethane extract of *H. rotundifolia* leaves on Estrogen level (g/L) of wound treated wistar albino rats

| Group | Day 1 | Day 7 | Day 14 | Day 21 |
|---------|------------|------------|------------|------------|
| Control | 46.67±0.88 | 81.67±2.19 | 35.67±0.88 | 23.67±0.88 |

| | | | | |
|------------|---------------------------|---------------------------|----------------------------|---------------------------|
| Vaseline | 50.33±0.88 ^{a,b} | 90.67±0.88 ^{a,b} | 40.33±0.88 ^{a,b} | 34.00±1.15 ^a |
| Gentamicin | 43.67±0.33 ^a | 63.00±1.15 ^a | 64.67±0.88 ^a | 33.00±1.15 ^a |
| HRE 1 | 22.67±0.88 ^{a,b} | 46.33±0.88 ^{a,b} | 55.33±1.20 ^{a,b} | 27.33±1.20 ^b |
| HRE 2 | 15.00±1.15 ^{a,b} | 39.67±0.88 ^{a,b} | 111.67±2.19 ^{a,b} | 38.33±0.88 ^{a,b} |

Superscript a is statistically different ($p < 0.05$) when control was compared with Vaseline, gentamicin and HRE 1 and HRE 2 on 1, 7, 14, and 21 days. Superscript b is statistically different ($p < 0.05$) when gentamicin was compared with Vaseline, HRE 1 and HRE 2 on 1, 7, 14, and 21 days.

Haematology

Significant increase ($p < 0.05$) were observed in RBC, Hb and Mono from day 7 in HRE1 and WBC in HRE2. Significant decrease ($p < 0.05$) was observed for neutrophil concentration in HRE2.

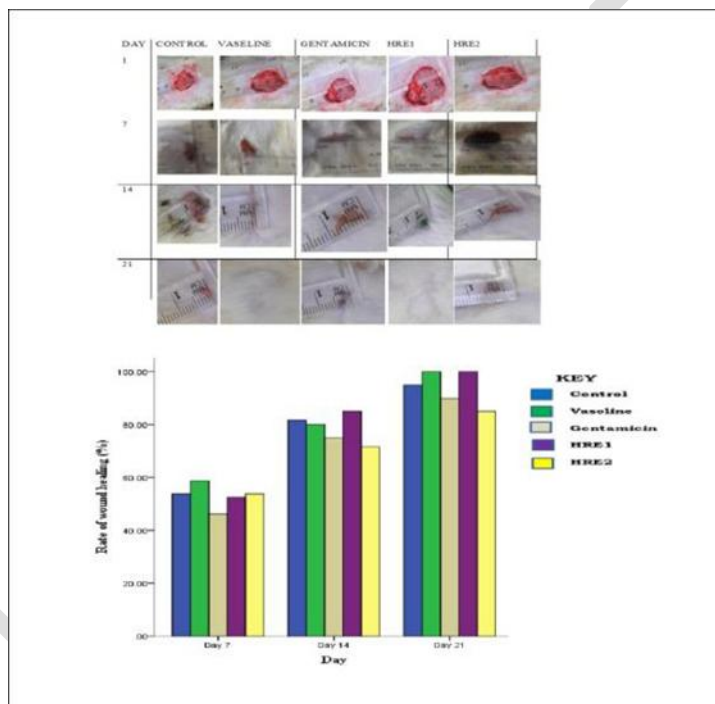


Figure 1: Effect of dichloromethane extract of *H. rotundifolia* leaves on rate of wound healing (%) of wound treated wistar albino rats

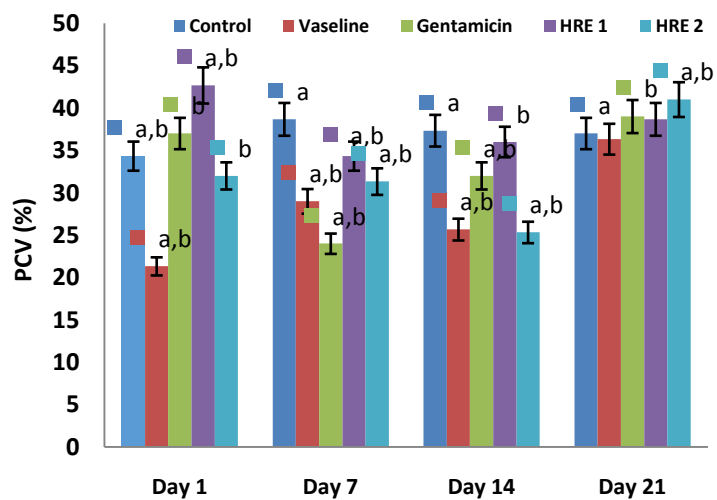


Figure 2: Effect of dichloromethane extract of *H. rotundifolia* leaves on Hb concentration of wound treated wistar albino rats

a is significantly different ($p < 0.05$) when control was compared with vaseline, gentamicin and HRE1 and HRE2. **b** is significantly different ($p < 0.05$) when gentamicin was compared with vaseline, HRE1 and HRE2

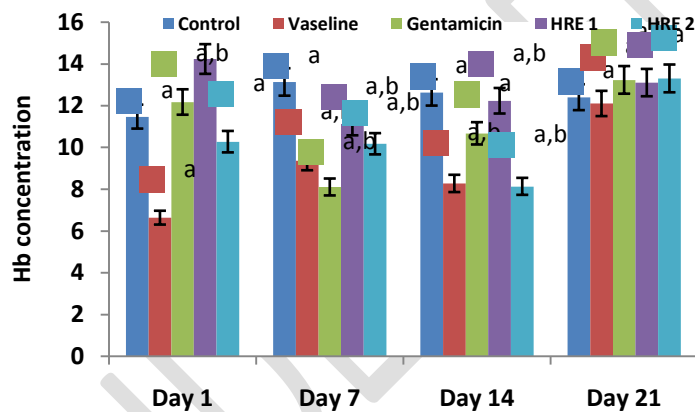


Figure 3: Effect of dichloromethane extract of *H. rotundifolia* leaves on Packed Cell Volume, PCV (%) level of wound treated wistar albino rats

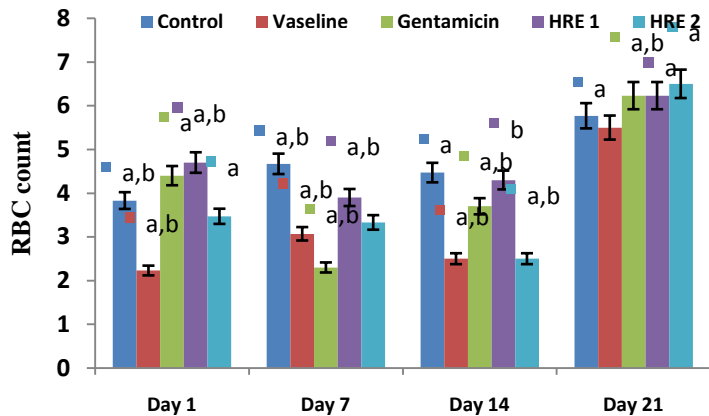


Figure 4: Effect of dichloromethane extract of *H. rotundifolia* leaves on RBC count of wound treated wistar albino rats

a is significantly different ($p < 0.05$) when control was compared with vaseline, gentamicin and HRE1 and HRE2. **b** is significantly different ($p < 0.05$) when gentamicin was compared with vaseline, HRE1 and HRE2.

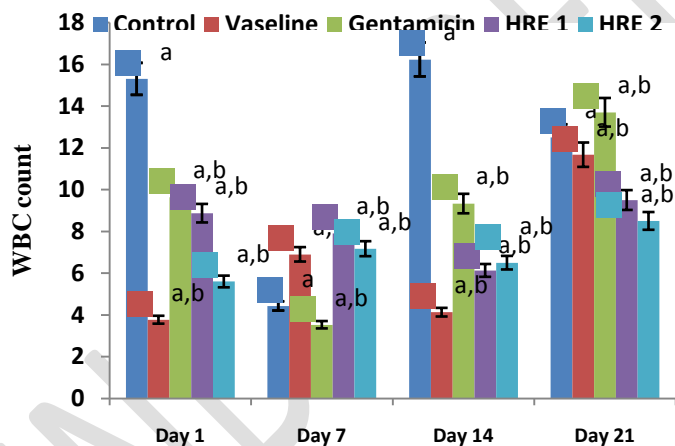


Figure 5: Effect of dichloromethane extract of *H. rotundifolia* leaves on WBC count of wound treated wistar albino rats

a is significantly different ($p < 0.05$) when control was compared with vaseline, gentamicin and HRE1 and HRE2. **b** is significantly different ($p < 0.05$) when gentamicin was compared with vaseline, HRE1 and HRE2.

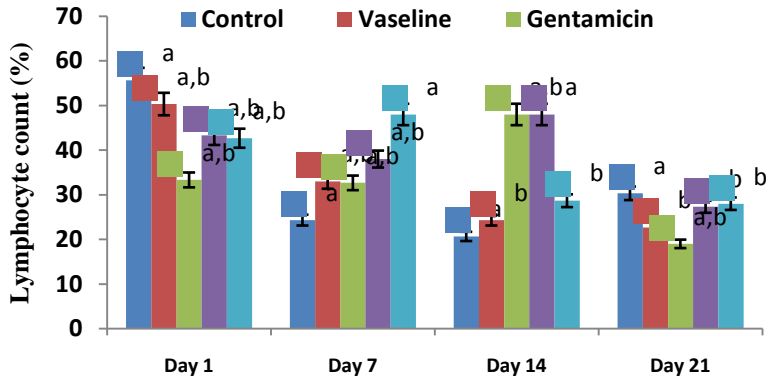


Figure 6: Effect of dichloromethane extract of *H. rotundifolia* leaves on Lymphocyte count (%) of wound treated wistar albino rats

a is significantly different ($p < 0.05$) when control was compared with vaseline, gentamicin and HRE1 and HRE2. b is significantly different ($p < 0.05$) when gentamicin was compared with vaseline, HRE1 and HRE2.

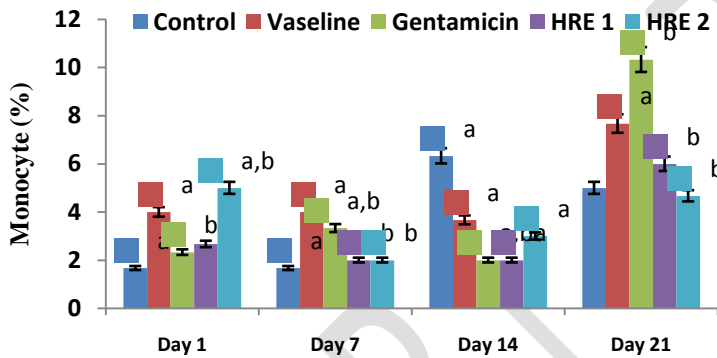


Figure 7: Effect of dichloromethane extract of *H. rotundifolia* leaves on Monocyte (%) of wound treated wistar albino rats

a is significantly different ($p < 0.05$) when control was compared with vaseline, gentamicin and HRE1 and HRE2. b is significantly different ($p < 0.05$) when gentamicin was compared with vaseline, HRE1 and HRE2

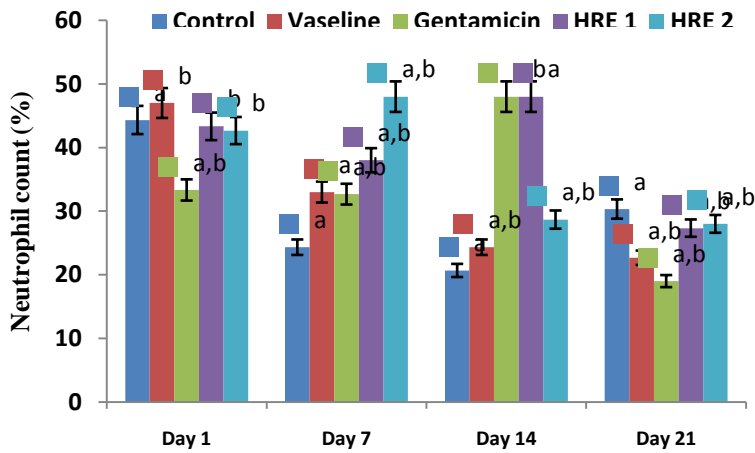


Figure 8: Effect of dichloromethane extract

of *H. rotundifolia* leaves on Neutrophil count of wound treated wistar albino rats

a is significantly different ($p < 0.05$) when control was compared with vaseline, gentamicin and HRE1 and HRE2. **b** is significantly different ($p < 0.05$) when gentamicin was compared with vaseline, HRE1 and HRE2.

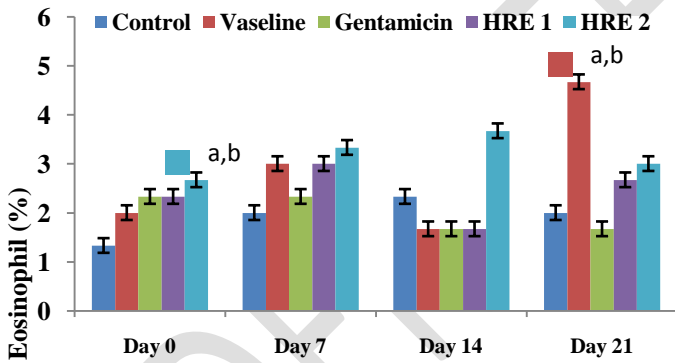


Figure 9: Effect of dichloromethane extract of *H. rotundifolia* leaves on Eosinophil (%) of wound treated wistar albino rats

a is significantly different ($p < 0.05$) when control was compared with vaseline, gentamicin and HRE1 and HRE2. **b** is significantly different ($p < 0.05$) when gentamicin was compared with vaseline, HRE1 and HRE2.

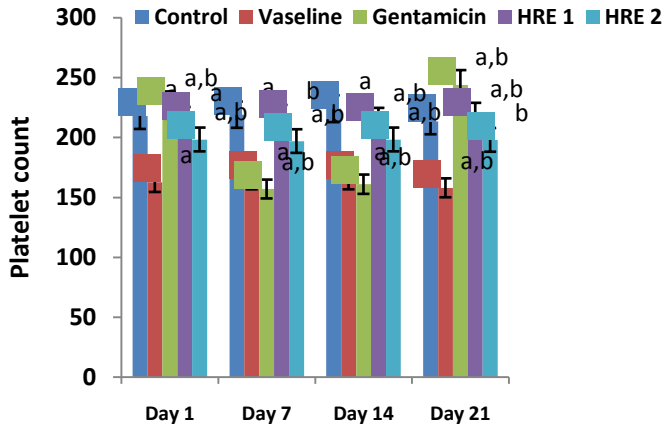


Figure 10: Effect of dichloromethane extract of *H. rotundifolia* leaves on Platelet count of wound treated wistar albino rats

a is significantly different ($p < 0.05$) when control was compared with vaseline, gentamicin and HRE1 and HRE2. **b** is significantly different ($p < 0.05$) when gentamicin was compared with vaseline, HRE1 and HRE2.

Rate of wound healing (%)

The wound size and rate of healing in rats treated with dichloromethane extract of *H. rotundifolia* leaves (Figure 1). The result revealed an observable reduction in the wound healing size and significant increase in rate of healing in all groups. Also complete healing was observed in vaseline and HRE 1 groups within 21 days. There were no statistically significant changes ($p > 0.05$) in the rate of wound healing across all the groups during the study period. There was no statistical difference ($p < 0.05$) between control and other groups and between gentamicin and Vaseline, HRE1 and HRE2.

DISCUSSION

This study disclosed a significant decrease ($p < 0.05$) in the Iron level (Table 1) of the test animals in HRE2 when compared to the control and gentamicin groups. This result points to a probable consequence of the metabolic activities of the body and that of the wounded tissue.

Science has revealed that aging is accompanied with delayed wound healing. The fundamental cause of this delay in wound healing is decreased level of circulating estrogen [15]. The Estrogen level (Table 2) of the wound treated rats revealed a significant ($p < 0.05$) decrease in all groups with higher levels observed on day 7 for control and Vaseline and on day 14 for gentamicin, HRE1 and HRE2. This therefore indicates that faster rate of wound healing was observed where estrogen levels were higher.

The haematological profile of the test animals stipulated that topical administration of *H. rotundifolia* leaves extract inferred a remarkable increase in PCV, Hb and RBC levels. The report of [16] clearly states that erythropoietin plays a key function in accelerating skin wound healing process by enhancing formation of granulation tissue, angiogenesis, collagen and extracellular matrix formation.

Lymphocytes are defined as the major effector cells of the immune system. The remarkable increase in lymphocyte level points out that the extract enhanced the level of effector cells thereby boosting the immune system [17].

Treatment of *H. rotundifolia* leaves had no remarkable effect on the white blood cell count and Eosinophil levels. The Platelet and Neutrophil levels revealed a significant decline ($p < 0.05$) as wound healing progresses. Platelets are blood components responsible for controlling bleeding by clumping and clogging blood vessel injuries and blood clotting. The greater concentration of platelet observed on day 1 indicates that sufficient amount of platelet migrated to the wound area during the homeostatic phase while the greater concentrations of neutrophils observed at the early period for all groups also indicates that large concentration of neutrophils migrated to the wound site during the inflammatory phase and gradually decreased as wound healing progresses. As stated in the study of [18] remarkable ($p < 0.05$) decline in neutrophil and platelet count as seen in this work may be major influence in early wound healing of experimental animals.

The wound healing size indicated a significant reduction in all groups. Complete healing occurred in Vaseline and HRE1 on day 21. Wound closure is based on contraction which takes place during the proliferation (tissue regrowth) phase. Collagen is needed in this phase as it is accountable for the formation of new tissues. According to [19], contraction generates into reduction in wound size, estimated from end to end along an incision. Wound contraction is also as a result of fibroblasts that congregate near the edge of the wound, pulling the wound edges together [20]. [19] also detailed that delay in wound contraction could be because of radiation and drug which inhibit cell division. The delay in wound contraction in Gentamicin and HRE2 could be because of the drug effect or unknown factor(s).

Early red scar formation was also seen, indicating normal healing. According to [21] cutaneous scars have no epidermal appendages and the collagen pattern is apparently different from unwounded skin. The red scar appearance is because of dense capillary network induced at the site of wound.

CONCLUSION

In conclusion, the study reveals that *H. rotundifolia* leaves possess blood boosting and wound healing potentials.

REFERENCES

1. Sabale, P., Bhimani, B., Prajapati, C. and Sabale, Y. (2012). An overview of medicinal plants as wound healers. *Journal of Applied Pharmaceutical Sciences.*, 2(11):143-150.
2. Firdous, S.M and Sautya, D. (2018). Medicinal plants with wound healing potential. *Journal of Bangladesh Pharmacological Society (BDPS).*, 13(1):41-52.
3. Ofusori, A.E., Raharjo, Y., Ofusori, D.A. and Adekunle, V.O. (2023). A comparative study of dichloromethane and ethylacetate root extract of *Celosia trigyna*: Phytochemical and wound healing effect analyses. *Journal of Wound Management and Research.*, 19(2):87-95.
4. Zaki, M.Z.M, Hamid, A. and Latiff, M.A. (2011). Effects of *Alocasia Sp.* Stem juice on open wound healing in rats. *Advances in Environmental Biology.*, 5(12):3734-3742.
5. Parkar, H. (2016). Wound healing potential of *Terminalia sericea*. (Master of Science dissertation).
6. Subramanian S, Sathish Kumar D, Arulselvan P (2006). Wound healing potential of Aloe vera leaf gel studied in experimental rabbits. *Asian J Biochem* 1:178–185.
7. Ekor, M (2014) The growing use of herbal medicines: issues relating to adverse reactions and challenges in monitoring safety. *Front. Pharmacol.* 4(177):1-10.
8. Purna, S. K and Babu, M (2000). Collagen based dressings- a review. *Burn.* 26(1):54-62.
9. Yeboah, O.K. and Osafo, N. (2017). Review of the ethnomedical, phytochemical, pharmacological and toxicological studies on *Dissotis rotundifolia* (Sm.) Triana. *Journal of Complementary and Alternative Medical Research.*, 2(3): 1-11.
10. Abere, T. A., Onwukaeme, D. N., Eboka, C. J. (2009). Pharmacognostic evaluation of the leaves of *Dissotis rotundifolia* Triana (Melastomataceae). *African Journal of Biotechnology.*, 8(1): 113-115.
11. Noumi, E. and Yomi, A. (2001). Medicinal plants used in intestinal diseases in Mbalmayo Region. *Fitoterapia.*, 72(3):246–254.
12. Amri, E and Kisangau, D.P. (2012). Ethnomedicinal study of plants used in villages around Kimboza forest reserve in Morogoro, Tanzania. *Journal of Ethnobiology and Ethnomedicine.*, 8:1.

13. Mann, A. and Ogbadoyi, E.O.(2012). Evaluation of Medicinal Plants from Nupeland for Their *in vivo* Antitrypanosomal Activity. *American Journal of Biochemistry*., 2(1): 1-6.
14. Lin, T.S., Latiff, A.A., Hamid, A.A., Ngah, W.Z.W. and Mazlan, M. (2012). Evaluation of topical tocopherol cream on cutaneous wound healing in streptozotocin-induced diabetic rats. *Evidenced-Based Complementary and Alternative Medicine*.,Pp: 1-6.
15. Čriepoková, Z. L, Lenhardt, L. L. and Gál, P. (2016). Basic roles of sex steroid hormones in wound repair with focus on estrogens (A review). *Folia veterinaria*, 60(1): 41-46.
16. Haroon Z A., Amin, K., Jiang, X and Arcasoy, M. O.A. (2003). Novel role for erythropoietin during fibrin-induced wound healing response. *American Journal of Pathology*.163(3):993–1000.
17. Ashafa, A.O.T., Sunmonu, T. & Afolayan, A.J. (2011). Effects of leaf and berry extracts of *Phytolacca dioica* L. on haematological and weight parameters of wistar rats. *African Journal of Pharmacy and Pharmacology*, 5(2):150-154.
18. Olaiya, A.K. (2016). Effect of the aqueous extract of *Moringa oleifera* leaves on epidermal wound healing in the domestic rabbit. *International Journal of Livestock Research*, 6(7): 44-50.
19. Simon, P.E., Al Moutran, H, Romo, T., Pafford, W., Pearson, J. M., Yalamanchili, H. & Zoumalan, R.A. (2016). Skin Wound Healing. *Medscape*. Available online: <http://emedicine.medscape.com/article/884594-overview#showall> (accessed on 24 January 2019).
20. Flanagan, M. (2000). The physiology of wound healing. *Journal of Wound Care*., 9(6):299-300.
21. Sorg, H., Tilkorn, D.j., Hager, S., Hauser, J. and Mirastschijiski, U. (2017). Skin wound healing: An update on the current knowledge and