

Case report

Liver metastasis of gallbladder cancer with portal venous tumor thrombosis

ABSTRACT

Aims: Gallbladder cancer (GBC) is associated with a poor prognosis in terms of biliary malignancies. Many patients with GBC patients develop liver metastasis and hepatoduodenal ligament involvement because of difficulties in early diagnosis. Herein, we report a case of GBC with liver metastasis, complicated with portal venous tumor thrombosis (PVTT).

Presentation of case: An 87-year-old male patient was referred to our hospital with a persistent fever. Contrast-enhanced computed tomography (CE-CT) and Gadolinium ethoxybenzyl diethylenetriamine pentaacetic acid-enhanced magnetic resonance imaging (EOB-MRI) revealed multiple ring-enhancing space-occupying lesions at liver segments 4 and 5, and tumor thrombosis from segment 4, adjacent to the umbilical portion of portal vein, with gallbladder wall thickening. Subsequently, extended left lobectomy with cholecystectomy was performed, and postoperative histopathological examination revealed gallbladder cancer with multiple liver metastases and PVTT. The patient was discharged after 22 days of postoperative recovery without any symptoms. However, multiple recurrent liver tumors were confirmed on CE-CT after 42 days of hepatectomy.

Discussion and Conclusion: GBC liver metastasis with PVTT is rare but has aggressive clinical features and needs careful multidisciplinary treatment planning.

Keywords: Gallbladder cancer; Hepatectomy; Metastatic liver tumor; Portal venous tumor thrombosis.

1. INTRODUCTION

Gallbladder cancer (GBC) has a poor prognosis in terms of biliary malignancies [1]. Although surgical resection is the only curative treatment, it may provide an unsatisfactory prognosis in advanced-stage disease [2, 3, 4].

Difficulties in early diagnosis result in many patients with GBC developing liver metastasis or hepatoduodenal ligament involvement. Advanced GBC malignancies had various symptoms, such as pain, jaundice, and [5]. In addition, coagulopathy and thromboembolism are also cancer-related symptoms in advanced GBC [6]. Portal venous tumor thrombosis (PVTT) arising from GBC is rare; however, three cases have been reported [7].

We report a surgically treated case of GBC liver metastasis with portal venous tumor thrombosis, a rare presentation of GBC extension.

2. CASE PRESENTATION

An 87-year-old male patient was referred to our hospital from a regional hospital because of persistent fever. He had no history of any significant comorbidities. The patient complained of right-sided hypochondrial pain and tenderness. Blood examination indicated inflammatory changes (white blood cell count: 5800/ μ L [reference, 3300–8600/ μ L] and C-reactive protein levels: 12.41 mg/dL [reference, 0.00–0.14 mg/dL]) with mild liver dysfunction (alkaline phosphatase: 196 U/L [reference, 38–113 U/L], gamma-glutamyl transferase levels: 109 U/L [reference, 13–64 U/L]) and elevation of cancer antigen 19-9 (CA19-9): 125.6 U/ml [reference, 0.0–37.0 U/ml]). Gadolinium ethoxybenzyl diethylenetriamine pentaacetic acid-enhanced magnetic resonance imaging (EOB-MRI) revealed multiple liver space-occupying lesions (SOL) without liquefaction (Figure 1). Contrast-enhanced computed tomography (CE-CT) indicated multiple liver tumors with portal venous tumor thrombosis (PVTT) from segment 4, adjacent to the umbilical portion, with GB wall thickening (Figure 2). Therefore, the preoperative diagnosis was intrahepatic cholangiocarcinoma (ICC) with portal venous thrombosis. The wall thickening of the GB fundus was diagnosed as adenomyomatosis.

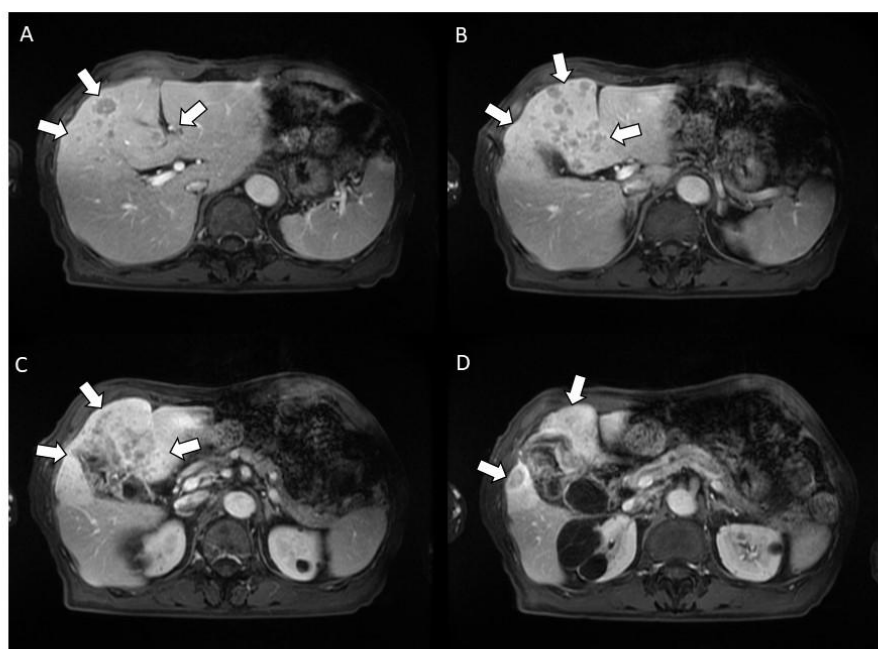


Figure 1

Fig. 1. An EOB-MRI reveals multiple ring-enhancing space-occupying lesions without liquefaction (white arrow).

EOB-MRI, gadolinium ethoxybenzyl diethylenetriamine pentaacetic acid-enhanced magnetic resonance imaging

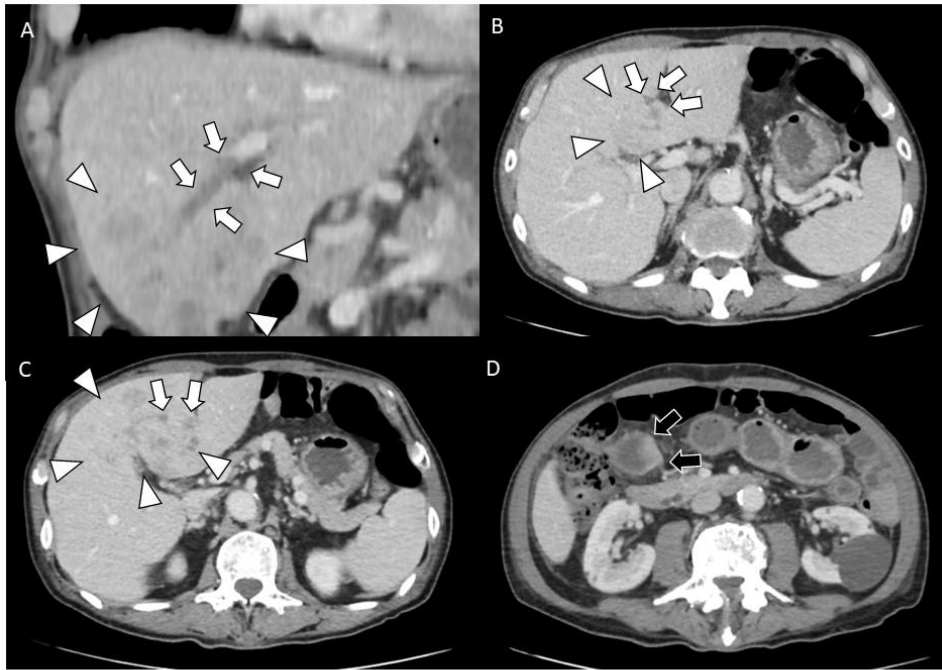


Figure 2

Fig. 2. Contrast-enhanced abdominal CT indicates multiple liver tumors at segments 4 and 5 (white arrowhead), with portal venous thrombosis adjacent to the umbilical portion (white arrow) and wall thickening of the fundal side of the gallbladder (black arrow).

CT, computed tomography

Following detailed information about the treatment protocol, the patient and his family consented to surgery to curtail cancer-related symptoms, including fever. During laparotomy, the GB showed whitish wall thickening with dimpling of the fundus. In addition, multiple masses in liver segments 4 and 5 with PVTT were confirmed using intraoperative ultrasonography. The patient underwent extended left hemihepatectomy, including the ventral portion of segment 5, and cholecystectomy.

Postoperative histopathological examination revealed poorly differentiated adenocarcinoma of the GB fundus. Moreover, multiple liver metastases with portal venous tumor thrombosis and perihilar lymph node metastases were identified (Figure 3).

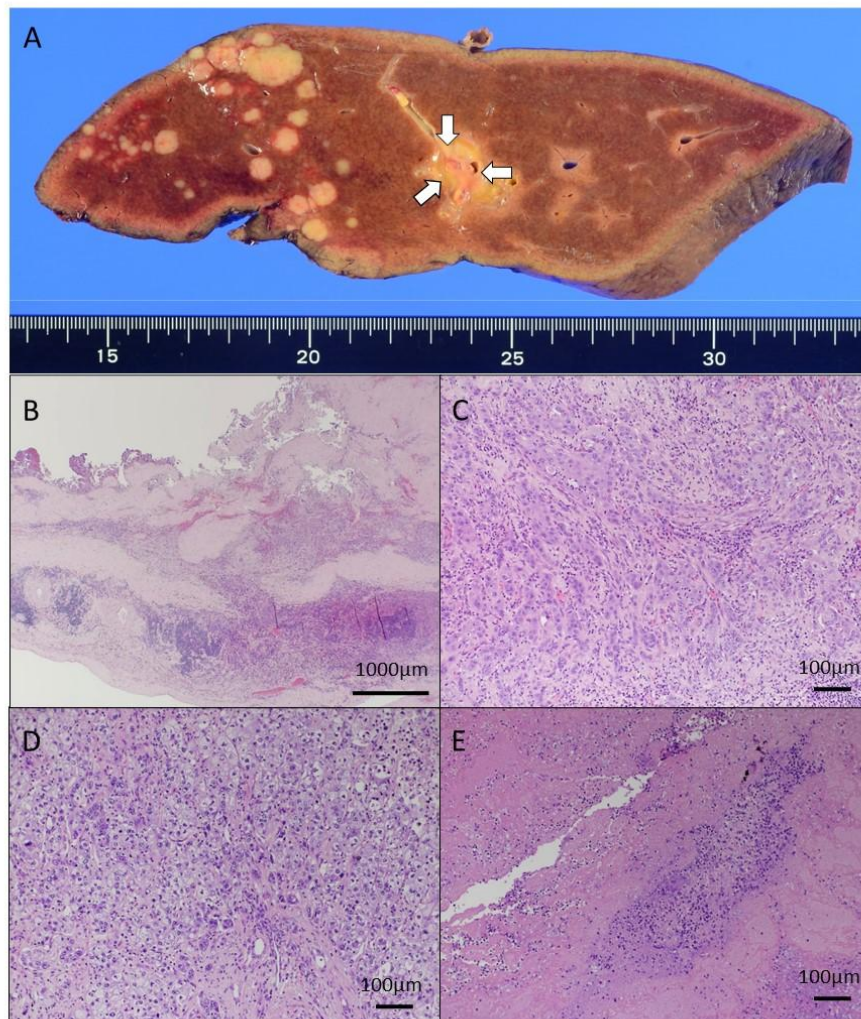


Figure 3

Fig. 3. In resected specimen, portal venous tumor thrombosis, adjacent to umbilical portion is observed macroscopically (A: white arrow). Postoperative histopathological examination depicts poorly differentiated adenocarcinoma at the fundus of the gallbladder (B: low-power field, C: high-power field). Additionally, multiple liver metastases (D: high-power field) and portal venous tumor thrombosis are confirmed histopathologically (E: high-power field).

After 22 days of recovery, the patient was discharged without any complications. Adjuvant therapy was not administered because of the patient's age. Contrast-enhanced CT performed 42 days after the hepatectomy revealed ascites with multiple recurrent tumors in the residual liver (Figure 4). The patient and his family returned to the referral hospital. The patient died of cancer cachexia after 101 days post-surgery.

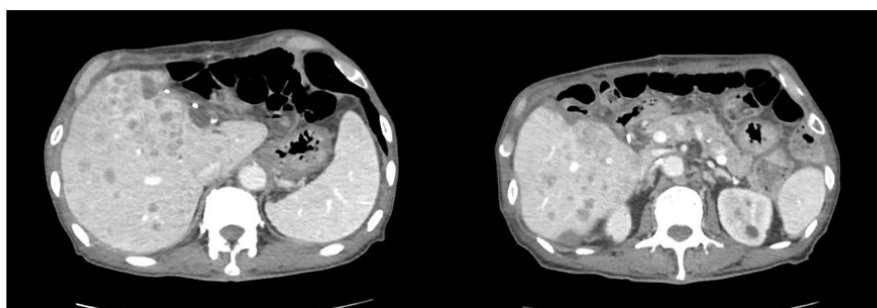


Figure 4. Contrast-enhanced CT 42 days after hepatectomy reveals ascites with multiple recurrent tumors in the residual liver.

CT, computed tomography

3. DISCUSSION

Regarding biliary malignancies, GBC has a poor prognosis owing to difficulties in early diagnosis [1]. Although the only curative treatment is surgical resection, the prognosis may be unsatisfactory in advanced-stage disease [2, 3, 4]. In the advanced stages of GBC, tumors cause various symptoms [5]. Coagulopathy and thromboembolism are other cancer-related symptoms [6].

In the present case, PVTT in segment four developed in the umbilical portion of the portal vein. Therefore, an extended left hemihepatectomy was performed to excise the PVTT of the umbilical portion. Initially, we expected pure tumor thrombosis to reflect the aggressive behavior of the tumor. Based on the histopathological findings in this case, PVTT consisted of a clot with a few tumor cells. These findings suggest aggressive features and GBC tumor extension, along with coagulopathy due to advanced GBC.

Previous reports described coagulopathies caused by GBC [6, 7]. Advanced malignant diseases, such as pancreatic cancers, stomach, brain, lymphomas, and metastatic diseases, induce marked coagulopathy and thromboembolism [8, 9]. PVTT usually carries a high risk of further tumor dissemination to the liver parenchyma, resulting in an inability to perform curative surgical resection [10]. Additionally, anticancer therapy exacerbates the prothrombotic state via endothelial cell activation [11]. Thus, anticancer therapy may have further expanded PVTT. We performed a major hepatectomy without any preoperative anticancer or anticoagulant therapy in this case.

PVTT is rare in GBC, with only 3 cases [7, 12, 13]. To our knowledge, this is the first reported case of PVTT at the site of liver metastasis in GBC. In cases of GBC with PVTT, early and prompt diagnosis is imperative to improve prognosis. Preoperative abdominal CE-CT and

CE-MRI are essential for an accurate preoperative diagnosis [7]. A combination with CT angiography is advantageous (CTA). With recent improvements in imaging studies, we can easily identify PVTT using CE-CT and CE-MRI. Therefore, CTA was deemed unnecessary.

Zhang et al. treated GBC with PVTT via surgery and adjuvant chemotherapy and concluded that early diagnosis and an adequate multidisciplinary approach with complete resection are crucial [7]. In this case, the patient was considered too old to undergo adjuvant therapy. Moreover, complete resection could not be achieved because of the widespread tumor presence; all these factors may have contributed to the early recurrence. In case of elderly patients with poor performance status, surgical resection could not be recommended for higher risk of postoperative complications. In such case, chemotherapy is also not recommended, because its adverse effects sometimes cause serious conditions. Thus, therapeutic strategy should be carefully planned according to the patient's condition.

Usually, cases of advanced GBC with synchronous liver metastases are contraindicated for radical surgery because of poor prognosis despite the high invasiveness of hepatectomy [14, 15]. In the present case, the preoperative clinical diagnosis was primary liver cancer, including intrahepatic cholangiocarcinoma (ICC) with portal vein thrombosis and intrahepatic metastases with chronic cholecystitis. An elevated lesion in the fundus of the GB was diagnosed as a small tumor, requiring a preoperative differential diagnosis of GBC (without distant metastases) and adenomyomatosis. Herein, the aggressiveness of GBC unexpectedly caused multiple metastatic liver lesions. Furthermore, we could not entirely exclude the possibility of multiple cancers, including small GBC and ICC. The aim of the surgery was curative and to alleviate symptoms, such as fever in tumors. The patient recovered without any complications and experienced relief from tumor-related symptoms. However, GBC recurrence occurred as early as approximately six weeks after surgery and was confirmed radiologically. Although the patient and his family provided informed consent, we should have cautiously assessed surgical indications in the present case.

4. CONCLUSIONS

This unique case highlights the aggressiveness of GBC with liver metastasis complicated by PVTT. Early diagnosis and multidisciplinary treatment are important for improving the prognosis. Especially, CE-CT and CE-MRI provide useful information for early diagnosis. The indications for surgery and planning therapeutic strategy should be judged more cautiously in patients with such advanced GBC.

CONSENT

As per international or university standards, patients (s) written consent was collected and preserved by the authors (s).

ETHICAL APPROVAL

Written ethical approval was obtained and preserved by the author(s) as per international standards or university standards.

REFERENCES

1. Wolpin BM, Mayer RJ. A step forward in the treatment of advanced biliary tract cancer. *N Engl J Med*. 2010;362(14):1335–7. <https://doi.org/10.1056/NEJMe1001183>
2. Yamamoto Y, Sugiura T, Ashida R, Okamura Y, Ito T, Uesaka K. Indications for major hepatectomy and combined procedures for advanced gallbladder cancer. *Br J Surg*. 2017;104(3):257–66. <https://doi.org/10.1002/bjs.10401>
3. Azizi AA, Lamarca A, Valle JW. Systemic therapy of gallbladder cancer: Review of first line, maintenance, neoadjuvant and second line therapy specific to gallbladder cancer. *Chin Clin Oncol*. 2019;8(4):43. <https://doi.org/10.21037/cco.2019.07.05>
4. Sturm N, Schuhbaur JS, Hüttner F, Perkhofer L, Ettrich TJ. Gallbladder Cancer: Current Multimodality Treatment Concepts and Future Directions. *Cancers (Basel)*. 2022;14(22):5580. <https://doi.org/10.3390/cancers14225580>
5. Kayahara M, Nagakawa T. Recent trends of gallbladder cancer in Japan: An analysis of 4770 patients. *Cancer* 2007;110(3):572-80. <https://doi.org/10.1002/cncr.22815>
6. Aggarwal M, Kundaikar J, Manchikanti D, Thomas S, Arsia A, Pusuluri R, et al. Gall bladder carcinoma associated with anticoagulation-resistant, progressive, multi-focal venous thrombosis and gangrene of all limbs: A case report and review of literature. *Int Surg J*. 2021;8(5):1625–9. <https://doi.org/10.18203/2349-2902.isj20211844>
7. Zhang XZ, Tu JJ, Chen W, Ma T, Bai XL, Liang TB. Gallbladder cancer with tumor thrombus in the portal vein: A case report. *Medicine (Baltimore)*. 2018;97(16):e0271. <https://doi.org/10.1097/md.00000000000010271>
8. Otani K, Ishihara S, Hata K, Muroto K, Sasaki K, Yasuda K, et al. Colorectal cancer with venous tumor thrombosis. *Asian J Surg*. 2018;41(3):197–202. <https://doi.org/10.1016/j.asjsur.2016.07.013>
9. Prandoni P, Falanga A, Piccioli A. Cancer and venous thromboembolism. *Lancet Oncol*. 2005;6(6):401–10. [https://doi.org/10.1016/S1470-2045\(05\)70207-2](https://doi.org/10.1016/S1470-2045(05)70207-2)
10. Paik KY. Is hepatectomy an appropriate option for bilobar liver metastasis with portal vein tumor thrombus of colorectal cancer? *Asia-Pac J Clin Oncol*. 2022;18(2):e182–e185. <https://doi.org/10.1111/ajco.13547>
11. Lee AY, Levine MN. The thrombophilic state induced by therapeutic agents in the cancer patient. *Semin Thromb Hemost*. 1999;25(2):137–45. <https://doi.org/10.1055/s-2007-994915>
12. Kaneko T, Nakao A, Endo T, Takagi H. Intraportal tumor thrombus of gallbladder carcinoma: detection with intravascular ultrasonography. *Am J Gastroenterol*. 1996;91(6):1268–1269.
13. Iyomasa S, Matsuzaki Y, Hiei K, Kawai M, Matsunaga H, Yamaguchi Y. Adenosquamous carcinoma of the gallbladder with tumor thrombus in left portal trunk. *J Hep Bil Pancr Surg*. 1997;4(3):332–6. <https://doi.org/10.1007/BF02489033>
14. Okumura K, Gogna S, Gachabayov M, Felsenreich DM, McGuirk M, Rojas A, et al. Gallbladder cancer: Historical treatment and new management options. *World J Gastrointest Oncol*. 2021;13(10):1317–35. <https://doi.org/10.4251/wjgo.v13.i10.1317>

15. Fang C, Li W, Wang Q, Wang R, Dong H, Chen J, et al. Risk factors and prognosis of liver metastasis in gallbladder cancer patients: A SEER-based study. *Front Surg.* 2022;9:899896. <https://doi.org/10.3389/fsurg.2022.899896>

UNDER PEER REVIEW