

OSTEOMYELITIS UNRAVELING DIFFERENT GENRE OF OSTEOPETROSIS : A CASE SERIES

ABSTRACT

Osteopetrosis is a rare inherited genetic disease .Three distinct forms of the disease have been recognized of which autosomal dominant osteopetrosis is the most common. Malfunctioning of osteoclastic activity along with normal osteoblastic activity causes defective remodelling of bone, which hampers the bone turnover rate. This increased formation of immature bone can lead to abnormal thickening of cortical bones which causes narrowing and obliteration of medullary cavities. Patients with osteopetrosis can show any of the following characteristic features: fragility of bones predisposing it to fracture, osteomyelitis, hematopoietic insufficiency, growth impairment ,disturbed tooth eruption cranial nerve palsies. This paper reports case series of osteomyelitis which unmasked the presence of osteopetrosis in the patient.

Here we report a case of chronic osteomyelitis of mandible leading to diagnosis of Osteopetrosis.

KEYWORDS

marble bone disease, Albers-Schonberg disease, malignant infantile osteopetrosis, osteomyelitis

INTRODUCTION

The term osteopetrosis has its origin from the Greek word “osteo” meaning bone and “petros” which means stone. Osteopetrosis is also known as “marble bone disease” and “Albers-Schonberg disease”, after the German radiologist who is credited with the first description of the condition in 1904 .¹ It was mentioned in 1880 by Neuman and also in 1901 by Jacksh as quoted by Arce. Karschner in 1926 coined the term osteopetrosis. ²

Three clinical forms are known:

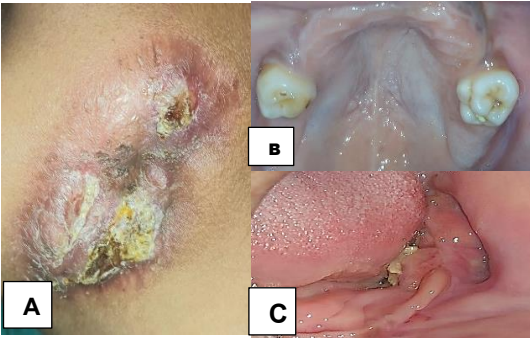
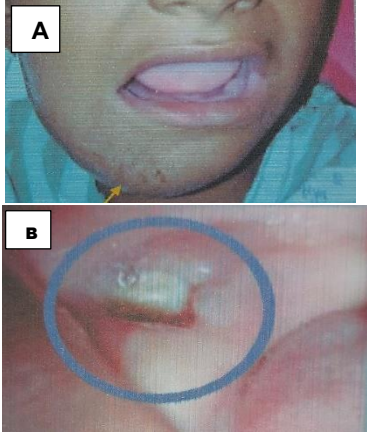
- (1) malignant infantile form with autosomal recessive inheritance and poor prognosis,
- (2) benign/adult osteopetrosis with autosomal dominant inheritance and with fewer symptoms,
- (3) intermediate form which is also autosomal recessive but unlike infantile osteopetrosis, it is a less severe variant.

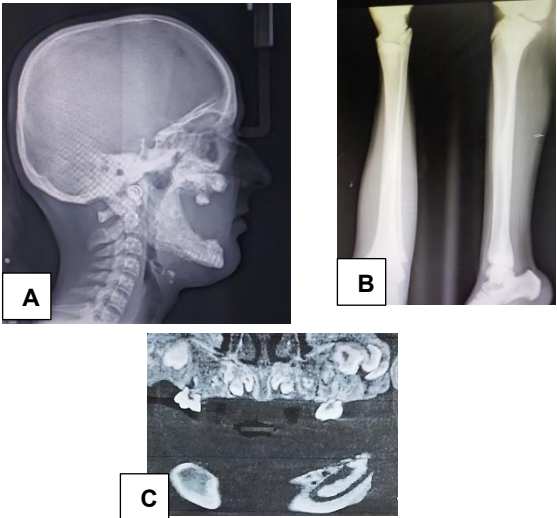
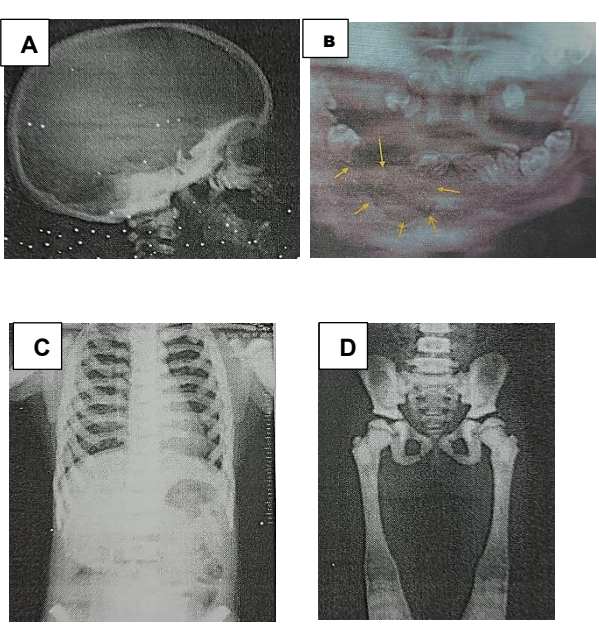
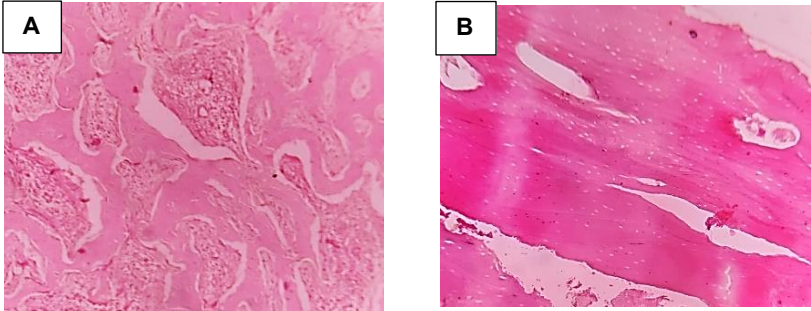
The incidence is 1:200,000 for autosomal-recessive osteopetrosis and 1:20,000 for autosomal-dominant osteopetrosis . ³ Osteopetrosis is a clinically and genetically heterogeneous group of conditions with the hallmark of increased bone density on radiographs. The increase in bone density is due to abnormalities in osteoclast

differentiation or function. 1 In the early-onset malignant infantile form, very young patients exhibit symptoms of bone marrow dysfunction such as anemia, bleeding tendency, and susceptibility to infection. Clinically significant delayed growth, cranial nerve damage, hydrocephalus, and hypocalcemia may make long survival impossible. In intermediate form of Osteopetrosis, patients exhibit fractures, osteomyelitis, and dental abnormalities during childhood . In the milder benign form, patients exhibit symptoms such as bone fractures, osteomyelitis, and facial paralysis in adulthood. 4

Reduced osteoclastic activities disturb bone remodelling, resulting in higher mineral density and higher compressive strength; therefore, bone fracture is a major physical symptom of osteopetrosis. Osteomyelitis of the mandible is a common and well-documented complication of osteopetrosis.5

	CASE -1	CASE -2
Clinical Presentation	<p>Age/Sex:15/ F</p> <p>C/O: swelling and pus discharge from left lower back region of jaw since 9 months.</p> <p>HOPI: Patient was a/a 4 years back when she got multiple extraction done for her conical and malformed permanent teeth by local practitioner. Few months later she developed swelling and pus discharge from lower jaw left side. She was treated for the same .</p>	<p>Age/Sex: 5 /F</p> <p>C/O: swelling in lower right back region of jaw since 7-8 months and pus discharge since 15 days.</p> <p>HOPI: Patient's milk tooth from right lower back region exfoliated on its own and within few days slight swelling with mild tenderness developed in the right lower jaw that increased for 7-8 days. Pus discharge started 15 days back with mild fever.</p>
General examination	short stature, hypertelorism, frontal bossing.	short statured ,distended stomach, hypertelorism , frontal bossing
Extraoral examination	diffuse swelling of left side of face was seen with multiple draining sinuses on lower border of mandible on left side extending from chin to angle of mandible.	diffuse swelling of right side of face was seen with multiple draining sinuses on lower border of mandible with increased local temperature
Intraoral examination	multiple missing teeth in maxillary arch and edentulous mandibular arch with exposed bone in premolar area on left side.	multiple missing teeth in maxillary arch and mandibular arch with exposed bone in molar area on right side.

<p>Clinical pictures</p>	 <p>FIG1: A. Multiple draining sinus on left side of face. B. Multiple missing teeth with deformed molars in maxillary arch. C. Exposed bone on left side of mandibular arch.</p>	 <p>FIG3: A. Multiple draining sinus on right side of face. B. Exposed bone on right side of mandibular arch.</p>
<p>Provisional diagnosis</p>	<p>Osteomyelitis</p>	<p>Osteomyelitis</p>
<p>Differential diagnosis</p>	<p>Paget disease, Osteopetrosis ,Myeloproliferative disease,Osteosclerosis.</p>	
<p>Blood investigation</p>	<p>normal ; serum alkaline phosphatase levels were raised.</p>	<p>leukopenia(3400) and anemia (7.8 g/dl)</p>
<p>Radiographic features</p>	<p>lateral cephalogram : increased skull vault density OPG: osteosclerosis with multiple malformed impacted teeth Long bone radiograph: Increased bone density of long bones</p>	<p>lateral cephalogram : increased skull vault density OPG: multiple malformed impacted teeth Long bone and axial radiograph: Ribs within ribs appearance, Ehler meyer flask deformity in long bones.</p>

<p>Radiographs</p>	 <p>FIG 2: A.Lateral Cephalogram showing increased vault density .B. Increased bone density of long bones. C. osteosclerosis with multiple malformed impacted teeth</p>	 <p>FIG 4: A.Lateral Cephalogram showing increased vault density .B. OPG showed multiple malformed impacted teeth C. Ribs within ribs appearance D. Ehlermeyer flask deformity in long bones.</p>
<p>Histopathology</p>	<p>H & E stained sections of hard and soft tissue bits obtained from both the patients exhibited soft tissue component with chronic inflammatory cell infiltrate and fibrous marrow tissue filling the intertrabecular areas of the bone. Compact bone exhibiting lacunae devoid of osteocytes and compressed marrow space. Overall features were consistent with the finding of osteomyelitis</p>  <p>FIG5: A. chronic inflammatory cell infiltrate and fibrous marrow tissue filling the intertrabecular areas of the bone B. Compact bone exhibiting lacunae devoid of osteocytes and compressed marrow space.</p>	
<p>Final Diagnosis</p>	<p>Chronic Osteomyelitis with underlying Benign Intermediate Osteopetrosis</p>	<p>Chronic Osteomyelitis with underlying Malignant Infantile Osteopetrosis</p>
<p>Treatment</p>	<p>Sequestrectomy and curettage of sinus tract was done .The patient was kept on hyperbaric oxygen therapy for five cycles.</p>	<p>Sequestrectomy and curettage of sinus tract was done .The patient was kept on Calcitriol, Erythropoietin and corticosteroids and hyperbaric oxygen therapy.</p>

DISCUSSION

Osteopetrosis forms a heterogeneous group of bone dysplasia characterized by a bone density increase due to defective bone resorption. Difference in genre of clinical variations in osteopetrosis is due to the heterogeneity of genetic defects resulting in osteoclast dysfunction.

Pathogenesis of osteopetrosis is due to diminished activity of osteoclasts, which results in defective remodelling of bone , hence, increased bone density. It is associated with the control of osteoclast intracellular and extracellular pH.9

Genes encoding this are

- (i) the ruffled border Cl⁻ conductance (CLCN7)
- (ii) the α3 subunit of the vacuolar H⁺ -ATPase of the ruffled border (TCIRG1)
- (iii) the enzyme carbonic anhydrase type II (CAII), which catalyses the hydration of CO₂ to H₂CO₃ to provide a source of H⁺
- (iv) the plekhm1 protein (PLEKHM1) which is likely to be involved in vesicle trafficking and acidification
- (v) the ostm1 protein (OSTM1) likely associated with the function of the Cl⁻ conductance

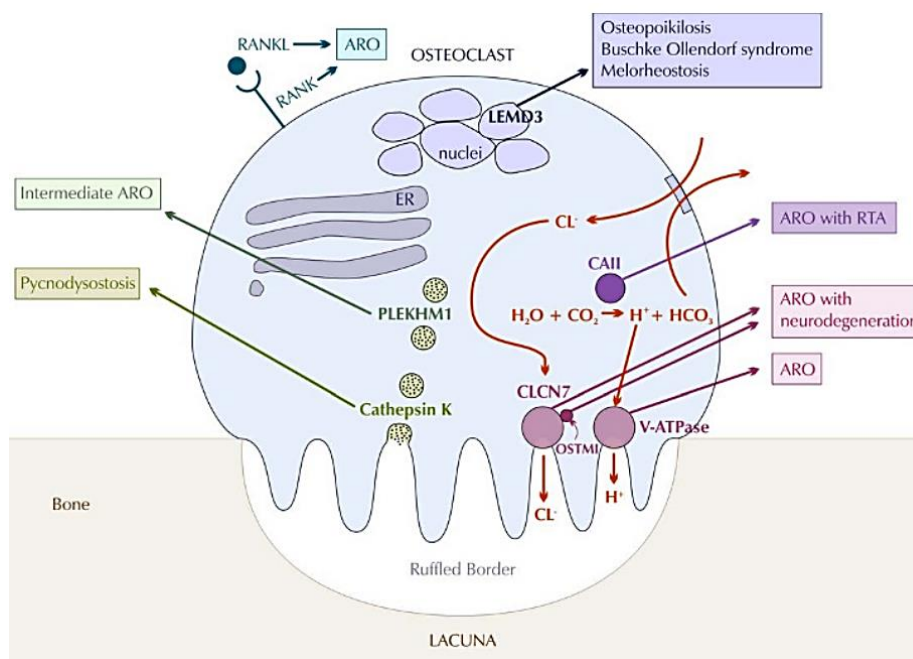
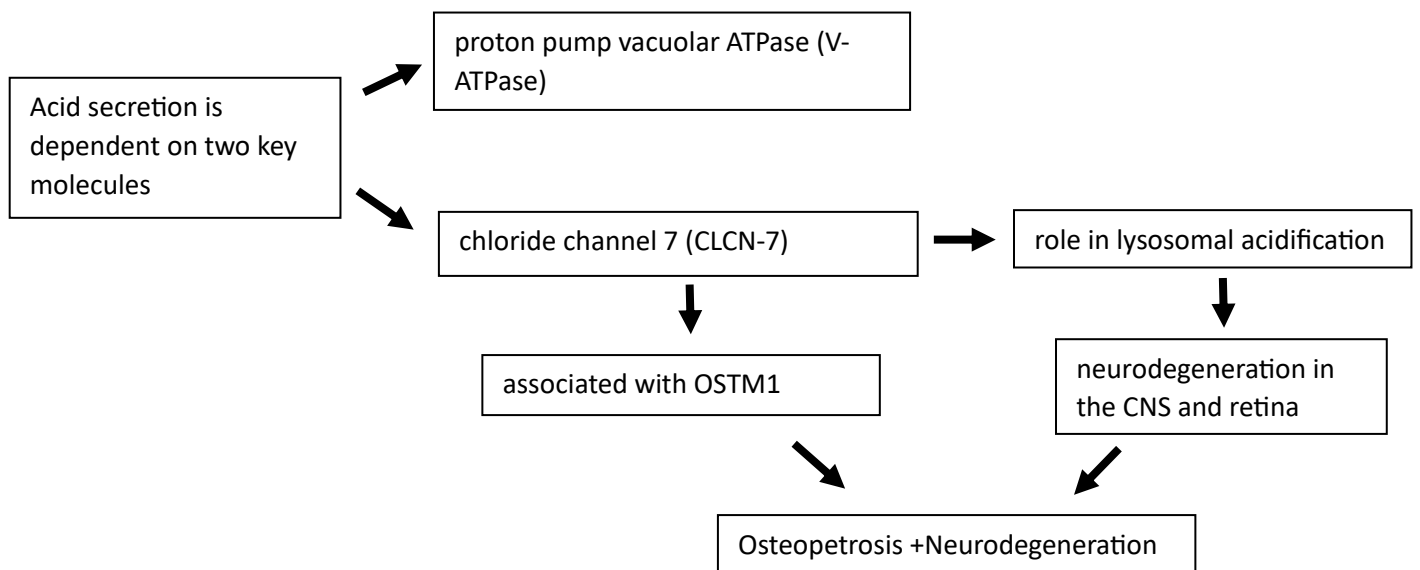
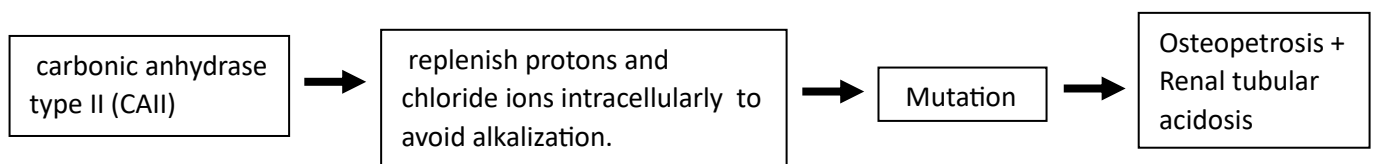


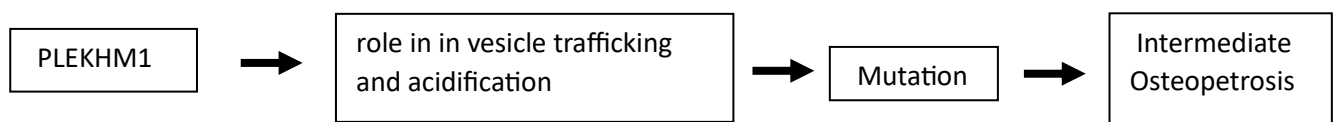
FIG6: Simplified representation of molecules involved in osteoclast differentiation and activation and playing a role in the pathogenesis of osteopetrosis



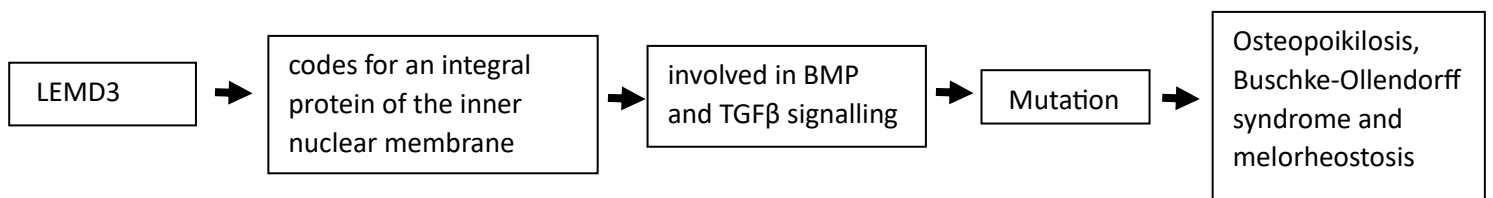
Flowchart 1: Role of V-ATPase and CLCN-7.



Flowchart 2: Role of CAII



Flowchart 3: Role of PLEKHM1



Flowchart 4: Role of LEMD 3.

This suggests that pH handling is a crucial function controlled by mechanisms that are highly specific for osteoclasts .10

Classic osteopetrosis can be described in 2 varieties - benign and malignant diseases.

The benign variant of osteopetrosis is transmitted as a mendelian-dominant trait. So, it develops later and is diagnosed at third or fourth decade of life while undergoing routine radiographic examinations. Autosomal dominant osteopetrosis (ADO) is characterized by a symmetrical and marked osteosclerosis of the skull and an enlarged thickness of the cranial vault. Clinically, ADO is the only type of osteopetrosis not associated with increased fracture rate.

However, Less sclerosis of the skull was found in benign autosomal recessive intermediate osteopetrosis, which is more pronounced in the base of the skull as seen in our case as well. Clinical manifestations shows long-bone fractures, hip osteoarthritis, facial nerve palsy etc. Our patient presented with characteristic findings of Intermediate osteopetrosis such as short stature, frontal bossing, malformed teeth and dental caries complicated by osteomyelitis. Patients with the intermediate form often suffer multiple pathologic fractures, increased bone density of long bone and osteosclerosis with multiple malformed impacted teeth.⁷ Our patient presented with thickening of cranial vault, increased bone density of long bone and osteosclerosis with multiple malformed impacted teeth without multiple fractures.

Previous authors have drawn attention to the fact that not all patients fit neatly into the lethal infantile and benign adult osteopetrosis categories. This intermediate form of osteopetrosis clearly differs from the autosomal recessive malignant infantile, precocious or lethal type.

Malignant infantile osteopetrosis is caused by the failure of osteoclast to resorb immature bone. This leads to abnormal bone marrow cavity formation and clinically to the signs and symptoms of bone marrow failures such as anemia. The body to some extent compensates for bone marrow failure by extramedullary haematopoiesis, resulting in hepatosplenomegaly. Abnormal remodelling of primary woven bone to lamellar bone results in brittle bone that is prone to fracture. Multiple fractures, visual impairment and bone marrow failure are classic features of this disease. Second case presented with anemia, hepatosplenomegaly, defective vision and diminishing hearing capacity.

Krithika C et al suggested the dental changes may vary from delayed eruption, early loss of teeth, missing teeth, malformed roots and crowns, teeth that are poorly calcified and prone to caries and thickened lamina dura.⁹ Similar finding were observed in our case with history of early exfoliation of primary teeth and multiple missing or malformed teeth with short roots on OPG. As teeth develop within the defective bone tissue, both the primary and the permanent dentition are often affected. Most teeth fail to erupt, or tooth enamel may be of poor quality and vulnerable to caries as our patient also showed multiple impacted teeth. ⁸ There is reduced blood circulation due to obliteration and fibrosis of the marrow.

Radiographs may show uniform increase in bone density without corticomedullary demarcation. The long bones may have an 'Erlenmeyer flask' deformity at their ends

due to failure of metaphyseal remodelling, giving gross distal under tabulation and the presence of dense bone, vertical fine radiolucencies extending to the metaphysis are present probably due to vascular channels being better seen against dense bone. The vertebral column has a 'sandwich' or 'rugger jersey' spine appearance with dense sclerotic bone at each end plate of the vertebral body. The most common complication is pathologic fractures, those with congenital presentation are likely to have the most fractures. Our patient presented 'Ribs within ribs' appearance and 'Erlenmeyer flask' deformity of long bones with an unusual absence of fractures, and no signs of healed or healing fractures were visible on radiology.

Medical management of osteopetrosis is based on efforts to stimulate host osteoclasts or provide an alternate source of osteoclasts. Stimulation of host osteoclasts has been attempted with calcium restriction, calcitriol, steroids, parathyroid hormone and interferon. Hyperbaric oxygen has been used in the treatment of mandibular osteomyelitis. Bone marrow transplant has been used with cure for infantile malignant osteopetrosis. If untreated, infantile osteopetrosis usually results in death by the first decade of life due to severe anemia, bleeding or infection. Osteomyelitis secondary to osteopetrosis tends to be refractory because of the reduced blood supply and accompanying anemia and neutropenia.

According to Kant P et al, Antibiotic therapy combined with complete debridement of necrotic tissue, bacterial culture and sensitivity testing, followed by suturing of soft tissue is the main therapeutic approach. Indeed, Adachi et al suggest hyperbaric oxygen therapy in recalcitrant cases.¹ However, improved oral hygiene and preventative care will minimise the infection risk.⁶ Antibiotic sensitivity test was done from swab of draining sinus, the patient was kept under hyperbaric oxygen therapy and under regular follow ups.

CONCLUSION

Refractory osteomyelitis evokes possibility of various spectrum of diseases. In both the cases unresolved osteomyelitis unravelled the underlying osteopetrosis. Both the cases presented with draining sinuses, osteosclerosis and multiple malformed impacted teeth were seen on OPG. Increased opacity of skull vault alluded the need for long bone X-rays. Though inconsistent, Serum calcium, phosphate, parathyroid hormones, Serum acid phosphatase levels and alkaline phosphatase level needs to be investigated. In first case, osteosclerosis and multiple malformed impacted teeth with evident bone marrow dysfunction supported the diagnosis of Benign intermediate osteopetrosis. Generalised osteosclerosis with bone marrow dysfunction, defective vision and hearing loss lead to the diagnosis of Malignant Infantile Osteopetrosis in second case. Along with Hyperbaric oxygen, different treatment modalities such as hematopoietic stem cell transplantation (HSCT), Calcitriol, Erythropoietin and corticosteroids are used in severe cases. Recently, interferon-gamma 1b (IFN- γ 1b) has been tried.

Moreover, because of the high infection risk and increased susceptibility to jaw fracture in these patients, they should receive increased attention and prophylactic dental treatment to maintain their fragile oral health status.

REFERENCE

1. Kant P, Sharda N, Bhowate RR. Clinical and radiological findings of autosomal dominant osteopetrosis type II: a case report. *Case Reports in Dentistry*. 2013 Oct 24;2013.
2. Loría-Cortés R, Quesada-Calvo E, Cordero-Chaverri C. Osteopetrosis in children: a report of 26 cases. *The Journal of pediatrics*. 1977 Jul 1;91(1):43-7.
3. Wu CC, Econs MJ, DiMeglio LA, Insogna KL, Levine MA, Orchard PJ, Miller WP, Petryk A, Rush ET, Shoback DM, Ward LM. Diagnosis and management of osteopetrosis: consensus guidelines from the osteopetrosis working group. *The Journal of Clinical Endocrinology & Metabolism*. 2017 Sep 1;102(9):3111-23.
4. Okawa R, Yokota Y, Morita Y, Mikasa Y, Nakano K. Osteomyelitis Possibly Caused by Exfoliation of Primary Teeth in a Patient with Osteopetrosis. *Children*. 2022 Dec 2;9(12):1894.
5. Mikami T, Miake Y, Bologna-Molina R, Takeda Y. Ultrastructural analyses of alveolar bone in a patient with osteomyelitis secondary to osteopetrosis: a review of the literature. *Journal of Oral and Maxillofacial Surgery*. 2016 Aug 1;74(8):1584-95.
6. Junquera L, Rodríguez-Recio C, Villarreal P, García-Consuegra L. Autosomal dominant osteopetrosis and maxillomandibular osteomyelitis. *American journal of otolaryngology*. 2005 Jul 1;26(4):275-8.
7. de Oliveira HD, Pereira Filho VA, Gabrielli MF, Gabrielli MA, Vieira EH. Marginal resection for treatment of mandibular osteomyelitis associated with osteopetrosis: case report. *Journal of Cranio-Maxillofacial Surgery*. 2011 Oct 1;39(7):525-9.
8. Balan A, Girija KL, Ranimol P. Osteomyelitis of maxilla in infantile osteopetrosis: a case report with review of literature. *International Journal of Clinical Pediatric Dentistry*. 2011 May;4(2):125.
9. Krithika C, Neelakandan RS, Sivapathasundaram B, Koteeswaran D, Rajaram PC, Shetkar GS. Osteopetrosis-associated osteomyelitis of the jaws: a report of 4 cases. *Oral Surgery, Oral Medicine, Oral Pathology, Oral Radiology, and Endodontology*. 2009 Sep 1;108(3):e56-65.
10. Del Fattore A, Cappariello A, Teti A. Genetics, pathogenesis and complications of osteopetrosis. *Bone*. 2008 Jan 1;42(1):19-29.

11. Venkateshwar V, Vaidya A, Roy P, Sampat S, De JK. Osteopetrosis. Medical Journal Armed Forces India. 2003 Oct 1;59(4):344-6.
12. Beighton, P,* Hamersma, H.** & Cremin B. Osteopetrosis in South Africa-the benign, lethal and intermediate forms. South African Medical Journal. 1979 Apr 1;55(17):659-65.
13. Ishaque A, Farid E, Nasir S, Qadar LT, Jamal A. Intermediate Autosomal Recessive Osteopetrosis With an Unusual Absence of Fractures. Ochsner Journal. 2022 Dec 21;22(4):366-71.