

Original Research Article

Experimentally Histological Assessment for The Effect of Resveratrol in The Liver of Mice

Abstract:

Resveratrol a major Polyphenolic compound is a non-flavonoid stilbene, was isolated and purified as a first time in Iraq from the skin of black grape had grown in this country. Many studies confirmed the biological importance of this substance in different disorders, beside the protective properties specially towered the hepatic cells against free radicals and drugs toxic effects as histological level. In this study the purified resveratrol from Iraqi black grape was administered to groups of normal mice in three doses to investigate if there is any unwanted or harmful effects which may appear on the mice liver after fifteen days and thirty days administrated as intrapretoneal single dose a day Results showed that the extraction method estimated resveratrol in two stereo isomer mixture cis and trance forms. The different doses within two intervals affected the hepatocytes in different manner. The harmful properties of this substance appeared to be more potent in ~~relation with~~ relation with dose and exposure time increasing. The study concluded that there must be an extensive studies that bridge the gap of available information with what is required regarding the Iraqi purified resveratrol as a safe therapeutic substance, not only for treating liver disorders, but in all it's therapeutic purposes.

Introduction

Polyphenols are big group in plant kingdom represented as secondary metabolites possess an important role in human nutrition as antioxidants. Resveratrol a trihydroxy-trans-stilbene; a major Polyphenolic compound is a non-flavonoid ~~stilbene~~, phytoalexin plant component, which was first isolated from the white hellebore by Takaoka in 1940 and then isolated from *polygonum Cusprdatum* (Jopanes – knot- weed) in 1963 by Nanomurad, also present in over 300 edible plants, in chiding grapes, berries, and peanuts, and other sources, that produced by plants as a defense mechanism against microbial injury, fungal infection or environ mental stress(1). It naturally has two different isomeric forms; trans and cis isomer. The trans form has been reported to be more important and stable than *cis* form, and, thus, more widely used in studies(2). Many studies have emphasized the ~~biological~~ biological effects of this substance especially on circulating system as antithrombotic and cardiovascular protective agent(3), the anti-inflammatory(4), blood sugar reducing(5) and anticancer activities of resveratrol (6). Other studies explain the mechanism for the antiinflamotary and protein-tyrosine Kinas inhibitory effects(7,8) while others explain it's anticancer activeties (9-10,11) Besides that, other researches demonstrated that Res. having another properties such as immune modulatory and in lymphoma disorders(12,13), antiproliferative (14), anti parasites and anti-Leishmanial(15,16).

evorpmi eb tsum :[1PM]Comment

? :[2PM]Comment

Formatted: Font: Italic

In liver disorders various studies demonstrated and confirmed its anti-oxidative properties in different model of hepatitis resulting in obvious reduction in the hepatic fibrosis; on the other hand it could reduce hepatic stenosis (17,18,19).

The aim of this study was to investigate and evaluate the effect of resveratrol of purified Res. from black grape skin on hepatic tissue histologically and chemically

Formatted: Justified

Methodology

Resveratrol Extraction and purification from black grape skin (13):

Black grape was pursued from local market. The outer skin was collected, washed and cleaned from any dust and impurities. A bout 500 g of fresh grape skin was macerated with ethyl acetate for 7 days in dark, cold place with gentle shaking occasionally. Then filtered and the filtrate was transferred to separator funnel with addition of equal volume from acidified distilled water with 2M HCl. After vigorous shaking two layers were separated, the upper ethyl acetate layer was taken to be washed with distilled water in order to get rid of any acid traces. The acetate layer was concentrated and a purification process was employed with aid of preparative silica gel chromatography technique (PTLC) using mobile phase: benzene: methanol: acetic acid, with ratio of (20:4:1). The purified resveratrol was subjected to the following analysis:

ro RMN dna RI on : [3PM] Comment ? ssaM

Analysis of the Extracted Resveratrol compound by HPLC technique (20)

evorpmi eb nac : [4PM] Comment

HPLC conditions for analysis of the standard and purified resveratrol of the extracted grape skin was shown in Table(1).

Table(1) HPLC conditions for Resveratrol analysis

| Parameters | Conditions |
|-------------------------|---|
| Instrument | Shimadzu, Japan |
| Mobile phase | Acetonitrile: water (60:40 v/v) |
| Column | reversed-phase C18 column (250 x 4.6 mm i.d.; 5 µm). |
| Flow rate | 0.6 ml / min |
| Injection Volume | 10 µl |
| Concentration of sample | 0.6 mg / 1 ml |
| Detection wavelength | UV-Vis at λ 307nm for Trans resveratrol & 280nm for cis resveratrol |

Formatted: Space Before: 6 pt, After: 6 pt

Formatted Table

Formatted: Space Before: 6 pt, After: 6 pt

Formatted: Space Before: 6 pt, After: 6 pt

Formatted: Space Before: 6 pt, After: 6 pt

Formatted: Space Before: 6 pt, After: 6 pt

Formatted: Space Before: 6 pt, After: 6 pt

Formatted: Space Before: 6 pt, After: 6 pt

Formatted: Space Before: 6 pt, After: 6 pt

| | |
|--------------------|---------------------------------|
| Column Temperature | Room Temperature |
| Standard used | Trance Resveratrole (0.6 mg/ml) |
| | Cis Resveratrol (0.6 mg/ml) |

Formatted: Space Before: 6 pt, After: 6 pt

Formatted: Space Before: 6 pt, After: 6 pt

II-Biological study of the Extracted resveratrolon mice liver function

Resveratrol Dosage Preparation

To prepare the required doses that were used in work; a purified resveratrol was dissolved in 10% Ethanol according to (21), and the resulting solution was sterilized through 0.22 µm Millipore filter to be intraperitoneally administrated to normal Albino mice had been employed in current study

Formatted: Justified

Laboratory animals Ethic statement

The research protocols that approved by Animal Care and Use ATU Committee guarantee of *AL-Dyaa* office for agricultures and veterinary services, involved Health Guidelines for the care and Laboratory Animals use, that provided with assurance certificate and approved by the Animal Ethics Committee. The animals were housed in individual cages under constant research conditions of humidity on a 12 hours light/dark cycle, food / water and temperature (22-25)°C Protocols.

Study Design and Experimental Work

The effect of purified Resveratrol on liver tissue was investigated in the current study. The 32 Albino male mice (*Mus musculus*), with 23–27 g weight and 8–10-week-old at the start of experiments, were divided into four groups and kept in a separate plastic cage. Each group contained eight mice. Each group had received the following resveratrol dose according to (21).

These groups included:

Formatted: Justified

- Group one: Untreated mice group considered as control.
- Group two: treated with 0.25 mg/mouse/day intraperitoneally, 4 mice treated for 15 days and 4 mice treated for 30 days.
- Group three: treated with 0.5 mg/mouse/day intraperitoneally, 4 mice treated for 15 days and 4 mice treated for 30 days.
- Group four: treated with 1.0 mg/mouse/day intraperitoneally, 4 mice treated for 15 days and 4 mice treated for 30 days.

Each dose was injected intraperitoneally as a single dose of 0.1 ml/mouse/day. Half of the mice from each group were treated for (15) days and another animals were treated in the same dose for (30) days. At the end of the experiment period, blood was pooled from animal's heart, and then mice were sacrificed by using inhalant chloroform as anesthetic for laboratory assessments (after 15 and 30 days).

II-Histopathological finding

The livers of the mice were taken from the dorsal mice back and stored in 10% formalin solution immediately, left overnight, and then embedded in paraffin blocks. The blocks were cut into 4-µm sections and stained with hematoxylin-eosin (H-E), using standard protocols (22)

The severity of hepatic injury in the sections was evaluated using a point-counting method on an ordinal scale according to the authenticated scale by Khalid(23) as follow:

grade (0), minimal or no evidence of injury;

grade(1), mild injury consisting of cytoplasmic vacuolation and focal nuclear pyknosis;

grade(2), moderate to severe injury with extensive nuclear pyknosis, cytoplasmic hyper-eosinophilia, and loss of intercellular borders;

grade (3), severe necrosis with disintegration of hepatic cords, hemorrhage, and neutrophil infiltration.

III Statistical Analysis(24)


The experimental data were analyzed by SAS statistical software and expressed by mean \pm standard deviation ($\bar{x} \pm s$). Statistical significance was defined as $P < 0.05$.

The Results

i-Resveratrol Extraction and purification from black grapeskin

Results for the extraction and isolation of resveratrol substance from the skin of Iraqi black grape indicated that each 1g. dried grape skin yields about 70 μ g pure crystals, which was purified with aid of preparative TLC technique as shown in Figure (1)

? tseretni :[5PM]Comment
?dnuopmoc fo erutcurts



Figure(1) PTLC Chromatogram for Isolation and Purification of The Extracted Resveratrol From Black Grape Skin

Formatted: Font: Italic

As shown in Figure (1) the Trans isomer was isolated then subsequent purified through PTLC technique to get a pure crystals subjected to different analysis listed in reference(25).

Formatted: Justified, Indent: First line: 0"

ii-Analysis the Extracted Resveratrol compound by HPLC technique

Formatted: Justified

The HPLC for the resulted crystals was compared with standard retention time using same condition. Figure (2) and (3) showed chromatogram for the standard and extracted resveratrol respectively.

Formatted: Justified, Indent: First line: 0"

Formatted: Justified

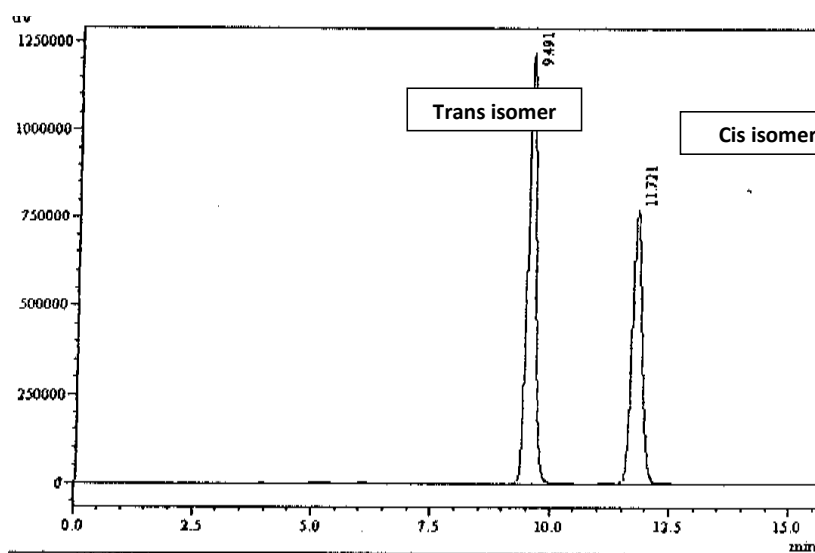


Figure2- HPLC Chromatogram for the Standard Resveratrol (Trans& Cis Isomers)

Formatted: Font: Bold, Italic

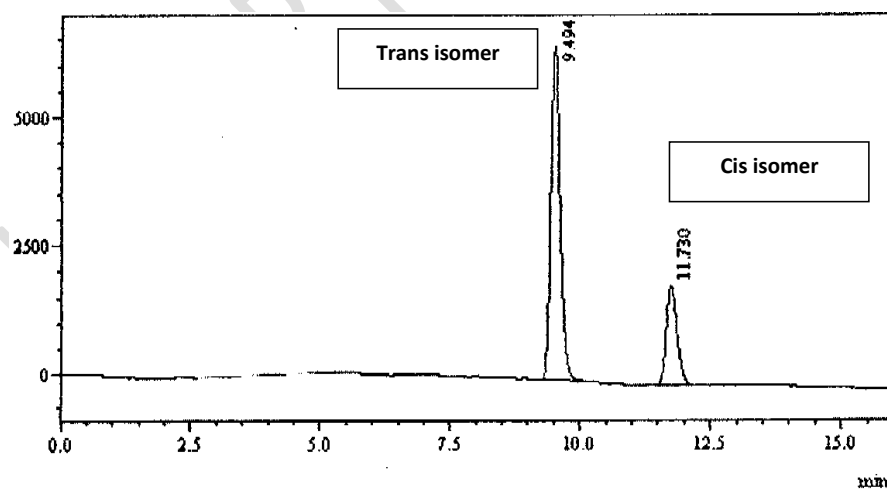


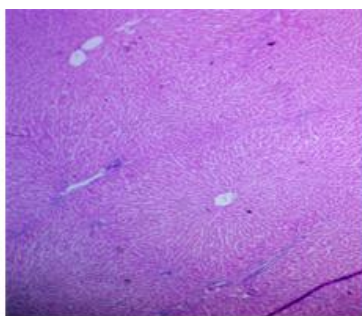
Figure3- HPLC Chromatogram for the Extracted Resveratrol(Trans& Cis Isomers)

Formatted: Font: (Default) Times New Roman, 12 pt, Bold, Italic

Histological study of the Extracted resveratrol on mice liver function

The histological results investigated lesion of group two liver's mice, treated with Resveratrol 0.25 mg/mouse/day intraperitoneally administrated for 15 days also showed congestion of blood vessels sinusoid, infiltration of multinuclear inflammatory cells in addition to vacuolar degeneration of hepatocyte around central vein, (Figure.5), in comparison with the control group as shown in Figure(4).

Formatted: Justified, Indent: First line: 0"



Figure(4) Histological section of liver tissue (control) live cell columns, blood sinusoids, central vein (H&E) 10 X.

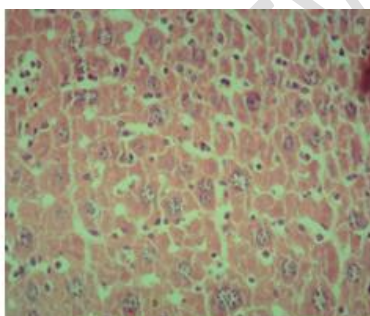
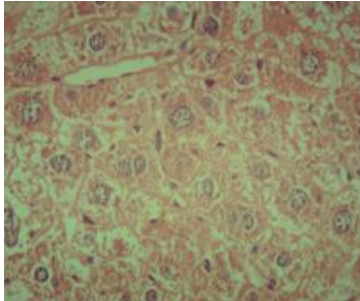


Figure (5) Histological section of group two liver's mice, treated with Resveratrol 0.25 mg/mouse/day intraperitoneally for 15 days, showed liver tissue, liver cells groups associated with few degeneration of liver cells. the blood sinusoids were dilated and appeared as network of blood channels engorged with multiple number of hypertrophic Kupffer cells (H&E 40 X)

esaelp tamrofer :[6PM]Comment

After 30 days for the group two liver's mice, treated with 0.25 mg/mouse/day intraperitoneally of Resveratrol, sections elucidate lesions above in addition to coagulative necrosis of hepatocytes around central vein, perivascular infiltration of inflammatory cells in portal area (Figure -6,7).

Formatted: Indent: First line: 0"



Figure(6) Histological section of mice liver treated with Resveratrol 0.25mg /mouse /day intraperitoneally, for 30 days showed hypertrophy of the liver cells, cytoplasmic degeneration of certain cells with karyolysis of its nuclei ,blood sinusoids with kupffer cells.(.H&E 40 X)

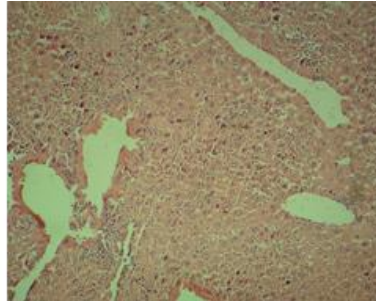


Figure (7) Histological section of mice liver treated with Resveratrol 0.25mg / mouse/day intraperitoneally, after 30)days showed coagulative necrosis of hepatocytes around central vein central vein empty from blood , rupture of basement membrane of C.V., crowded liver cells to each other narrow blood sinusoid and coagulative necrosis(H&E 10 X)

esaelp tamrofer :[7PM]Comment

For group three that represented mice treated with 0.5mg/mouse/day intraperitoneally, mice treated for (15) days, liver sections showed coagulation necrosis of hepatocytes, **extensive** infiltration of chronic inflammatory cells, as shown in Figure (8) while dilation of central vein and sinusoid ,hemorrhage hypertrophic of kupffer cells were investigated for this group after 30 days, and the same results were seen as in Figure (9), with more sever lesion was appeared shown in Figure (10.)

Formatted: Indent: First line: 0"

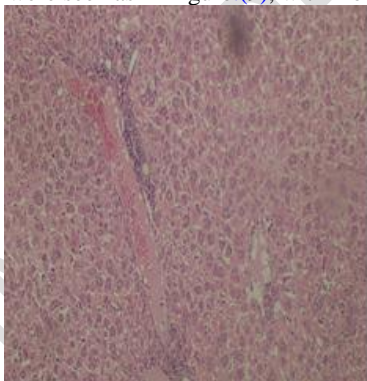


Figure (8) Histological section of mice liver treated with Resveratrol 0.5mg /mouse /day intraperitoneally for 15 days showed liver tissue with hyperplasia of hepatocytes vascular leukocytes cuff. (H&E 10 X)

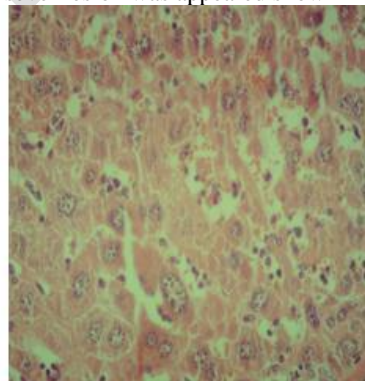


Figure (9) Histological section of mice liver treated with Resveratrol 0.5mg / mouse/day intraperitoneally after 30 days showed degeneration of liver cells with karyolysis of its nuclei , dilation of blood sinusoid and hyperplasia of kupffer cells(H&E 40 X)

esaelp tamrofer :[8PM]Comment

In group four treated with 1.0mg/ mouse /day intraperitoneally administrated Res. For (15) days, liver's mice section showed changes include crowded liver cells with inflammatory leukocytic infiltration around the branch of portal vein in the portal area [Figure \(11\)](#)

Formatted: Indent: First line: 0"

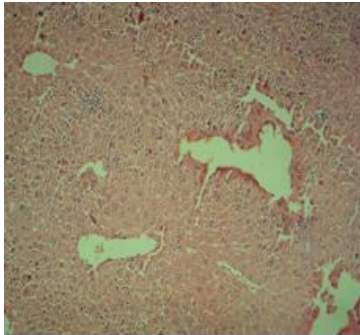


Figure (10) Histological section of mice liver treated with Resveratrol 0.5mg /mouse /day intraperitoneally after 30 days showed liver tissue, distortion of basement membrane and endothelial desquamation in the lumen of C.V. (H&E 10 X)

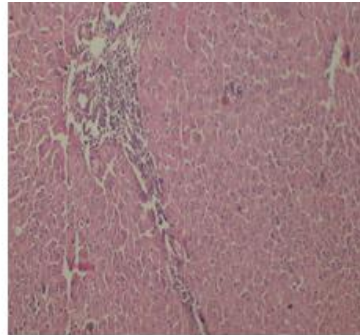
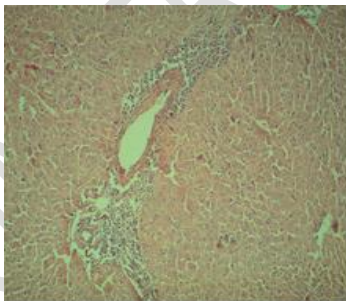


Figure (11) Histological section of mice liver treated with Resveratrol 1mg/mouse/day intraperitoneally after 15 days showed liver tissue, crowded liver cells with inflammatory leukocyte infiltration around the branch of portal vein in the portal area (H&E 10X)

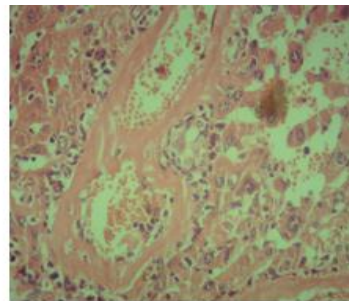
esaelp tamrofer :[9PM]Comment

While after (30) days liver's mice section showed more sever changes include coagulation necrosis of hepatocytes in some area ,vacuolar degeneration.....in others, dilation and congestion of sinusoids ,perivascular infiltration of mononuclear inflammatory cells in central vein and portal area , hyalinization in the wall of blood vessels [Figure 12-, 13\(A& B\) and 14.](#)

Formatted: Indent: First line: 0"



A



B

Figure(13- A & B) Histological section of mice liver treated with Resveratrol 1mg /mouse/day intraperitoneally after (30) days showed in A: liver tissue with extensive liver cells degeneration, B: blood vessels and blood sinusoids with cellular debris and leukocyte infiltration, hyaline degeneration in the wall of blood vessels(H&E 40X)

esaelp tamrofer :[10PM]Comment

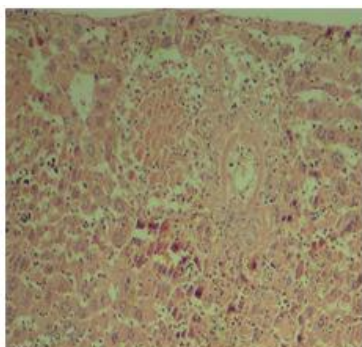


Figure (12) Histological section of mice liver treated with Resveratrol 1mg /mouse/day intraperitoneally after 30 days showed distortion of liver cells showed presence of co-agulative necrosis, blood sinusoids with multiple kupffer cells, (H&E 40 X)

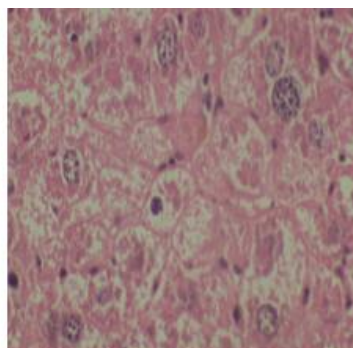


Figure (14) Histological section of mice liver treated with Resveratrol 1mg /mouse/day intraperitoneally after 30 days showed vacuolar degeneration of the certain liver cell and hyperplasia of kupffer cells in the blood sinusoid (H&E 40 X)

esaelp tamrofer :[11PM]Comment

Discussion

Since resveratrol is a new therapeutic substance that attracts researchers to study all its therapeutic effects as well as its toxicity, and since this substance is extracted for the first time in Iraq as a raw material purified from the skin of Iraqi black grapes as a rich source with this substance(25) in the form of a mixture of two stereoisomers, *cis* and *trans*, it has become necessary to conduct investigative studies on this natural substance in all aspects. This concept is regarded as the most important of which is investigating the therapeutic dose and the effect of different concentrations on the different organs of laboratory animals such as mice, as in-vivo study to identify the extent of its toxicity(26).

It was clear that this substance showed toxicity on liver tissue, especially at high concentrations. Researches indicated the synergistic effect of this substance, it had been showed a therapeutic effect in certain doses, and in larger doses, toxicity had been appeared on living cells. In some *in vitro* and *in vivo* studies clarified this phenomena which appeared to be strongly associated with what called a hormetic effect in the behavior of this substance, where the resveratrol low doses may be associated to curable effects, while the increasing in dose usually lead to toxic effects (27,28)

The hermetic property of resveratrol had regard with a suggestion that associated that associated with the biphasic evidence of redox state affected living cells. This effect had been reported to be; at low doses resveratrol appeared to involved antioxidant activity while the substance may act as pro-oxidant with high doses which may explain the controversial results in these studies (29). On the other hand, the route of administration and the method of giving treatment played an important role in enhancing and arising the side effects of this substance (30) or due to its metabolism and delivery system.(31,32). Moreover, the solvent used to dissolve the substance may have an enhanced toxicity effect. Resveratrol *in vivo* and *in vitro* bioavailability effects still unclear when administered systemically and due to that the current study tend to applied the

evorpmi eb nac :[12PM]Comment

Formatted: Indent: First line: 0"

Formatted: Font: Italic

Formatted: Font: Italic

Formatted: Font: Not Bold

intraperitoneal administration which might overcome this therapeutic dilemma, by using ethanol and DMSO for dissolving Resveratrol and safety for long-term *in vivo* treatment remain unknown(21).

Formatted: Font: Italic

In spite that; there were many studies declared that resveratrol possessed therapeutic effects on different liver diseases, that lead to a significant improvements in rate of survival especially in liver transplantation(33,34,35), besides; resveratrol was widely used as a dietary supplement, a proven safety studies now a day had not found employed the specific doses and administration routes and intervals for this compound with optimal pharmacodynamics and pharmacokinetics investigation which might lead to an important limitation that for resveratrol dispensing as a drug(36,37).

In a review summarized the most developed delivery systems for resveratrol during the last 5 years, which aimed to overcome some of the limitations derived from the low aqueous solubility, intestinal permeation, bioavailability, and photostability of this substances, including liquid formulations with vesicles, emulsions and nanocapsules, as well as solid formulations based on mesoporous silica nanoparticles and nano-crystals(38,39). In addition, many factors could play as an effective cause in resveratrol activity and toxicity, such as enzymatic reconversion of resveratrol metabolites to the parent compound at the site of action(40).

Although the protective properties and beneficial effects of resveratrol in huge numbers of human and animal studies had been reported, the harmful effects of this substances are not enough clinically studied, and since such studies involved that compound was mostly focused on the short-term resveratrol intake, the molecular studies were needed to understand the precise mechanism of action must be better identified(28)

All the repercussions that have been raised about the effect of this substance require urgent studies and research to avoid all harmful effects and make it safer as a successful medical treatment for many disorders.

Perhaps the clearest reason for the varying effect of this substance is that it is a mixture of two isomers that may actually cause a synergistic effect by showing a stronger toxicity for the substance, which is most likely in the researcher's opinion.

Conclusion

As long as resveratrol constitutes a promising treatment for many cases, starting from improving immunity and using it as a nutritional supplement, and ending with determining the best dose for administering the drug, the best method of administration, and the best pharmaceutical form, all of this requires the preparation of extensive studies that bridge the gap of available information with what is required to identify it as a safe therapeutic substance, not only for treating liver disorders, but for all cases in which the effective and unique effect of that substance was found.

evorpmi eb tsum :[13PM]Comment

Formatted: Indent: First line: 0"

References

1- Li-Xue, Z.; Chang-Xing, L.; Mohib -Ullah, K.; Muhammad -Sajjad, K.; Pei-Feng, W.; Rai-Muhammad, A.; Dong-Fang, D.; Muhammad ,N.; Qin-Yuan, L.; Muhammad, S.; Ji-Qiang, S.; Shahid, A. R.; and Jian-Hua, L. Resveratrol (RV): A pharmacological review and call for further research. *Biomedicine & Pharmacotherapy*, Volume 143, November 2021, 112164

dna IOD dda :[14PM]Comment
notiatneserp ezinomrah

2- Zainab, Y. M. H.; Fatma, A. A. O.; Ahmed, A. Abdulmunem J. and Alaa, F. Alwan. *In vitro* study of the effect of resveratrol purified from the skin of Iraqi black grape (*Vitis vinifera*) on lymphocyte cultures isolated from the blood of patients with lymphoma. *JML, JOURNAL of MEDICINE and LIFE 2022, VOL. 15* ISSUE: 6 JUNE page 778-783. DOI 10.25122/jml-2022-0038

Formatted: Highlight

3- Samar, R.; Anthony, F.; Jessie, W.; Matthew, L.; Adam, B.; Frank, G.; Phillip, S.; Melita, V.; Jose, P.; Mario, C.; Andrew, M.; Miguel, R.; Michelle, B.; Honghai, L.; Dawn, T.; Niyatie, A.; Rachel, S.; Megan, C.; and Bernhard, K. Design and rationale of a clinical trial to increase cardiomyocyte division in infants with tetralogy of Fallot. *International Journal of Cardiology*, Volume 339, 15 September 2021, Pages 36-42.

Formatted: Justified

4- Bahare, S.; Abhay, P. M.; Manisha, N.; Bilge, S.; Mehtap, K.; Mehdi, S.; Patrick, V. T. F.; Natália, M.; and Javad, S. Review Resveratrol: A Double-Edged Sword in Health Benefits *Biomedicines* 2018, 6, 91,2-20.

5- Tamires, M. S.; Lucas, Y.O.; Marcelo, M. R.; Lúcia, P. B.; Inar, A. Effect of resveratrol supplementation on biomarkers associated with atherosclerosis in humans. *Complementary Therapies in Clinical Practice*. Volume 46, February 2022, 101491

Formatted: Justified

6- Gustavo, H. F.; Karen, L. K.; Nathalia, F.; Marisa, F.; Alessandra, R.; Solange, D. A.; Célia M.; and Antonio, P. M. Sirtuin 1 and Vascular Function in Healthy Women and Men: A Randomized Clinical Trial Comparing the Effects of Energy Restriction and Resveratrol. *Nutrients* 2023, 15, 2949.

7- Sheng, S. W.; Shuyan, S.; Xinyi, W.; Xin, L.; Xinyang, H. Yubao, S.; Gaoyuan, W.; Deshen, M.; Conghan, L.; Bangjie, C.; and Xiaoyu, C. The role of resveratrol on rheumatoid arthritis: From bench to bedside. *Frontiers in Pharmacology*. *Frontiers in Pharmacology* 22. August 2022. DOI 10.3389/fphar.2022.829677

(8) Hadi, K.; ShadiSadat, S.; Ensieh, N.E. Farideh, R.; and Reza, M. Resveratrol supplementation decreases blood glucose without changing the circulating CD14CD16 monocytes and inflammatory cytokines in patients with type 2 diabetes: a randomized, double-blind, placebo-controlled study. *Nutrition Research*. Volume 54, June 2018, Pages 40-51

(9) Soudeh, G.; Zahra, B.; Hamed, S.; Bashdar, M.H.; Seyede, F.T.; Sadia, G.; Mohammad, T.; and Seyed, A.A. Disease-associated regulation of gene expression by resveratrol: Special focus on the PI3K/AKT signaling pathway. *Cancer Cell International* (2022) 22:298

Formatted: Justified

(10) Jung, Y. J.; Eunok, I.; and Nam, D. K. Mechanism of Resveratrol-Induced Programmed Cell Death and New Drug Discovery against Cancer: A Review *Int. J. Mol. Sci.* 2022, 23, 13689.

(11) Aleksandra J.; Nataša, J.; Senka, V.; Jelena, V.; Nikola, J.; Milan, I.; Tatjana, S.R.; Vesna, K.; and Dimitar, J. The Effects of Resveratrol-Rich Extracts of *Vitis vinifera* Pruning Waste on HeLa, MCF-7 and MRC-5 Cells: Apoptosis, Autophagia and Necrosis Interplay *Pharmaceutics* 2022, 14, 2017-2022.

Formatted: Justified

(12) Xianxian, S.; Canjing, Z.; Jianan, Z.; Shengxuan, C.; Chen, X.; Feng, T.; Xiuling, Z.; Bobin, C.; Songmei, W.; and Lianhua, Y. Resveratrol inhibits Extranodal NK/T cell lymphoma through activation of DNA damage response pathway. *Journal of Experimental & Clinical Cancer Research* (2017) 36:133)

(13) Zainab Yaseen Mohammed Hasan¹; Mohammad Mahmoud Farhan AlHalbosiy² ; Raghad K. Al-Lihaibi. **The Immunomodulation Effect Of Purified Resveratrol Extracted From Black Grape Skin Cultivated In Iraq**.*Nat. Volatiles & Essent. Oils*, 2021; 8(4): 4490-4504-

Formatted: Justified

Formatted: Highlight

(14) Paulina, K.; Malgorzata, K.; Jacek, K.; Dawid, L.; Marcin, W.; and Marek, M. Resveratrol Analogues as Selective Estrogen Signaling Pathway Modulators: Structure–Activity Relationship. *Molecules* 2022, 27, 6973

(15) Yu, N. L.; Xin, Y, S.; Jing, M.L.; Guang, N. J.; Hui, W. L.; Xiang, X.; and Lian, X. P. Resveratrol inhibits Toxoplasma gondii -induced lung injury, inflammatory cascade and evidences of its mechanism of action. *Phytomedicine*. Volume 108, January 2023, 154522 .

(16) Parisa, M.; Bahman, R.E.; Maryam, P.; Mahdi, F.; Zabihollah, S.; Seyed, H.; Hadi H.; Ayatollah, N. O.; and Hamid, H. Anti-leishmanial effects of resveratrol and resveratrol nanoemulsion on Leishmania. *BMC Microbiology* (2022) 22:56. Mousavi et al. *BMC Microbiology* (2022) 22:56

Formatted: Justified

(17) Katarzyna, S.; Monika, O.; Iwona, H.; and Tomasz, S. Resveratrol ameliorates inflammatory and oxidative stress in type 2 diabetic Goto-Kakizaki rats. *Biomedicine & Pharmacotherapy* 125 (2020) 110026

(18) Daniil, N. O.; Vladimir, V. C.; and Nadezhda, K. C. Polymeric Compounds of Lingonberry Waste: Characterization of Antioxidant and Hypolipidemic Polysaccharides and Polyphenol-Polysaccharide Conjugates from Vaccinium vitis-idaea Press Cake. *Foods* 2022, 11, 2801.

(19) Veronique, S. C.; Graeme, A. M.; Jennifer, H.; Jonathan; P. W.; Moore, S.; Paul, L.; Michael, F.; Kerenaftali, K.; Paul, J. T.; Maree, F.; Jeff, S.; Gethin, P. T.; Gary, J. C. Carl, M. J. K.; Johannes, B. P.; and Ingrid, J. H. Resveratrol Does Not Benefit Patients With Nonalcoholic Fatty Liver Disease. *Clinical Gastroenterology and Hepatology*. Volume 12, Issue 12, December 2014, Pages 2092-2103.e6

(20) Samir, B. T.; Juhee, J.; Byung, G. P.; Dabin, S.; Chang, S. L.; and Jae, K. S. Production of Resveratrol Glucosides and Its Cosmetic Activities. *Cosmetics* 2023, 10, 98., 1-19.

Formatted: Highlight

(21) Li-Xia Z.; Mo-Li, W.; Hong L.; Jia L.; and Li-Zhu, L. Efficacy and safety of intraperitoneally administered resveratrol against rat orthotopic ovarian cancers. *Cancer Management and Research*, 2019; 11, 6113–6124.

(22) Anthony, L.M. Junquera's Basic Histology text and atlas 14th edition, 2016, Editor; Lange MC Graw Hill Education, New York, pp. 1-3.

Formatted: Justified

(23) Khalid, E.I.; Mohsen, G.; Amel, O.B.; and Haseeb, A.K. Histopathology of the Liver, Kidney, and Spleen of Mice Exposed to Gold Nanoparticles. *Molecules* 2018, 23, 1848 Pp; 2 of 14

Formatted: Space After: 0 pt

Formatted: Justified

(24) SAS Statistical Analysis System, User's Guide. Statistical Version 9.1th ed. SAS Inst. Inc. Cary, NC, USA, 2012

Formatted: Space After: 0 pt, Don't adjust space between Latin and Asian text, Don't adjust space between Asian text and numbers

25- Zainab, Y. M.; Essam, F. Al-Jumaily and Nahi Y. Y. *In Vitro* Cytotoxic Study for Purified Resveratrol Extracted from Grape Skin Fruit *Vitis vinifera*. *Iraqi J Pharm Sci* ,2009, Vol.18 (Suppl.) page 19-25

Formatted: Justified

26- Gambini,J.; Inglés, M.; Olaso. G.; Lopez-Grueso,R.; Bonet-Costa, V.; Gimeno-Mallench,L.; Mas-Bargues, C.; Abdelaziz, K.M.; Gomez-Cabrera,M.C; and Borrás,C .Properties of Resveratrol: *In Vitro* and *In Vivo* Studies about Metabolism, Bioavailability, and Biological Effects in Animal Models and Humans.. *Oxidative Medicine and Cellular Longevity* 2015/ Volume 2015, 13 pages.

Formatted: Justified, Space After: 0 pt, Don't adjust space between Latin and Asian text, Don't adjust space between Asian text and numbers

27- Abdullah, S.; Anna, M. P.; Nadin, Y.; Hiba, H.; Sarah, H.; Dalal, A.; Anjud, Al. M.; Waeim, A. R.; Ali, H. E.; Gheyath, K. N.; and Gianfranco, P.Potential Adverse Effects of Resveratrol: A Literature Review . *Int. J. Mol. Sci.* 2020, 21, 2084

Formatted: Justified

28- Carmine, I.; Monica, A.; Giuseppe, M.; Roberta, S.; Marcello, D.; Mario, M.; Alessandro, F.; and Marcello, P. The Role of Resveratrol in Liver Disease: A Comprehensive Review from *In Vitro* to Clinical Trials. *Nutrients* 2021, 13, 933

Formatted: Justified, Space After: 0 pt, Don't adjust space between Latin and Asian text, Don't adjust space between Asian text and numbers

Formatted: Justified

29-Anna, M. P.; Roberta, G.; Annalisa, C.; Gheyath, K.; Nasrallah, A. S.; , Haissam, A.S.; Ali, H. E.; and Gianfranco, P. Flavin Oxidase-Induced ROS Generation Modulates PKC Biphasic Effect of Resveratrol on Endothelial Cell Survival. *Biomolecules* 2019, 9, 209.

30- Sebastiano, I.; Maria, N. M.; Ludovica, M. S.; and Lucia, M.Strategies to Improve Resveratrol Systemic and Topical Bioavailability: An Update, *Antioxidants* 2019, 8, 244;

31-Shosuke, I.; Yui, F.; Nina, M.; Makoto, O.; Kazumasa, W. Tyrosinase-catalyzed oxidation of resveratrol produces a highly reactive *ortho*-quinone: Implications for melanocyte toxicity. *Pigment Cell & Melanoma Research* Volume 32, Issue 6 p. 766-776.

Formatted: Justified

32-Jaqueline, de P. R.; Eliara, A.H.; Hauster, M.; Campos, De P.,R.; Soares, M.; David, D.S.; Luis, H.M.; and Ana,C. Human serum albumin-resveratrol complex formation: Effect of the phenolic chemical structure on the kinetic and thermodynamic parameters of the interactions. *Food Chemistry* 307 (2020) 125514.

33-Ning, X.; Ulrich, F.; and Huige, L.. Effects of resveratrol on eNOS in the endothelium and the perivascular adipose tissue. *Ann N Y Acad Sc.* 2017 Sep;1403(1):132-141.

34- Akhand, P.; Singh, Rachna, S.; , Sumit, S. V.; Vipin, R.; Catherine, H.; Kaschula, P. M.; and Subash, C. Health benefits of resveratrol: Evidence from clinical studies. *Medicinal Research Reviews.* 2019, Volume 39, Issue 5 p. 1851-1891 *nutrients*

35- Alice, C.; Christian, C.; and Josep, M. Resveratrol, Metabolic Syndrome, and Gut Microbiota. *Nutrients* 2018, 10, 1651;1-29.

36- Frederick, Y.K.; Siu, S. Y.; , Hui ,L.; and Shoujun, L. Galactosylated PLGA nanoparticles for the oral delivery of resveratrol: enhanced bioavailability and in vitro anti-inflammatory activity. *International Journal of Nanomedicine* 2018;13, 4133–4144

37-,Elsheikh E.M, P.M.; Hady, E.; Abdallah, SH.; andKonsowa, M.M Histogenesis of the rabbit liver (pars hepatica) with particular reference to the portal area.*Iraqi Journal of Veterinary Sciences*,2023;Vol. 37, No. 1, 2023 (177-182) .

38-Konrad, de- V.; Morné, S. and Vanessa, S. A Brief Updated Review of Advances to Enhance Resveratrol's Molecules 2021, 26, 4367.Bioavailability.

39-Noelia, D.; Mariana, A. F.; and David, D.Recent Strategies in Resveratrol Delivery Systems. Spanish National Research Council, Government agency.

40-John, M. P.. Resveratrol: Twenty Years of Growth, Development and Controversy,2019, *Biomol Ther* 27(1), 1-14 (2019)

UNDER PEER REVIEW