

Ulceration within a neurofibromatous nodule: A case report

Abstract:

Neurofibromatosis (NF1) is a genetic disorder characterized by the development of multiple benign nerve sheath tumors called neurofibromas. In approximately 8-12% of individuals with NF1, these neurofibromas can undergo malignant transformation into malignant peripheral nerve sheath tumors (MPNST). Here, we present the case of a 46-year-old male with known NF1, who presented with a large, progressively increasing neurofibromatous nodule in the occipital region that eventually ulcerated. The patient had a history of multiple neurofibromatous nodules covering his body since the age of 15. A team of expert plastic surgeons completely excised the tumor, and histopathological examination revealed a high-grade MPNST. The patient was informed about the clinical implications and treatment options. Genetic testing was also considered to assess the risk for relatives of the proband. This case underscores the importance of close monitoring and early detection of malignant transformation in patients with NF1. NF1 is associated with a wide range of clinical manifestations, including café-au-lait spots, Lisch nodules, and skeletal abnormalities. Regular clinical evaluations and imaging studies are crucial in patients with NF1 to detect any signs of malignant transformation early. Treatment options for MPNST include surgical resection, radiation therapy, and

chemotherapy, but the prognosis remains poor, emphasizing the importance of early intervention and genetic counseling in affected individuals and their families.

Keywords: Neurofibromatosis [NF-1], malignant peripheral nerve sheath tumours, recurrent lesion, Surgical excision

Introduction:

Neurofibromatosis type I (NF1) or Von Recklinghausen disease is an autosomal dominant genetic disorder affecting nerve cell growth and development leading to neoplasms developing on nerves, skin and other organs.¹ The condition produces considerable amount of disfigurement and individuals with neurofibromatous nodules at pressure points on the body are at increased risk of developing pressure ulcers due to constant pressure from external forces.² This genetic disorder has increased risk of developing benign and malignant tumours but currently there are no consensus guidelines for screening in NF1 patients. Hence, there is a need for strong suspicion of malignant transformation and consideration for differential diagnosis in cases of ulceration arising in longstanding nodules of neurofibromatosis. Malignant peripheral nerve sheath tumour (MPNST) is the most frequent malignant neoplasm associated with NF1 patients. This condition is potentially fatal with limited treatment options and they tend to occur at a younger age. Here we present one such case diagnosed with NF1 and now

presented with a rapidly increasing nodule with ulceration, which when excised was subsequently diagnosed as (MPNST).

Case report:

A 46-year-old male presented to the plastic surgery department suspecting pressure ulcer at the summit of a long-standing neurofibromatous nodule. He had multiple neurofibromas covering 70% of body surface area from 15 years of age. One of these nodules located in occipital region started progressively increasing in size for the past 3 months with recent onset of pain and ulceration. There was no positive family history of neurofibromatosis or any other malignancy in the immediate relatives. On examination, the nodule was 12x10x9 cm in size with ulceration at the apex, base showed slough, pus discharge and necrotic tissue. There was no induration or inflammation around the swelling [Figure 1]. MRI brain showed a large neurofibroma in the right posterior inferior occipital region with no intracranial extension. Hence a wide local excision of the entire nodule was done under general anaesthesia [Figure 2].

The wound was primarily closed with corrugated drain [Figure 3]. Post operative period was uneventful. The tumour was sent for histopathological examination. It was well circumscribed with a fleshy lobulated appearance. Light microscopy showed a cellular spindle cell neoplasm with fascicular and

herringbone arrangement [Figure 4a], considerable nuclear atypia and marked mitotic activity [Figure 4b]. There were also areas of necrosis [Figure 4c] with benign heterologous chondroid elements [Figure 4d].

Immunohistochemistry was performed, which showed strong vimentin positivity [Figure 5a], patchy S100 positivity [Figure 5b] and a very high Ki67 of 80% [Figure 5c]. A diagnosis of MPNST was eventually made. Postoperatively the patient was discharged and was advised to undergo genetic testing and consult radiation oncologist for further treatment options, however due to financial constraints, the patient did not comply with our suggestions and six months later he presented with 2 recurrent nodules of 11x10x8cms and 10x9x7cms size at the same site. [Figure 6]. Both the nodules were excised after excluding intracranial extension. Histopathology of these lesions confirmed recurrence of the same tumour; a high grade MPNST. After 1 year, the patient now presented with metastasis from MPNST at the L2/L3 vertebral level infiltrating the psoas muscle.

Discussion:

MPNSTs account for 10% of all soft tissue sarcomas but their incidence in patients with NF1 has been estimated to be 2-5%. They are highly aggressive tumours and are a leading cause for mortality in patients with NF1.³ MPNSTs are seen to have a strong association with a cancer predisposition condition called Neurofibromatosis type I - NF1 or Von Recklinghausen disease.

This is an autosomal dominant genetic disorder caused by mutation/deletion of the NF1 gene. This is a tumour suppressor gene which encodes a GTPase activating protein called neurofibromin and is located at chromosome 17q11. This altered gene product plays an important role in the dysregulation of tumour suppression by negatively regulating the RAS/MAPK signalling pathway which plays a crucial role in cell growth and survival.⁴ Neurofibromin acts by converting the active state of RAS to inactive state thereby prevents the cells from growing and dividing too rapidly in an uncontrolled way. Mutations in the NF1 gene results in a nonfunctional neurofibromin protein which downregulates the MAPK signalling pathway leading to excessive cell growth and tumour formation.⁵

A German pathologist Friedrich Daniel vonRecklinghausen initially identified NF1 as a genetic disease and provided insights into its pathogenesis.¹ Review of literature shows 50% of patients with MPNST have NF1, rest may be sporadic or due to radiation.¹⁰ NF1 gene mutation is dominant, so approximately half of the individuals with NF1 inherit the condition from one of their parents while the other half develop it as a result of spontaneous or de novo mutation⁶ as in our case. Since the inheritance pattern autosomal dominant NF1 cannot “skip a generation” and only one copy of mutated or deleted NF1 gene is sufficient to affect an individual. A detailed family history of our patient did not reveal any evidence of inherited NF1 gene; neither the parents nor any of the immediate family

members were affected, so the symptoms were entirely due to a new spontaneous mutation. The phenotypic expression and clinical severity in individuals with NF1 vary among genetically related family members and this is due to variable expressivity.⁹

While various cell types have been found in neurofibromas, there is strong evidence that the tumour cell of origin arises from the Schwann cell lineage.⁷ However, there is still uncertainty about the exact timing of when the tumour cell of origin appears during Schwann cell development. The development of Schwann cells starts with multipotent migratory neural crest stem cells (NCSCs) that differentiate into Schwann cell precursors (SCPs).⁸ These SCPs then give rise to immature Schwann cells (ISCs), which further differentiate into mature Schwann cells (MSCs) after birth. MSCs include myelinating cells that wrap around axons to form myelin sheaths and nonmyelinating cells that interact with small diameter axons to form Remak bundles. SCPs also have the potential to differentiate into melanocytes and fibroblasts. The distinct clinical features, location, and timing of cutaneous neurofibromas (cNFs) and plexiform neurofibromas (pNFs) suggest different cellular origins, which have been further investigated in preclinical models.⁸

The National Institutes of Health (NIH) Consensus Conference has formulated a diagnostic criterion for diagnosis of NF1 and this has been universally accepted by clinicians world-wide. All patients develop multiple benign dermal neurofibromas from the age of 10

to 15 which slowly increase in size due to hormonal factors during puberty. A wide variety of gliomas are also seen in NF1 patients like pilocytic astrocytomas, brain stem gliomas, and optic pathway gliomas. Other tumours frequently encountered in these individuals are pheochromocytoma and gastrointestinal tumours. Besides tumours, there are several non-tumour diagnostic features. NF1 is a neurocutaneous syndrome and a broad spectrum of cutaneous manifestations are encountered in them which include café-au-lait macules (CALMs light brown skin patches), intertriginous axillary skin freckling, Nevus Anemicus (a new diagnostic marker), Lisch nodules (melanocytic hamartomas in iris, usually bilateral).⁹ Another dermal association with NF1 is Juvenile Xanthogranuloma which is the most common non Langerhans cell histiocytosis. It is often present in the first year of life and is benign and self-limiting. The skin related changes pose minimal or no health risk and are more of a cosmetic concern. Neurocognitive deficits are also common in children with NF1; many patients experiencing learning difficulties, speech problems and seizures. Some children show extreme hyperactivity and behavioural problems. Additionally, skeletal abnormalities including scoliosis and long bone dysplasia, cardiovascular defects and secondary hypertension may also be encountered in individuals with NF1. Among craniofacial alterations, orbital and sphenoidal wing dysplasia are characteristic of NF1 and may also produce exophthalmia. Jaw bone lesions within the intra-osseous compartment have also been seen which cause

widening of the mandibular canal and enlargement of mandibular foramina which is not related to any tumour mass. Genetic testing to confirm the presence of NF1 gene is currently available, but seldom used in routine practice as the procedures employed for genetic characterization are very expensive, time consuming and labourintensive and also because most patients present in the appropriate clinical setting. However molecular diagnostic tools like next generation sequencing and NF1 mutation screening may be essential in mosaic cases of NF1 with segmental involvement and those with a mild phenotypic expression especially in early childhood.

Several complications can also arise in NF1 patients, the potentially fatal one being malignant peripheral nerve sheath tumour.¹⁰ This condition affects the quality of life as it is associated with excruciating pain from multiple tissue involvement, nerve damage and ulceration. Due to chronic pain, many patients resort to substance use disorder producing opioid overdose and dependence. Major depressive disorder and suicidal ideation are common among such patients.²

Malignancies tend to develop at a much younger age in patients with NF1 and have a poorer prognosis. MPNSTs that develop in children and adolescents with NF1, tend to be of low grade while high grade MPNSTs usually develop in patients with NF1 in their 20s or 30s. Patients with NF1 are seen to have a lesser life expectancy on average than the general population.¹¹ Those with

plexiform neurofibromas (localized and diffuse) have a higher risk for malignant transformation. Most arise from nerve bundles of extremities and trunk like brachial or sacral plexus.¹² They may present with neurological deficit, pain or tingling sensation. Compression of airway and spontaneous haemorrhage are complications witnessed in NF with plexiform neurofibroma.¹³ A condition associated with plexiform neurofibromas, Elephantiasis neuromatosain which there is massive enlargement of the skin and soft tissues is also reported.¹⁴ Our patient presented with a painful infected ulcer on a longstanding neurofibroma.

Ulceration in a neurofibroma may occur due to tumour invading the epidermis and should raise the suspicion of a malignant transformation^{15,16,17,18}. Some cases can produce bleeding or itching which further damages the skin layers leading to infection. They can also cause mass effect and pressure induced changes producing bony deformity.^{19,20}

Other differential diagnosis to be considered for ulcer in NF1 patients is cutaneous vasculopathy. In our case, the ulceration was initially suspected to be a pressure ulcer and later diagnosed to be MPNST by histopathology. Malignant peripheral nerve sheath tumours and vasculopathy are the most important causes of death in individuals with NF1.

Currently there are very limited therapeutic options for MPNST and a multidisciplinary management approach is necessary. The preferred treatment modalities include surgical excision with

adjuvant radiotherapy depending on the size, extent or location of the tumour.¹⁰ The tumor size, location and involvement of adjacent vital structures are factors involved incomplete resection. The surgeon should also consider and identify the risks of local recurrence and metastasis before proceeding with surgical removal. Complete resection may not be practically possible in some due to involvement of vital structures; surgical debulking with radiation therapy is widely used in such cases to control any residual disease. Systemic chemotherapy has a very limited role in its management. A few clinical trials for treating MPNST are currently underway with CDK inhibitors, however no FDA approved drugs are available at present. Non pharmacotherapy methods including a holistic approach targeting the body and mind may be useful to combat the chronic pain and psychological trauma that negatively impacts the patient's quality of life.

Conclusion:

In conclusion, NF1 is an incurable disease and MPNST is a dreaded complication encountered in these patients with a potentially fatal course highlighting the importance of regular screening and follow up. Though NF1 is a genetic condition with cancer predisposition, currently there are no consensus guidelines for screening. Owing to the complexity of clinical features and variable expressivity, genetic characterization using molecular diagnostic tools with a targeted gene panel may prove to be a valuable adjunct to confirm diagnosis in a few cases. Annual clinical surveillance is necessary to facilitate

early diagnosis and prompt surgical intervention needed to improve the quality of life and prevent mortality. A rapidly enlarging mass with ulceration should promptly raise the concern and suspicion of malignant transformation.

Ethical Approval:

As per international standards or university standards written ethical approval has been collected and preserved by the author(s).

Consent

As per international standards or university standards, patient(s) written consent has been collected and preserved by the author(s).

References:

1. Gerber PA, Antal AS, Neumann NJ, Homey B, Matuschek C, Peiper M, Budach W, Bölke E. Neurofibromatosis. *European journal of medical research*. 2009 Dec;14(3):102-5
2. Nnomadim OP, Helfrich BB, Nnomadim O. Complications of neurofibromatosis 1 (NF1) in an adult with multiple comorbidities. *Cureus*. 2021 Jul 20;13(7).
3. Pulliam S, Madwani K, Fox AD, El-Hachoum N, Ullah A, Patel N, Karim NA. Metastatic Malignant Peripheral Nerve Sheath Tumor (MPNST) in Neurofibromatosis Type 1: Challenges in Diagnosis and Management. *Cureus*. 2022 Jun 21;14(6).
4. Spyk, S.Lv., Thomas, N., Cooper, D.N. et al. Neurofibromatosis type 1-associated tumours: Their somatic

- mutational spectrum and pathogenesis. *Hum Genomics* 5, 623 (2011).
5. Pasmant E, Parfait B, Luscan A, Goussard P, Briand-Suleau A, Laurendeau I, et al. Neurofibromatosis type 1 molecular diagnosis: what can NGS do for you when you have a large gene with loss of function mutations? *European Journal of Human Genetics* [Internet]. 2014 Jul 30 [cited 2020 Oct 14];23(5):596–601.
 6. Jett, K., Friedman, J. Clinical and genetic aspects of neurofibromatosis 1. *Genet Med* 12, 1–11 (2010)
 7. Jiang C, McKay RM, Lee SY, Romo CG, Blakeley JO, Haniffa M, et al. Cutaneous neurofibroma heterogeneity: Factors that influence tumor burden in neurofibromatosis type 1. *J Invest Dermatol* [Internet]. 2023;143(8):1369–77
 8. Bui A, Jiang C, McKay RM, Klesse LJ, Le LQ. Insights into the Pathogenesis of NF1-Associated Neoplasms. *JID Innov.* 2021 Sep;1(3):100044. Doi: 10.1016/j.xjidi.2021.100044. Epub 2021 Aug 20. PMID: 34604833; PMCID: PMC8486282.
 9. Poplousky D, Young JN, Tai H, Rivera-Oyola R, Gulati N, Brown RM. Dermatologic Manifestations of Neurofibromatosis Type 1 and Emerging Treatments. *Cancers* [Internet]. 2023 Jan 1 [cited 2023 Aug 18];15(10):2770.
 10. Leroy K, Dumas V, Martin-Garcia N, Falzone MC, Voisin MC, Wechsler J, et al. Malignant Peripheral Nerve Sheath Tumors Associated With Neurofibromatosis Type 1: A Clinicopathologic and Molecular Study of 17 Patients. *Archives of Dermatology* [Internet]. 2001 Jul;137(7):908–13.

11. Rasmussen SA, Yang Q, Friedman JM. Mortality in Neurofibromatosis 1: An Analysis Using U.S. Death Certificates. *The American Journal of Human Genetics*. 2001 May;68(5):1110–8.
12. Mattox AK, Douville C, Silliman N, Ptak J, Dobbyn L, Schaefer J, Popoli M, Blair C, Judge K, Pollard K, Pratilas C. Detection of malignant peripheral nerve sheath tumors in patients with neurofibromatosis using aneuploidy and mutation identification in plasma. *Elife*. 2022 Mar 4;11:e74238.
13. Copley-Merriman C, Yang X, Juniper M, Amin S, Yoo HK, Sen SS. Natural History and Disease Burden of Neurofibromatosis Type 1 with Plexiform Neurofibromas: A Systematic Literature Review. *Adolescent Health, Medicine and Therapeutics [Internet]*. 2021 May 19 [cited 2022 Jan 26];12:55–66.
14. Patel N, Gregory Scott Stacy. Musculoskeletal Manifestations of Neurofibromatosis Type 1. *American Journal of Roentgenology*. 2012 Jul 1;199(1):W99–106.
15. Pemov, A.; Li, H.; Presley, W.; Wallace, M.R.; Miller, D.T. Genetics of human malignant peripheral nerve sheath tumors. *Neurooncol. Adv.* 2019, 2 (Suppl. 1), i50–i61.
16. Brohl, A.S.; Kahen, E.; Yoder, S.J.; Teer, J.K.; Reed, D.R. The genomic landscape of malignant peripheral nerve sheath tumors: Diverse drivers of Ras pathway activation. *Sci. Rep.* 2017, 7, 14992.
17. Kiuru, M.; Busam, K.J. The NF1 gene in tumor syndromes and melanoma. *Lab. Investig.* 2017, 97, 146–157.

18. Aldelaimi, T. N., Khalil, A. A. (2013). Massive pediatric facial plexiform neurofibromatosis in Iraq. *J Dent Oral Disord Ther*, 1(1), 3. DOI: <http://dx.doi.org/10.15226/jdodt.2013.00104>
19. Gracia-Cazaña T, de la Fuente S, Concellón MA, Ara-Martín M. Lower Extremity Skin Ulcer Associated with Neurofibromatosis Type 1: A Case Report. *Wounds: a Compendium of Clinical Research and Practice*. 2019 Oct 1;31(10):E65-7.
20. Afrah A Aldelaimi, Hamid H Enezei, Tahrir N Aldelaimi, Khalil Abdulla Mohammed, Tumors of Craniofacial Region in Iraq (Clinicopathological Study), *J Res Med Dent Sci*, 2021, 9 (1): 66-71

Figure 1: Ulceration with slough and necrotic tissue in the Occipital Neurofibroma

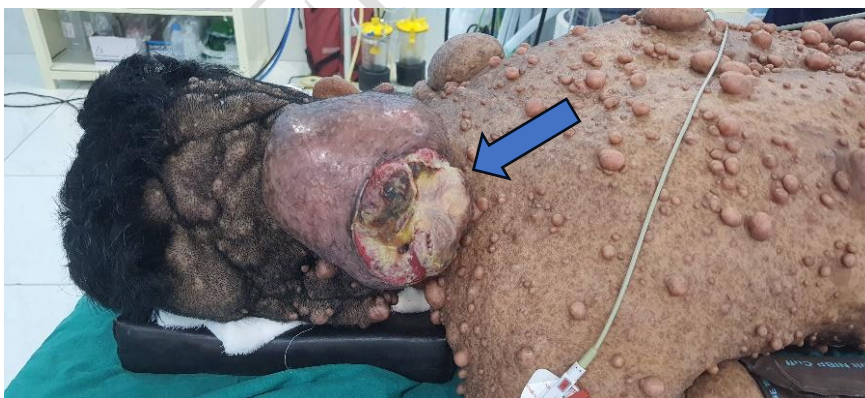


Figure 2: Specimen after wide local excision of tumor

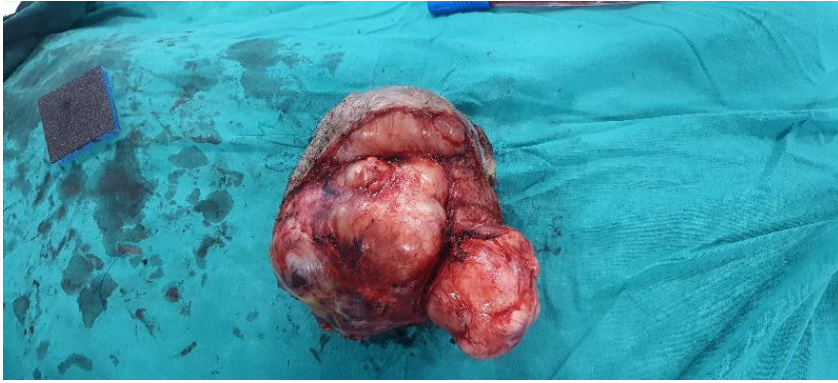


Figure 3: Primary closure of surgical excision site done after placing a corrugated drain

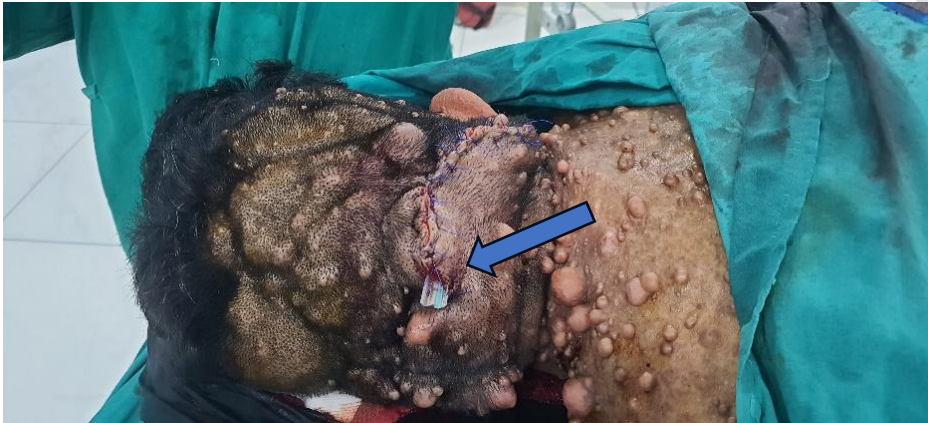

Figure 4: Histopathology showing cellular spindle cell neoplasm arranged in fascicles

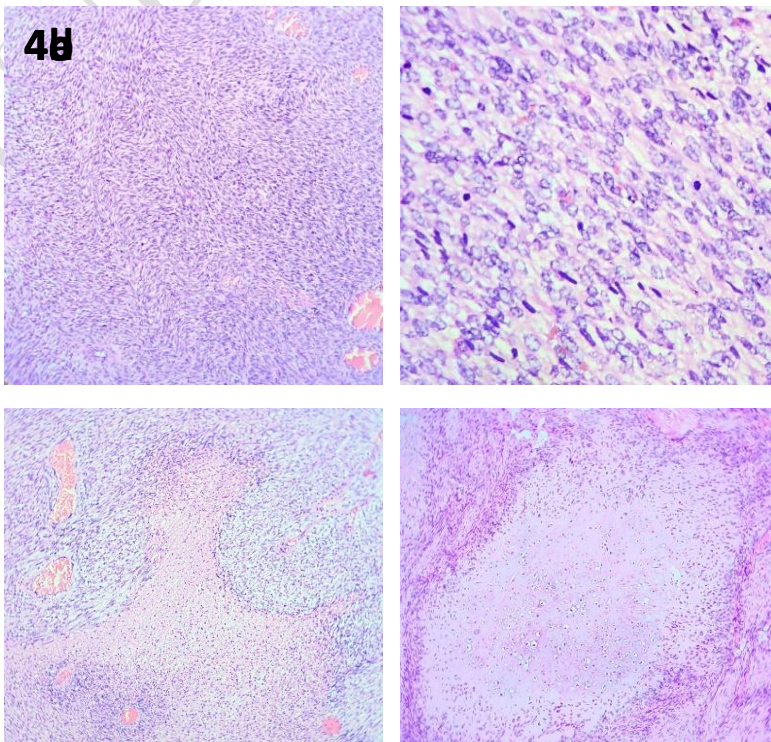


Figure 5: Immunohistochemistry showing strong diffuse vimentin positivity

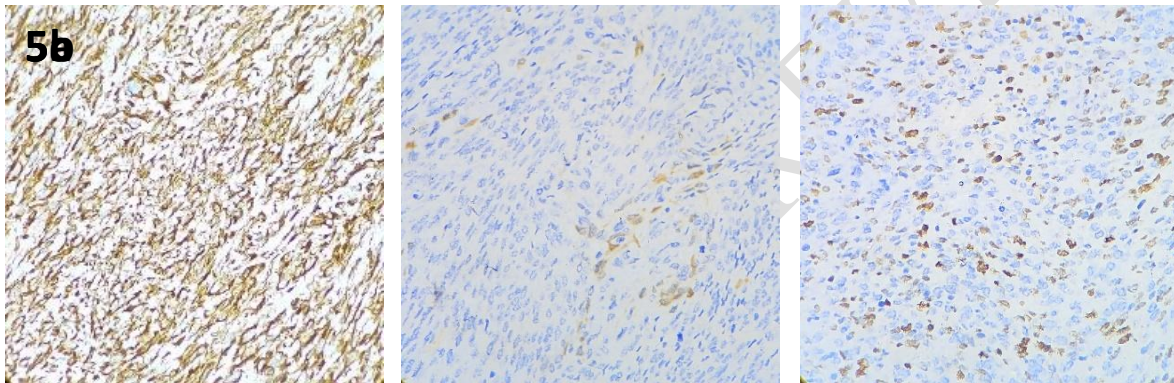


Figure 6: Recurrent tumor at the same site

