

DACRYOCYSTITIS COMPLICATED WITH ABSCESS: A CASE REPORT

ABSTRACT

Objective: To describe a case of dacryocystitis complicated by an abscess.

Case: This is the case of a 66-year-old patient who had been treated for dacryocystitis for two months, complicated by a recurrent abscess. The Treatment consisted of antibiotic therapy and drainage of the abscess, which progressed well. A dacryocystorhinostomy was performed after infection control.

INTRODUCTION

Dacryocystitis is an obstruction of the lacrimal duct secondary to inflammatory and/or infectious damage to the lacrimal mucosa **1**. It is a very common pathology, the chronic form of which is more common in people over 60. In the absence of appropriate treatment, it can become complicated, leading to abscesses that make management complex **2**. We report the case of a patient admitted for dacryocystitis complicated by an abscess.

CASE REPORT

This was a 66-year-old patient with a history of dacryocystitis, which had been treated two months previously. He was admitted to the emergency department with a red, painful swelling over the right eye that had been present for four days, and a fever that was not quantified.

Examination revealed impenetrable visual acuity on the right, with a value of 09/10 on the left.

The right eye showed palpebral oedema; a red, painful, hard swelling on palpation located at the level of the medial canthus; with no possibility of spontaneous eyelid opening. Examination of the anterior and posterior segments not performed

Left eye: ophthalmological examination was normal

An emergency orbito-cerebral CT scan showed hypodense images of necrosis with a cloisonné appearance and peripheral contrast in favor of an extra-conical orbital abscess in the medial canthus of the right eye.

Biological tests revealed an inflammatory syndrome with elevated polymorphonuclear cells and CRP.

Emergency treatment consisted of broad-spectrum antibiotic therapy with: Amoxicillin-clavulanic acid + metronidazole (intravenous).

Drainage of the abscess was performed within 48 hours, yielding around 3ml of pus and we applied pressure dressing. Corticosteroid therapy was added. The abscess improved well after drainage. The bacteria isolated was *Staphylococcus Aureus* Meti S and were sensitive to treatment (Shown in post-drainage image). After 05 days of hospitalization, the patient was discharged with a week's follow-up antibiotic therapy, a lacrimal duct examination and a dacryocystorhinostomy after complete control of the infection.

The patient returned for follow-up with further recurrence of his swelling and fistulization of the abscess, despite a well-managed course of antibiotics.

The patient was readmitted to hospital, and the swab found the previous bacterial isolate again

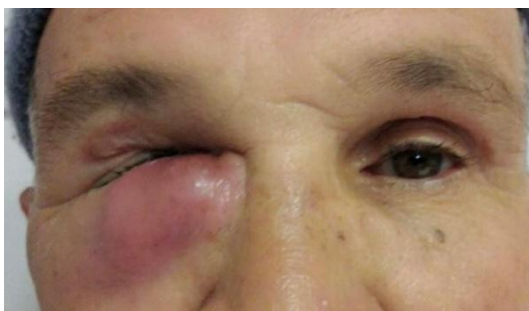

Figure 1: Hard swelling of the medial canthus, red and painful

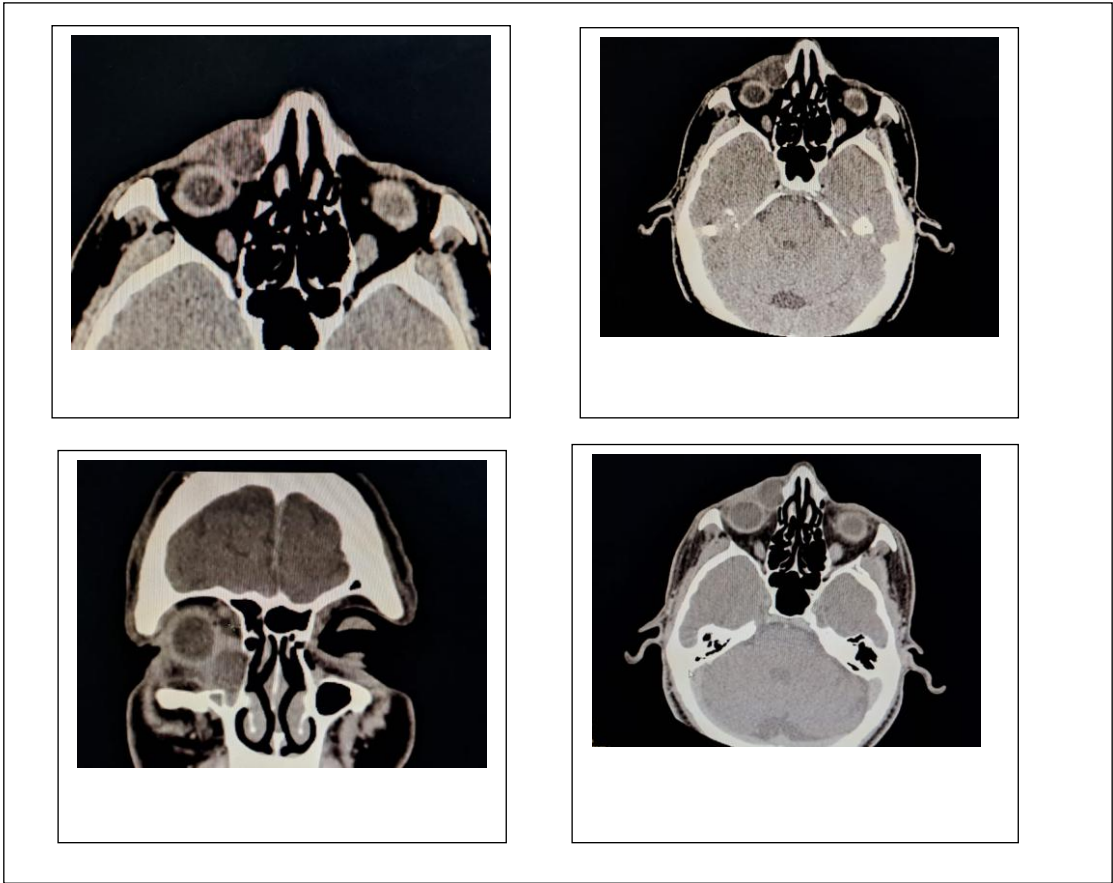


Figure 2: Orbito-cerebral scan of the patient

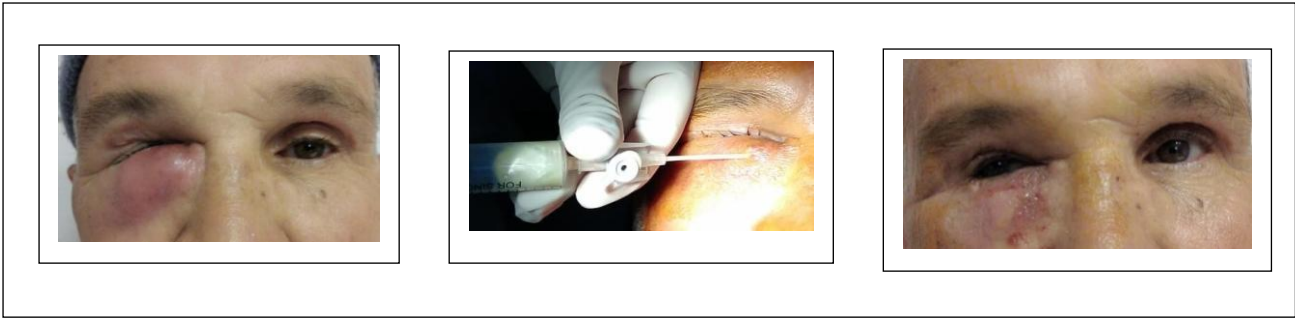

Figure 3: Appearance of abscess before and after first drainage

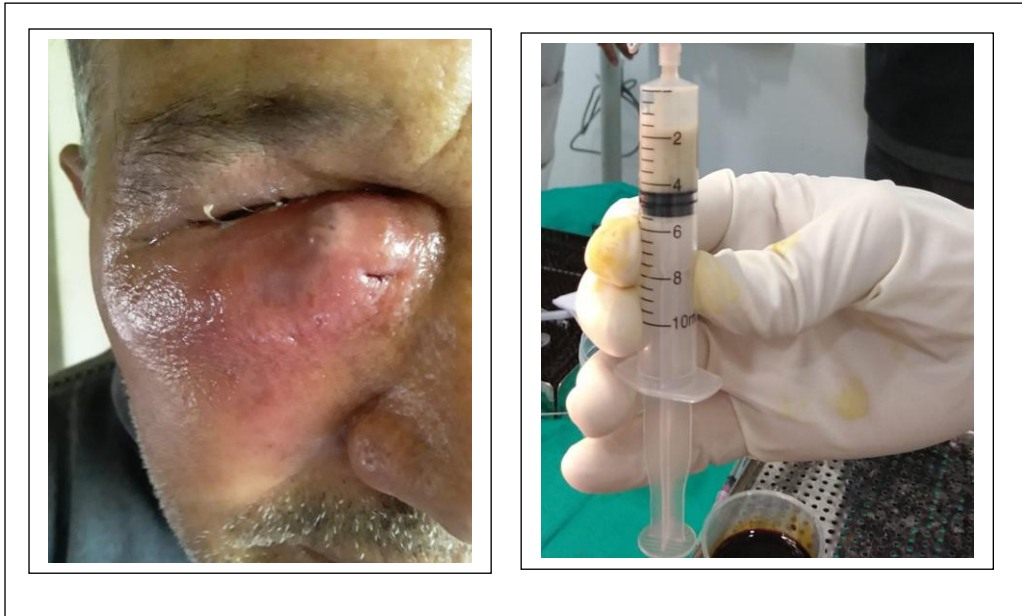

Figure 4: Appearance of abscess on inspection and amount of pus drained

DISCUSSION

Chronic dacryocystitis occurs secondary to untreated or inadequately treated acute dacryocystitis. Epidemiologically speaking, chronic dacryocystitis affects people over the age of 60, with a predominance of women, whereas acute dacryocystitis affects children 3-4. Infectious etiologies are multiple, but are dominated by microbiological, immunological, mechanical and traumatic agents 2. In the case of chronic dacryocystitis, the lacrimal mucosa is predisposed to acute reactivation by several mechanisms: superinfection of the lacrimal sac, or microbial pullulation of organisms present in the sac and becoming pathogenic 5-6. The germs most frequently implicated are staphylococci, streptococci, Haemophilus, and pseudomonas 7-8. The initial treatment for bacterial dacryocystitis is empirical parenteral broad-spectrum antibiotic therapy, which is then adapted according to the results of the antibiogram, followed by a second course of oral antibiotics.⁹ Due to anatomical barriers, severe orbital complications of dacryocystitis are rare, and are indicative of severe involvement and a chronic course. Most often, the course is favorable under medical treatment, but complications such as orbital

cellulitis, abscesses, meningitis, thrombosis of the cavernous sinus and even life-threatening situations may arise, often requiring surgical intervention 6-7. In case of abscess, as in our case, surgical drainage is performed as a matter of urgency, combined with antibiotic therapy with cephalosporins, protected amoxicillin, clindamycin, vancomycin and metronidazole in case of anaerobes 7-10. Once the infection is under control, dacryocystorhinostomy is performed 11.

CONCLUSION

Bacterial dacryocystitis is a frequent pathology, with a favorable outcome when treated early and appropriately. Any negligence in these cases exposes patients to complications that are often severe and avoidable.

Consent

As per international standards or university standards, patient(s) written consent has been collected and preserved by the author(s).

REFERENCES

- 1-Bakshi SS. Acute dacryocystitis. *Cleve Clin J Med.* 2020 Jul 31;87(8):477. doi: 10.3949/ccjm.87a.19121. PMID: 32737045.
- 2- Badr jatik, mohamedelBelhadji Chronic dacryocystitis in adults: epidemiological, clinical and therapeutic aspects; French Ophthalmology Society; 2020
- 3- El Khaoua, M., Elyamouni, O., Tzili, N., Mellal, Z., Abdallah, E., & Berraho, A. (2013). Chronic dacryocystitis in children. *Maroc Medical*, 35(4).
- 4--DU CHAPTER, P. L. A. N. (2022). Orbital infections. *Imaging of the orbit, membranous labyrinth and skull base*, 37.
- 5- Agharbi, F.Z. (2020). Dacryocystitis complicated by cellulitis. *PAMJ-Clinical Medicine*, 2(101).
- 6-BTS, V., YA, A., NH, K., KDC, N., KE, A., KV, N. G., & NB, K. Orbital and periorbital cellulitis: epidemiological, diagnostic and therapeutic aspects at the center university hospital of Bouaké.

- 7- Luo B, Li M, Xiang N, Hu W, Liu R, Yan X. The microbiologic spectrum of dacryocystitis. *BMC Ophthalmol.* 2021 Jan 11;21(1):29. doi:10.1186/s12886-020-01792-4. PMID: 33430825; PMCID: PMC7802334.
- 8- Diabaté, N. C. R. (2021). Results of microbiological analyzes in dacryocystitis at IOTA University Hospital in Bamako.
- 9- Bekoin, F. (2005). 587 Acute dacryocystitis: retrospective assessment over 4 years. *French Journal of Ophthalmology*, 28, 309.
- 10- Ali, T. B., Ouaggag, B., Jellab, B., Khoumiri, R., Machmoumi, F., Hajji, I., & Moutaouakil, A. (2008). 752 Acute dacryocystitis complicated by blindness: report of a case. *French Journal of Ophthalmology*, 31, 225.
- 11- McEwen DR. Surgical treatment of dacryocystitis. *AORN J.* 1997 Aug;66(2):268-70, 273, 275-8 passim; quiz 281. doi: 10.1016/s0001-2092(06)62795-6. PMID: 9513697