

# Adenoid cystic carcinoma of the external auditory canal

## Abstract

There are very few primary malignant tumours of the external auditory canal, and adenoid cystic carcinoma is an extremely rare tumour. The majority of patients present with severe or dull unilateral pain, reduced hearing, and a mass in the external ear. Accounting for around 5%. The majority of patients present with severe or dull, constant and prolonged unilateral pain, reduced hearing and a mass in the external ear. These tumours are treated with aggressive surgical excision and adjuvant radiotherapy. Despite this, the overall prognosis is poor due to recurrence and distant metastases. We report a rare case of cystic adenoid carcinoma in a 75-year-old man who presented with right ear fullness for one year. He was treated by wide local excision of the mass followed by adjuvant radiotherapy.

**Keywords:** adenoid cystic carcinoma, external auditory canal, Hearing loss, Otagia, Ceruminous gland malignancy surgery, parotidectomy.

## Introduction

Malignant tumors of the external acoustic meatus (MAE) are rare, representing <0.2% of head and neck cancers. Only 4% of cancers of the outer ear are confined to the EAC. [1, 2] The majority of histological types are squamous cell carcinomas. Other carcinomas of the lining epithelium of the EAM are also occasionally reported. Glandular origin **even more rare. These tumors are**, in decreasing order of frequency, cystic adenoid carcinomas (CAK) or cylindromas, adenocarcinomas and mucoepidermoid tumors [3]. In the external acoustic meatus, the origin of CAK appears to be the ceruminous glands [4]. The prognosis of CAC depends essentially on local control [3, 5].

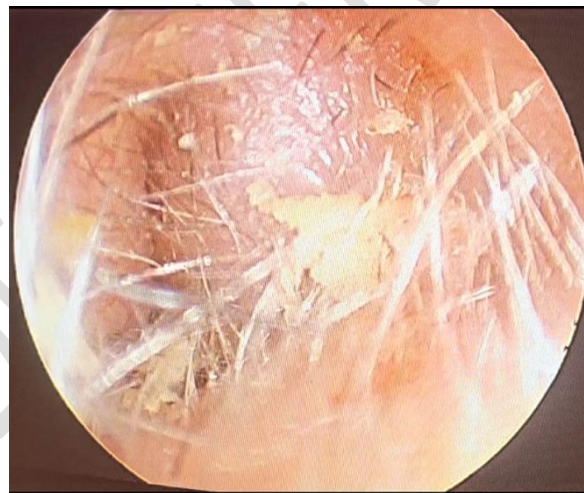Clinical signs and symptoms of EAC cancer typically include otorrhea, hearing loss, EAC tumors, and earaches. They might, however, be non-specific. While early intermittent earache is the most common complaint among patients with EAC cancer, some older **patients** may experience otorrhea and infection [6, 7]. As a result, early identification is frequently overlooked, and benign neoplasms of the external ear canal, external otitis, and chronic otitis media may all be mistakenly classified as carcinoma [8].

The primary treatment for ACC of the EAC is surgery, which is followed by radiation therapy. However, there is a significant risk of morbidity associated with both surgery and radiation [9, 10], as well as an increased chance of recurrence in situations of inadequate excision [15]. A high probability of direct intracranial expansion and perineural and bone invasion are linked to ACC of the EAC [15]. Many years following surgery, recurrence has been noted, and lung metastasis has been primarily blamed for mortality [15, 11, 12].

Only a small number of reports [15, 11–13, 17] have, to the best of our knowledge, included more than three patients with ACC of the EAC; the majority of investigations [7, 14–16] have reported on individual instances. Because ACC of the EAC is a rare disease, standards for diagnosing and treating this malignancy are lacking, and little is known about the disease's natural course or course of treatment. Thus, reviewing the clinical characteristics of patients with ACC of the EAC who were diagnosed and treated at a single center was the goal of the current investigation. It was expected that the findings will further our understanding of this illness and inform the development of better diagnostic and therapeutic approaches.

## Case report

A 75-year-old man presented with progressively reduced hearing and **fullness** of the right ear for the past 1 year. There was no history of ear pain or recurrent ear discharge. He had no history of tinnitus, bleeding from ear or **vertigo**. No previous history of surgery or trauma was noted. Physical examination showed **no** cervical lymphadenopathy. Examination of the parotid gland and facial nerve was unremarkable. Otoscopic examination revealed a mass filling the entire external auditory meatus. **The surface was** pinkish, smooth, and firm in consistency, occluding the entire ear canal. No collection of discharge was seen in the EAC or surrounding the mass. The mass is **non-tender** and does not bleed upon palpation. There was no other significant findings on examination. [Figure 1, 2].



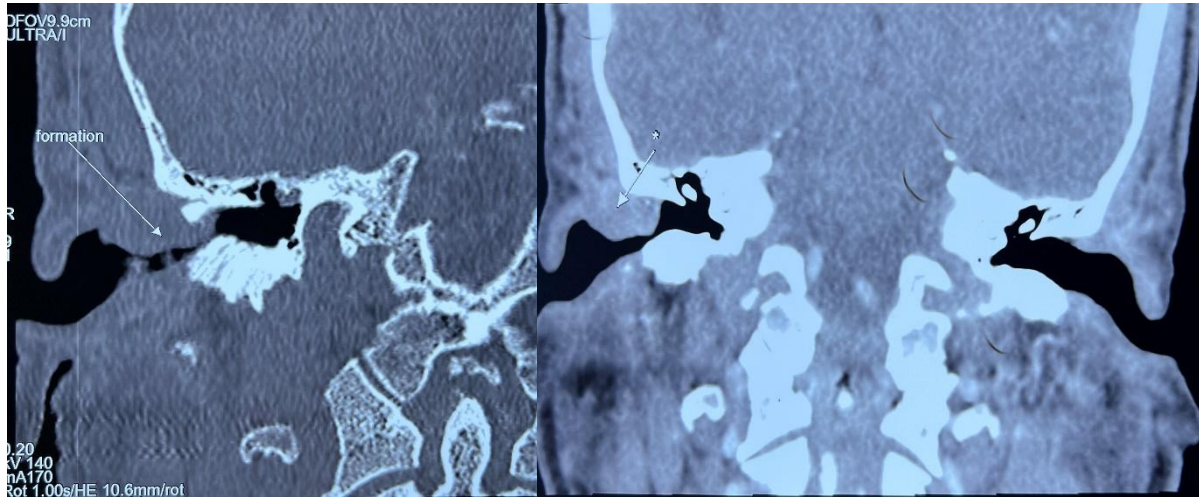
**Figure 1:** Image of a well-limited rounded mass fill-up the entire external auditory canal



otoscopy.mp4

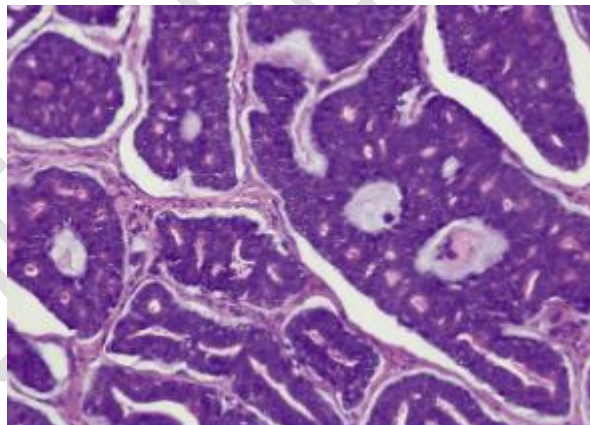
**Figure 2:** Otoscopy of the right ear round mass fill-up the entire external auditory canal

The audiogram shows conductive hearing loss over the right ear. The parotid gland is normal and the facial nerve is intact. High-resolution computed tomography (CT) shows the right EAC soft tissue mass at the cartilaginous and bony junction of EAC, at the expense of its postero-superior wall. **The wall was** almost completely obliterating the ear canal, without bony erosion, measuring 20 x 13 mm in axial section. **The mass** does not extend to the tympanic membrane, middle ear, and mastoid cavity [Figure 3].



**Figure 3:** CT of rocks in coronal and axial cuts mass occupying the external auditory canal well limited of tissue density without extension in the middle ear nor bone lysis.

Biopsy of the mass was performed. Histopathological examination revealed a grade 2 cystic adenoid carcinoma [Figure 4].



**Figure 4:** Histological section showing infiltration of the duct by a cystic adenoid carcinoma with tubular and cribriform aspects

The right EAC mass was excised via an endoscopic transcanal approach under general anesthesia. **Reconstruction** with split thickness graft **was performed, and then followed** by adjuvant radiotherapy. Postoperatively, the patient was well and the otoendoscopic view showed a well-taken SSG site.

## Discussion

About 5% of cases of Adenoid Cystic Carcinoma (ACC) arise from the EAC; the majority (more than 80%) are squamous cell carcinoma [1]. Consequently, in clinical practice, adenoid cystic carcinoma

originating from the EAC is extremely uncommon. The salivary glands, oral cavity, palate, nasal cavity, and nasopharynx are typically home to ACC of the head and neck [2].

The diagnosis of cystic adenoid carcinoma (CAK) of the external meatus is often delayed. The largest series of CAK of the external acoustic meatus is that of Xiaojun Jianget al. reporting 23 cases [17]. This tumor is insidious and slow-growing [18, 19]. The average time between onset of symptoms and diagnosis is several years. This delay in diagnosis is mainly due to **non-specific clinical signs**. Radiological signs are discrete and rarely suggestive of malignancy. The most frequent symptom in the literature is treatment-resistant otalgia. This symptom is almost constant and is thought to be due to tumour invasion of adjacent sensory nerves or of the periosteum and adjacent perichondrium.

An uncommon type of adenocarcinoma that develops from glandular tissue is called ACC. While the cause of primary ACC of the EAC is still unknown, some theories propose that eccrine sweat glands, ectopic salivary glands, or ceruminous glands are the source of the cancer [7]. Adenoma, papilloma, tuberculosis, and tumors like squamous cell carcinoma, adenocarcinoma, basal cell carcinoma, and mucoepidermoid carcinoma are among the differential diagnoses for ACC of the EAC [7]. Studies using immunohistochemistry on salivary gland ACC revealed that certain cells express carcinoembryonic antigen (CEA) [20], and that the expression of p53 is linked to unfavorable results [21]. Nevertheless, there is a paucity of immunohistochemistry data for p53 and CEA in the ACC of the EAC.

There is no consensus on the use of imaging for extension assessment. Local assessment involves CT scan, more or less combined with MRI. For distant assessment, a chest X-ray or CT scan is required. This should be discussed on a case-by-case basis, depending on the location and size of the tumour. In our case, the time **was** short, and the chest X-ray was normal.

The most useful method for displaying infiltration into surrounding structures is gadolinium-DTPA contrast enhanced MRI [22, 23]. The usual course of treatment for controlling local disease is aggressive surgical resection, combined with adjuvant radiotherapy [24]. Positive surgical margins, involvement of the parotid gland and surrounding structures, and bone involvement are important prognostic factors [12, 24]. The risk of recurrence due to its metastatic potential is estimated by some authors at 30% [25]. Secondary sites are mainly **the lungs**, but also bone, kidney and brain [23].

In the literature, the diagnosis of primary cutaneous CAK can only be considered once a cutaneous extension of a tumour developed in a neighbouring structure or a distant metastasis of a salivary CAK has been strictly ruled out [26].

Selective removal may be discussed on a case-by-case basis, depending on the extent of the tumour. In our case, the tumour was localized and lymph node dissection was not performed. Complementary radiotherapy is not indicated in the case of wide resection with healthy margins [5]. There is no consensus on adjuvant chemotherapy. It was decided on the basis of the high risk of recurrence.

Additionally, the treatment of the parotid gland is controversial. Some authors consider that superficial parotidectomy is suitable for all patients with ACC of the EAC, even in the early stages [8]. The EAC and parotid gland have a close histological association. Additionally, the Santorini cracks provide a way for invading the parotid gland [8]. Nevertheless, it is recommended that patients with early disease undergo superficial parotidectomy at the same time as lesion resection because the lack of recurrence observed in the present study may be caused by a combination of factors such as a short follow-up and a small sample size. The parotid gland can be partially removed to ensure safety. If the parotid gland is markedly invaded, it can be completely removed.

According to Moffat et al. [27] radiation therapy can eliminate subclinical tumor foci and improve the success of surgery. When achieving safe margins is challenging for advanced cancers, radiotherapy may be very beneficial. Furthermore, Chen et al. [28] proposed that postoperative radiation therapy utilizing more than 60 Gy of radiation can successfully avert postoperative ACC recurrence in the head and neck. According to Silverman et al. [29] people with low clinical stage and negative margins following the initial surgery do not require radiotherapy, but those with advanced clinical disease may need postoperative radiotherapy. There has been a suggestion that chemotherapy has little effect on ACC patients' survival [30].

## Conclusion

CAK is a rare tumour of the external acoustic meatus. The diagnosis is based on histological examination optimised by deep and wide biopsy. Pathologists must consider this type of tumour in this atypical location. Treatment is primarily surgical, with a wide, total and sometimes radical excision. The particularity of CACs is their nervous tropism. It is important to perform a parotidectomy with dissection of the facial nerve in order to dissection of the facial nerve, in order to control any possible dissemination along the perineurium of this nerve. The cervical should be discussed in view of the low lymphocytosis of this tumour. Additional external radiotherapy is indicated by most authors in order to reduce the risk of local recurrence, which remains the most important prognostic factor. Early aggressive surgical management with adjuvant radiotherapy may help to prevent distant metastasis

## HIGHLIGHTS

- Describe and study the case of a rare location of Adenoid cystic carcinoma of the external auditory canal
- Highlight the role of the biopsy in the histological study to make the diagnosis
- The management varies according to the size of the tumor and the staging assessment

## References

1. Moody SA, Hirsch BE, Myers EN. Squamous cell carcinoma of the external auditory canal: An evaluation of a staging system. *Am J Otol* 2000; 21:582–8.
2. Kuhel WI, Hume CR, Selesnick SH. Cancer of the external auditory canal and temporal bone. *Otolaryngol Clin North Am* 1996;29:827–52.
3. Dehesdin D, Andrieu-Guitrancourt J, Hemet J, Cauchois P, Marie JP, Vinel V. Tumeurs glandulaires du conduit auditif externe. *Ann Otolaryngol Chir Cervicofac* 1993;110:70–4.
4. Wassef M, Thomas V, Deffrennes D, Lacau Saint-Guily J. Les carcinomes adénoïdes kystiques cutanés primitifs. *Ann Pathol* 1995; 15:150–5.
5. Perzin KH, Gullane P, Conley J. Adenoid cystic carcinoma involving the external auditory canal. A clinicopathologic study of 16 cases. *Cancer* 1982; 50:2873–83
6. Gu FM, Chi FL, Dai CF, Chen B, Li HW. Surgical outcomes of 43 cases with adenoid cystic carcinoma of the external auditory canal. *Am J Otolaryngol*. 2013; 34:394–398. doi: 10.1016/j.amjoto.2013.01.018.
7. Liu SC, Kang BH, Nieh S, Chang JL, Wang CH. Adenoid cystic carcinoma of the external auditory canal. *J Chin Med Assoc*. 2012; 75:296–300. doi: 10.1016/j.jcma.2012.04.007
8. Zhang T, Dai C, Wang Z. The misdiagnosis of external auditory canal carcinoma. *Eur Arch Otorhinolaryngol*. 2013; 270:1607–1613. doi: 10.1007/s00405-012-2159-4.

9. Kwok HC, Morton RP, Chaplin JM, McIvor NP, Sillars HA. Quality of life after parotid and temporal bone surgery for cancer. *Laryngoscope*. 2002; 112:820–833. doi: 10.1097/00005537-200205000-00010.
10. Wang CC. Radiation therapy in the management of carcinoma of the external auditory canal, middle ear, or mastoid. *Radiology*. 1975; 116:713–715. doi: 10.1148/116.3.713.
11. Pulec JL, Parkhill EM, Devine KD. Adenoid cystic carcinoma (Cylindroma) of the external auditory canal. *Trans Am Acad Ophthalmol Otolaryngol*. 1963; 67:673–694.
12. Perzin KH, Gullane P, Conley J. Adenoid cystic carcinoma involving the external auditory canal. A clinicopathologic study of 16 cases. *Cancer*. 1982; 50:2873–2883. doi: 10.1002/1097-0142(19821215)50:12<2873:AID-CNCR2820501230>3.0.CO;2-R.
13. Choi JY, Choi EC, Lee HK, Yoo JB, Kim SG, Lee WS. Mode of parotid involvement in external auditory canal carcinoma. *J Laryngol Otol*. 2003; 117:951–954. doi: 10.1258/002221503322683821.
14. O'Neill PB, Parker RA. Sweat gland tumours (ceruminomata) of external auditory meatus. *J Laryngol Otol*. 1957; 71:824–831. doi: 10.1017/S002221510005252X.
15. Dong F, Gidley PW, Ho T, Luna MA, Ginsberg LE, Sturgis EM. Adenoid cystic carcinoma of the external auditory canal. *Laryngoscope*. 2008; 118:1591–1596. doi: 10.1097/MLG.0b013e31817c42a8.
16. Nayak SP, Walke VA, Helwatkar SB, Bobhate SK. Adenoid cystic carcinoma of the external auditory canal: Report of two cases. *Indian J Pathol Microbiol*. 2009; 52:540–542. doi: 10.4103/0377-4929.56157.
17. Vishnu Prasad, Vijendra S Shenoy, Raghavendra A Rao, Panduranga M Kamath, and Haseena Shihab. Adenoid Cystic Carcinoma— A rare Differential Diagnosis for a mass in the External Auditory Canal. *J Clin Diagn Res*. 2015 Jan; 9(1): MD01–MD02
18. Perzin KH, Gullane P, Conley J. Adenoid cystic carcinoma involving the external auditory canal. A clinicopathologic study of 16 cases. *Cancer* 1982; 50:2873–83.
19. Fenniche S, Haouet S, Mdimagh H, et al. Les tumeurs des glandes cérumineuses. *Ann Pathol* 1995;15:147–9.
20. Triantafillidou K, Dimitrakopoulos J, Iordanidis F, Koufogiannis D. Management of adenoid cystic carcinoma of minor salivary glands. *J Oral Maxillofac Surg*. 2006; 64:1114–1120. doi: 10.1016/j.joms.2005.06.017.
21. De Lucia A, Gambardella T, Carra P, Motta G. A case of highly aggressive adenoid cystic carcinoma of the external auditory canal. *Acta Otorhinolaryngol Ital*. 2004;24:354–356.
22. Sigal R, Monnet O, de Baere T, Micheau C, Shapeero LG, Julieron M, et al. Adenoid cystic carcinoma of the head and neck: evaluation with MR imaging and clinical-pathologic correlation in 27 patients. *Radiology*. 1992; 184:95–101.
23. Conlin PA, Mira JL, Graham SC, Kaye KS, Cordero J. Ceruminous gland adenoid cystic carcinoma with contralateral metastasis to the brain. *Arch Pathol Lab Med*. 2002; 126:87–89.
24. Zainor S, Mamat H, Saad SM. Adenoid cystic carcinoma of external auditory canal: A case report. *Egyptian Journal of Ear, Nose, Throat and Allied Sciences*. 2013;14(1):41–44.
25. Bassereau G, Brasnu D, Roux FX, Menard M, Laccourreye H. Carcinome primitif du conduit auditif externe et de l'oreille moyenne (à propos de 14 cas). *Ann Otolaryngol Chir Cervicofac* 1989;106:169–75.

26. Buda-Nowak A, Swiader M, Puskulluoglu M, Dyduch G, Krupinski M, Krzemieniecki K. Adenoid cystic carcinoma of the external auditory canal with metastases to lymph nodes and lungs-problematic diagnosis and treatment based on a case report. *Przegl Lek.* 2015; 72:383–386.
27. Moffat DA, Wagstaff SA, Hardy DG. The outcome of radical surgery and postoperative radiotherapy for squamous carcinoma of the temporal bone. *Laryngoscope.* 2005; 115:341–347. doi: 10.1097/01.mlg.0000154744.71184.c7
28. Chen AM, Bucci MK, Weinberg V, Garcia J, Quivey JM, Schechter NR, Phillips TL, Fu KK, Eisele DW. Adenoid cystic carcinoma of the head and neck treated by surgery with or without postoperative radiation therapy: Prognostic features of recurrence. *Int J Radiat Oncol Biol Phys.* 2006; 66:152–159. doi: 10.1016/j.ijrobp.2006.04.014.
29. Silverman DA, Carlson TP, Khuntia D, Bergstrom RT, Saxton J, Esclamado RM. Role for postoperative radiation therapy in adenoid cystic carcinoma of the head and neck. *Laryngoscope.* 2004; 114:1194–1199. doi: 10.1097/00005537-200407000-00012.
30. Cristalli G, Manciocco V, Pichi B, Marucci L, Arcangeli G, Telera S, Spriano G. Treatment and outcome of advanced external auditory canal and middle ear squamous cell carcinoma. *J Craniofac Surg.* 2009; 20:816–821. doi: 10.1097/SCS.0b013e3181a14b99.

UNDER PEER REVIEW