

The interest of the global longitudinal strain in severe valve disease: Moroccan experience

ABSTRACT

Aims: Valvular heart diseases, primarily mitral stenosis, are a significant concern in Morocco. Early detection of left ventricular systolic dysfunction is crucial, especially in high-prevalence valvular disease populations. This study aims to investigate global longitudinal strain as a more sensitive tool for early detection, potentially providing early warning signs before a decrease in ejection fraction. Additionally, it addresses the gap in the literature, focusing on global longitudinal strain application in the Moroccan population, with a particular emphasis on mitral stenosis and aortic stenosis degenerative but also and above all rheumatic.

Study design: A descriptive study

Place and Duration of Study: Cardiology department, CHU Ibn Rochd, Casablanca, Morocco, from 2020 to 2023.

Methodology: We included 81 individuals, adhering to ESC 2021 criteria, focusing on patients with pure severe mitral stenosis or severe aortic stenosis and preserved LVEF ($\geq 50\%$). Excluding patients with LVEF $< 50\%$, all underwent comprehensive echocardiography, including valvular disease severity evaluation, LVEF assessment by Simpson biplane, and global longitudinal strain, with descriptive analysis conducted using Excel.

Results: 51.9% of our patients had severe mitral stenosis, and 48.1% had severe aortic stenosis. Mitral stenosis was mainly rheumatic and aortic stenosis was mainly degenerative. The global longitudinal strain was the lowest for mitral stenosis with -14.95% , and -15.25% for aortic stenosis.

Conclusion: Our Moroccan experience has underscored the significance of global longitudinal strain in assessing valvular heart disease cases with preserved ejection fraction. Our specific focus on mitral stenosis, highly prevalent in our population and exhibiting the most pronounced global longitudinal strain impairment, underscores the value of routine global longitudinal strain measurements in valve disease evaluation, particularly in mitral stenosis. Ongoing patient monitoring will further contribute to prospective, conclusive insights into mitral stenosis management.

Keywords: Global longitudinal strain; valvular disease; mitral stenosis.

1. INTRODUCTION

In this study, we delve into the intriguing terrain of echocardiography, an indispensable tool in the assessment of valve anomalies, focusing particularly on the Moroccan experience.

Indeed, we think that our Moroccan population is interesting because the rheumatic pathology is predominant and this will then allow us to study a larger population than those described in the literature of mitral stenosis of rheumatic origin but also of rheumatic and degenerative aortic stenosis. Note that the majority of studies concerning strain have focused on degenerative lesions.

While the left ventricular ejection fraction has long stood as a cornerstone indicator of left ventricular dysfunction, our scrutiny reveals a nuanced reality. Often, the insidious progression of cardiac damage persists even in the presence of preserved cardiac function, warranting a deeper diagnostic perspective. Against this backdrop, the spotlight turns to an innovative player in cardiac assessment: the global longitudinal strain (GLS). A parameter relatively unexplored in mitral stenosis, our study endeavors to fill this critical gap in research. Within a population endemic for articular rheumatism, where mitral stenosis reigns as the most prevalent valve affliction, our investigation takes on a distinct significance. By probing the efficacy of global longitudinal strain in mitral stenosis and aortic stenosis, we aim to unearth a potential early detector of cardiac dysfunction that could reshape diagnostic paradigms and impact therapeutic interventions.

2. METHODOLOGY

In this descriptive study between 2020 and 2023, 81 patients were collected from the valve registry including patients seen in valve clinic consultation, as well as hospitalized patients.

The inclusion criteria were as follows: pure severe mitral stenosis or pure severe aortic stenosis in asymptomatic patients with preserved left ventricular ejection fraction (LVEF $\geq 50\%$).

Patients with LVEF $< 50\%$, or aged less than 18 years, with a congenital pathology or a multiple valvular disease were excluded. Also excluded were tight mitral stenosis with a high thromboembolic risk factor or a high risk of hemodynamic decompensation (a history of embolic, recent spontaneous dense contrast or paroxysmal AF, systolic PAP > 50 mmHg at rest, before non-cardiac surgery at high risk, in case of desire to become pregnant).

The predominant etiologies were rheumatic and degenerative.

Every single one of our patients underwent a complete echocardiography, which confirmed the severity of the valvular disease; the valve severity criteria were those of the European Society of Cardiology with a mitral surface $< 1.5\text{cm}^2$ and aortic surface $< 1\text{cm}^2$ or $< 0.6\text{cm}^2/\text{m}^2$.

Our echocardiography also included LVEF by the Simpson biplane, and left ventricular GLS. Descriptive analysis was done using Excel software.

3. RESULTS AND DISCUSSION

Our population had a 70% female preponderance. The average age was 46.6 years. 51.9% of our patients had severe mitral stenosis, and 48.1% had severe aortic stenosis. (Figure 1)

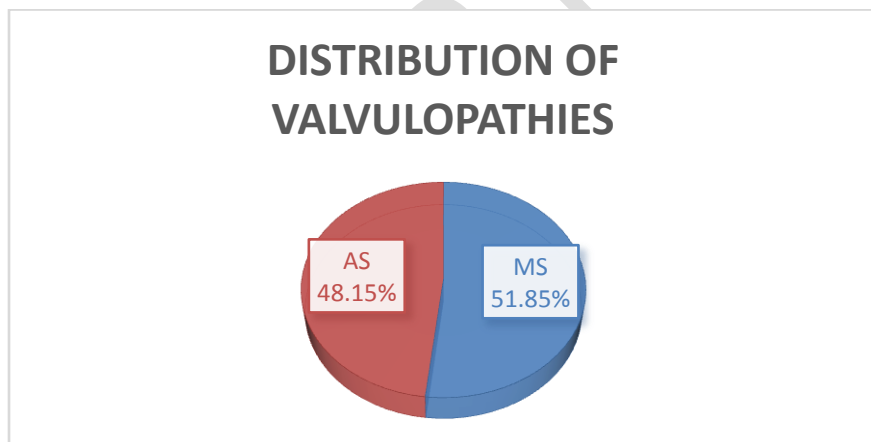


Figure 1: Distribution of heart valve diseases in our population (MS: mitral stenosis; AS: Aortic stenosis)

All our patients were asymptomatic.

The majority of our patients had an appearance of rheumatic mitral stenosis, only 2 of them were elderly and had the appearance of a degenerative MS.

The average mitral surface was 1.2cm^2 , and 1.8cm^2 for aortic surface.

Degenerative etiology was the most common for aortic stenosis.

The average of LVEF was 55% for MS and 52% for AS. The global longitudinal strain was the lowest for MS with -14.95%, and -15.25% for AS.

(Figure 2) (Image 1)

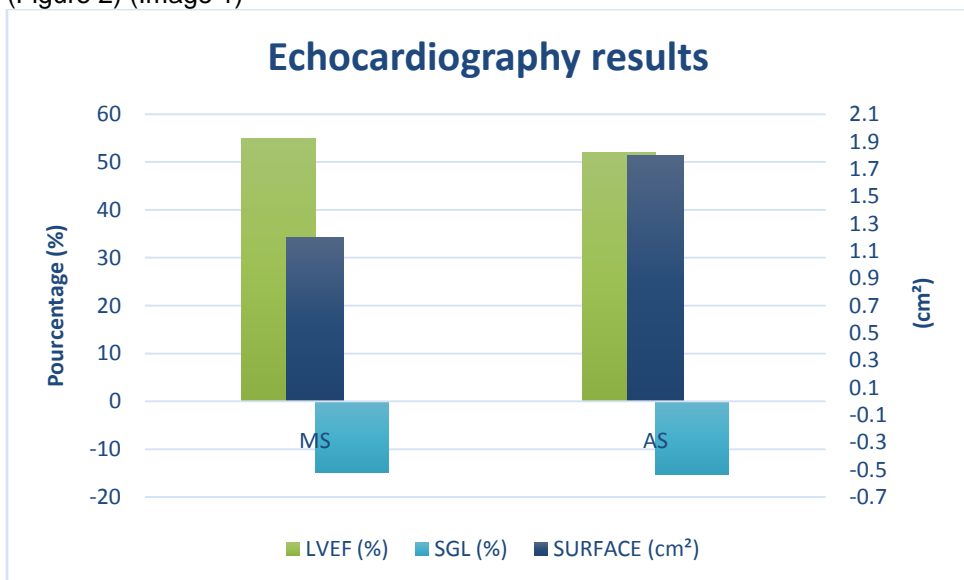


Figure 2: Echocardiography results (MS: mitral stenosis; AS: Aortic stenosis)

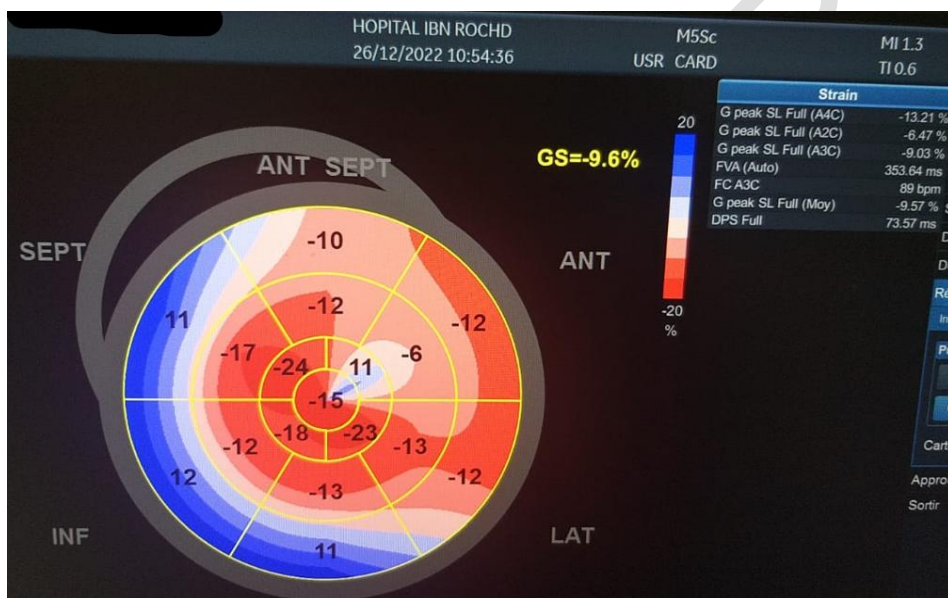


Image 1: Left ventricular global longitudinal strain damage in a patient with a severe mitral stenosis

In our study, mitral stenosis (MS) was the primary valve disease of interest, and we aimed to contribute uniquely to the existing body of research in this field. Notably, there is a scarcity of studies that have assessed mitral stenosis using GLS as a parameter. What sets our study apart is the distinctiveness of examining GLS in a population such as ours. In a context where rheumatic fever stands as the predominant cause of valvular disease, MS emerges as the most prevalent valvular condition.

The most impaired GLS was that of mitral stenosis (-14.95%). Compared to the Turkish study by Ozdemir¹, one of the rare studies focusing on GLS in MS, there was also a majority of women (80%). Individuals with isolated MS had significantly lowered mean GLS (-17.3% vs. -19.5%, $P = 0.006$) despite having adequate left ventricular (LV) systolic function as measured by ejection fraction (66.8%); however, our mean GLS was lower. The population can explain this difference; indeed, they included patients with mild to moderate MS, while we included moderate to severe MS. In 2014, Sengupta et al.² showed that the GLS values of 85% of patients with severe MS corresponded to the lowest quartile for the control group. The best predictor of GLS in these individuals was LV end-diastolic volume, indicating that modified

loading conditions play a major role in determining the deterioration of LV contractile performance in MS patients. Thus, LV deformation is actually correlated with the hemodynamic severity of MS and is decreased in individuals with severe MS.

Other studies focusing on strain in mitral stenosis focused more on right ventricular strain.³

Concerning aortic stenosis and global longitudinal strain, it is the most described valvular disease in studies. Because of our African context, it appears as the second valvulopathy in terms of prevalence in our population. The GLS for aortic stenosis in our study was -15.25%, which is close to literature, with a GLS of -13.3±3.7% in severe aortic stenosis.⁴ A GLS worse than -18.2% has been showed to be linked with disease progression, as measured by the emergence of symptoms and the requirement for valve intervention, in patients with asymptomatic severe aortic stenosis and normal ejection fraction.⁵

Indeed, the latest studies have focused more on the prognostic benefit of GLS, by prospectively following patients and focusing on mortality depending on the strain.

In aortic stenosis, it has been demonstrated that GLS, regardless of stenosis severity, LVEF, or other established predictors, is a very reliable indicator of all-cause mortality. Furthermore, in all treatment options for surgical or transcatheter aortic valve replacement, preoperative GLS, whether high-gradient or low-flow, low-gradient, was linked to long-term postoperative cardiac mortality and morbidity in patients with symptomatic severe aortic stenosis.⁶

However, there are no prospective studies focusing on prognosis and mortality according to GLS in mitral stenosis. We will therefore follow our patients with mitral stenosis to obtain results concerning the relevance of GLS in the long term and, in particular, post-operatively.

4. CONCLUSION

Our Moroccan experience has shed light on the interest of GLS in the evaluation of valvular heart disease with preserved LVEF. Our context also placed emphasis on mitral stenosis, which is very important in our population and in which we found the most impaired GLS. This shows the benefit of measuring GLS systematically in the evaluation of valve disease, particularly mitral stenosis with preserved LVEF. We will continue to monitor our patients, in order to provide more conclusive prospective results regarding mitral stenosis.

REFERENCES

¹ Ozdemir, A. O., Kaya, C. T., Ozcan, O. U., Ozdol, C., Candemir, B., Turhan, S. et al. Prediction of subclinical left ventricular dysfunction with longitudinal two-dimensional strain and strain rate imaging in patients with mitral stenosis. *The international journal of cardiovascular imaging*, 2010; 26(4), 397–404. <https://doi.org/10.1007/s10554-009-9550-2>

² Shantanu P. Sengupta, Makoto Amaki, Manish Bansal, Mahesh Fulwani, Sunil Washimkar et al. Effects of Percutaneous Balloon Mitral Valvuloplasty on Left Ventricular Deformation in Patients with Isolated Severe Mitral Stenosis: A Speckle-Tracking Strain Echocardiographic Study, *Journal of the American Society of Echocardiography*. 2014; 27 (6), 639-647. <https://doi.org/10.1016/j.echo.2014.01.024>.

³ Taamallah K, Jabloun TY, Guebsi M, Hajlaoui N, Lahidheb D, Fehri W. Subclinical right ventricular dysfunction in patients with mitral stenosis. *J Echocardiogr*. 2022 June ;20(2) :87-96. doi: 10.1007/s12574-021-00554-5.

⁴ Cvijic, M., & Voigt, J. U. Application of strain echocardiography in valvular heart diseases. *Anatolian journal of cardiology*, 2020; 23(5), 244–253. <https://doi.org/10.14744/AnatolJCardiol.2020.09694>

⁵ Vollema, E. M., Sugimoto, T., Shen, M., Tastet, L., Ng, A. C. T., Abou, R., et al. Association of Left Ventricular Global Longitudinal Strain with Asymptomatic Severe Aortic Stenosis: Natural Course and Prognostic Value. *JAMA cardiology*. 2018 ; 3(9), 839–847. <https://doi.org/10.1001/jamacardio.2018.2288>

⁶ D'Andrea, A., Carbone, A., Agricola, E., Riegler, L., Sperlongano, S., Tocci, G., et al. Predictive Value of Left Ventricular Myocardial Deformation for Left Ventricular Remodeling in Patients with Classical Low-Flow, Low-Gradient Aortic Stenosis Undergoing Transcatheter Aortic Valve Replacement. *Journal of the American Society of Echocardiography: official*

UNDER PEER REVIEW