

Occlusion of the small intestine associated with acute radiation enteritis: case report

Abbreviations: RT : radiation therapy; RE : radiation enteritis

ABSTRACT

Background:

Radiotherapy for abdominal and pelvic cancers can lead to delayed small intestine damage (radiation enteritis), even years after treatment. This case report highlights the diagnostic challenges and management complexities associated with such late-onset complications.

Case Description:

A 57-year-old woman presented 5 months after pelvic radiotherapy with acute intestinal obstruction symptoms (abdominal pain, nausea, vomiting, distension). Imaging revealed a small bowel stricture at the prior hysterectomy site. Despite conservative management, surgical exploration confirmed radiation enteritis and a partial bowel obstruction requiring resection. The patient recovered well and was discharged after 5 days.

Discussion:

This case exemplifies the challenges of diagnosing radiation enteritis, often relying on clinical context and imaging. Management is further complicated by potential cancer progression, malnutrition, and progressive damage. While treatment focuses on symptom control, nutrition, and surgery for specific complications, preventive measures are crucial to improve patient outcomes.

Conclusions:

As radiotherapy use increases, the prevalence of radiation enteritis is likely to rise. This case emphasizes the need for continued research on optimal prevention strategies and comprehensive management approaches to enhance patients' quality of life.

Keywords: Radiation enteritis; diagnosis; Radiotherapy; conservative treatment; Small bowel; CT imaging; preventive measures.

Introduction :

Radiotherapy (RT) is an essential component of the therapeutic arsenal for abdomino-pelvic cancers (gastrointestinal, urological, and gynecological) [1]. It is used alone or in combination with chemotherapy and/or surgery.

Radiation enteritis (RE) is a complication of abdomino-pelvic RT, defined by the presence of acquired morphological lesions in the intestinal mucosa and wall.

Although much is known about the late intestinal side effects of radiation, relatively little has been published on its acute complications. We present a case of small intestine obstruction associated with acute radiation enteritis.

Observation:

A 57-year-old patient underwent surgery for endometrial carcinoma in July 2021. As adjuvant treatment, they received external radiotherapy (RT) starting October 5, 2021, at a dose of 2 Gy per session.

Five sessions after initiating external radiotherapy, the 57-year-old patient presented to the emergency department with a 7-day history of occlusive syndrome.

Symptoms included: Cessation of bowel movements and gas passage; Fecal vomiting; Abdominal distension; Diffuse abdominal tenderness and empty rectal ampulla on physical examination

A non-injection abdominal CT scan revealed a discrepancy in the caliber of the grelic vein at the level of the hysterectomy loge. An upstream dilatation measured 61 mm, with hydro-aeric levels (NHA) and a flattened colon. There was no evidence of progressive tumor process or signs of severity, such as peritoneal effusion or pneumoperitoneum [Figure 1].

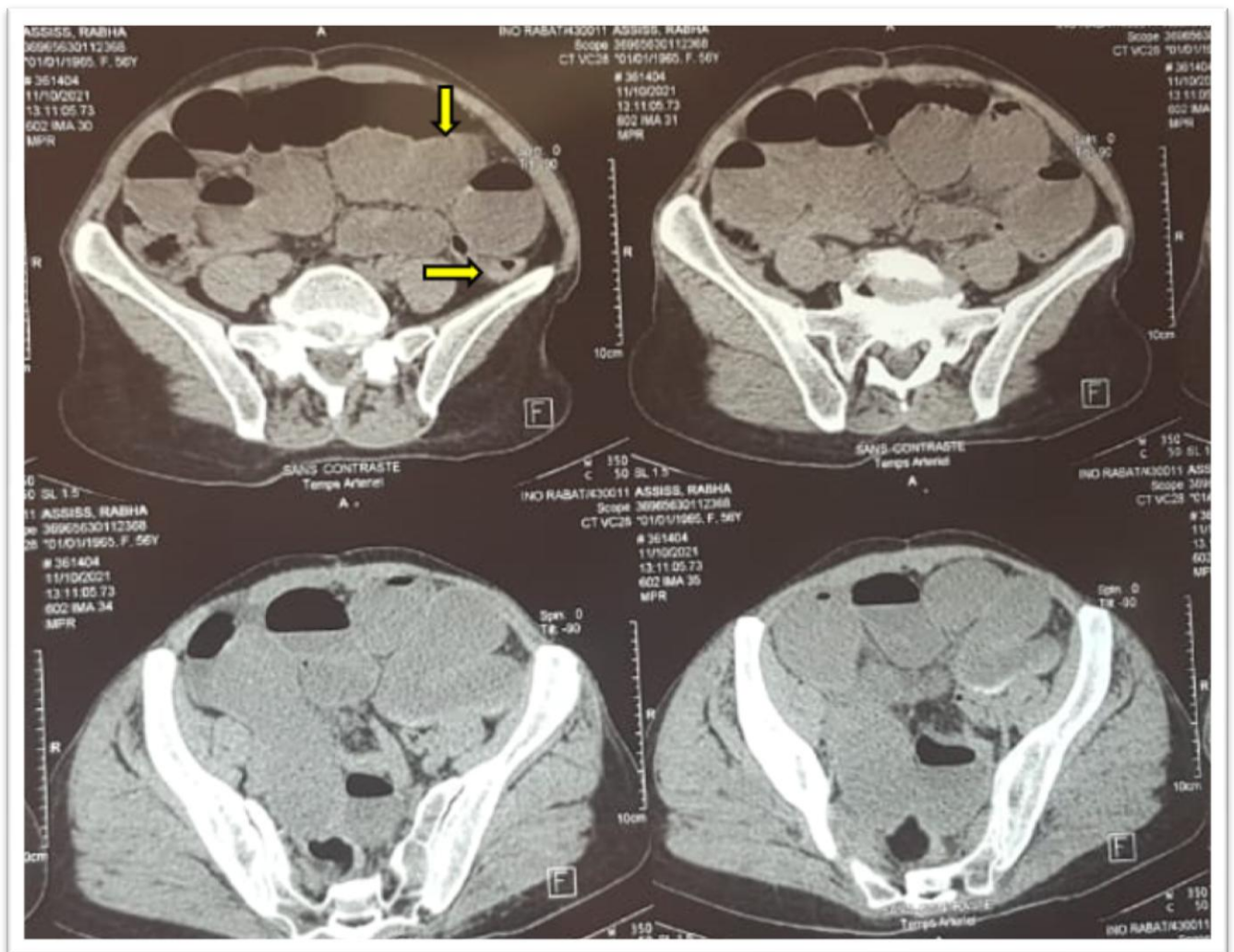


Figure 1: Abdomino-pelvic CT scan (cross-section): bowel occlusion (Arch: boweINHA; flat colon)

Laboratory tests revealed: Hyponatremia: 120 mEq/L, Normal potassium: 4.2 mEq/L, Hypochloremia: 76 mEq/L, Elevated CRP: 12.97 mg/L and Leukopenia: $3.67 \times 10^3/uL$

After appropriate resuscitation to correct electrolyte imbalances, the patient was stabilized and admitted for surgery.

Persisting signs led to surgery within 24 hours of admission. Exploration revealed radiating segments of the terminal small intestine, just upstream of the gallbladder, causing obstruction. The culprit was identified as gallbladders found at the hysterectomy site (Figure 2).

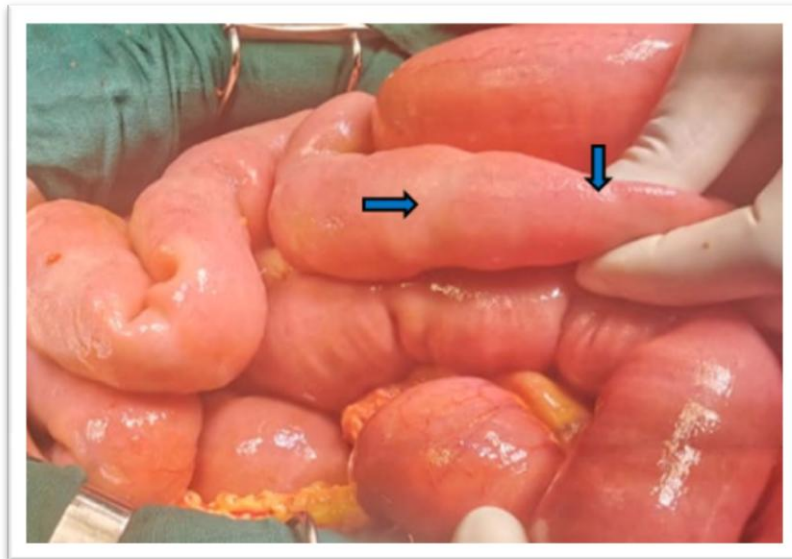


Figure 2: Intraoperative image showing dilated and inflamed small bowel.

During surgery, adhesions were lysed and the area was debrided. There were no signs of damage to the small intestine wall during its detachment.

The involved segment of the small intestine remained viable, and its lumen was confirmed to be open during antegrade emptying.

Recovery:

The patient's postoperative recovery was positive.

Transit resumed on the first day, and they progressed well on a gradually reintroduced diet.

Following a simple follow-up, they were discharged on the fifth day with a favorable checkup after three weeks.

Radiotherapy:

The patient resumed radiotherapy on November 8, 2021, receiving 20 sessions at 2 Gy per session (total dose of 46 Gy) until December 3, 2021.

They then underwent four brachytherapy sessions starting on December 21, with 7 Gy per session. Their progress remained favorable throughout this treatment.

Discussion

Pelvic cancer radiotherapy (RT) often leads to clinical digestive radio lesions in exposed segments, with the small bowel being most frequently and severely affected [1]. While long-term digestive complications are well-documented, few studies explore acute impacts [2].

Pathophysiology of RE :

Due to its position, the small intestine is highly susceptible to radiation damage during abdominal/pelvic radiotherapy. This risk increases when bowel loops fill the void left by organ removal (e.g., total hysterectomy or proctectomy) [19].

**Acute radiotoxicity affects mucosal crypt cells and microvascular endothelium, causing:

1. Replacement of healthy villous epithelium with non-functional cells, leading to:**
 - Loss of barrier function
 - Abdominal pain
 - Accelerated intestinal transit
 - Nutritional deficiencies due to impaired permeability and absorption
2. Impacts across various nutrient categories (hematopoietic vitamins, water, electrolytes) [20]**

Risk factors for radiation enteritis

Several factors, both treatment-related and patient-specific, influence the risk and severity of radiation enteritis.

- **Treatment factors:** Modern techniques can minimize damage, but high doses ($\geq 30\text{Gy}$) still cause mucosal damage in most patients, leading to diarrhea within weeks [4].
- **Patient factors:** Individual susceptibility to radiation varies due to genetic factors [18]. Additionally, conditions like smoking, hypertension, diabetes, micro-angiopathies, and chronic inflammatory bowel disease (IBD) can exacerbate intestinal toxicity [17, 21][24].

Therefore, effective RT planning requires careful consideration of both irradiation characteristics and patient-specific risks.

Diagnosis of Acute Radiation Enteritis

Acute intestinal toxicity, typically manifesting as radiation enteritis, arises within three months of radiotherapy, peaking between weeks 4-5 [22]. However, diagnosis proves challenging, even with imaging tools.

While CT scans, especially in the context of recent exposure, offer valuable insights into location, extent, and severity of damage, including potential complications like perforation, fistula, and abscess formation [5, 6], they have limitations:

- Differentiating from other causes: CT scans cannot definitively distinguish radiation enteritis from other conditions with similar symptoms, such as inflammatory bowel disease.
- Early detection limitations: Subtle mucosal changes, a hallmark of early-stage radiation enteritis, may not be readily apparent on CT scans.
- Radiation exposure: Repeated CT scans carry their own radiation risks.

Therefore, diagnosis often relies on a combination of:

- Clinical presentation: Symptoms like diarrhea, abdominal pain, and blood in stool.
- Medical history: Recent radiotherapy and potential confounding factors like inflammatory bowel disease.
- Imaging findings: CT scan for potential complications, but with the understanding of its limitations.
- Exclusion of other causes: Ruling out alternative sources of symptoms.

TREATMENT

Managing radiation lesions presents a complex challenge due to:

- Progressive nature: Damage evolves over time, leading to increasing pain, diarrhea, and malnutrition, making symptom control difficult.
- Cancer progression risk: Radiation itself can increase the risk of new cancers arising within the damaged tissue, complicating treatment decisions.
- Malnutrition: Damage to the digestive tract hinders nutrient absorption, leading to weight loss, weakened immune response, and slower healing, further complicating management.

Prevention strategies focus on minimizing radiation exposure to the small intestine:

- Dose/volume ratio adjustments: Advanced radiotherapy techniques like intensity-modulated radiation therapy (IMRT) or volumetric modulated arc therapy (VMAT) allow fine-tuning radiation delivery, reducing the dose to healthy tissues while maintaining coverage of the tumor area.[25]
- Omentopexy techniques: These surgical procedures aim to anchor the greater omentum in the pelvic cavity, preventing intestinal loops from falling into the irradiated area. Different approaches exist:
 - ◆ Anterior omentopexy: Fixes the omentum to the anterior pelvic wall and bladder.
 - ◆ Posterior omentopexy: Fixes the omentum to the posterior pelvic wall and sacrum.
 - ◆ Total omentopexy: Combines both anterior and posterior fixation.

However, these strategies have limitations:

- Dose reductions have trade-offs with tumor control, requiring careful balancing.[25]
- Omentopexy success depends on individual anatomy and may not completely prevent intestinal prolapse.

Therefore, comprehensive management involves a multidisciplinary approach:

- Gastrointestinal specialists: Manage symptoms like pain and diarrhea and optimize nutrition through dietary adjustments or supplements.
- Surgeons: May intervene for complications like perforation or obstruction.
- Oncologists: Monitor for cancer progression and adjust treatment plans as needed.

By understanding the challenges and employing preventive and management strategies, healthcare teams can strive to improve the quality of life and clinical outcomes for patients with radiation lesions.

The role of medical treatment

Medical management of radiation enteritis focuses on symptom control and nutritional support, tailoring interventions based on individual needs and severity.

Nutritional Support:

- Dietary modifications: Simple adjustments like avoiding irritants (spicy foods, alcohol), increasing soluble fiber, and small frequent meals can improve tolerance. In severe cases, dietician-guided plans or oral nutritional supplements may be necessary. [15][24]
- Parenteral nutrition: For patients with significant malabsorption or malnutrition, 4-8 week courses of parenteral nutrition directly deliver essential nutrients through a central line, improving healing and recovery. [15][24]

Symptom Management:

- Probiotics: Specific strains like *Lactobacillus rhamnosus* GG and *Saccharomyces boulardii* have shown promise in reducing diarrhea severity and duration, but evidence remains limited and benefits may vary based on individual gut microbiota. [3, 4][24]
- Residue-free diet: This temporary approach excludes high-fiber and roughage-rich foods that can worsen diarrhea, but its long-term effectiveness and impact on gut health require further investigation. [4][24]
- Transit retardants: Medications like loperamide slow intestinal motility, reducing stool frequency but potentially causing constipation. Their use should be cautious and balanced with gut motility needs. [8]
- Bile acid chelators: Medications like colestyramine bind bile acids, reducing diarrhea associated with excess bile salt secretion. However, potential side effects like vitamin deficiencies necessitate careful monitoring. [8][24]
- Sulfasalazine: This anti-inflammatory medication exhibits some benefit in reducing symptoms, potentially by modulating gut inflammation. However, its mechanism of action remains unclear, and further research is needed to elucidate its role and optimal use. [3, 8][24]

It's important to recognize limitations:

Each intervention has potential drawbacks, requiring careful evaluation and individualization of treatment plans.

Dietary modifications and probiotics may not offer complete symptom relief for all patients.

Long-term efficacy and safety data for some options, like residue-free diets and sulfasalazine, are still evolving.

Surgical Management of Obstruction in Radiation Enteritis

Obstruction remains a critical complication in radiation enteritis, often necessitating surgical intervention. While conservative management with nasogastric decompression, fluid resuscitation, and parenteral nutrition is the cornerstone of initial treatment, surgery becomes necessary under specific circumstances.

Timeframe for Surgical Intervention:

The decision to proceed with surgery typically occurs after a defined period of failed medical management. This timeframe varies depending on the severity of obstruction and presence of complications.

Studies suggest considering surgery after 72 hours of unsuccessful conservative management for complete obstructions and within 24 hours for suspected necrosis or perforation [18, 24]. Ultimately, the decision remains clinical, relying on individual patient factors and ongoing response to conservative measures.

Specific Complications Requiring Surgery:

- Persistent Obstruction: Failure to resolve obstruction after adequate medical management, indicating mechanical impaction or potential ischemic stricture [12, 13].
- Immediate Complications: Presence of perforation, necrosis, gangrene, or life-threatening hemorrhage necessitates immediate surgical intervention to prevent peritonitis, sepsis, and other life-threatening outcomes [4, 12, 13].

- Intraluminal Causes: Foreign bodies, internal hernias, or strictures caused by factors other than radiation enteritis may require specific surgical approaches beyond simple resection or bypass [9, 10, 11].

Emerging Minimally Invasive Techniques:

The field of minimally invasive surgery (MIS) offers promising advancements for managing obstructive radiation enteritis. Techniques like laparoscopic adhesiolysis, bowel resection, and bypass are increasingly employed due to their benefits of reduced incision size, faster recovery, and potentially lower complication rates compared to open surgery [19, 20, 22]. However, careful patient selection and surgeon expertise are crucial for successful MIS application in this complex setting.

Conclusion:

Pelvic abdominal radiotherapy (RT) carries a growing risk of causing radiation enteritis, a damaging condition affecting the small intestine wall. Prevention strategies focus on minimizing radiation exposure through dose reduction and targeted fields.

Managing radiation enteritis presents a complex challenge due to its:

- Multifocal and progressive nature: Damage evolves over time, impacting multiple areas and worsening with time.
- Carcinogenic risk: Radiation itself can increase the risk of new cancers arising within the damaged tissue.
- Associated malnutrition: Damage to the digestive tract hinders nutrient absorption, leading to weight loss and weakened immune response.

While the acute form is self-limiting, the chronic form significantly impacts quality of life and can lead to serious complications like obstruction.

For obstructions, conservative management is preferred initially. However, timely surgical intervention becomes crucial for persistent obstructions or specific complications like perforation or necrosis. Emerging minimally invasive techniques offer potential benefits, but require further research and surgeon expertise for broader adoption in this complex patient population.

Ethical Approval:

As per international standards or university standards written ethical approval has been collected and preserved by the author(s).

Consent

As per international standards or university standards, patient(s) written consent has been collected and preserved by the author(s).

REFERENCES

- [1] Mahé MA, Barillot I, Chauvet B. [Guidelines for external radio-therapy and brachytherapy: 2nd edition]. *Cancer Radiother* 2016; 20 Suppl: S4-7.
- [2] Martínez Hernández Magro P. Bowel obstruction secondary to radiation enteritis: a case report. *Revisita de Gastroenterología de México*. 2015; 80(1): 111-3
- [3] Bismar mm, Sinicrope FA. Radiation enteritis. *Curr Gastroenterol Rep* 2002; 4: 361-365.
- [4] Zimmerer T, Böcker U, Wenz F, Singer mV. Medical prevention and treatment of acute and chronic radiation induced enteritis - is there any prevention? A short review. *Z Gastroenterol* 2008; 46: 441-448
- [5] Toomey DP, Cahill RA, Geraghty J, Thirion P. Radiation enteropathy. *Ir Med J* 2006; 99: 215-217.
- [6] Ilangovan R, Burling D, George A, Gupta A, Marshall M, Taylor SA. CT enterography: review of technique and practical tips. *The British Journal of Radiology*. 2012; 85(1015): 876-886. PubMed | Google Scholar
- [8] Kilic D, Ozenirler S, Egehan i, Dursun A. Sulfasalazine decreases acute gastrointestinal complications due to pelvic radiotherapy. *Ann Pharmacother* 2001; 35: 806-810.
- [9] Onodera H, Nagayama S, Mori A et al. Reappraisal of surgical treatment for radiation enteritis. *World J Surg* 2005; 29: 459-463

- [10]. H. HACHI, A. BOUGTAB, F. TIJAMI et al. THE SURGICAL TREATMENT OF RADICAL LESIONS OF THE GRETEL. *Médecine du Maghreb* 2000 n°80
- [11] Regimbeau JM, Panis Y, Gouzi JL, Fagniez PL. French University Association for Surgical Research. Operative and long term results after surgery for chronic radiation enteritis. *Am J Surg* 2001;182:237-42.
- [12] L. Loge, C. Florescu, A. Alves, B. Menahem Radiation enteritis: Diagnostic and therapeutic issues
- [13] Amiot A, Joly F, Lefevre JH, et al. Long-term outcome after extensive intestinal resection for chronic radiation enteritis. *Dig Liver Dis* 2013;45:110-4.
- [14] Lawrie TA, Green JT, Beresford M, et al. Interventions to reduce acute and late adverse gastrointestinal effects of pelvic radiotherapy for primary pelvic cancers. *Cochrane Database Syst Rev* 2018;1:CD012529
- [15] Silvain C, Besson I, Ingrand P, et al. Long-term outcome of severe radiation enteritis treated by total parenteral nutrition. *Dig Dis Sci* 1992;37:1065-71
- [16] Andreyev HJ, Davidson SE, Gillespie C, Allum WH, Swarbrick E. British Society of Gastroenterology; Association of ColoProctology of Great Britain and Ireland; Association of Upper Gastrointestinal Surgeons; Faculty of Clinical Oncology Section of the Royal College of Radiologists. Practice guidance on the management of acute and chronic gastrointestinal problems arising as a result of treatment for cancer. *Gut* 2012;61:179-92.
- [17] L. Loge a, C. Florescu b, A. Alves a,c,d, B. Menahem. Radiation enteritis: Diagnostic and therapeutic issues. *j. visc surg.* 2020.08.012
- [18] MARTEL PH, DESLANDES M, DUGUE L, SEZEUR A, GALLOT D, MALAFOSSE M. Radical lesions of the small intestine: surgical treatment. *Annales de chirurgie* 1996, 50, n°4 : 312-3 17
- [19] Nuyttens JJ, Robertson JM, Yann D, Martinez A. The position and volume of the small bowel during adjuvant radiation therapy for rectal cancer. *Int J Radiat Oncol Biol Phys* 2001;51:1271-80.
- [20] Hauer-Jensen M, Denham JW, Andreyev HJ. Radiation enteropathy-pathogenesis, treatment and prevention. *Nat Rev Gastroenterol Hepatol* 2014;11:470-9.
- [21] Andreyev HJ, Wotherspoon A, Denham JW, Hauer-Jensen M. "Pelvic radiation disease": new understanding and new solutions for a new disease in the era of cancer survivorship. *Scand J Gastroenterol* 2011;46:389-97.
- [22] Kennedy GD, Heise CP. Radiation colitis and proctitis. *Clin Colon Rectal Surg* 2007;20:64-72.
- [23] Girvent M, Carlson GL, Anderson I, Shaffer J, Irving M, Scott NA. Intestinal failure after surgery for complicated radiation enteritis. *Ann R Coll Surg Engl* 2000;82:198-201.
- [24] Huiwen Ren, Qi Wu, Zhiqiang Sun, Mingming Fang, Jun Liu, and Judong Luo; Research progress and treatment of radiation enteritis and gut microbiota. *Radiat Oncol J.* 2023 Jun; 41(2): 61–68.
- [25] Emily S. Weg, MD,^a Xin Pei, PhD,^b Marisa A. Kollmeier, MD,^a Sean M. McBride, MD, MPH,^a and Michael J. Zelefsky, MD,^{a,*} Dose-Escalated Intensity Modulated Radiation Therapy for Prostate Cancer: 15-Year Outcomes Data. *Adv Radiat Oncol.* 2019 Jul-Sep; 4(3): 492–499.