

Sonographic measurement of the liver in a private care setting in Chattogram.

ABSTRACT:

Introduction: The liver is one of the principal organs of our body involved in over 500 physiological functions related to metabolism, digestion, immunity, and storage of nutrients, which makes it an essential organ to preserve life. The aim of my study is to measure the different size of the liver sonographically in a randomly selected patients sample and identify factors that affect liver size.

Methods: In this cross sectional study 100 subjects were evaluated for liver length in a private care setting during a one-year study period from 01.01.2021 to 31.12.2021 after informed written consent. Diagnosis of liver diseases, gender differences, liver and non-liver involvements and risk factors were obtained from the subjects. Sonographic measurements of the liver in centimeters were taken from the participants.

Results: The average liver size in the midclavicular line was 15.0 ± 1.5 cm; the average for females was 14.9 ± 1.6 cm and 15.1 ± 1.5 cm for males. 29% of all patients were male with various liver pathologies while 47% of patients were both male and female but shared the same liver pathology, the remaining 24% of patients were female with different pathologies of the liver. Minimum age of the study population was 6 years and the maximum age were 82 years.

Regarding occupations of study population, 16% were doing service, 29% were housewives, 18% were students. Most of the study subjects were from Chattogram (98%) and 32% of the patients had a history of smoking. Liver size exceeded 16 cm in 53% of patients had liver or non-liver involvement and 47% are liver involvement. The fatty changes in the liver Grade I were the most common finding (36%).

Conclusions: Sonographic measurement of liver length can lead to early diagnosis of various liver diseases.

Keywords: liver length, liver anatomy, sonography.

1. INTRODUCTION :

Abdominal ultrasonography is widely used in evaluating liver size as it is noninvasive, safe (no ionizing radiation), available and lower cost than other radiological modalities¹. Several studies have developed techniques to measure the liver using 2D ultrasonography². Measurement of the right liver lobe (RLL) length by two-dimensional (2D) ultrasound is taken as an anatomical criterion to assess hepatomegaly, usually defined as $RLL \geq 16.5$ cm. Therefore, it is of pivotal clinical importance that sonographers and physicians feel confident about their assessment of liver health through 2D ultrasound³. The most common measurement of the liver size is obtained in the midclavicular line (MCL). Liver size is affected by many conditions such as malignant tumors, fatty liver changes, and infective diseases⁴. The liver size is related to anthropometric variations of the people from different age, sex and location as affecting factors⁵. This study is to establish objective anatomical criteria to obtain accurate and reliable measurements of RLL length by ultrasound.

A common guideline in clinical ultrasound practice and ultrasound textbooks is that a liver measuring over 14 cm in the mid-clavicular line is enlarged⁶. Some other studies showed measurement of the right liver lobe (RLL) length by two-dimensional (2D) ultrasound is usually defined as $RLL \geq 16.5$ cm⁷. There is also the observation that the line most typically traced for RLL measurement is in the oblique rather than in the craniocaudal plane⁸.

Normal liver and hepatomegaly

The liver is the largest organ in the human body, weighing approximately 1500 g in the adult. The liver is involved in over 500 physiological functions. The major functions metabolism of proteins, carbohydrates, fat, vitamins; synthesis of cholesterol and bile acids; bilirubin transport and metabolism; synthesis of blood coagulation factor; and removal of waste products from the blood. The liver is frequently involved in systemic and local diseases, sonographic examination is often requested to assess hepatic abnormality.

The liver is best examined with real-time sonography. Both supine and right anterior oblique positions should be used. Sagittal and transverse views are suggested using both a standard abdominal transducer.

An accurate assessment of the liver is difficult with real-time ultrasound equipment because of the limited field of view. Gosink and leymaster proposed measuring the liver length in the midhepatic line.⁹

Liver size is a significant indicator of the presence of a disease process. Knowledge of liver size is also important in surgical planning and follow-up of treatments. The liver has multiple physiological functions, and consequently, there are many conditions that can affect the liver causing hepatomegaly. Hepatomegaly is a term used to describe a liver that is enlarged beyond its normal dimensions. In itself, hepatomegaly is not a disease, but rather an indicator of a potential underlying disease process.¹⁰

The liver can be easily measured using ultrasound. Common measurement techniques provide linear measurements rather than volume measurements. Abdominal ultrasound is often the first line of investigation after clinical suspicion of hepatomegaly because it is inexpensive, available, non-invasive and does not use any ionizing radiation.¹¹

The causes of hepatomegaly are dilated hepatic sinusoids, high venous pressure causing congestions, fatty infiltration of the parenchymal cells causing fibrous tissue formation, Viral hepatitis due to infection with hepatitis A, B or C. Toxic hepatitis, common viral infection like mononucleosis and Alcohol-associated hepatitis. Hepatomegaly can potentially be reversible if treated correctly.

Rationale: Sonographically measuring the liver is not always possible due to variations in shape and limitations of imaging techniques to capture the appropriate anatomical boundaries of the organ. So we need to measure and assess the variability of liver length to classify it according to different factors.

Research Question: What are the liver lengths among the subjects in a private care setting?

Objectives:

General- To assess the liver length among normal and abnormal conditions.

Specific- To assess the demographic data.

- To see comorbidities like DM and HTN.

- To calculate the odds ratio of increased liver length for different risk conditions like food habits, DM, HTN, etc.

2. MATERIALS AND METHODS :

Type of study: Cross-sectional study.

Place of study: In a private consultation chamber of Chittagong, Bangladesh.

Duration of study: One year from January 2022 to December 2022

Sample size: 100 subjects.

Sampling technique: Purposive sampling technique.

Inclusion criteria: 1. Subjects visiting the chamber for different health related issues.

2. Wiling to be included in the study.

Exclusion criteria : Acute conditions like organ failure.

Study Procedure: Subjects coming to the consultation center were counseled about the study, and written informed consent from the subjects was taken to be included in the study. Primary information was collected in the case record form. Ultra sonogram of hepato-biliary systems were done by the (GE-VOLUSON E8) machine on all 100 subjects. Liver span was calculated and noted. Other pathology

was noted. Quantitative data like age, length of liver etc. and qualitative variables like sex, comorbidities, non-liver disease etc. were compiled and chi-squared tests were used for qualitative variables and t test was used for t- test. After collection data were compiled and analyzed by SPSS 23.

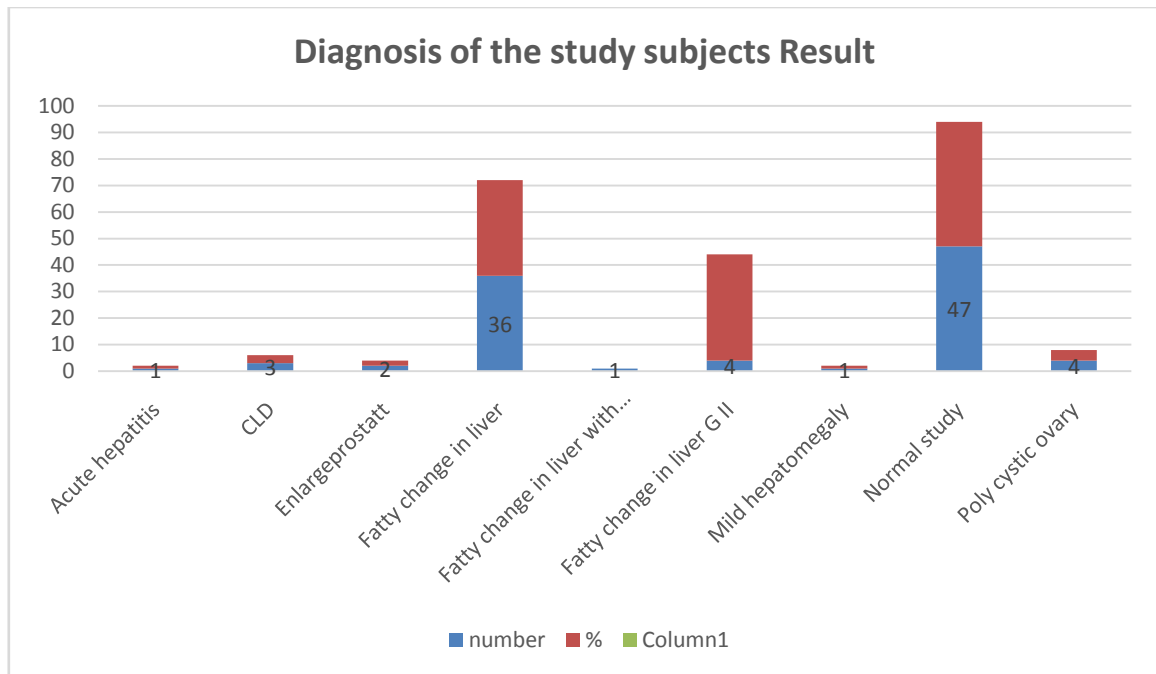
Ethical issue: Informed written consent of the patients was taken from all the subjects and ethical clearance was taken from the IRB of a tertiary care hospital (Southern Medical College Hospital).

3. RESULTS AND DISCUSSION

Table 1: Diagnosis of the study subjects Results:

Diagnosis	N	%
Acute hepatitis	1	1.0
CLD	3	3.0
Enlarged prostate	2	2.0
Fatty change in liver GI	36	36.0
Fatty change in liver GI with mild hepatomegaly	1	1.0
Fatty change in liver GI, hepatomegaly	1	1.0
Fatty change in liver GII	4	4.0
Mild hepatomegaly	1	1.0
Normal study	47	47.0
Poly cystic ovary	4	4.0
Total	100	100.0

Table 1 is showing USG diagnosis where fatty changes of liver (Grade I) were the common findings 36% and next was fatty change of liver Grade II were the second common. 47% cases had normal liver ultrasound. Among all 53% patients had liver or non-liver involvement.

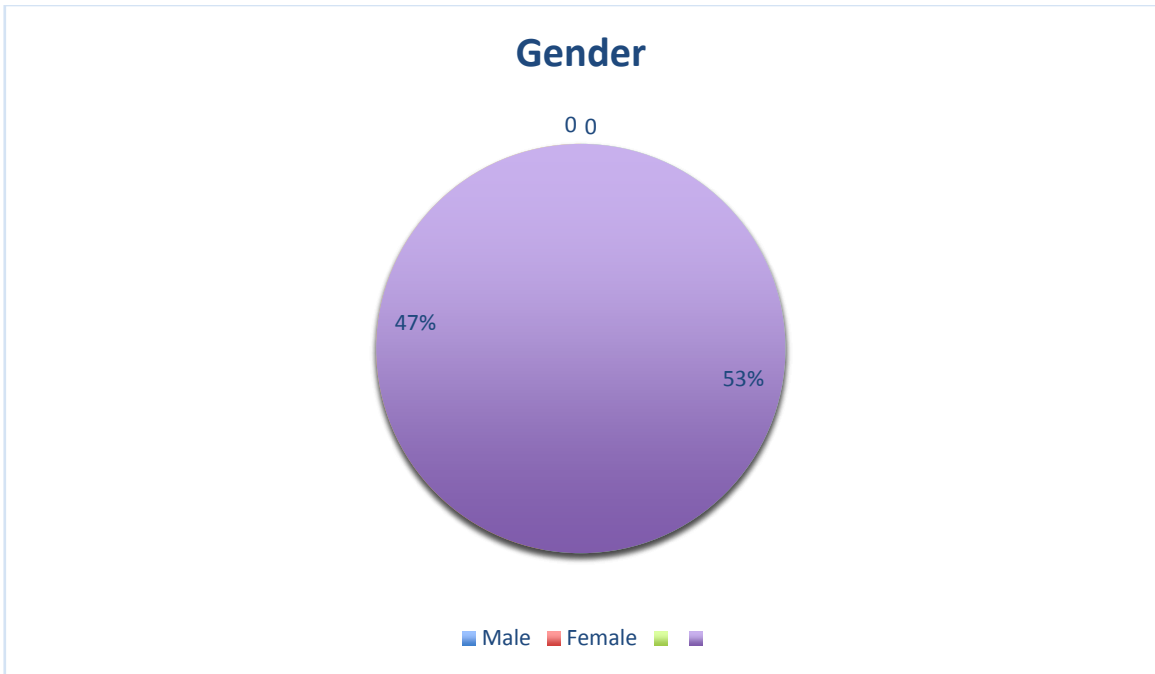


Bar chart 1 showing diagnosis of the study population.

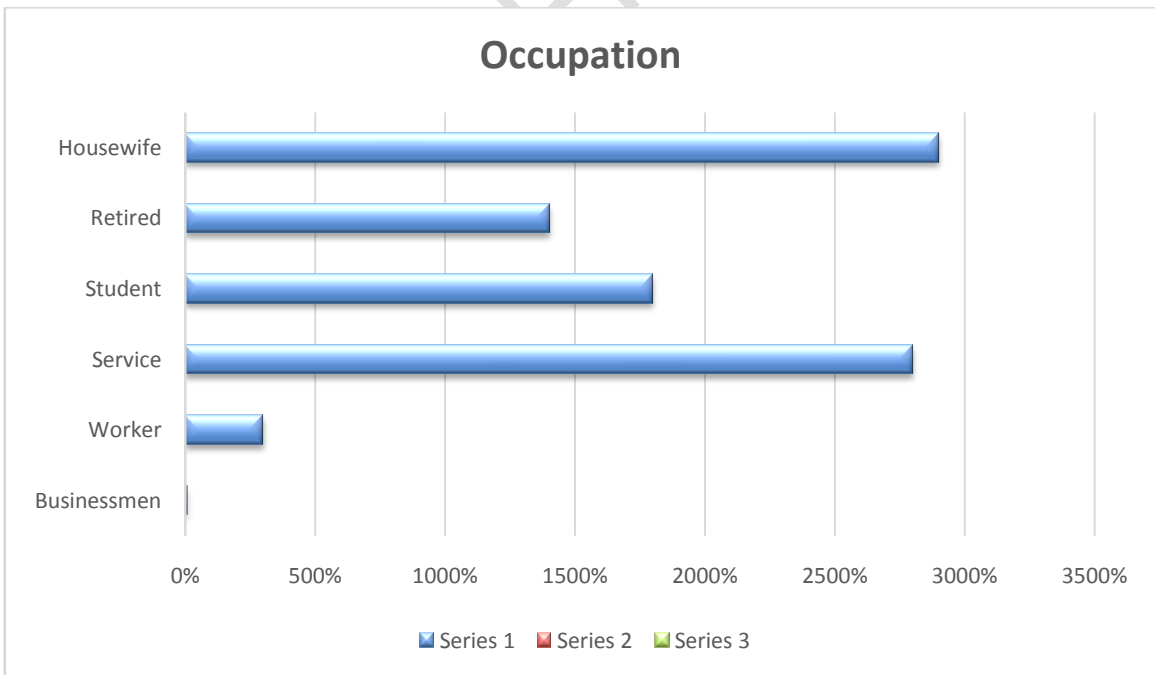Table 2: Gender variations of the subjects

Gender	Normal+non liver involvement	Liver involvement	Total	P value
Male	29(54.7%)	24(45.3%)	53(100%)	0.72
Female	24(51.1%)	23(48.9%)	47(100%)	
Total	53(53%)	47(47%)	100(100%)	

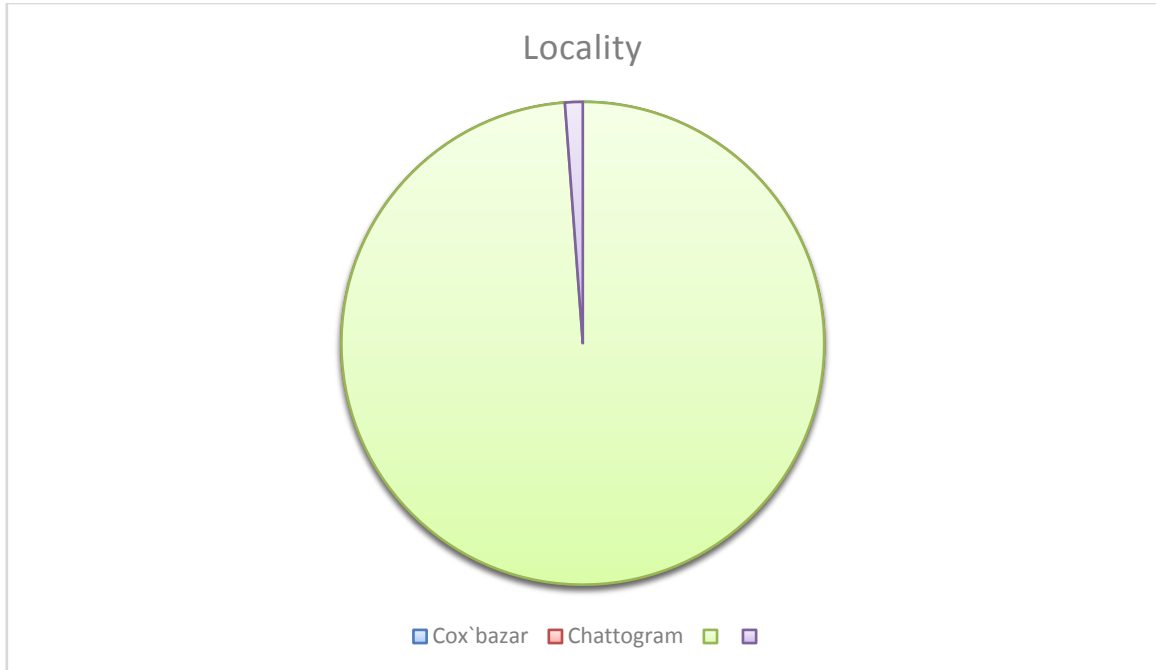
Table 2 is showing 29(54.7%) males and 24(51.1%) females had different types of pathology.



Pie chart 1 showing gender of the study population.



Bar chart 2 showing different occupation of the study population.



Pie chart 2 showing locality of the study population.

Table 3: Smoking history

Smoking information	Normal+non liver involvement	Liver involvement	Total	P value
No	39(57.4%)	29(42.6%)	68(100%)	0.20
Yes	14(43.8%)	18(56.3%)	32(100%)	
Total	53(53%)	47(47%)	100	

Table 3 is showing 32(32%) subjects had history of smoking

Table 4: Pattern of hypertension

Hypertension	Normal+non liver involvement	Liver involvement	Total	P value
No	45(63.4%)	26(36.6%)	71(100%)	0.001
Yes	8(27.6%)	21(72.4%)	29(100%)	
Total	53(53%)	47(47%)	100(100%)	

Table 4 is showing in non-normal and non-liver involvement group 8(27.6%) were hypertensive and in liver involved group it was 21(72.4%)

Table 5: Pattern of DM

Diabetes Mellitus	Normal+non liver involvement	Liver involvement	Total	P value
No	40(67.8%)	19(32.2%)	59(100%)	<0.001
Yes	13(31.7%)	28(68.3%)	41(100%)	
Total	53(53%)	47(47%)	100(100%)	

Table 5 is showing in the non-liver involvement group 13(31.7%) had DM and in the liver involvement group it was 28(68.3%).

Table 6: Food habits

Food type	Normal+non liver involvement	Liver involvement	Total	P value
Balanced	20(71.4%)	8(28.6%)	28(100%)	0.02
Non-balanced	33(45.8%)	39(54.2%)	72(100%)	
Total	53(53%)	47(47%)	100(100%)	

Table 6 is showing food habits where 33(45.8%) were taking non-balanced diet and it was 39(54.2%) in liver involved group.

Table 7: Symptom analysis.

Symptom	Normal+non liver involvement	Liver involvement	Total	P value
Abdominal pain	33(48.5%)	35(51.5%)	68(100%)	0.71
Respiratory problem	3(60%)	2(40%)	5(100%)	
Gynecological problem	5(71.4%)	2(28.6%)	7(100%)	
Dribbling of urine	7(63.6%)	4(36.4%)	11(100%)	
Others	5(55.6%)	4(44.4%)	9(100%)	
Total	53(53%)	47(47%)	100(100%)	

Table 7 shows different symptom analyses where 68 subjects had abdominal pain.

Table 8: Age and liver length

	Diagnosis	N	Mean	Std. Deviation	p
Age (years)	Normal+non liver involvement	53	36.58	18.536	0.009
	Liver involvement	47	45.81	15.437	
Liver length (cm)	Normal+non liver involvement	53	12.215	1.2037	<0.001
	Liver involvement	47	13.730	1.3415	

Table 8 is showing age and liver length where there were significant age variations in the liver involved group in the normal group(p-0.009) and liver length was significantly higher in the liver involvement group(mean- 13.730 cm vs 12.213 cm) respectively than normal group.

Table 09 : Risk analysis

	OR	p
Liver length	2.511	<0.001
Age	.992	0.69
Occupation	1.116	0.52
Food type	1.125	0.62
Hypertension	1.398	0.65
Diabetes mellitus	2.627	0.13

Table 09 is showing different odds ratio of liver involvement where it was 2.511(p-<0.001) and 2,627 for liver length and DM respectively.

Discussion:

USG diagnosis revealed fatty changes of the liver (Grade I) were the most common finding at 36% and next fatty change of the liver Grade II was the second most common. 47% of cases had normal liver ultrasound. Among all 53% of patients had liver or non-liver involvement. Sonographic measurement of this organ is most commonly performed with the patient in the supine position, where RLL length is assessed longitudinally in the midclavicular line. Traditionally, this measurement is considered as being obtained in the craniocaudal plane.¹¹ Tip of the liver cannot be visualized in real-time sonographic images, panoramic views should be obtained for measurement accuracy. This study shows that the most accurate way to obtain measurement of the RLL was from the uppermost right hemidiaphragm to the inferior tip of the right lobe through a horizontal line parallel to the anterior liver wall through the midaxillary line.¹¹ ultrasound is relatively inexpensive and accessible, compared to other diagnostic techniques, our results suggest that ultrasound may be the imaging technique of choice for screening for the presence of fatty liver in clinical settings and, especially, population studies.¹¹

Among all 29(54.7%) male and 24(51.1%) female had different types of pathology. Regarding different types of occupations in the normal or non-liver involved group 16(57.1%) were doing service and it was 12(33.3%) were involved group. Among all 18 were students. Regarding the locality of the study subjects where most were from Chattogram 98(98%) and 32(32%) subjects had a history of smoking. The above demographic data may not match the current demographic data of the city as samples were collected by purposive sampling technique.

Liver involvement varies with the presence of different diseases. In the normal and non-liver involvement group, 8(27.6%) were hypertensive, and in the involved group was 21(72.4%) and it was statistically significant ($p < 0.001$). In the non-liver involvement group, 13(31.7%) had DM and in the liver involvement group, it was 28(68.3%). Distribution was significant ($p < 0.001$). Food habits showed 33 (45.8%) were taking a non-balanced diet and it was 39 (54.2%) in the liver involved group and it was significant ($p = 0.02$).

Age and liver length showed there was significant age variations in liver involved group the normal group($p < 0.009$) and liver length was significantly higher in liver involvement group(mean- 13.730 cm vs 12.213 cm) than normal group. The odds ratio of liver involvement it was 2.511($p < 0.001$) and 2,627 for liver length and DM respectively.

4. CONCLUSION:

It is important to assess liver length to assist the clinicians to get a clue for their diagnosis. In the study both normal and non-liver causes and liver causes was found

to have the increased liver length. There are some risk factors also found in the study to be related with liver involvement like diet and DM. The accurate depiction of liver length through any imaging modality is crucial to arrive at a diagnosis. Classically, though MRI has yielded the highest sensitivities in terms of disease assessment in previous studies, ultrasonography remains an inexpensive tool that can be utilized in a resource poor setting like Bangladesh. The limitations of the study included primarily included a small sample size. Studies like the one done currently require a larger sample size in order to obtain statistically significant important pieces of information that can be better applied in the local population.

ETHICAL APPROVAL (WHEREEVER APPLICABLE)

Ethical issue: Informed written consent of the patients was taken from all the subjects and ethical clearance was taken from the IRB of a tertiary care hospital (Southern Medical College Hospital).

REFERENCES

:1. Ultrasonographic Measurements of the Liver, Gallbladder Wall Thickness, Inferior Vena Cava, Portal Vein and Pancreas in an Urban Region, Malaysia

Abdul Sattar Arif Khammas^{1,*} and Rozi Mahmud²

2. Methods of Determining the Size of the Adult Liver Using 2D Ultrasound: A Systematic Review of Articles Reporting Liver Measurement Techniques

Jessie T. Childs, BHSc, Grad Dip Medical Sonography, Adrian J. Esterman, PhD, FACE, [...], and Richard C. Turner, MBBS, BMedSc, FRACS.

3. Anatomical criteria to measure the adult right liver lobe by ultrasound

Bárbara L. Riestra-Candelaria,¹ Wilma Rodriguez-Mojica,² and Juan Carlos Jorge¹

4. Ultrasonographic Measurements of the Liver, Gallbladder Wall Thickness, Inferior Vena Cava, Portal Vein and Pancreas in an Urban Region, Malaysia

Abdul Sattar Arif Khammas^{1,*} and Rozi Mahmud²

5. Ultrasonographic Measurements of the Liver, Gallbladder Wall Thickness, Inferior Vena Cava, Portal Vein and Pancreas in an Urban Region, Malaysia

Abdul Sattar Arif Khammas^{1,*} and Rozi Mahmud²

6. Methods of Determining the Size of the Adult Liver Using 2D Ultrasound: A Systematic Review of Articles Reporting Liver Measurement Techniques

Jessie T. Childs, BHSc, Grad Dip Medical Sonography, Adrian J. Esterman, PhD, FACE, [...], and Richard C. Turner, MBBS, BMedSc, FRACS

7. Anatomical criteria to measure the adult right liver lobe by ultrasound

Bárbara L. Riestra-Candelaria,¹Wilma Rodríguez-Mojica,² and Juan Carlos Jorge¹

8. Anatomical criteria to measure the adult right liver lobe by ultrasound

Bárbara L. Riestra-Candelaria,¹Wilma Rodríguez-Mojica,² and Juan Carlos Jorge¹

⁹. Diagnostic Ultrasound. P- 109. Carol M. Rumack, Deborah Levine. 5th. Vol. 1.

10. Ultrasound in the assessment of hepatomegaly: A simple technique to determine an enlarged liver using reliable and valid measurements

Jessie T Childs, Adrian J Esterman, Kerry A Thoires, Richard C Turner

11. Ultrasound Accuracy of Liver Length Measurement with Cadaveric Specimens

Bárbara L. Riestra-Candelaria, BS,¹Wilma Rodríguez-Mojica, MD, FACR,²Luis E. Vázquez-Quiñones, PhD,³ and Juan Carlos Jorge, PhD^{1,*}

UNDER PEER REVIEW