

# **Paragonimiasis: A Global Neglected Tropical Lung Disease**

---

### **ABSTRACT**

#### **ABSTRACT:**

Paragonimiasis is a neglected tropical disease (NTD) caused by the zoonotic trematode *Paragonimus* spp., which is spread by eating uncooked or improperly prepared crabs. The parasite is endemic to Southeast Asia and Pacific regions. This disease is characterized by a broad spectrum of clinical manifestations due to its intricate migration path. Clinical signs and radiological findings often overlap and are similar to those of pulmonary tuberculosis (TB) and lung cancer, so they are potentially misdiagnosed. The pathogenesis, diagnosis, and management of this parasite infection are discussed. This review highlights paragonimiasis as the potential to be used as a differential diagnosis for pulmonary TB cases indicating the need for future basic and clinical studies to more accurately identify, manage, control, and ultimately eradicate this disease.

*Keywords: Paragonimiasis; Paragonimus spp.; Trematode, Lung*

### **1. INTRODUCTION**

The lung trematode *Paragonimus* spp. that causes paragonimiasis is a neglected tropical disease (NTD) [1, 2] with significant socio-economic implications due to food-borne infection. Currently, more than 50 known species of *Paragonimus* have been reported worldwide and seven of which cause disease in humans are found in Asia [3, 4]. The parasite is endemic across the Far East, particularly in Asia and Southeast Asia, where the population frequently consumes raw or undercooked crustaceans [5].

*Paragonimus* spp. has an intricated life cycle that includes mammals' final hosts, first, and second intermediate hosts. The clinical picture of paragonimiasis is mainly pulmonary symptoms, which occur when freshwater crabs containing metacercariae are consumed raw or undercooked, or when humans consume uncooked paratenic hosts infected with the larval stages [1, 4]. The metacercariae then excyst in the small intestine, break through the abdominal wall, and go into the diaphragm, and lung. Adult flukes lodge in the lung tissue and develop symptoms including chronic cough, hemoptysis, chest or abdominal pain, pleural effusion, intrapulmonary nodules, and pneumothorax with respiratory symptoms [6, 7]. A condition known as extrapulmonary paragonimiasis or ectopic infection results when metacercariae move to certain additional tissues, including the liver, neck, kidney, peritoneum, and spinal cord, especially in the central nervous system (CNS), which is common in some species in Asia [8, 9]. The gold standard for diagnosing *Paragonimus* spp.

is detecting ova in a sample of sputum. Radiological examination and computed tomography (CT) in paragonimiasis found nodules or lung masses. Pulmonary and radiological symptoms often overlap and are like those of pulmonary tuberculosis (TB) and lung cancer, so they are potentially misdiagnosed. Microbiologists have reported pulmonary paragonimiasis diagnosed as smear-negative TB and subsequently treated with tuberculosis drugs [3, 10].

Human paragonimiasis has spread across the globe recently because of increased international tourism, human migration, and foodstuff trading. Paragonimiasis is thought to pose a risk to approximately 22 million people globally. The World Health Organization (WHO) in 2015 reported that an estimated 14 million people worldwide suffer from TB and the global burden of *Paragonimus* spp. is approximately one million disability-adjusted life years (DALYs) [11, 12].

We outline the characteristics of paragonimus geographical distribution and epidemiology, biology, and life cycle, as well as the pathogenesis, diagnosis, and management. We also demonstrate that paragonimiasis has the potential to be used as a differential diagnosis for pulmonary tuberculosis cases in Indonesia indicating the need for future basic and clinical studies to more accurately identify, manage, control, and ultimately eradicate this disease.

## 2. LUNG TREMATODE: THE GENUS *PARAGONIMUS*

The genus *Paragonimus* (Trematoda: Paragonimidae) is a multi-host fluke with a complicated life cycle that includes the definitive host mammals and two intermediates host (snails and freshwater copepods crustaceans), which transmits a lung disease through food called paragonimiasis [13]. Seven of the fifty *Paragonimus* species that have been discovered—particularly *P. westermani*, *P. heterotremus*, and *P. skrjabinimiyazakii*—highly crucial in regard to infection in humans and spreading throughout Asia [13, 14].

### 2.1 GEOGRAPHICAL DISTRIBUTION

The tropics and subtropics have a widely scattered of the genus *Paragonimus*, where the species that cause human paragonimiasis vary between countries. Human cases occur sporadically due to the habit of intake raw/underdone crab or crayfish. About 20 million people are infected with *Paragonimus*, and about 300 million people are at risk, with most in mainland China [10]. Japan has the highest prevalence of paragonimiasis in the entire globe, ranging around from 25 % to 67%. The etiology of paragonimiasis in Japan is *Paragonimuswestermani* with *P. skrjabinimiyazakii*, where *P. westermani* predominates [10, 15].

An epidemiological survey in China in 2000 stated that the prevalence of paragonimiasis ranged from 1.9 to 33.7% [16]. According to a survey study in the Philippines, the average paragonimiasis prevalence was between 12% to 52%, and an update from Zamboanga stated that the prevalence reached 6.7% [17]. Infection prevalence in newly endemic regions was discovered nearly 7% in India, ranging between 0.2 to 11% in Vietnam's North and 0.6% to 14% in Laos [18-20]. The primary agent in East Asian and Philippines is *P. westermani*. Yet, *P. heterotremus* acts as the main culprit in three South China territories, as well as in South and Southeast Asian nations [15, 21].

Four species of Paragonimiasis in Africa —*P. uterobilateralis*, *P. africanus*, *P. gondwanensis*, *P. kerberti*—commonly occur in Cameroon, Ivory Coast, and Nigeria [1, 22].

The sole species that infects humans in North America is *P. kellicotti* [23, 24]. While, *P. peruvianus*, *P. ecuadorensis*, as well as *P. inca*, are the main culprits in Central to South America, that well thought to *P. mexicanus* synonyms [25]. Even though *Paragonimus* spp. are not native to Indonesia, numerous investigations in Java have found adult *P. westermani* worms in cats and dogs. Krijgsman, 1933 discovered *P. westermani* from Sumatera tigers. However, until now no cases of autochthonous paragonimiasis in humans have been reported in Indonesia [26], which is common in Asia and Southeast Asia.

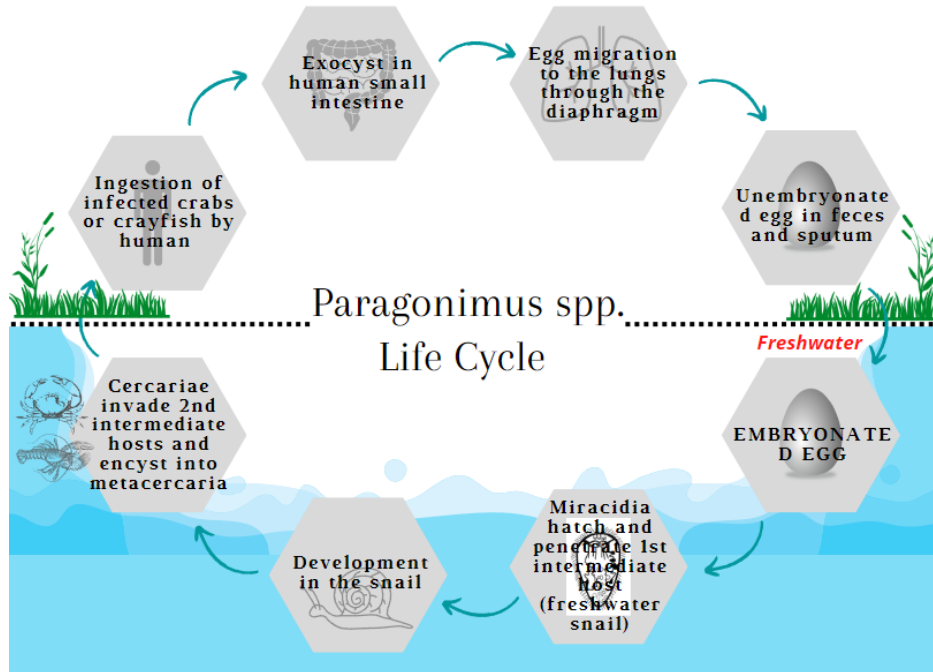
According to the phylogenetic analysis of the genus *Paragonimus*, there are many different species belonging to this genus, which affect significant taxa alteration due to the collection of genetic data. A few species are currently replaceable by *P. ohirai*, including *P. iloktuensis* and *P. sadoensis*. Respectively, it is acknowledged that *P. proliferus* and *P. harinasutai* can both be used interchangeably with *P. hokuoensis* and *P. microrchis*. Many subspecies are established of various species, and *P. miyazakii* is a subspecies of *P. skrjabini* [27, 28]. There are four "species complexes" made up of *P. westermani*, *P. skrjabini*, *P. heterotremus*, plus *P. ohirai*, according to a phylogenetic study of *Paragonimus* spp. in Asia. A group of animals that belong to distinct species but have plenty of genetic similarities due to having morphological, physiological, or other phenotypic traits is referred to as a "species complex" [29]. *Paragonimus westermani* is grouped into three primary categories determined by genetic data: Southern, Southeast, and Northeast Asian [30-32].

## 2.2 MORPHOLOGY AND LIFE CYCLE OF *PARAGONIMUS* SPP.

The adult flukes have an ova-like form with measures: 10 mm long, 5 mm wide, and 4 mm thick. Live flukes resemble coffee beans (in shape, size, and color) along with suckers (mouth and stomach). The primary features used to identify a species are often determined by the size, structure, and ratio between the oral and stomach sucker, the spines-shaped cuticle as well as the testes' and ovaries' form, position, and size. Species identification is frequently performed using the morphology of metacercaria [3, 11, 19].

The hermaphrodite fluke *Paragonimus* spp. has intricate life cycles (**Fig. 1**), usually living as pairs in cystic spaces in the lungs of the definitive mammalian host and less often in other organs [3]. The human life cycle of these fluke ranges from one to twenty years. The definitive host of *Paragonimus* spp. outside humans especially cats and carnivores, among other species of crab-eating mammals. *Paragonimus* spp. ova containing undeveloped miracidium are expelled from hosts through the respiratory system in sputum or become ingested and expelled with faeces. These immature ova are distinctive; they are frequently asymmetric, somewhat oval, yellow-brown, 80–120  $\mu$ m x 45–70  $\mu$ m in size (properly sized by species) and have thick-smooth shells with prominent operculum observable at the end. Large ova size aids in the detection of *Paragonimus* spp. [19, 33].

The miracidium is released once the paragonimus ova hatches in freshwater after growing fully in the outer milieu for about two weeks. The freshwater snails that prevail as the first intermediate hosts belong to *Semisulcospira*, *Hua*, *Syncera*, and *Brotia* which can be detected by the ciliated miracidium and then enter the soft tissues. Miracidium produces



**Fig. 1.** The life cycle of Paragonimiasis. Miracidium-containing undeveloped eggs are discharged from hosts in sputum or feces. Freshwater snails are the first intermediate hosts that the released miracidium enters when the eggs hatch in freshwater. During asexual growth in snails, Miracidium creates sporocysts, two generations of redia, and cercariae. The developed metacercaria (an infectious form) emerges from the adult cercariae as they exit the snail and infiltrate the secondary host tissue (crabs or crawfish). When eating unripe, undercooked, or pickled meat from a second intermediate host who has previously been exposed to Paragonimus' metacercaria, the definitive host will get sick. Metacercaria exits the small intestine and enters the pleural cavity and lungs through the abdominal wall. The metacercarial bronchioles in the lungs form capsules that develop into adult flukes.

sporocysts, two generations of redia, and cercariae during asexual growth in snails. The mature cercariae discharge from the snail and invade the secondary host tissue. The second intermediate host is crabs or crawfish. The crabs are from the genera *Eriocheir*, *Geothelphusa*, and *Potamon*, but in Asia are from the families *Potamidae* and *Parathelphusidae*. While crawfish are usually from the genera *Cambaroides* and *Procambarus*. The second intermediate host acquires infection after ingesting snails infected with cercariae. Furthermore, the cercariae develop into metacercaria, an infectious form with a spheroid and a diameter of 280–450 m [34, 35].

Upon ingestion of unripe, undercooked, or pickle meat from a second intermediate host formerly exposed to *Paragonimus*' metacercaria, the definitive host will become infected. Metacercaria leaves the small intestine within 3 - 6 hours, notably the duodenum, pass through the intestinal wall to the peritoneal cavity, penetrate the abdominal wall, and dwell there for a few days. Afterward, metacercaria adjourn through the abdominal wall or about the diaphragm to the pleural cavity and lungs. In the lungs, capsules form surrounding the metacercarial bronchioles and grow into adult flukes [10, 36]. Human paragonimiasis may also be brought on by ingesting unripe or undercooked paratenic hosts harbouring larvae. Metacercaria that paratenic hosts ingest are persisted in the tissues as a larval stage, usually in muscle [34, 37].

### **3. PARAGONIMIASIS**

Among "neglected tropical disease" agents, paragonimiasis typically has a broad spectrum of manifestations due to its intricate migration path. The infections may result in extrapulmonary complications in addition to pulmonary symptoms based on the site of the flukes [37, 38]. Paragonimiasis manifestations proceed from the initial metacercaria movement from the digestive to the respiratory system. Due to the patient sensitivity, there may develop a spreading allergic rash. Approximately 20% of paragonimiasis patients have no symptoms. The acute phase is characterized by abdominal pain, diarrhea, and urticaria, which coincide with the time of invasion and migration of the adult flukes. Several days after the initial symptoms, fever, cough, dyspnea, chest discomfort, malaise, and sweating occur [5, 39]. In some cases, hepatosplenomegaly, pulmonary abnormalities, and eosinophilia may present. This acute phase lasts for several weeks on average [40].

#### **3.1 Pulmonary paragonimiasis**

The flukes enter the lungs through the pleura by crossing the diaphragm. Changes occur with forming of granulomatous inflammation caused by parasitic invasion of the lungs and pleural space. Pulmonary manifestation due to invading flukes into the lungs can appear as pleurisy, pneumonia, and bronchitis. Generally, the symptoms include chest discomfort or snugness, productive cough with bloody or brownish phlegm sputum [41, 42]. Major pathological changes, such as hydropneumothorax, parenchymal infiltration, and pleural effusion can be found in the early invasive stage. Migration flukes can also invade the mediastinum. At this stage of infection subsequently, dense fibrous granulomas filled with purulent fluid encircled the flukes. The predominant histological abnormalities are cystic bronchial dilatation and widespread or localized pulmonary fibrosis [43-45]. The highly prevalent feature in thorax photos is unilateral or bilateral pleural effusion. An image of inflammatory infiltration, nodular lesions, calcify spots, and fibrotic lesions is also present. Additionally, the cavity lesion is not as common as would be predicted [10, 46, 47]. Paragonimiasis may occasionally be incorrectly recognized as pulmonal malignancy or tuberculosis, yet eosinophilia was evident even in these cases of misdiagnosis at the first hospital visit. Thus, key indicators for the diagnosis of paragonimiasis are localized eosinophilic infiltration and peripheral eosinophilia due to intense eosinophilic inflammation present wherever flukes are sited. Additional laboratory results include leucocytosis and raise serum total Ig-E levels than normal controls by at least threefold [3, 19, 48]. If paragonimiasis is left untreated, the patient may continue suffering from certain symptoms for years.

### 3.2 Extrapulmonary paragonimiasis

The lung fluke *Paragonimus* spp. sometimes migrates improperly to other areas of the body causing granulomatous lesions. The sites most affected are the subcutaneous tissue, especially the abdomen and anterior chest wall. Cerebral paragonimiasis is the most severe disease linked to paragonimiasis, which manifests with certain neurological symptoms and potentially causes death, depending on the location. Involvement of the nervous system accounted for 45% of all extrapulmonary paragonimiasis cases in Korea [49]. Uncertainty exists on how the flukes move from the lung to the brain. The flukes may reach the brain by passing via free muscular spaces between the spinal column, or they might simply get there by entangling themselves in the soft tissues that encircle the carotid artery and other small blood vessels. In the early active stages, cerebral herniation can result from migrating flukes providing cerebrovascular oedema with or without a middle-line shift. Long-distance migration is primarily fuelled by the fluke's active motility and tissue-hydrolysing proteolytic enzymes detached by the flukes. This migration often causes acute/subacute hematomas [8, 50, 51], nevertheless most cerebral cases are associated with chronic morbidity due to cephalgia, homonymous hemi or quadrantanopia, and partial seizures (including Jacksonian and temporal lobe epilepsy) [52, 53]. Predilection sites for brain involvement include the temporal, occipital, and parietal lobes. Although rare, spinal paragonimiasis can also occur commonly in the thoracic spine [8, 50]. *Paragonimus kellicotti* infection is over inclined to involve the pleura, cardiac and pericardial, lymphatic glands, and up of abdomen rather than *P. westermani* infection, possibly because of its tendency to migrate [54, 55].

### 3.3 Pathogenesis and Clinical symptoms

Right after swallowing, encysted (derived crustacea hosts) or juvenile (derived paratenic hosts), metacercariae infiltrate the gut wall. After penetrating the intestinal wall, the juvenile flukes immediately reach the peritoneum space and temporarily reside within the muscle of retroperitoneum [56, 57]. After 5-7 days, it develops there, reappears in the peritoneum space, then moves past the diaphragm to the space of pleura about 14 days after infection and finally the flukes enter the lungs. The flukes mating in the pleural cavity and then move to the lung parenchyma where fibrous cysts develop around the flukes. Each fluke produces ova that pass from the cyst to the small bronchioles and finally to the external environment via sputum or faeces. On their route to the pulmonary, a number of flukes stray to fully grow in different places beyond the pulmonary [35, 41].

Intense inflammatory eosinophilic around the flukes is one of the clinical indications of paragonimiasis that can be found anywhere that flukes are present. Eosinophils are generally believed to play important roles in the pathogenesis of certain allergic or inflammatory disorders resulting in tissue damage through eosinophil-derived cytotoxic mediators involved in eosinophilic inflammation. In order to accumulate within sites of inflammation, eosinophils must adhere to, and migrate across the microvasculature. These processes are largely controlled by type 2-immune responses. It is well known that eosinophils have anti-microbial activity, often elevated, and represent important effector cells in the course the fluke infections. The onset of eosinophilia typically occurs together with the larval movement through tissues earlier during fluke infection. The eosinophilia that characterizes paragonimiasis is often noticeable, peaks about two months after the illness begins coincides with pleural implication, and gradually diminishes as the parenchymal illness progresses [58-60].

*Paragonimus* spp. metacercariae ought to excystment in the host intestinal tract to infect a definitive or paratenic host since it is known that particular cysteine proteases from metacercariae contribute to excystation. The excretory-secretory product (ESP) of recently expelled metacercariae showed signs of protease activity. Specific stimuli cause this product to activate, causing excitement [61, 62]. Metacercariae secrete biologically active molecules such as cysteine proteases and antioxidant enzymes, which have a prominent function in pathophysiological mechanisms due to the involvement in fluke movement by encouraging tissue lysis and regulating the host immune response by neutralizing Immunoglobulin G (IgG). Excretory-secretory products (ESP) from metacercariae activated by specific stimuli, promote excystation. Previous study found that a reductant, dithiothreitol (DTT) and cysteine protease inhibitors affected the excystation. To infect a definitive or paratenic host, metacercariae of *Paragonimus* spp. must exit the host gut and it is known that certain cysteine proteases from metacercariae are involved in excystation. Protease activity was detected in the excretory-secretory product (ESP) of newly excreted metacercariae [37, 63, 64]. This proteolytic enzyme is linked to eosinophil IL-8 generation, proliferation of cells CD8-positive, and interleukin (IL)-2 receptor expression oppression in lymphocytes. During the initial migratory phase, these enzymes can help enervate helminthiasis triggered by eosinophils which are IgG-dependent, as well as tissue inflammation brought on by eosinophils. Flukes secrete cysteine proteases which can trigger the Th2 component of the immune response to generate response of IgG [65-68].

The milieu of Th2-type immune response in the host is regulated by the flukes to assure survival. Fluke parasites secrete chemicals that not solely harshly enhance Th2 immune responses but also could decrease Th1 cytokine responses to successfully establish a persistent infection [63, 66]. The Th2 cell subset triggers a wide variety of reactions deemed essential for defending the host against parasitic helminth infections and for encouraging damaged tissue healing. The Th2 cell subset releases IL-4, IL-5, IL-9, and IL-13, whilst IL-5 rises in the presence of *Paragonimus* spp. Further, combining these cytokines fosters type 2 immune response features such as smooth muscle contraction, the growth of B cells, class switching of immunoglobulin to Ig-E, eosinophilia and mastocytosis, goblet cell hyperplasia, macrophages polarization [69-72]. The detoxifying and removal of possibly hazardous xenobiotics involving superoxide dismutase, catalase, glutathione peroxidase, and glutathione transferase which are antioxidant enzymes that act as intermediaries for reactive oxygen and glutathione peroxidase [8, 13, 73]. Peripheral eosinophilia in paragonimiasis has been linked to higher blood serum IL-5 levels and pleural effusions, and limited knowledge regarding the host's effector immune system [74-76].

## **4. DIAGNOSIS**

The clinical and epidemiology histories of the patient, alongside radiographic and laboratory results, are all important factors in making the paragonimiasis diagnosis. The diagnosis gets established when ova features are found through microscopic analysis of faeces or sputum specimens [77, 78]. Nevertheless, Identification of ova is not applicable for extrapulmonary paragonimiasis with a limited accuracy of less than 50 percent [5, 79]. Current findings of paragonimiasis can be confirmed using serologic testing. The most accurate and precise test for paragonimiasis is immunoblot test, which may reflect immature and fully developed variants of the cysteine protease, respectively [8, 68, 80].

### **4.1 Parasitology examinations**

Paragonimiasis patients frequently cough up brick-colored, rotten fish-smelling sputum. It has a foul odor and a rusty phlegm-like appearance, or dark hemoptysis. The sputum smear was microscopic examined, and a sizable golden-brown ova mass was discovered [10, 81, 82]. Bronchoscopy and bronchoalveolar lavage (BAL) are frequently performed on patients with paragonimiasis because the radiological findings, signs, and symptoms are similar to those of pulmonary malignancy and tuberculosis. Ova of *Paragonimus* spp. are discovered in cytological smears of BAL fluid. Due to the patient constantly swallowing phlegm, ova of *Paragonimus* spp. might also be found in the faeces when it is examined. Due of the relatively limited sensitivity of the Kato-Katz stool test, the formalin-ether concentration approach is advised. For increased diagnostic sensitivity, up to five examinations must be performed [54, 83].

The biopsy material stained with hematoxylin and eosin serves as the basis for the confirming diagnosis of extrapulmonary paragonimiasis. A large granuloma formed primarily of palisading histiocytes, Charcot-Leyden crystals, and inflammatory cells such as eosinophils, lymphocytes, and neutrophils can be seen under the microscope. The fluke is found in the middle of the granuloma in samples of active lesions such as subcutaneous paragonimiasis. A single granuloma often contains two flukes. The size of the worm part, tegumental spines, sub-tegumental cells, the architecture of the gut, and distinctive egg part serves as markers for determining the species of *Paragonimus*. It is important to differentiate between *Fasciola* species while diagnosing fluke parts. Caseous substances are present in the middle of the calcification conglomerated granuloma in ectopic foci. A direct examination of necrotic tissue or an inspection of ova in the granuloma walls corroborates the diagnosis [35, 41, 64].

#### **4.2 Features of radiography**

Pneumothorax or hydropneumothorax, localized space consolidation, and linear opaqueness are the earliest signs of pleuropulmonary paragonimiasis. Thin-walled, dense mass-like consolidations, nodules, or bronchiectasis brought on by fluke cysts are later cyst findings. Additionally, ring shadows and uneven airspace consolidation, with or without cystic alterations, are frequently seen. Pneumothorax or bilateral pleural effusions are recognized as well but rare, occurring more frequently in instances of serious illness. Linear opacities brought on by fluke movement are crucial for the differential diagnosis of tuberculosis. These results are frequently comparable to those seen in tuberculosis. Round attenuated cystic lesions filled with fluid or gas are typically seen in consolidation on computed tomography (CT) studies. It is possible to find intracystic fluke by looking for peripheral linear opacities, which represent signs of fluke migration. Additionally, CT can shed light on helminth cysts and their migration routes, but results may differ depending on the infection stage [76, 82, 84-86].

Round low-attenuated cystic lesions are frequently seen inside the consolidation on computed tomography (CT) imaging. It is possible to find intracystic worms by looking for peripheral linear opacities, which are indicative of fluke migration trails. The findings may differ depending on the infection stage; however, CT can provide further information on the fluke cyst and migration path. A cluster of enhancing lesions with a grape-cluster look and surrounding oedema in one cerebral hemisphere, with or without enhancing lesions, is the most typical feature in early cerebral paragonimiasis. There are also areas of low density that are poorly defined and cerebral hematoma. Typically, hardened granuloma lesions with great density are seen over time. Conventional skull radiographs of patients with persistent cerebral paragonimiasis show calcifications that resemble soap bubbles [13, 54, 77, 82].

### 4.3 Immunology techniques

A straightforward indirect enzyme-linked immunosorbent assay (ELISA) employing somatic extracts of adult fluke as an antigen is the most used serological test in Japan for the diagnosis of paragonimiasis [87-89]. Due to the antigenic similarities across species, patients with other trematode illnesses, such as schistosomiasis, fascioliasis, and clonorchiasis, frequently experience cross-reactions. More advanced assays for detecting immunoglobulin classes have been used in Southeast Asia, where many fluke infections are common. They proved that particular IgE and IgG sub-class antibodies can boost the sensitivity and specificity of paragonimiasis diagnosis. Different antigen preparations have been assessed in order to increase the specificity of serodiagnosis. A good option for an ELISA antigen with high specificity is claimed to be the excretory-secretory (ES) antigen of adult worms, which is a metabolic byproduct of flukes that is collected *in vitro*. Additionally, with great success, monoclonal antibody-affinity purified antigens are employed [73, 74, 90, 91].

The trends in animal experimentation—reducing, substituting, and refining animal testing—make it increasingly difficult to obtain mature flukes. The application of serodiagnosis techniques using ES antigens is constrained by the challenge of antigen production. The synthesized peptide based on the antigenic region of *Paragonimus* spp. preprocathepsin L demonstrated high cross-reactivity in addition to excellent sensitivity and positive predictive value [91]. Recombinant *Paragonimus* spp. antigens, including as secreted cysteine proteases and egg proteins, have been reported to be applied to ELISA to get around the issue [92-95]. Although they have not yet been used in a clinical diagnosis, ongoing investigations suggest that ELISAs based on recombinant *Paragonimus* spp. antigens could be a useful tool for enhancing the sensitivity and specificity for serodiagnosis of paragonimiasis. In order to diagnose paragonimiasis, further information such as clinical signs and clinical data about risk factors for *Paragonimus* spp. infection such as place of residence, travel history, and consumption of freshwater crab or uncooked wild boar and/or deer meat should be acquired. There are no distinguishing characteristics of paragonimiasis for pulmonary symptoms with peripheral blood eosinophilia and increased serum Ig-E levels. As a result, a quick and easy differential diagnosis method is crucial as a first screening step. The multiple-dot ELISA technique was created for this purpose and is now used in the regular serodiagnosis of parasite diseases [94-97].

### 4.4 Molecular techniques

Even though examination of sputum or feces for ova is the gold standard for the diagnosis of paragonimiasis, ova can rarely be found. In paragonimiasis-tuberculosis-endemic locations that rely on microscopic techniques to detect *Paragonimus* spp. ova, a poor ova detection rate will present issues. This is worsened by clinical signs and radiological findings similar to tuberculosis. Moreover, concomitant food-borne trematodiasis occurs in several countries, and it is challenging to distinguish them simply based on morphological traits [40, 64, 98].

Current developments in molecular biology, particularly the polymerase chain reaction (PCR) and sequencing methods, are useful in helping distinguish closely related species, such as *Mycobacterium tuberculosis*, by comparing their DNA. The spread of *Paragonimus* spp. and its evolutionary diversity have been successfully demonstrated using PCR-based methods

relying on both mitochondrial cytochrome c oxidase subunit 1 (CO1) sequence and the second internal transcribed spacer (ITS2) of ribosomal DNA [99, 100].

## 5. HUMAN PARAGONIMIASIS: POTENTIALLY PUBLIC HEALTH ISSUE

One of the NTDs that the Sustainable Development Goals of the United Nations [101] aim to eradicate is paragonimiasis infections, which are becoming a growing public health issue in the Southeast Asian (SEA) and Pacific regions. SEA covers the following countries: Bangladesh, Bhutan, India, the Democratic People's Republic of Korea, Timor-Leste, the Maldives, Myanmar, Nepal, Sri Lanka, Thailand, and Indonesia. While Pacific region covering Australia, Brunei Darussalam, Cambodia, China, Japan, Malaysia, and so forth [102, 103].

Three indigenous focus regions—Asia, South and Central America, and Africa—are endemic to human paragonimiasis. The cases have been documented in India, Thailand, China, Japan, Lao PDR, South Korea, Philippines, and Vietnam [104-110]. On the other hand, there are limited data on paragonimiasis in some nations, such as Cambodia [111]. On the Indonesian island of Java, Soediro discovered *P. westermani* in dogs and cats, whereas Krijgsman was discovered in Sumatra tigers [26]. As of the present time, Indonesia has not reported any cases of human paragonimiasis.

Paragonimiasis is a lung trematode infection caused by genus *Paragonimus*, which is spread by eating uncooked or improperly prepared crabs. Due to the clinical signs (including hemoptysis and a persistent cough) and radiological findings of paragonimiasis being similar to those of tuberculosis, misdiagnosis of this parasite infection is frequent, especially in co-endemic areas. An incorrect diagnosis could result in unnecessary expenses from inefficient therapy and the infection's persistent morbidity, which would impair the infection's ability to be controlled. WHO suggests combining TB and paragonimiasis surveillance [103].

In the WHO's Southeast Asian and Pacific regions, paragonimiasis has evolved into a more serious public health issue due to its intensely focalized infection spread. Paragonimiasis infections have an adverse effect on public health and the economy in terms of absenteeism, morbidity, medical expenses, and lost output in agriculture and other sectors. Nevertheless, health education that promotes hygienic food handling and cooking techniques, along with appropriate care-seeking behaviours and targeted therapy, greatly lowers the number of paragonimiasis cases [112]. Furthermore, building the capacity of health workers is essential for identifying cases, medication delivery, and data gathering for the formulation of policies based on scientific evidence. Academic research facilities and health science centers can be important assets for enhancing capacity and serving as centers of reference for patients requiring specialized care and additional diagnosis [113].

Encircled geographically by endemic countries and has the second-highest TB burden worldwide, hence paragonimiasis cases in Indonesia are not completely ruled out. The Indonesian government through the Ministry of Health has never conducted a national survey on paragonimiasis and TB. Independent research is very rare, making paragonimiasis a very neglected NTD disease. In the future, policy stakeholders and researchers may use this data to investigate *Paragonimus* spp. in Indonesia and determine humans paragonimiasis prevalence. Due to this, paragonimiasis may need to be taken into consideration as a differential diagnosis for tuberculosis or co-infection. Furthermore, the government could take this into account in the future when renewing the tuberculosis eradication campaign.

## 6. CONCLUSION

Finding paragonimiasis cases and taking preventive measures are critical to reducing disease morbidity and ending the cycle of transmission. Patients with clinical symptoms and radiological features resembling pulmonary tuberculosis should be further evaluated for paragonimiasis, especially in endemic areas. Non-endemic countries ought to keep to be vigilant concerning the emergence of paragonimiasis. It is crucial to think about reevaluating the diagnosis if anti-tuberculosis therapy fails, a smear examination yields a negative result, and there is a history of consuming crabs or crayfish.

## CONSENT

Not Applicable.

## ETHICAL APPROVAL

Ethics approval was not required because this study did not involve human or animal experiments.

## REFERENCES

1. Rabone M, Wiethase J, Clark PF, Rollinson D, Cumberlidge N, Emery AM. Endemicity of *Paragonimus* and paragonimiasis in Sub-Saharan Africa: A systematic review and mapping reveals stability of transmission in endemic foci for a multi-host parasite system. *PLoS Negl Trop Dis*. 2021; **15**(2): e0009120. doi: 10.1371/journal.pntd.0009120. PMID: 33544705; PMCID: PMC7891758.
2. Delos Trinos JPC, Ison OT, Anino MRC, Lacuna JDM, Jorge MC, Belizario VY. Identification of suspected paragonimiasis-endemic foci using a questionnaire and detection of *Paragonimus* ova using the Ziehl–Neelsen technique in Zamboanga Region, the Philippines. *Pathog Glob Health*. 2020;**114**(3): 136-144. doi: 10.1080/20477724.2020.1741900. PMID: 32191613; PMCID: PMC7241446.
3. Qian M, Li F, Zhang Y, Qiao Z, Shi Y, Shen J. A retrospective clinical analysis of pediatric paragonimiasis in a Chinese children's hospital from 2011 to 2019. *Scientific Reports*. 2021;**11**(1): 1-8. doi: 10.1038/s41598-021-81694-7.
4. Blair D. Paragonimiasis. In: Toledo R, Fried B. (eds) *Digenetic Trematodes*. *Adv Exp Med Biol*. 2019; 1154: 105-138. Springer, Cham. doi: 10.1007/978-3-030-18616-6\_5
5. Al Bishawi A, Salameh S, Ehtesham A, Massad I, Arachchige S, Hatim A, et al. *Paragonimus* infection: Rare manifestation with pericardial effusion: A Case report and Literature review. *IDCases*. 2021;**24**:e01075. doi: 10.1016/j.idcr.2021.e01075. PMID: 33850719; PMCID: PMC8022158.
6. Hwang KE, Song HY, Jung JW, Oh SJ, Yoon KH, Park DS, et al. Pleural fluid characteristics of pleuropulmonary paragonimiasis masquerading as pleural

- tuberculosis. *Korean J Intern Med.* 2015;**30**(1): 56.doi: 10.3904/kjim.2015.30.1.56. Epub 2014 Dec 30. PMID: 25589836; PMCID: PMC4293564.
7. Kim HJ. Pneumothorax induced by pulmonary paragonimiasis: two cases report. *Korean J Thorac Cardiovasc Surg.* 2014;**47**(3): 310.doi: 10.5090/kjtcs.2014.47.3.310. PMID: 25207235; PMCID: PMC4157488.
  8. Kim JG, Ahn CS, Kang I, Shin JW, Jeong HB, Nawa Y, Kong Y. Cerebral paragonimiasis: Clinicoradiological features and serodiagnosis using recombinant yolk ferritin. *PLoS Negl Trop Dis.* 2022;**16**(3): e0010240. doi: 10.1371/journal.pntd.0010240. PMID: 35294433; PMCID: PMC8959177.
  9. Cumberlidge N, Rollinson D, Vercruyse J, Tchuem Tchuenté LA, Webster B, Clark PF. Paragonimus and paragonimiasis in West and Central Africa: unresolved questions. *Parasitology.* 2018;**145**(13): 1748-1757.doi: 10.1017/S0031182018001439. PMID: 30210013.
  10. Yoshida A, Doanh PN, and Maruyama H. Paragonimus and paragonimiasis in Asia: an update. *Acta Trop.* 2019;**199**: 105074.doi: 10.1016/j.actatropica.2019.105074. Epub 2019 Jul 8. PMID: 31295431.
  11. World Health Organization. WHO estimates the global burden of foodborne diseases: foodborne disease burden epidemiology reference group 2007-2015. World Health Organization; 2015.
  12. Weissferdt A. Infectious Lung Disease. In: Weissferdt A (ed). *Diagnostic Thoracic Pathology.* 2020;3-71. Springer, Cham. doi:10.1007/978-3-030-36438-0\_1
  13. Zhou XJ, Yang Q, Tan QH, Zhang LY, Shi LB, Zou JX. Paragonimus and its hosts in China: an update. *Acta Trop.* 2021;**223**: 106094.doi: 10.1016/j.actatropica.2021.106094. PMID: 34389330.
  14. Orner KD, Naughton C, Stenstrom TA. *Water and Sanitation for the 21st Century: Health and Microbiological Aspects of Excreta and Wastewater Management (Global Water Pathogen Project).* 2018.
  15. Nagayasu E, Yoshida A, Hombu A, Horii Y, Maruyama H. Paragonimiasis in Japan: a twelve-year retrospective case review (2001-2012). *Intern Med.* 2015;**54**(2): 179-186.doi: 10.2169/internalmedicine.54.1733. PMID: 25743009.
  16. Liu Q, Wei F, Liu W, Yang S, Zhang X. Paragonimiasis: an important food-borne zoonosis in China. *Trends Parasitol.* 2008;**24**(7): 318-323.doi: 10.1016/j.pt.2008.03.014. PMID: 18514575.
  17. Belizario V Jr, Totanes FI, Asuncion CA, De Leon W, Jorge M, Ang C, Naig JR. Integrated surveillance of pulmonary tuberculosis and paragonimiasis in Zamboanga del Norte, the Philippines. *Pathog Glob health.* 2014;**108**(2): 95-102.doi: 10.1179/2047773214Y.0000000129. PMID: 24601907; PMCID: PMC4005588.
  18. Doanh PN, Horii Y, Nawa Y. Paragonimus and paragonimiasis in Vietnam: an update. *Korean J Parasitol.* 2013;**51**(6): 621-627.doi: 10.3347/kjp.2013.51.6.621. PMID: 24516264; PMCID: PMC3916448.

19. Singh TS, Sugiyama H, Rangsiruji A. Paragonimus & paragonimiasis in India. *Indian J Med Res.* 2012;**136**(2): 192-204. PMID: 22960885; PMCID: PMC3461730.
20. Vidamaly S, Choumlivong K, Keolouangkhot V, Vannavong N, Kanpittaya J, Strobel M. Paragonimiasis: a common cause of persistent pleural effusion in Lao PDR. *Trans R Soc Trop Med Hyg.* 2009;**103**(10): 1019-23. doi: 10.1016/j.trstmh.2008.12.005. PMID: 19185895.
21. Irie T, Yamaguchi Y, Doanh PN, Guo ZH, Habe S, Horii Y, et al. Infection with *Paragonimus westermani* of boar-hunting dogs in Western Japan maintained via artificial feeding with wild boar meat by hunters. *J Vet Med Sci.* 2017; **79**(8): 1419-1425. doi: 10.1292/jvms.17-0149. PMID: 28717056; PMCID: PMC5573832.
22. Aka NA, Adoubryn K, Rondelaud D, Dreyfuss G. Human paragonimiasis in Africa. *Ann Afr Med.* 2008;**7**(4): 153-162. doi: 10.4103/1596-3519.55660. PMID: 19623916.
23. Diaz JH. Paragonimiasis acquired in the United States: native and nonnative species. *Clin Microbiol Rev.* 2013;**26**(3): 493-504. doi: 10.1128/cmr.00103-12. PMID: 23824370; PMCID: PMC3719489.
24. Procop GW. North American paragonimiasis (caused by *Paragonimus kellicotti*) in the context of global paragonimiasis. *Clin Microbiol Rev.* 2009;**22**(3): 415-446. doi: 10.1128/CMR.00005-08. PMID: 19597007; PMCID: PMC2708389.
25. Bowman DD, Hendrix CM, Lindsay DS, Barr SC. *Feline clinical parasitology.* John Wiley & Sons; 2008.
26. Kwo EH, Miyazaki I. *Paragonimus westermani* (Kerbert, 1878) from tigers in north Sumatra, Indonesia. *J Parasitol.* 1968;**54**(3): 630. PMID: 5757735.
27. Blair D, Chang Z, Chen M, Cui A, Wu B, Agatsuma T, et al. *Paragonimus skrjabini* Chen, 1959 (Digenea: Paragonimidae) and related species in eastern Asia: a combined molecular and morphological approach to identification and taxonomy. *Syst Parasitol.* 2005;**60**(1): 1-21. doi: 10.1007/s11230-004-1378-5. PMID: 15791397.
28. Doanh N, Shinohara A, Horii Y, Habe S, Nawa Y, Le NT. Discovery of *Paragonimus proliferus* in Northern Vietnam and their molecular phylogenetic status among genus *Paragonimus*. *Parasitol Res.* 2008;**102**(4): 677-683. doi: 10.1007/s00436-007-0811-5. PMID: 18071749.
29. Nawa Y, Doanh PN. *Paragonimus bangkokensis* and *P. harinasutai*: reappraisal of phylogenetic status. *J Trop Med Parasitol.* 2009;**32**(2): 87-96.
30. Devi K, Narain K, Mahanta J, Nirmolia T, Blair D, Saikia SP, et al. Presence of three distinct genotypes within the *Paragonimus westermani* complex in northeastern India. *Parasitology.* 2013;**140**(1): 76-86. doi: 10.1017/S0031182012001229. PMID: 22917216.
31. Iwagami M, Rajapakse RP, Paranagama W, Okada T, Kano S, Agatsuma T. Ancient divergence of *Paragonimus westermani* in Sri Lanka. *Parasitol Res.* 2008;**102**(5): 845-852. doi: 10.1007/s00436-007-0820-4. PMID: 18193283.

32. Nawa Y, Thaenkham U, Doanh PN, Blair D. *Paragonimus westermani* and *Paragonimus* species. In: Motarjemi Y, Moy G, Todd E (eds). *Encyclopedia of Food Safety*. 2014; 179-188. Elsevier, San Diego, CA, USA. doi: 10.1016/B978-0-12-378612-8.00159-1
33. Chai JY. Chapter 23 - Paragonimiasis. In: Garcia HH, Tanowitz HB, Del Brutto OH (eds). *Handbook of Clinical Neurology*. 2013;283-296. Elsevier, San Diego, CA, USA. doi: 10.1016/B978-0-444-53490-3.00023-6
34. Chai JY, Jung BK. "Paragonimus spp." Water and Sanitation for the 21st Century: Health and Microbiological Aspects of Excreta and Wastewater Management (Global Water Pathogen Project). 2019: 1-23. doi: 10.14321/waterpathogens.46
35. Chai JY, Jung BK. General overview of the current status of human foodborne trematodiasis. *Parasitology*. 2022;149(10): 1262-1285. doi: 10.1017/S0031182022000725. PMID: 35591777; PMCID: PMC10090779.
36. Chai JY. Paragonimiasis. *Handb Clin Neurol*. 2013;114: 283-296. doi: 10.1016/B978-0-444-53490-3.00023-6. PMID: 23829919.
37. Mahanta J. Paragonimiasis. In: Parija SC, Chaudhury A (eds). *Textbook of Parasitic Zoonoses, Microbial Zoonoses*. 2022;245-258. Springer, Singapore. doi: 10.1007/978-981-16-7204-0\_22
38. Blair D. Lung flukes of the genus *Paragonimus*: ancient and re-emerging pathogens. *Parasitology*. 2022;149(10): 1286-1295. doi: 10.1017/S0031182022000300. PMID: 35292126; PMCID: PMC10090773.
39. Shim SS, Kim Y, Lee JK, Lee JH, Song DE. Pleuropulmonary and abdominal paragonimiasis: CT and ultrasound findings. *Br J Radiol*. 2012; 85(1012): 403-10. doi: 10.1259/bjr/30366021. PMID: 22457403; PMCID: PMC3486672.
40. Le TH, Nguyen KT, Pham LTK, Doan HTT, Agatsuma T, Blair D. The complete mitogenome of the Asian lung fluke *Paragonimus skrjabini miyazakii* and its implications for the family Paragonimidae (Trematoda: Platyhelminthes). *Parasitology*. 2022;149(13):1709-1719. doi: 10.1017/S0031182022001184. PMID: 36101009.
41. Kalhan S, Sharma P, Sharma S, Kakria N, Dudani S, Gupta A. *Paragonimus westermani* infection in lung: A confounding diagnostic entity. *Lung India*. 2015; 32(3): 265-7. doi: 10.4103/0970-2113.156248. PMID: 25983414; PMCID: PMC4429390.
42. Shah P, Sah R, Pradhan S, Bhandari P, Baral R, Khanal B, et al. Pulmonary Paragonimiasis: A Case Series. *JNMA J Nepal Med Assoc*. 2023;61(259): 290-293. doi: 10.31729/jnma.8080. PMID: 37203942; PMCID: PMC10231548.
43. Boddu P, Parimi V, Taddonio M, Kane JR, Yeldandi A. Pathologic and Radiologic Correlation of Adult Cystic Lung Disease: A Comprehensive Review. *Patholog Res Int*. 2017; 2017: 3502438. doi: 10.1155/2017/3502438. PMID: 28270943; PMCID: PMC5320373.
44. Culquichicón C, Hernández-Pacherres A, Labán-Seminario LM, Cardona-Ospina JA, Rodríguez-Morales AJ. Where are we after 60 years of paragonimiasis research? A

- bibliometric assessment. *Infez Med.* 2017; 25(2): 142-149. PMID: 28603233; PMCID: PMC5800300.
45. Cong CV, Anh TT, Ly TT, Duc NM. Paragonimiasis diagnosed by CT-guided transthoracic lung biopsy: Literature review and case report. *Radiol Case Rep.* 2022; 17(5): 1591-1597. doi: 10.1016/j.radcr.2022.02.046. PMID: 35309377; PMCID: PMC8927937.
  46. Sah SK, Du S, Liu Y, Yin P, Ganganah O, Chiniyah M, Yadav PK, Guo YY, Li Y. Imaging findings of *Paragonimus westermani*. *Radiol Infect Dis.* 2016; 3(2): 66-73. doi: 10.1016/j.jrid.2016.01.008
  47. Seon HJ, Kim YI, Lee JH, Kim SH, Kim YH. Differential Chest Computed Tomography Findings of Pulmonary Parasite Infestation Between the Paragonimiasis and Nonparagonimiasis Parasite Infestation. *J Comput Assist Tomogr.* 2015; 39(6): 956-61. doi: 10.1097/RCT.0000000000000310. PMID: 26359583.
  48. Yamamuro S, Ohoni S, Kamiya K, Imamura G, Harano S, Tahara J, et al. A case of cerebral paragonimiasis misdiagnosed as eosinophilic granulomatosis with polyangiitis. *Neuropathology.* 2022;42(4): 323-328. doi: 10.1111/neup.12841. PMID: 35723635; PMCID: PMC9542038.
  49. Kim MJ, Kim SH, Lee SO, Choi SH, Kim YS, Woo JH, et al. A Case of Ectopic Peritoneal Paragonimiasis Mimicking Diverticulitis or Abdominal Abscess. *Korean J Parasitol.* 2017. 55(3): 313-317. doi: 10.3347/kjp.2017.55.3.313. PMID: 28719956; PMCID: PMC5523897.
  50. Du J, Liu L, Fan H, Yu Y, Luo Y, Yu H, Liao X. Computed Tomography and Magnetic Resonance Imaging in the Diagnosis of Cerebral Paragonimiasis in Children. *Front Neurol.* 2022; 13: 852334. doi: 10.3389/fneur.2022.852334. PMID: 35720062; PMCID: PMC9198490.
  51. Xia Y, Chen J, Ju Y, You C. Characteristic CT and MR imaging findings of cerebral paragonimiasis. *J Neuroradiol.* 2016; 43(3): 200-6. doi: 10.1016/j.neurad.2014.10.006. PMID: 27261801..
  52. Moon SW, Kim T. Cerebral Paragonimiasis Presenting with Dementia. *Korean J Parasitol.* 2022; 60(5): 353-355. doi: 10.3347/kjp.2022.60.5.353. PMID: 36320112; PMCID: PMC9633155.
  53. Kim JG, Ahn CS, Kang I, Shin JW, Jeong HB, Nawa Y, Kong Y. Cerebral paragonimiasis: Clinoradiological features and serodiagnosis using recombinant yolk ferritin. *PLoS Negl Trop Dis.* 2022; 16(3): e0010240. doi: 10.1371/journal.pntd.0010240. PMID: 35294433; PMCID: PMC8959177.
  54. Henry TS, Lane MA, Weil GJ, Bailey TC, Bhalla S. Chest CT features of North American paragonimiasis. *AJR Am J Roentgenol.* 2012; 198(5): 1076-83. doi: 10.2214/AJR.11.7530. Erratum in: *AJR Am J Roentgenol.* 2013; 201(5): 1165. PMID: 22528896; PMCID: PMC3832351.
  55. Johannesen E, Nguyen V. *Paragonimus kellicotti*: A Lung Infection in Our Own Backyard. *Case Rep Pathol.* 2016; 2016: 2107372. doi: 10.1155/2016/2107372. PMID: 27213066; PMCID: PMC4860236.

56. Chae KJ, Kim JH. Mediastinal cysts associated with *Paragonimus westermani*. *Int J Infect Dis*. 2023; 133: 82-84. doi: 10.1016/j.ijid.2023.05.001. PMID: 37150353.
57. Zhang Y, Xie Y, Luo Y, Xiang S, Zhong W, Wu N, et al. Massive secretions in paragonimiasis pleural effusion: a new finding concerning clinical recognition and treatment. *Eur J Clin Microbiol Infect Dis*. 2023;42(4): 493-501. doi: 10.1007/s10096-023-04567-z. PMID: 36826718.
58. Nagata M, Nakagome K, Soma T. Mechanisms of eosinophilic inflammation. *Asia Pac Allergy*. 2020; 10(2): e14. doi: 10.5415/apallergy.2020.10.e14. PMID: 32411579; PMCID: PMC7203432.
59. Lombardi C, Berti A, Cottini M. The emerging roles of eosinophils: Implications for the targeted treatment of eosinophilic-associated inflammatory conditions. *Curr Res Immunol*. 2022; 3: 42-53. doi: 10.1016/j.crimmu.2022.03.002. PMID: 35496822; PMCID: PMC9040157.
60. O'Connell EM, Nutman TB. Eosinophilia in Infectious Diseases. *Immunol Allergy Clin North Am*. 2015; 35(3): 493-522. doi: 10.1016/j.iac.2015.05.003. PMID: 26209897; PMCID: PMC4515572.
61. Feng Y, Fürst T, Liu L, Yang GJ. Estimation of disability weight for paragonimiasis: a systematic analysis. *Infect Dis Poverty*. 2018; 7(1): 110. doi: 10.1186/s40249-018-0485-5. PMID: 30342548; PMCID: PMC6196032.
62. Morter R, Adetifa I, Antonio M, Touray F, de Jong BC, Gower CM, Gehre F. Examining human paragonimiasis as a differential diagnosis to tuberculosis in The Gambia. *BMC Res Notes*. 2018; 11(1): 31. doi: 10.1186/s13104-018-3134-y. PMID: 29334998; PMCID: PMC5769439.
63. Lee EG, Na BK, Bae YA, Kim SH, Je EY, Ju JW, et al. Identification of immunodominant excretory–secretory cysteine proteases of adult *Paragonimus westermani* by proteome analysis. *Proteomics*; 2006;6(4): 1290-1300. doi: 10.1002/pmic.200500399. PMID: 16404718.
64. Sanpool O, Intapan PM, Thanchomnang T, Janwan P, Laymanivong S, Sugiyama H, Maleewong W. Morphological and molecular identification of a lung fluke, *Paragonimus macrorchis* (Trematoda, Paragonimidae), found in central Lao PDR and its molecular phylogenetic status in the genus *Paragonimus*. *Parasitol Int*. 2015; 64(6): 513-8. doi: 10.1016/j.parint.2015.06.013. PMID: 26170107.
65. Shin MH, Kita H, Park HY, Seoh JY. Cysteine protease secreted by *Paragonimus westermani* attenuates effector functions of human eosinophils stimulated with immunoglobulin G. *Infect Immun*. 2001; 69(3): 1599-604. doi: 10.1128/IAI.69.3.1599-1604.2001. PMID: 11179333; PMCID: PMC98062.
66. Donnelly S, Dalton JP, Robinson MW. How pathogen-derived cysteine proteases modulate host immune responses. *Adv Exp Med Biol*. 2011; 712: 192-207. doi: 10.1007/978-1-4419-8414-2\_12. PMID: 21660666; PMCID: PMC7123607.
67. Shin MH, Lee SY. Proteolytic activity of cysteine protease in excretory-secretory product of *Paragonimus westermani* newly excysted metacercariae pivotally regulates

- IL-8 production of human eosinophils. *Parasite Immunol.* 2000; 22(10): 529-33. doi: 10.1046/j.1365-3024.2000.00337.x. PMID: 11012979.
68. Grote A, Caffrey CR, Rebello KM, Smith D, Dalton JP, Lustigman S. Cysteine proteases during larval migration and development of helminths in their final host. *PLoS Negl Trop Dis.* 2018; 12(8): e0005919. doi: 10.1371/journal.pntd.0005919. PMID: 30138448; PMCID: PMC6107106.
  69. Wen T, Rothenberg ME. The Regulatory Function of Eosinophils. *Microbiol Spectr.* 2016; 4(5). doi: 10.1128/microbiolspec.MCHD-0020-2015. PMID: 27780017; PMCID: PMC5088784.
  70. Walker JA, McKenzie ANJ. T<sub>H</sub>2 cell development and function. *Nat Rev Immunol.* 2018; 18(2): 121-133. doi: 10.1038/nri.2017.118. PMID: 29082915.
  71. Taniguchi H, Mukae H, Matsumoto N, Tokojima M, Katoh S, Matsukura S, et al. Elevated IL-5 levels in pleural fluid of patients with paragonimiasis westermani. *Clin Exp Immunol.* 2001; 123(1): 94-8. doi: 10.1046/j.1365-2249.2001.01425.x. PMID: 11168004; PMCID: PMC1905947.
  72. Bandeira-Melo C, Weller PF. Mechanisms of eosinophil cytokine release. *Mem Inst Oswaldo Cruz.* 2005; 100 Suppl 1(Suppl 1): 73-81. doi: 10.1590/s0074-02762005000900013. PMID: 15962102; PMCID: PMC2747295.
  73. Di Maggio LS, Curtis KC, Erdmann-Gilmore P, Sprung RSW, Townsend RR, Weil GJ, et al. Comparative proteomics of adult *Paragonimus kellicotti* excretion/secretion products released in vitro or present in the lung cyst nodule. *PLoS Negl Trop Dis.* 2022; 16(8): e0010679. doi: 10.1371/journal.pntd.0010679. PMID: 35976975; PMCID: PMC9423667.
  74. Taniguchi H, Mukae H, Matsumoto N, Tokojima M, Katoh S, Matsukura S, et al. Elevated IL-5 levels in pleural fluid of patients with paragonimiasis westermani. *Clin Exp Immunol.* 2001; 123(1): 94-8. doi: 10.1046/j.1365-2249.2001.01425.x. PMID: 11168004; PMCID: PMC1905947.
  75. Wang J, Luo W, Shen P, He J, Zeng Y. Retrospective study of pleural parasitic infestations: a practical diagnostic approach. *BMC Infect Dis.* 2019; 19(1): 576. doi: 10.1186/s12879-019-4179-9. PMID: 31272486; PMCID: PMC6610822.
  76. Paranjape N, Nunez V, Dicks D. Paragonimiasis presenting as an acute hemorrhagic stroke. *IDCases.* 2021; 26: e01287. doi: 10.1016/j.idcr.2021.e01287. PMID: 34589413; PMCID: PMC8461369.
  77. Poudyal BS, Paudel B, Bista B, Shrestha GS, Pudasaini P. Clinical, Laboratory and Radiological Features of Paragonimiasis Misdiagnosed as Pulmonary Tuberculosis. *Iran J Parasitol.* 2022; 17(3): 410-414. doi: 10.18502/ijpa.v17i3.10632. PMID: 36466025; PMCID: PMC9682384..
  78. Vélez ID, Ortega JE, Velásquez LE. Paragonimiasis: a view from Columbia. *Clin Chest Med.* 2002; 23(2): 421-31, ix-x. doi: 10.1016/s0272-5231(02)00003-5. PMID: 12092036.

79. Park CW, Chung WJ, Kwon YL, Kim YJ, Kim ES, Jang BK, et al. Consecutive extrapulmonary paragonimiasis involving liver and colon. *J Dig Dis.* 2012; 13(3): 186-189. doi: 10.1111/j.1751-2980.2011.00572.x. PMID: 22356314.
80. Sadaow L, Sanpool O, Yamasaki H, Maleewong W, Intapan PM. Development of point-of-care testing tool using immunochromatography for rapid diagnosis of human paragonimiasis. *Acta Trop.* 2020; 203: 105325. doi: 10.1016/j.actatropica.2019.105325. PMID: 31891708.
81. Kunitomo K, Yumoto S, Tsuji T. A Case of Paragonimiasis in a Patient with Wet Cough. *Am J Trop Med Hyg.* 2020; 103(3): 939-940. doi: 10.4269/ajtmh.20-0395. PMID: 32896236; PMCID: PMC7470576.
82. Cong CV, Anh TT, Ly TT, Duc NM. Paragonimiasis diagnosed by CT-guided transthoracic lung biopsy: Literature review and case report. *Radiol Case Rep.* 2022; 17(5): 1591-1597. doi: 10.1016/j.radcr.2022.02.046. PMID: 35309377; PMCID: PMC8927937.
83. Hwang KE, Song HY, Jung JW, Oh SJ, Yoon KH, Park DS, Jeong ET, Kim HR. Pleural fluid characteristics of pleuropulmonary paragonimiasis masquerading as pleural tuberculosis. *Korean J Intern Med.* 2015; 30(1): 56-61. doi: 10.3904/kjim.2015.30.1.56. PMID: 25589836; PMCID: PMC4293564.
84. Blair D. Paragonimiasis. *Adv Exp Med Biol.* 2019; 1154: 105-138. doi: 10.1007/978-3-030-18616-6\_5. PMID: 31297761.
85. Jiang YX, Li GQ, Pan CJ, He ZQ, Wang C, Mu QR, Cao LL. Pediatric paragonimiasis: a retrospective analysis of cases from a county in south-west China. *Front Pediatr.* 2023; 11: 1143262. doi: 10.3389/fped.2023.1143262. PMID: 37266536; PMCID: PMC10229819.
86. Calvopina M, Romero-Alvarez D, Macias R, Sugiyama H. Severe Pleuropulmonary Paragonimiasis Caused by *Paragonimus mexicanus* Treated as Tuberculosis in Ecuador. *Am J Trop Med Hyg.* 2017; 96(1): 97-99. doi: 10.4269/ajtmh.16-0351. PMID: 27879464; PMCID: PMC5239718.
87. Kashida Y, Niuro M, Maruyama H, Hanaya R. Cerebral Paragonimiasis with Hemorrhagic Stroke in a Developed Country. *J Stroke Cerebrovasc Dis.* 2018; 27(10): 2648-2649. doi: 10.1016/j.jstrokecerebrovasdis.2018.05.033. PMID: 30031686.
88. Mahanty S, Maclean JD, and Cross JH. CHAPTER 123 - Liver, Lung, and Intestinal Fluke Infections. In: Guerrant RL, Walker DH, Weller PF (eds). *Tropical Infectious Diseases: Principles, Pathogens and Practice (Third Edition)*. 2011;854-867. W.B. Saunders: Edinburgh.
89. Zhao QP, Moon SU, Na BK, Kim SH, Cho SH, Lee HW, et al. *Paragonimus westermani*: Biochemical and immunological characterizations of paramyosin. *xp Parasitol.* 2007; 115(1): 9-18. doi: 10.1016/j.exppara.2006.05.004. PMID: 16814286.
90. Kong Y, Ito A, Yang HJ, Chung YB, Kasuya S, Kobayashi M, et al. Immunoglobulin G (IgG) subclass and IgE responses in human paragonimiasis caused by three different species. *Clinical Diagnostic Laboratory Immunology.* 1998;5(4): 474-478. doi: 10.1128/CDLI.5.4.474-478.1998. PMID: 9665951; PMCID: PMC95602.

91. Intapan PM, Sanpool O, Janwan P, Laummaunwai P, Morakote N, Kong Y, et al. Evaluation of IgG4 subclass antibody detection by peptide-based ELISA for the diagnosis of human paragonimiasis heterotremata. *Korean J Parasitol.* 2013;**51**(6): 763-6. doi: 10.3347/kjp.2013.51.6.763. PMID: 24516288; PMCID: PMC3916472.
92. Kim TY, Joo IJ, Kang SY, Cho SY, Kong Y, Gan XX, Sukomtason K, Sukomtason K, Hong SJ. Recombinant *Paragonimus westermani* yolk ferritin is a useful serodiagnostic antigen. *J Infect Dis.* 2002; 185(9): 1373-5. doi: 10.1086/339880. PMID: 12001061.
93. Lee JS, Lee J, Kim SH, Yong TS. Molecular cloning and characterization of a major egg antigen in *Paragonimus westermani* and its use in ELISA for the immunodiagnosis of paragonimiasis. *Parasitol Res.* 2007; 100(4): 677-81. doi: 10.1007/s00436-006-0324-7. PMID: 17136389.
94. Ahn CS, Na BK, Chung DL, Kim JG, Kim JT, Kong Y. Expression characteristics and specific antibody reactivity of diverse cathepsin F members of *Paragonimus westermani*. *Parasitol Int.* 2015; 64(1): 37-42. doi: 10.1016/j.parint.2014.09.012. PMID: 25284814.
95. Pothong K, Komalamisra C, Kalambaheti T, Watthanakulpanich D, Yoshino TP, Dekumyoy P. ELISA based on a recombinant *Paragonimus heterotremus* protein for serodiagnosis of human paragonimiasis in Thailand. *Parasit Vectors.* 2018; 11(1): 322. doi: 10.1186/s13071-018-2878-5. PMID: 29843786; PMCID: PMC5975669.
96. Nakamura-Uchiyama F, Hiromatsu K, Ishiwata K, Sakamoto Y, Nawa Y. The current status of parasitic diseases in Japan. *Intern Med.* 2003; 42(3): 222-36. doi: 10.2169/internalmedicine.42.222. PMID: 12705786.
97. Yu S, Zhang X, Chen W, Zheng H, Ai G, Ye N, Wang Y. Development of an immunodiagnosis method using recombinant PsCP for detection of *Paragonimus skrjabini* infection in human. *Parasitol Res.* 2017; 116(1): 377-385. doi: 10.1007/s00436-016-5300-2. PMID: 27796563.
98. Choi JW, Lee CM, Kim SJ, Hah SI, Kwak JY, Cho HC, et al. Ectopic peritoneal paragonimiasis mimicking tuberculous peritonitis: A case report. *World J Clin Cases.* 2022; 10(16): 5359-5364. doi: 10.12998/wjcc.v10.i16.5359. PMID: 35812672; PMCID: PMC9210911.
99. Intapan PM, Sanpool O, Thanchomnang T, Imtawil K, Pongchaiyakul C, Nawa Y, Maleewong W. Molecular identification of a case of *Paragonimus pseudoheterotremus* infection in Thailand. *Am J Trop Med Hyg.* 2012; 87(4): 706-9. doi: 10.4269/ajtmh.2012.12-0235. PMID: 22826489; PMCID: PMC3516323.
100. Shu QH, Yang Y, Wang MM, Li SD, Tian M, Bai WW, Meng Y, He SM, Wang WL. Morphological and Molecular Characterization of *Paragonimus* Species Isolated from Freshwater Crabs in Southern Yunnan, China. *J Trop Med.* 2021; 2021: 5646291. doi: 10.1155/2021/5646291. PMID: 35003270; PMCID: PMC8741392.
101. Organization, W. H. (2023). Global report on neglected tropical diseases 2023, World Health Organization.

102. Organization, W. H. (2021a). South-East Asia regional strategy for primary health care: 2022–2030, World Health Organization. Regional Office for South-East Asia.
103. Organization, W. H. (2021b). "The health-related Sustainable Development Goals: progress report of the Western Pacific Region, 2020."
104. Das, M., et al. (2016). "Paragonimiasis in tuberculosis patients in Nagaland, India." *Global Health Action* 9(1): 32387.
105. Yoonuan, T., et al. (2008). "Paragonimiasis prevalences in Saraburi Province, Thailand, measured 20 years apart." *Southeast Asian journal of tropical medicine and public health* 39(4): 593.
106. Zhang, X.-l., et al. (2012). "Distribution and clinical features of Paragonimiasis skrjabini in Three Gorges Reservoir Region." *Parasitology international* 61(4): 645-649.
107. Nagayasu, E., et al. (2015). "Paragonimiasis in Japan: a twelve-year retrospective case review (2001-2012)." *Internal Medicine* 54(2): 179-186.
108. Odermatt, P., et al. (2007). "Paragonimiasis and its intermediate hosts in a transmission focus in Lao People's Democratic Republic." *Acta Tropica* 103(2): 108-115.
109. Jin, Y., et al. (2017). "Significance of serology by multi-antigen ELISA for tissue helminthiasis in Korea." *Journal of Korean Medical Science* 32(7): 1118.
110. Belizario, V., et al. (2016). "A model for integrating paragonimiasis surveillance and control with tuberculosis control program." *Southeast Asian J Trop Med Public Health* 47(4): 625-637.
111. Pacific, W. H. O. R. O. f. t. W. (2008). WHO standard acupuncture point locations in the Western Pacific Region, World Health Organization.
112. Organization, W. H. (2011). Report of the WHO expert consultation on foodborne trematode infections and taeniasis, World Health Organization.
113. Organization, W. H. (2002). Joint WHO/FAO Workshop on Foodborne Trematode Infection in Asia, Ha Noi, Viet Nam, 26-28 November 2002: report, WHO Regional Office for the Western Pacific.