

Case report

Flexor tendon sheath ganglion of the A1 pulley causing trigger thumb: A Case report.

Abstract

Ganglion as a cause of Trigger Thumb is rarely described and to the best of our knowledge this is the second case report in English literature(1). We present the case of a 34-year-old lady who presented with triggering of the right thumb. During the surgical exploration a 4x2mm ganglion was excised, which relieved the symptoms of triggering .

Introduction

Stenosing tenosynovitis is a common cause of hand disability(2). Bimodal distribution is observed with peaks observed in the 1st decade and in the 5th and 6th decades of life. It has a prevalence of 2-3% in the adult population(3-4). Higher prevalence is seen in patients with diabetes mellitus, other endocrine disorders and inflammatory arthropathies(5).

Critical review of literature suggest that ganglion cysts flexor synovial sheath is uncommon cause of triggering. Ganglion cysts around the hand and wrist comprise about 60% of all hand tumors of which 5-16% occur along the flexor tendon sheaths (6-7). Ganglion cyst of A1 pulley resulting in triggering of thumb is highly uncommon and this is only the second reported case in English literature.

Case Report

A 34-year-old female-stay at home mother presented to the out-patient department with complaints of pain at palmar aspect of base of right thumb and triggering for 3 months. Triggering was also elicited on clinical examination. A small firm non-tender swelling was palpable at the level of thumb flexion crease. It was not moving with tendon excursion. Patient was advised an ultrasound/Magnetic resonance Imaging but was declined by the patient. Patient had declined aspiration as well. She denied a traumatic event or similar swellings on contralateral side. Patient was agreeable for surgical excision. Following routine pre-anesthetic check and investigations patient was taken up for surgery.

At the thumb flexion crease local anesthetic infiltration was given and under loupe magnification transverse incision at the thumb flexion crease was used. A 1x1cm swelling was noted at the A1 pulley of the thumb and dissected out with care being taken to preserve the digital neurovascular

bundle. Swelling was excised with surrounding portion of A1 pulley and sent for histopathological examination. Patient was relieved of triggering symptom. Patient was placed in a well-padded bulky dressing. Sutures were removed at 3 weeks and patient was seen at 3 months and 1 year following surgery. Patient had no recurrence noted at 1 year follow-up.

Discussion

Ganglions are common hand tumors and account for about 50-70% of all upper limb swellings and a leading cause for the significant loss of normal hand function. The etiology of flexor sheath ganglions is still an enigma(7). A higher prevalence is noted in females(8). There are several hypotheses regarding the formation of these cysts including myxoid degeneration, increased production of hyaluronic acid and nonspecific proliferation of mesenchymal cells(8). Doyle proposed possibility of tear in the synovial membrane and subsequent healing with an extracapsular segment of synovium that secretes synovial fluid(6). Nelson et al proposed a post traumatic etiology(9,10). In our patient no specific etiology could be attributed and presumably it was degenerative in origin.

A variety of treatment modalities exist for treatment of flexor sheath ganglion from manual compression(11) to ultrasound guided aspiration with or without steroid injection(11). The disadvantage of steroid injection is high risk of recurrence and digital nerve injury. Surgical excision is the preferred mode of treatment as it avoids the pitfalls of aspiration and injection. Surgical excision of the cyst is combined with excision of a small portion of the pulley to prevent recurrence and enhance patient satisfaction.

Conclusion

Trigger finger and ganglion cysts of the flexor sheath are both common conditions, but their simultaneous occurrence is infrequent. Clinicians must devote careful attention to the diagnosis and open surgical excision of the A1 pulley ganglion under magnification to reduce the risk of neurovascular injury and recurrence.

References

1. Altaf W, Attarde D, Sancheti P, Shyam A. Triggering of Thumb by a Ganglion Cyst of the Flexor Tendon Sheath at A1 Pulley: A Case Report. *Journal of Orthopaedic Case Reports* 2021 March;11(3): 10-12.
2. Gil JA, Hresko AM, Weiss AC. Current Concepts in the Management of Trigger Finger in Adults. *J Am Acad Orthop Surg*. 2020 Aug 1;28(15):e642-e650. doi: 10.5435/JAAOS-D-19-00614. PMID: 32732655.
3. David M, Rangaraju M, Raine A: Acquired triggering of the fingers and thumb in adults. *BMJ* 2017;359:j5285.
4. Lunsford D, Valdes K, Hengy S: Conservative management of trigger finger: A systematic review. *J Hand Ther* 2019;32:212-221.
5. Kuczarski AS, Harris AP, Gil JA, Weiss APC: Management of diabetic trigger finger. *J Hand Surg Am* 2019;44:152-153.
6. Gunaseelan P, Jeremy P, Chua CK, Rashdeen F. Ganglion of the Flexor Tendon Sheath at the A2 Pulley - Case Report. *Malays Orthop J*. 2015 Mar;9(1):28-29. doi: 10.5704/MOJ.1503.002. PMID: 28435592; PMCID: PMC5349344.
7. Abe Y, Watson HK, Renaud S. Flexor tendon sheath ganglion: analysis of 128 cases. *Hand Surg*. 2004 Jul;9(1):1-4. doi: 10.1142/s0218810404001930. PMID: 15368618.
8. Jung, Kyu & Choi, Hwanjun & Kim, Jun. (2014). Ganglion of the Flexor Tendon Sheath between A1 Pulley and A2 Pulley. *Archives of Hand and Microsurgery*. 23. 29-32. 10.15596/ARMS.2014.23.1.29.

9. Nelson CL, Sawmiller S, Phalen GS. Ganglions of the wrist and hand. *J Bone Joint Surg Am* 1972;54:1459-64.
10. Al-Khawashki H, Hooper G. The distribution of fibrous flexor sheath ganglions. *J Hand Surg Br* 1997;22:226-7
11. Hvid-Hanson O. On the treatment of ganglia. *Acta Chir Scand* 1970; 136: 471-6.

UNDER PEER REVIEW

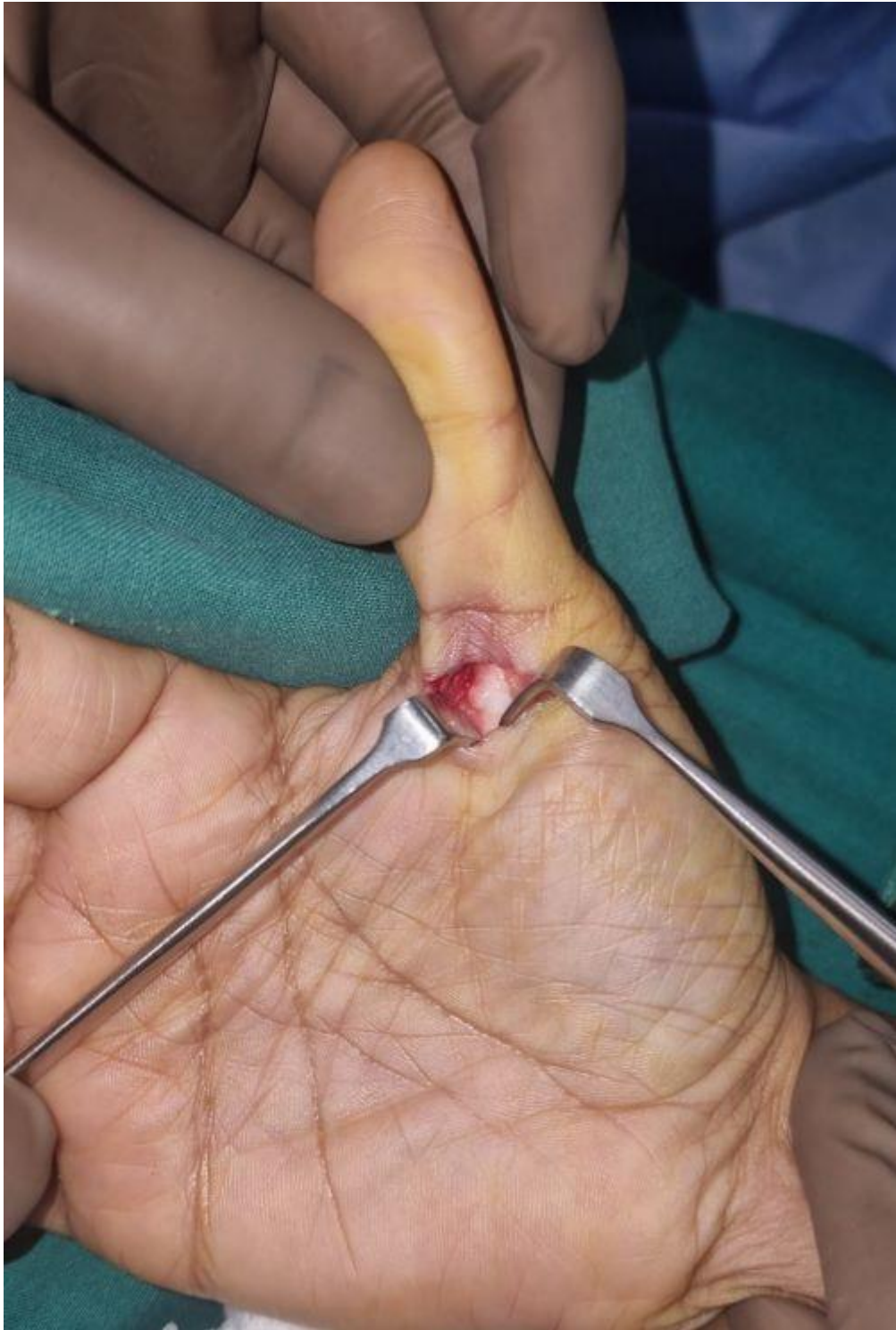

Fig 1. Transverse incision at the thumb flexion crease. Neurovascular bundles dissected and retracted. Ganglion noted over the A1 pulley of thumb flexor sheath.




Fig 2. The 4x2mm Cyst, filled with Gelatinous fluid .

UNDER PEER REVIEW