

*Retrospective Evaluation of Primary Bone Tumors and their incidence in the "Ignacio García Téllez"  
Specialty Hospital CMN IMSS*

**Abstract**

In 1948, Steiner conducted an analysis of cancer registries in the United States of America, estimating that primary bone tumors constituted approximately 1% of all fetal malignancies. For its part, in Great Britain, a similar incidence of primary bone tumors is observed, fluctuating between 0.8% and 0.9%. A later statistic from the United States at a rate of 1.87:1000 000 deaths among children under 14 years of age, increasing to 11.97:1000 000 deaths in people aged 11 to 19 years. Since all bone components are derived from the mesoderm, they have the potential to be composed of any of the four basic types of cells: fibroblasts, chondroblasts, osteoblasts and the reticulo-myelogenous series, to achieve a correct diagnosis it is necessary to have the complementary radiological and pathological support to part of biochemical and hematological investigations. The present investigation focused on a retrospective, observational, quantitative, risk-free study, based on the review of records and tracking of histological reports of patients who were treated at the "Ignacio García Téllez" CMN IMSS Specialty Hospital in a period of 5 years, including all those cases with primary tumors of bone or cartilage origin, both benign and malignant of bone marrow and vascular, in addition to pseudotumor lesions such as fibrous dysplasia, metaphyseal fibrous defect, solitary bone cyst.

**Keywords:** osteoma, osteochondroma, fibrous dysplasia, sarcoma, Ewing, Giant cell tumors

**Introduction**

In 1948, Steiner conducted an analysis of cancer registries in the United States of America, estimating that primary bone tumors constituted approximately 1% of all fetal malignancies. For its part, in Great Britain, a similar incidence of primary bone tumors is observed, fluctuating between 0.8% and 0.9%. A later statistic from the United States at a rate of 1.87:1000 000 deaths among children under 14 years of age, increasing to 11.97:1000 000 deaths in people aged 11 to 19 years. From another perspective, in Germany the existence of primary tumors was recorded with a population of approximately 17 million, this being a more exact figure because notification of all malignant tumors is mandatory, registering an approximate of 4987 primary bone tumors in 2000<sup>1</sup>.

Since all components of bone are derived from mesoderm, they have the potential to be composed of any of the four basic cell types: fibroblasts, chondroblasts, osteoblasts, and the reticulomyelogenous series. Having the possibility of developing pathologies such as:

**Osteoma:** a benign lesion characterized by mature and well-differentiated bone tissue, has three different types: conventional, juxtacortical and medullary. Radiographically, it manifests as a dense and radiopaque bone mass, generally without defined structure, with often lobulated edges, and is usually less than 3 cm in diameter. Histopathologically, compact cortical bone is observed with narrow intertrabecular marrow spaces occupied by active or adipose marrow, without osteoblastic or osteoclastic activity<sup>2</sup>.

**Osteochondroma:** is characterized by a bony projection with a cartilage cap that protrudes from the surface of the affected bone. Although it may not be a true neoplasm, but rather a developmental disorder, it is the most common benign bone tumor in adolescents and children. A theory is suggested that postulates that exostoses are produced by small nests of cartilage derived from the periosteal cambium layer<sup>3</sup>.

**Fibrous dysplasia:** A disorder that primarily affects bone, sometimes accompanied by skeletal abnormalities. Classified into three groups: monostotic, polyostotic and polyostotic with endocrine abnormalities, it occurs more frequently in women. The monostotic type mainly affects the femur, tibia, rib or facial bone, while the polyostotic type shows segmental preference in the bones of an extremity, particularly affecting the femur, tibia, fibula, some bones of the foot and part of the iliacus<sup>4</sup>.

**Aneurysmal bone cyst:** a solitary bone tumor, characterized by radiolucency with a soap bubble appearance. Its etiology is not completely known, but it is believed to be related to local circulatory disorders. Histologically, it presents a thin-walled distended cyst containing a network of trabecular spaces. It is frequently located in the spine and long bones<sup>5</sup>.

**Ewing's sarcoma:** a rare primary malignant bone tumor, it is the second most common in children, with a predilection in ages 10 to 15 years. It is located mainly in the iliac, femur, humerus, fibula or tibia. The prognosis is unfavorable, as it tends to soon develop metastases to the lungs, lymph nodes and other bones. It is radiosensitive and the preferred treatment is radiotherapy<sup>6</sup>.

**Giant cell tumor:** An aggressive tumor, it is characterized by highly vascularized tissue and evenly distributed osteoclastic giant cells. Its radiographic appearance shows a radiolucent expansive zone located eccentrically at the external epiphyseal end<sup>7</sup>.

The correct diagnosis of these nosological entities must be carried out through radiological and pathological support, complemented, if necessary, with biochemical and hematological investigations. So far, these methods play a limited role in the diagnosis of most bone tumors and should not be considered essential sources of information. From a radiographic perspective, it is crucial for the diagnosis that the pathologist always has the relevant radiographs before making a definitive diagnosis. Likewise, it is essential to provide the pathologist with detailed clinical information. In addition to x-rays, other imaging modalities should be included, such as CT scans, angiograms, and CT scans. Bone scintigraphy and biopsy are also valuable tools in this process.

## Materials and methods

Retrospective, observational, quantitative, risk-free study, based on the review of records and tracking of histological reports of patients who were retreated at the "Ignacio García Téllez" CMN IMSS Specialty Hospital in a period of 5 years, including all those cases with primary tumors of bone or cartilage origin, both benign and malignant, bone marrow and vascular, as well as pseudotumoral lesions such as fibrous dysplasia, metaphyseal fibrous defect, solitary bone cyst.

Inclusion criteria: records with primary bone tumor, without distinction of sex and the age of the patient is not taken into account as they are also referred from the Gynecology-Obstetrics and Pediatrics Hospital No. 48.

## Results

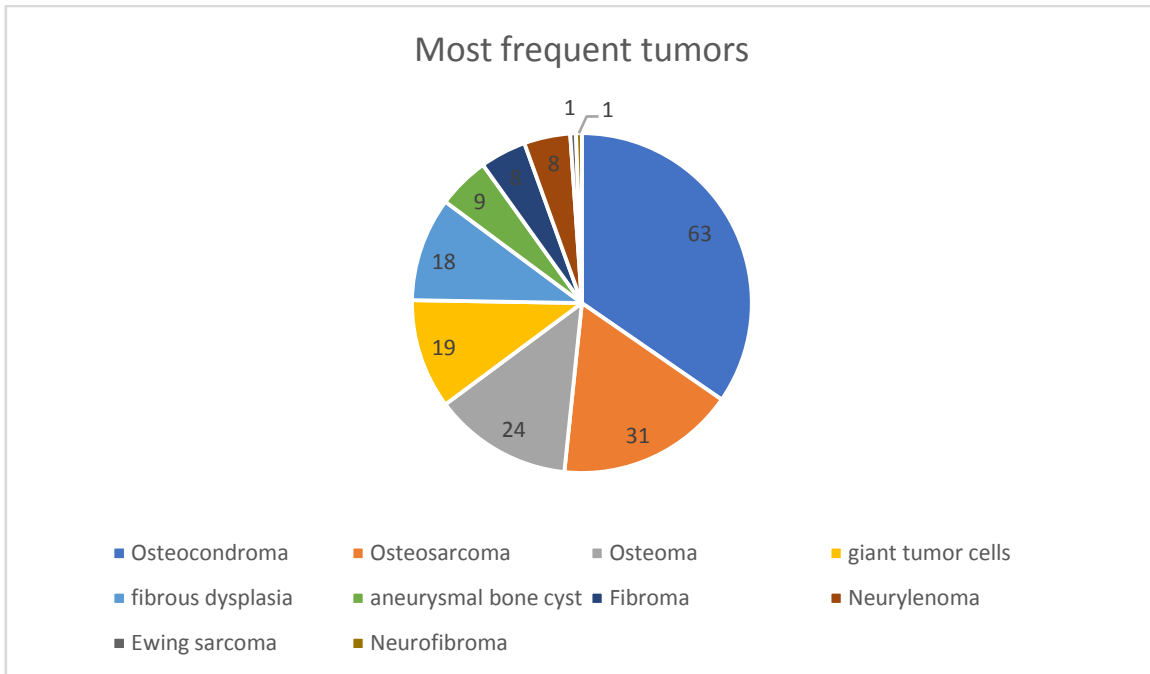
A total of 182 histological records and reports were recorded in a period of 5 years where a total of 93 women and 89 men were recorded, with ages ranging from 3 months of extrauterine life to 87 years. 129 benign tumors were reported in 63 men and 66 women; Meanwhile, a total of 53 malignancies were counted in 26 men and 27 women. Graph 1.

The most frequently reported neoplasms were osteochondroma in 63 patients, of which 33 were men and 30 women, with conditions found in the distal metaphysis of the femur, followed less frequently in the humerus, tibia, fibula and fingers of the hand. It is noteworthy that these second neoplasms found correspond to osteogenic sarcoma, with 31 patients, 16 men and 15 women, again with a clear predominance of the distal metaphysis of the femur, in the proximal tibia, scapular, ribs, fibula and humerus. Graph 2.

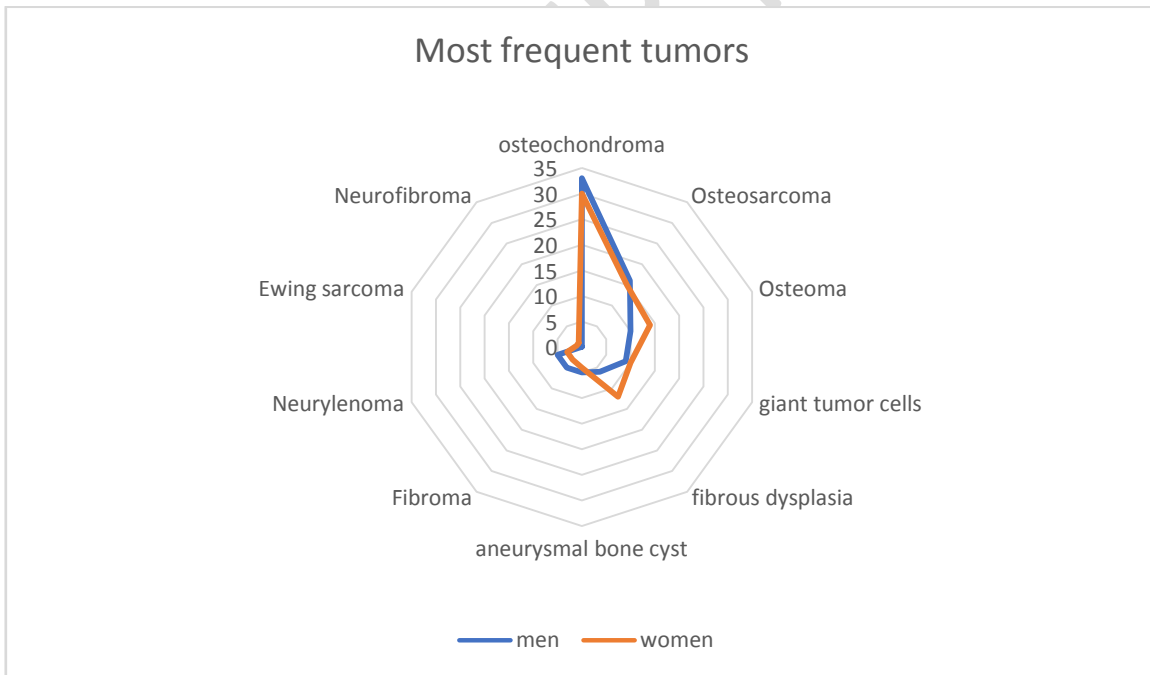
Thirdly, we found osteoma with 24 cases of which 14 were women and 10 men; This tumor is followed in frequency by giant cell tumor with 19 cases, 10 being women and 9 men; fifthly, fibrous dysplasia with 18 cases, its most frequent location being in the maxilla; In sixth place is the aneurysmal bone cyst with 9 cases reported, followed by fibroma and neurofibroma with 8 cases each.

Finally, the least common tumors are Ewing's sarcoma, recorded in a single case in a 20-year-old patient at the level of the right radius, and neurofibroma in a single case, also in a 27-year-old female at the level of the right scapula.

Likewise, the various pathologies are expressed in relation to the side of the body where they occurred most frequently. Table 1-10.



Graph 1: total de pacientes reportados en consulta con diversas patologías de tumores óseos primarios.



Graph 2: frecuencia de casos reportados de tumores óseos primarios en relación al sexo.

Anatomical frequency of osteochondroma		
anatomical zone	Right	left
Scapula	0	2
Humerus	7	4

Rib	1	0
Ulna	2	1
Metacarpal	4	1
Phalanx	2	0
Femur	4	19
Tibia	5	5
Fibula	2	2
Foot	2	0

Table 1: Anatomical frequency of osteochondroma in the femur left.

Frequency anatomy of osteosarcoma		
anatomical zone	Right	left
Scapula	1	2
Humerus	2	2
Rib	1	0
Femur	9	5
Tibia	0	7
Fibula	1	1

Table 2: Frequency anatomy of osteosarcoma in the femur right.

Osteoma anatomy frequency		
anatomical zone	Right	left
Maxillary	4	0
Skull	9	1
Metacarpal	1	0
Femur	4	5
Phalanx	0	1
Tibia	0	1
Foot	2	1

Table 3: Osteoma anatomy frequency in the skull right.

Frequency anatomy of giant cell tumor		
anatomical zone	Right	left
Maxillary	2	0
Radio	1	1
Ulna	1	0
Phalanx	3	0
Femur	5	2
Tibia	1	1
Fibula	2	0

Table 4: Frequency anatomy of giant cell tumor in the femur right.

Frequency anatomy of fibrous dysplasia		
anatomical zone	Right	left
Maxillary	7	0
Skull	3	1
Humerus	4	0
Metacarpal	1	0

Fibula	0	2
--------	---	---

Table 5: Frequency anatomy of fibrous dysplasia in the maxillary right.

Anatomy frequency of aneurysmal bone cyst		
anatomical zone	Right	left
Clavicle	1	1
Humerus	2	1
Femur	1	1
Tibia	0	1
Radio	0	1

Table 6: Anatomy frequency of aneurysmal bone cyst in the humerus right.

Anatomical frequency of fibroma		
anatomical zone	Right	left
Maxillary	2	0
Humerus	1	0
Metacarpal	1	0
Tibia	2	0
Fibula	1	0
Foot	0	1

Table 7: Anatomical frequency of fibroma in the maxillary and tibia right.

Frequency anatomy of neurileoma		
anatomical zone	Right	left
Maxillary	1	0
Scapula	1	0
Skull	1	0
Femur	1	3
Foot	1	0

Table 8: Frequency anatomy of neurileoma in the femur left.

Frequency anatomy of Ewing sarcoma		
anatomical zone	Right	left
Radio	1	0

Table 9: Frequency anatomy of Ewing sarcoma in the right radio.

Frequency anatomy of neurofibroma		
anatomical zone	Right	left
Scapula	1	0

Table 10: frequency anatomy of neurofibroma in the right scapula.

## Discussion

The number of patients evaluated in the present study is 182, with a slight predominance in women compared to men, highlighting the importance of a timely diagnosis through the use of an appropriate methodology to improve patient management.

Focusing on the tumors identified, we noted a significant frequency of osteogenic sarcoma in our series, with 31 patients and a slight predominance in men. The most frequent location of these sarcomas is in the distal metaphysis of the femur, affecting 14 of the 31 patients. This finding highlights the relevance of early identification and management of these injuries.

## Conclusion

The current study facilitates the evaluation of the most common neoplasms in our environment, with the aim of raising awareness about the importance of having adequate resources to develop a timely diagnosis and treatment plan for the benefit of patients.

Likewise, it seeks to encourage interest in continuing the follow-up of patients from this date, with the purpose of obtaining a deeper knowledge about the final evolution. This will allow the generation of significant statistics related to the treatment offered to patients with primary bone tumors. Collecting this data will help improve understanding of therapeutic options and optimize medical care in similar cases in the future.

## References :

1. Gutiérrez DÁ, Manzotti C, Gallardo-Rodríguez KM, Rodríguez-Caulo AP, Gutiérrez-Cierco JL, Gutiérrez-DI, Villar-Rodríguez JL. Gastric carcinoma with lymphoid stroma: 3 clinicopathological entities. *Spanish Journal of Pathology*. 2017;50(3):167-173.
2. Tepelenis K, Skandalakis GP, Papathanakos G, Kefala MA, Kitsouli A, Barbouti A, Tepelenis N, Varvarousis D, Vlachos K, Kanavaros P, Kitsoulis P. Osteoid Osteoma: An updated review of epidemiology, Pathogenesis, clinical presentation, radiological features, and treatment options. *In vivo*. 2021;35(1):1929-1938.
3. Morales VY, Viera LL, Betancourt LE. Cervical osteochondroma. Case report. *Medical record of the center*. 2023;17(4):791-797.
4. Castro CJ, Villa-Fernández JM, Agulleiro-Díaz JP. Craniofacial fibrous dysplasia and aneurysmal bone cyst in a patient with McCune-Albright syndrome. *Neurosurgery*. 2023;34(5):268-272.
5. Ortega SD, Hidalgo RA, Droguett OD, Celis CC. Clinic, epidemiology and imaging of aneurysmal bone cyst in the craniofacial territory, analysis of its histopathological patterns: narrative review. *Av Odontostomatol*. 2023;39(1):24-35.
6. Sbaraglia M, Righi A, Dei Tos AP. Ewing Sarcoma and Ewing-like tumors. *Virchows archive*. 2020;476:109-119.
7. Villarreal HE, Jaramillo-Becerra CA, Machado-DG, Encalada-Espinoza MD, Jiménez BP. Giant cell tumor with aggressive behavior case report and review of the literature. *Medical records*. 2023;33(1):66-72.