

Serous Cystadenoma at Tail of Pancreas : A Case Report

Abstract

Pancreatic serous cystadenoma is an infrequent, non-cancerous tumor occurring in the pancreas, typically found in isolation within the body or tail of the organ and potentially linked to Van-Hippel-Lindau syndrome. The size of these cystadenomas can range from 1 cm to 20 cm, displaying a smooth outer surface and containing one or more thin-walled cysts filled with clear, watery serous fluid. They often present as either unilocular or multilocular structures and are commonly discovered incidentally, exhibiting no symptoms. With an excellent prognosis, pancreatic serous cystadenomas are benign growths more frequently identified in individuals aged 40-50.

We are presenting a rare case involving a 40-year-old female who experienced abdominal pain and a palpable lump in the left upper quadrant of the abdomen. The diagnosis was confirmed through a CT scan of the abdomen, revealing a pancreatic serous cystadenoma. The recommended course of action involved a complete surgical excision of the tumor located in the tail of pancreas with surgical excision being the preferred treatment for this condition.

Key words

Serous cystadenoma, microcystic, macrocystic, pancreas

Introduction

Pancreatic serous cystadenomas are predominantly benign lesions, often incidentally discovered and usually asymptomatic. Comprising 1%-2% of all pancreatic neoplasms, they can be microcystic or macrocystic and are more prevalent in women (3:1 ratio). Typically, patients present between their 5th and 7th decades, with lesions more frequently occurring in the body and tail of the pancreas, often associated with 77% of cases involving Van-Hippel-Lindau syndrome. The most common symptoms include abdominal pain and a palpable abdominal mass. However, a significant proportion of cases remain asymptomatic and are identified incidentally. [1,2,4]

Radiologically, typical cases display a polycystic honeycomb appearance of the tumor mass. Grossly, the majority of pancreatic serous cystadenomas are well-defined, with a cut surface revealing numerous small cystic spaces filled with clear serous fluid (microcystic), lined by flattened or cuboidal epithelium. Sizes can range from 1 cm to over 20 cm, and they do not communicate with the pancreatic duct. [2,3,4]

The use of imaging modalities such as ultrasonography, CT, MRI, and endoscopic ultrasound (EUS) has significantly improved diagnostic accuracy. Surgical approaches depend on the location and may involve distal pancreatectomy with or without splenectomy procedures, with an emphasis on preserving endocrine and exocrine pancreatic function. Generally, pancreatic serous cystadenomas are benign tumours with an excellent prognosis. [2,4,6,9]

Case Report

On September 1, 2009, a 40-year-old female was admitted to our centre, presenting with epigastric abdominal pain and a palpable lump in the left upper quadrant. Physical examination revealed a lump in the left hypochondrium. The spleen was not palpable. A CT abdomen scan indicated a cystic, hypodense swelling with honeycomb appearance measuring 4x5 cm with well-

defined margins at the tail of pancreas. Preoperative serum carcinoembryonic antigen (CEA) levels were within normal limits, and all other laboratory blood investigations were normal.

Under general anaesthesia, a complete surgical resection of the tail pancreatic tumor was performed while preserving the spleen. The tumor was easily separated from the pancreatic tail with no injury to the pancreatic tissue, and the cyst was not communicative with the pancreatic duct. Grossly, the cyst measured 4x5 cm, had well-defined capsules, and was well-circumscribed. The cut surface revealed numerous small cystic spaces filled with clear, whitish-yellow serous fluid.

Microscopically, the cystic spaces were lined by a single layer of cuboidal epithelial cells with a moderate amount of clear to faintly eosinophilic cytoplasm. The nuclei of the epithelial cells were uniform and centrally placed. The post-operative recovery was uneventful, and the patient was discharged on the 10th postoperative day. Over the course of a 10-year follow-up, there was no recurrence, and the patient remains in good health. (Fig 1-8)

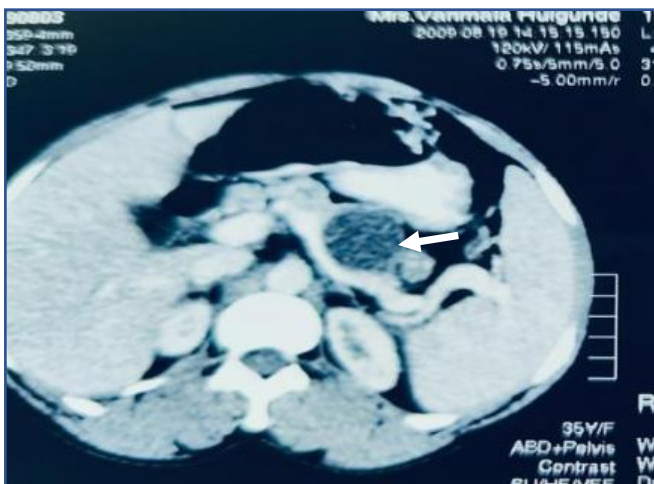


Fig-1 CT abdomen showed well defined, hypodense and honeycomb cystic mass at tail of pancreas

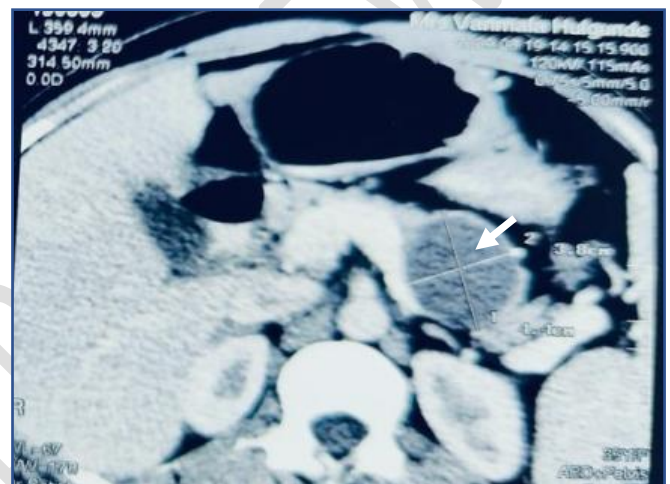


Fig-2 CT abdomen showed honeycomb cystic mass measuring 4x5 cm

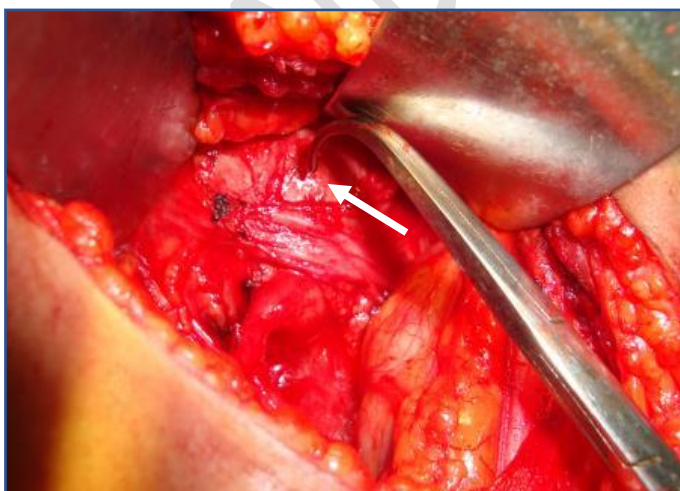


Fig-3 Intra operative photographs showing cystic lesion

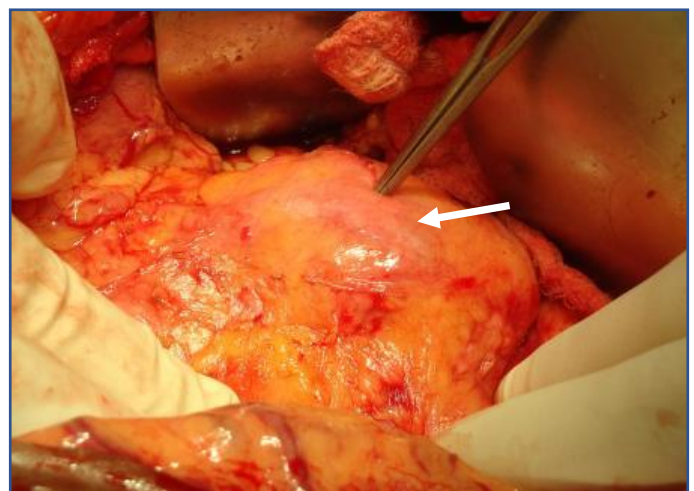


Fig-4 Intra operative photographs showing cystic lesion

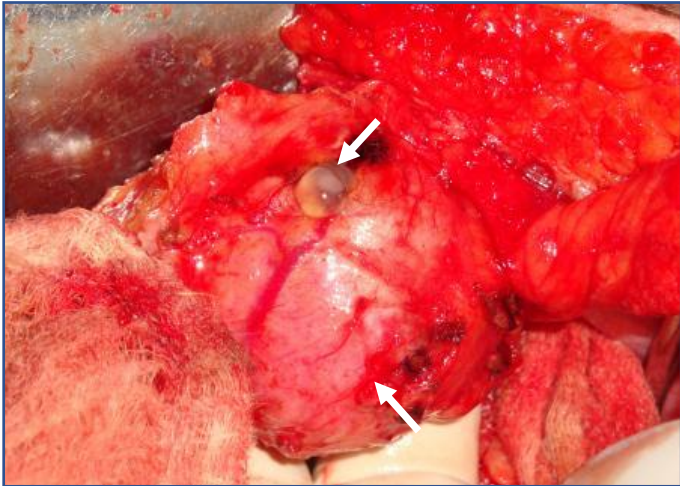


Fig-5 Intra operative photographs showing yellowish serous fluid from well defined cystic mass

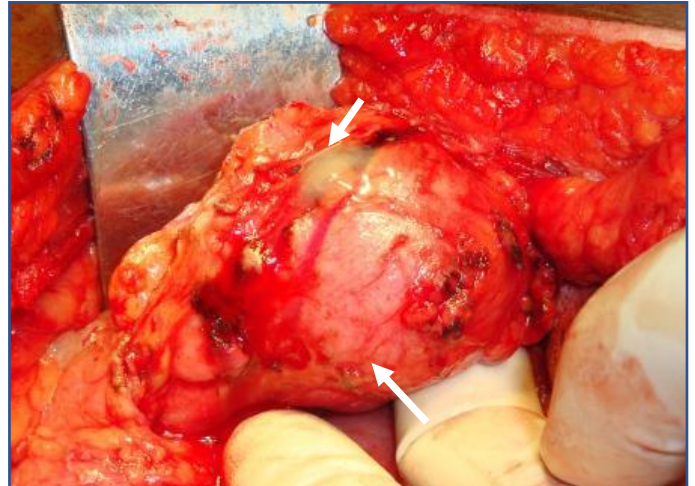


Fig-6 Intra operative photographs showing cystic lesion at tail of pancreas measuring 4x5 cm

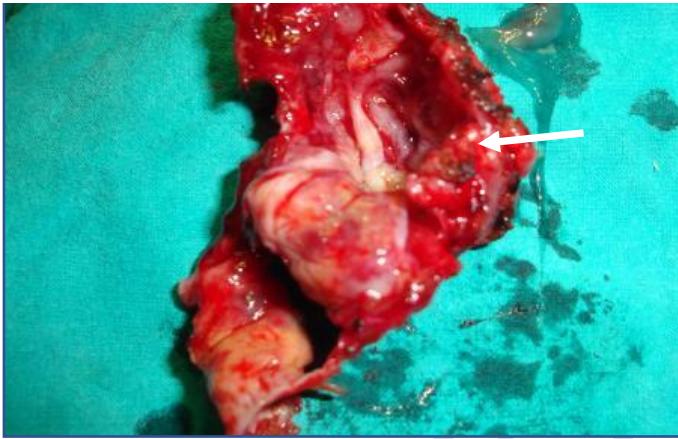

Fig-7 photographs showing gross specimen of serous pancreatic cyst

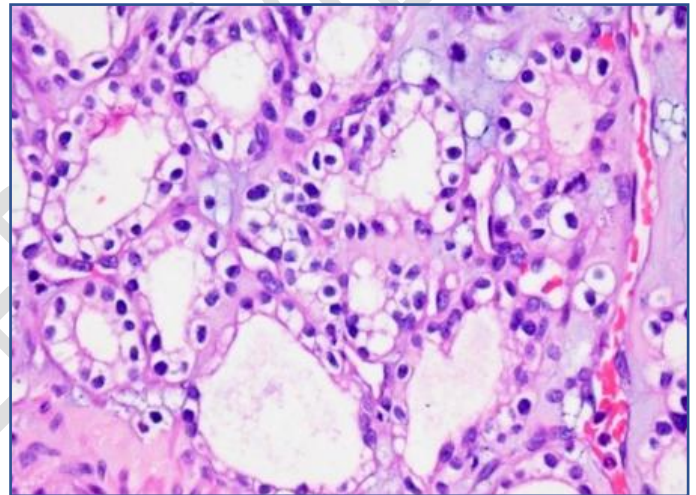


Fig-8 Histopathology photographs showing cuboidal epithelium with round nuclei and clear eosinophilic cytoplasm. (Benign serous cystadenoma)

Discussion

Pancreatic serous cystadenomas are benign exocrine pancreatic neoplasms with a favourable prognosis, with females being three times more commonly affected than males in a ratio of 3:1. These tumours can manifest with symptoms such as abdominal pain, palpable mass, vomiting, weight loss, and occasionally jaundice, particularly in cases involving the head of the pancreas leading to common bile duct occlusion. However, nearly 50% of cases are incidentally detected during radiological examinations. Pancreatic lesions are observed in 25-70% of individuals with Von Hippel-Lindau (VHL) syndrome. [2,3,4]

According to the World Health Organization classification, pancreatic serous cystadenomas can be categorized as follows: [4,5,6,7]

1. Microcystic serous cystadenoma: A benign epithelial neoplasm composed of cuboidal cells forming numerous small cysts containing serous fluid, exhibiting a honeycomb appearance. Often associated with Von Hippel-Lindau syndrome.
2. Macrocytic serous cystadenoma: Characterized by larger, less well-defined cysts that are fewer in number.
3. Solid serous cystadenoma: These neoplasms consist of two components, well-differentiated pancreatic endocrine neoplasms, and serous cystadenomas.
4. Von Hippel-Lindau syndrome-associated serous cystadenoma: Involves the entire pancreas in a patchy fashion.
5. Mixed serous neuroendocrine neoplasm: A rare entity of serous cystadenoma.

Imaging modalities aid in diagnosing pancreatic serous cystadenomas:

1. Ultrasound: Typically presents as a well-circumscribed, lobulated lesion with hypoechoic cystic portions and a honeycomb appearance due to multiple microcysts.
2. CT findings: Show a well-circumscribed mass with a honeycomb or sponge pattern, and a central scar may be present in up to 30% of cases, forming a "sunburst" pattern.
3. MRI: More sensitive in detecting fluid compared to CT imaging, especially in cases with microcysts.
4. Endoscopic ultrasound (EUS): Allows for accurate diagnosis through EUS-guided fine-needle aspiration cytology studies.
5. Tumor markers: Levels of carcinoembryonic antigen (CEA) and carbohydrate antigen (CA 19-9) are typically low. [2,3,4,8]

Treatment

The choice of surgical approach is contingent on the tumour's location and may involve procedures such as distal pancreatectomy with or without splenectomy, middle pancreatectomy, Whipple's procedure, or enucleation. Enucleation has been previously reported as a safe option for serous cystadenoma, aiming to preserve the endocrine and exocrine pancreatic function. Patients with serous cystadenoma exhibit an excellent prognosis, with long-term survival expected after surgical resection, necessitating regular follow-up.

Pancreatic serous cystadenomas are characterized by their slow growth and benign nature, resulting in an outstanding prognosis. The honeycomb pattern, observed in 20% of cases, manifests as numerous tiny cysts resembling a honeycomb or sponge. Approximately 40% of these cystadenomas originate from the pancreatic head and uncinate process, while 60% arise from the body and tail of the pancreas.

Conclusion

Pancreatic serous cystadenoma is an uncommon epithelial neoplasm, primarily found in the body and tail of the pancreas, typically affecting elderly females and associated with an excellent prognosis. The preferred diagnostic imaging modality is CT, serving as the initial choice. Complete surgical resection proves to be curative in all instances of pancreatic serous cystadenoma.

Ethical Approval:

As per international standards or university standards written ethical approval has been collected and preserved by the author(s).

Consent

As per international standards or university standards, patient(s) written consent has been collected and preserved by the author(s).

References

1. Nakamura, S., Murata, Y., Uchida, K. et al. Microcystic serous cystadenoma mimicking pancreatic neuroendocrine neoplasm: report of a resected case with preoperative diagnostic difficulty and review of the literature. *surg case rep* 8, 188 (2022). <https://doi.org/10.1186/s40792-022-01544-0>
2. Tariq MU, Ahmad Z, Abdul-Ghafar J, Din NU. Serous cystadenoma of pancreas: A clinicopathologic experience of 23 cases from a major tertiary care center. *Rare Tumors*. 2018 Nov 5;10:2036361318809183. doi: 10.1177/2036361318809183. PMID: 30542522; PMCID: PMC6236590.
3. Tseng JF, Warshaw AL, Sahani DV, Lauwers GY, Rattner DW, Fernandez-del Castillo C. Serous cystadenoma of the pancreas: tumor growth rates and recommendations for treatment. *Ann Surg*. 2005 Sep;242(3):413-9; discussion 419-21. doi: 10.1097/01.sla.0000179651.21193.2c. PMID: 16135927; PMCID: PMC1357749
4. L.C. Chu, A.D. Singhi, R.R. Haroun, R.H. Hruban, E.K. Fishman, The many faces of pancreatic serous cystadenoma: Radiologic and pathologic correlation, *Diagnostic and Interventional Imaging*, <https://doi.org/10.1016/j.diii.2016.08.005>.
5. Yang, J., Guo, X., Zhang, H. et al. Differential diagnosis of pancreatic serous cystadenoma and mucinous cystadenoma: utility of textural features in combination with morphological characteristics. *BMC Cancer* 19, 1223 (2019). <https://doi.org/10.1186/s12885-019-6421->
6. Timothy J. Van Dyke, Frederick C. Johlin, Andrew M. Bellizzi, James R. Howe; Serous Cystadenocarcinoma of the Pancreas: Clinical Features and Management of a Rare Tumor. *Dig Surg* 1 April 2016; 33 (3): 240–248. <https://doi.org/10.1159/000444721>
7. Tariq MU, Ahmad Z, Abdul-Ghafar J, Din NU. Serous cystadenoma of pancreas: A clinicopathologic experience of 23 cases from a major tertiary care center. *Rare Tumors*. 2018;10. doi:10.1177/2036361318809183

8. Gregory W. Charville, Chia-Sui Kao; Serous Neoplasms of the Pancreas: A Comprehensive Review. *Arch Pathol Lab Med* 1 September 2018; 142 (9): 1134–1140. doi: <https://doi.org/10.5858/arpa.2017->
9. Choi JY, Kim MJ, Lee JY, Lim JS, Chung JJ, Kim KW, et al. Typical and Atypical Manifestations of Serous Cystadenoma of the Pancreas: Imaging Findings with Pathologic Correlation. *AJR* 2009;193:136–42.
10. Chen H-Y, Deng X-Y, Pan Y, Chen J-Y, Liu Y-Y, Chen W-J, Yang H, Zheng Y, Yang Y-B, Liu C, Shao G-L and Yu R-S (2021) Pancreatic Serous Cystic Neoplasms and Mucinous Cystic Neoplasms: Differential Diagnosis by Combining Imaging Features and Enhanced CT Texture Analysis. *Front. Oncol.* 11:745001. doi: 10.3389/fonc.2021.745001

UNDER PEER REVIEW