

## Case report

### **Lower eyelid reconstruction using the Tenzel technique in a case of eyelid basal cell carcinoma**

#### **Abstract**

##### **Summary:**

The reconstruction of transfixing eyelid defects is subject to surgical requirements determined by the anatomical and functional particularities of the eyelids. In order to meet these requirements, numerous reconstruction processes are available, presenting their own objectives and particular constraints.

Among them, we sought to determine the place and reliability of the use of the TENZEL technique.

observation: this is a patient operated on in our training for left lower eyelid basal cell carcinoma and in whom a reconstruction was carried out using the Tenzel technique. A very good progress was noted in our patient without any notable complications. The functional and aesthetic results were satisfactory.

Conclusion: The blepharopoesis process using the TENZEL technique has many advantages. It is a simple, versatile technique, allowing extensive and complex eyelid reconstructions, in a single operating stage. This process is characterized by great reliability and allows good results to be obtained, both functional and aesthetic. The Tenzel technique represents a major tool in eyelid repair surgery.

**Keywords :** loss of substance, eyelid, BCC, Tenzelreconstruction

##### **Introduction :**

Basal cell carcinoma is the most common malignant eyelid tumor. The treatment is essentially surgical with the aim of oncological excision of the tumor followed by eyelid reconstruction allowing the restoration of eyelid function and obtaining a satisfactory aesthetic result.

“Although numerous procedures for reconstruction of periorbital defects have been proposed, no method is universally used” [1-10]. “A typical surgical plan involves simply covering the defect based on its location and size”. [18]

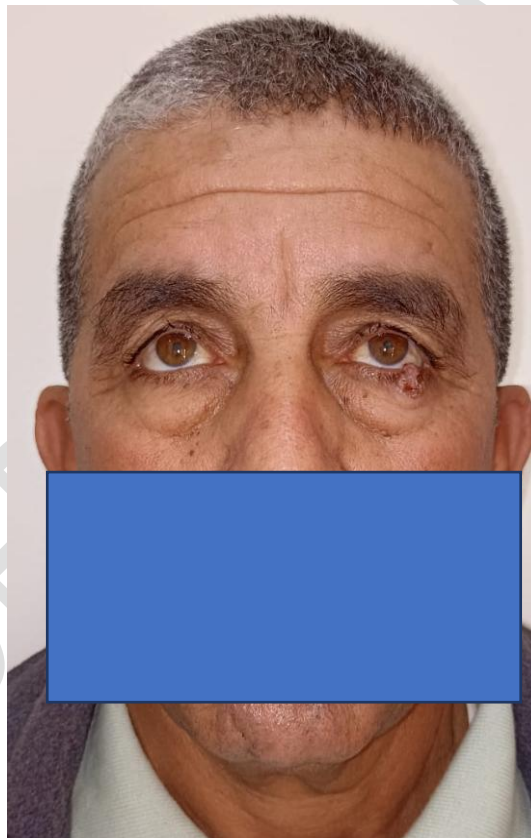
Since its introduction in 1975, the TENZEL technique has been well used in eyelid reconstructions when there are no specific contraindications to its use [11,12].

## Case presentation

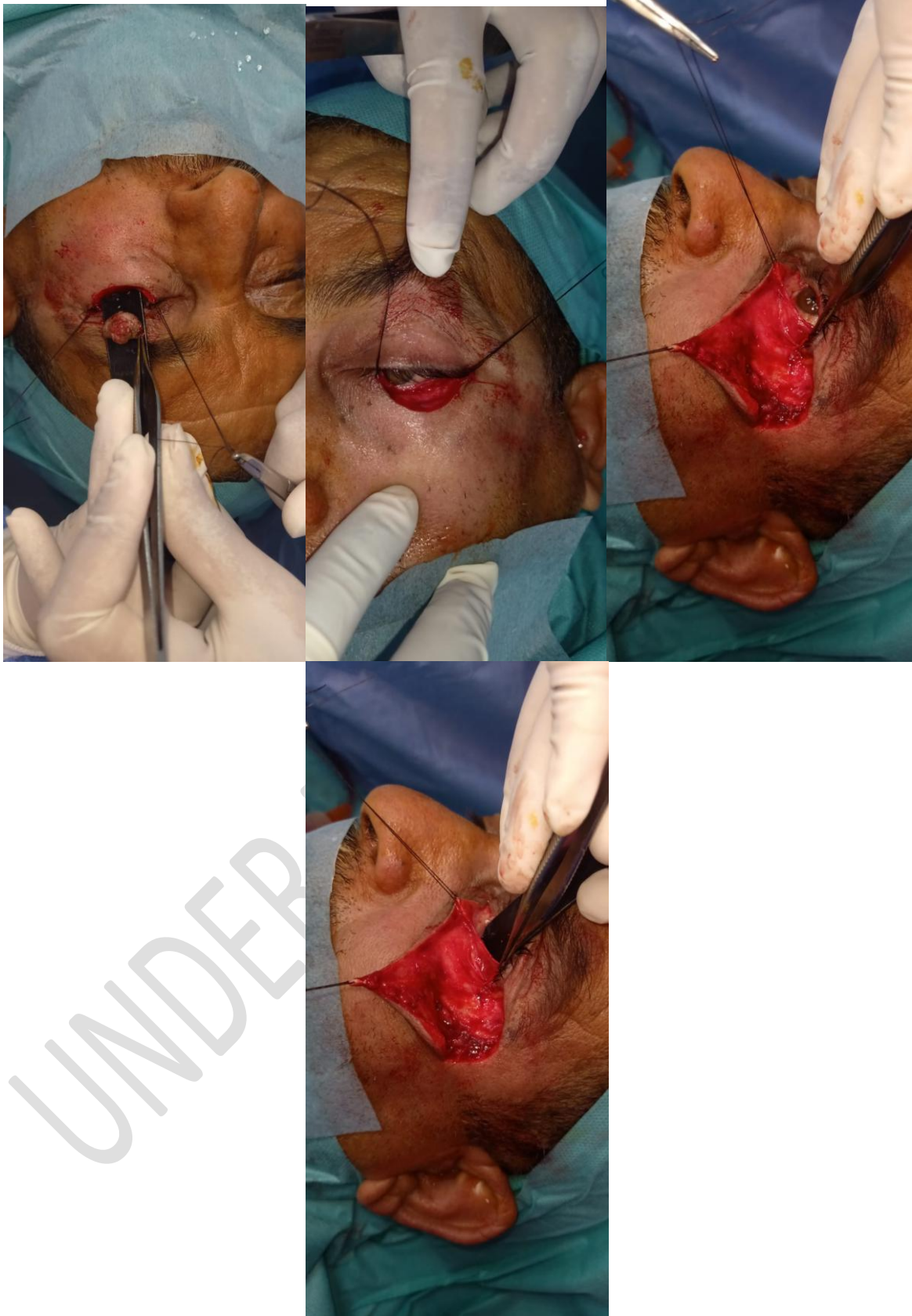We report the case of a 56-year-old man who presented with a one centimeter large diameter ulcerative-vegetative tumor, occupying the outer third of the lower left eyelid, bordered by a pearly collar and infiltrating the tarsal conjunctiva. We opted for a wide excision with eyelid reconstruction of the 2 planes: the tarsal plane by lifting the tarsal conjunctiva and the cutaneous plane by sliding flap according to the Tenzel technique in the same operating time.

The surgical specimen was sent to the anatomical pathology laboratory, anatomical pathological study came back positive with excision margins quite distant from the tumor. A lower eyelid suspension was performed in our patient. A favorable outcome during the dressing change, no postoperative complications were noted. Stitch removal was performed after 7 days.

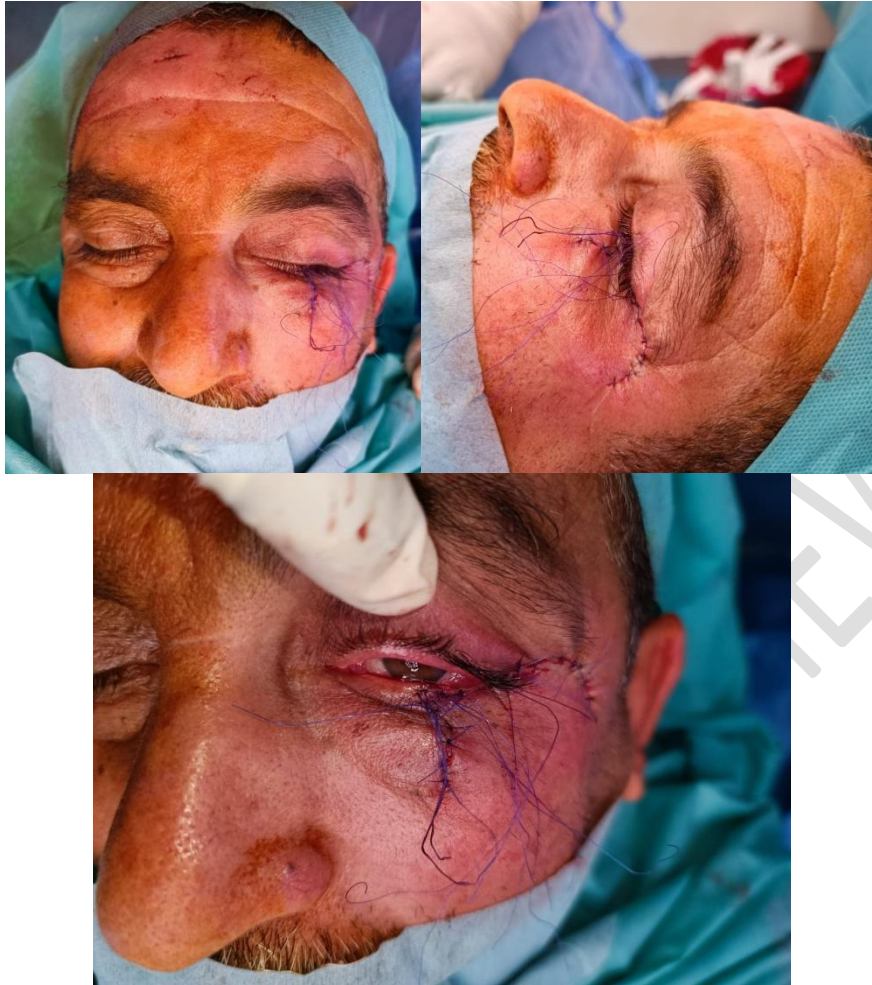The surgical result was judged satisfactory to excellent in our case from a functional and aesthetic point of view.



**Figure1:** image showing the left lower eyelid CBC



**Figure2:** excision of the eyelid CBC with removal of the TENZEL flap



**Figure3:** immediate postoperative photo showing the final result with the lower eyelid suspension thread



**Figure 4:** our patient one year after the surgical procedure showing an excellent morphological and functional result

#### **Discussion :**

The semicircle flap technique offers several distinct advantages. It is useful for reconstruction of the upper and lower eyelids. The reconstruction is performed in a single procedure without requiring closure of the eyelid fissure. Manipulation of the ipsilateral eyelid is avoided. Creating eyebrow, forehead, or cheek flaps is not necessary, nor is grafting tissue from distant sites such as nasal or ear cartilage, labial mucosa, or skin.

“The Tenzel flap, first described in 1975, is a lateral flap that is elevated and rotated to provide sufficient mobilization to repair periorbital deficiencies. Lower lid defects involving up to 60% of the lid can be closed using a Tenzel flap” [13]. “The Tenzel flap can be used to cover moderate-sized deficits in a single stage, simply and effectively, and it also has minimal donor site morbidity”. [18]

“Despite its advantages, the classic Tenzel procedure is not free from scar ectropion. Although the risk of developing ectropion of the lower eyelid after its reconstruction cannot be entirely eliminated, several techniques can help avoid causing this complication, in particular: the elevation of the flap occurs along the subcutaneous plane, because some evidence has suggested that ectropion may occur more often when using the deep plane after its reconstruction if necessary” [14,15,16,17]. Lower tension should be minimized by recruiting tissue into the lateral areas of the deficit, suspension sutures are used to anchor the flaps. Specifically, the flap is anchored to the periosteum, usually in the lateral border, so that all tension is distributed there.

“The Tenzel flap has been shown to have several advantages over traditional procedures. Its main advantages are its wide applicability, simplicity of the procedure, less visible scars and effective prevention of complications such as lower eyelid ectropion and distal flap necrosis”.<sup>[18]</sup>

### **Conclusion :**

The reconstruction of large upper eyelid defects can be accomplished by different methods, that of Tenzel is particularly suitable for the repair of a central eyelid defect with tarsus on both sides for better approximation. However, it should be noted that, from an aesthetic point of view, the result of this technique has the disadvantage of an absence of eyelashes at the outer edge of the eyelid.

### **Ethical Approval:**

As per international standards or university standards written ethical approval has been collected and preserved by the author(s).

### **Consent**

As per international standards or university standards, patient(s) written consent has been collected and preserved by the author(s).

### **References:**

1. Musarde JC. Repair and reconstruction in the orbital region. 2nd ed. London: Churchill Livingstone; 1971.
2. Hughes WL. A new method for rebuilding a lower lid: report of a case. Arch Ophthalmol. 1937;17:1008–17.
3. Vayvada H, Menderes A, Tan O, Yilmaz M. Total lower eyelid reconstruction using paranasal flap. J CraniofacSurg. 2006;17:1020–6.
4. Scuderi N, Rubino C. Island chondro-mucosal flap and skin graft: a new technique in eyelid reconstruction. Br J Plast Surg. 1994;47:57–9.
5. Zinkernagel MS, Catalano E, Ammann-Rauch D. Free tarsal graft combined with skin transposition flap for full-thickness lower eyelid reconstruction. Ophthalmic Plast Reconstruction Surg. 2007;23:228–31.
6. Matsumoto K, Nakanishi H, Urano Y, Kubo Y, Nagae H. Lower eyelid reconstruction with a cheek flap supported by fascia lata. Plast Reconstruction Surg. 1999;103:1650–4.

7. Papp C, Maurer H, Geroldinger E. Lower eyelid reconstruction with the upper eyelid rotation flap. *Plast Reconstruction Surg.* 1990;86:563–5.
8. Heywood AJ, Quaba AA. A cheek island flap for the lower eyelid. *Br J Plast Surg.* 1991;44:183–6.
9. Nakajima T, Yoshimura Y. One-stage reconstruction of fullthickness lower eyelid defects using a subcutaneous pedicle flap lined by a palatal mucosal graft. *Br J Plast Surg.* 1996;49:183–6. [
10. Mehrotra ON. Repairing defects of the lower eyelid with a free chondromucosal graft. *Plast Reconstruction Surg.* 1977;59:689–93.
11. j.-p. Adenis, s. Morax. Orbital-palpebral pathology, sfo report 1998.
12. k.Heilmann, d. Paton. Atlas of ophthalmological surgery volume 1 1986.
13. .Tenzel RR. Reconstruction of the central one half of an eyelid. *Arch Ophthalmol.* 1975;93:125–6
14. Kroll SS, Reece GP, Robb G, Black J. Deep-plane cervicofacial rotation-advancement flap for reconstruction of large cheek defects. *Plast Reconstruction Surg.* 1994;94:88–93.
15. Austen WG, Jr, Parrett BM, Taghinia A, Wolfort SF, Upton J. The subcutaneous cervicofacial flap revisited. *Ann Plast Surg.* 2009;62:149–53.
16. Delay E, Lucas R, Jorquera F, Payement G, Foyatier JL. Composite cervicofacial flap for reconstruction of complex cheek defects. *Ann Plast Surg.* 1999;43:347–53.
17. Becker FF, Langford FP. Deep-plane cervicofacial flap for reconstruction of large cheek defects. *Arch Otolaryngol Head Neck Surg.* 1996;122:997–9
18. Cha JA, Lee KA. Reconstruction of periorbitaldefectusing a modifiedTenzelflap. *Archives of CraniofacialSurgery.* 2020 Feb;21(1):35.