

## **APERT'S DISEASE: Three case reports and review of the literature**

### **Abstract**

Apert's disease is an acrocephalosyndactyly, which is part of the craniofaciostenosis group. It is characterized by craniofacial dysmorphism and syndactyly of the hands and feet. It is a rare autosomal dominant condition, but sporadic cases are common. The pathogenesis is poorly understood. It is due to premature welding of the coronal sutures.

Presently described are cases of three infants diagnosed with Apert syndrome based on symptomatic association with the help of medical imaging.

Apert syndrome requires treatment by a multidisciplinary team. The priority of treatment is to combat brain compression in children and to manage cardiorespiratory problems. Facial anomalies most often require several surgical interventions at different ages of life.

**Keywords:** Apert syndrome, craniofaciostenosis, craniofacial dysmorphism, coronal sutures

### **INTRODUCTION:**

Apert's disease is an acrocephalosyndactyly, which is part of the craniofaciostenosis group. It is characterized by craniofacial dysmorphism and syndactyly of the hands and feet. It is a rare autosomal dominant condition, but sporadic cases are common. The pathogenesis is poorly understood. It is due to premature welding of the coronal sutures [1].

### **CASE REPORTS:**

#### Case 1:

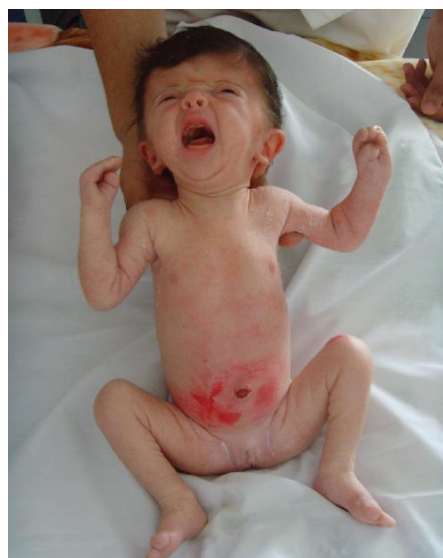Female newborn admitted at H1 of life for management of respiratory distress and malformation syndrome. She is the last of a family of 4 children. There is no consanguinity. She was born at full term vaginally with an Apgar of 9/10 at the 5th minute. The examination revealed brachycephaly, hypoplasia of the midface, syndactyly of the hands and feet and atresia of the choana. The skull x-ray, face and profile, showed a welded appearance of the 2 coronal sutures. The x-ray of the right hand showed syndactyly involving the 1st phalanges of the 2nd and 3rd ray of both hands with agenesis of multiple phalanges. The x-ray of both feet showed polydactyly, syndactyly of the first 2 phalanges of the 1st and 2nd rays and distal phalangeal agenesis of the 1st and 2nd rays. Cardiovascular examination found a small patent foramen ovale. Ophthalmological examination showed divergent strabismus and globular lens and chorioretinal atrophy in the left eye. This symptomatic association led to the diagnosis of Apert syndrome.

#### Case 2:

3-month-old infant, third of 3 siblings, from non-consanguineous parents, an unmonitored pregnancy and a vaginal birth. She presents a polymalformative syndrome with excessive height of the skull, facial dysmorphism with hypertelorism, bilateral exophthalmos, an ogival palate and syndactyly affecting all four limbs.

The hand x-ray showed synostosis of the distal phalanges and the skull x-ray showed coronal synostosis with digitiform impression. Brain CT showed brachycephaly.

Fig 1 : Picture of 3-month-old infant



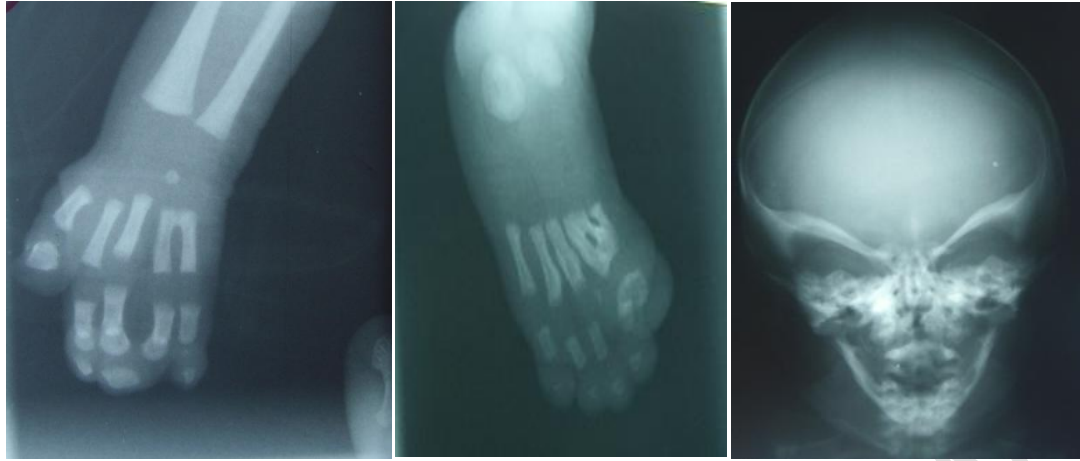


Fig 2: Xray report

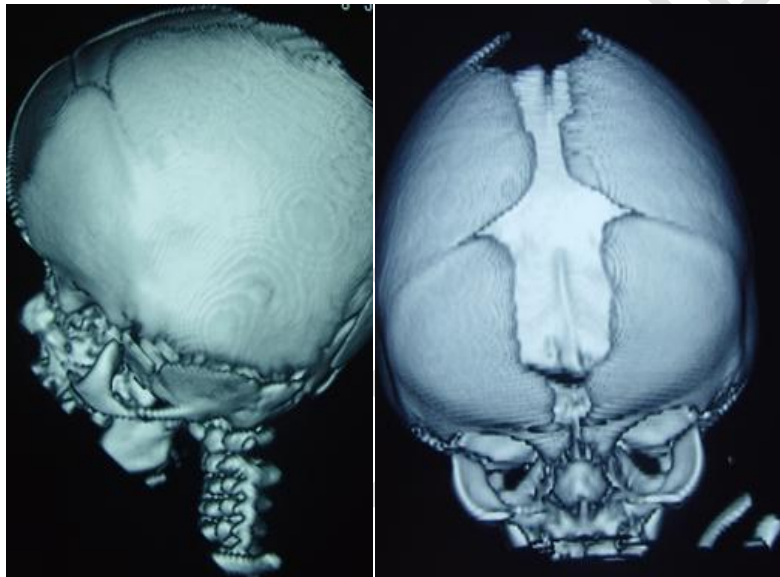


Fig 3 : Brain CT scan

Case 3:

One-month-old infant, only child, from non-consanguineous parents and a vaginal delivery. He presents with a polymalformative syndrome comprising brachycephaly, facial dysmorphism associating flattening of the root of the nose, hypertelorism and bilateral exophthalmos. She presents syndactyly of all four limbs. X-rays of the hands showed syndactyly of the distal phalanges and that of the skull a reduction in anteroposterior dimensions, coronal synostosis and digitiform impressions. Brain CT showed ventricular dilatation, cerebral edema and cortical atrophy.

**DISCUSSION:**

“AS is known as acrocephalosyndactyly type I which is a form of craniosynostosis. AS is characterized mainly by premature craniosynostosis, hypertelorism, syndactyly of hands, and feet, and many phenotypical symptoms”. [13]“It has an autosomal dominant inheritance, and develops as a mutation of fibroblast growth factor receptor -2 gene (FGFR2) on 10q26 gene locus. FGFR2 gene enables coding of a protein called fibroblast growth factor receptor -2 gene. This protein is one of the four FGFRs responsible for the formation of blood vessels, wound healing, embryonic evolution, and regulation of cellular division, growth, and maturation. FGFR binds to fibroblast growth factors with higher affinity, and plays an important role in signal pathways which function in the fusion process of skull bones” [4].

“AS is especially seen in children of the parents (frequently advanced paternal age) of advanced age. Although generally paternal mutations are seen, most of the cases are sporadic, and develop because of new mutations. Its incidence is 9.9–15.5 per one million live births which do not differ between genders” [5, 6].

“Phenotypic manifestations of the disease are explained by premature fusion of cranial sutures. Premature closure of coronal sutures before 3 months of age causes shorter anteroposterior diameter, high, and prominent forehead associated with acrocephalic (cone-shaped) head. The most prominent symptoms of this syndrome are syndactyly of hands, and feet” [5, 6]

In these patients midface is hypoplastic. Eye manifestations include hypertelorism, proptosis, and downslanting palpebral fissures. Nose, and nasal root is short, and widened.

“Rarely internal organ (renal, cardiac, gastrointestinal, genitourinary) involvement, elbow, shoulder, vertebral column (vertebral malsegmentation, fusion, hemivertebra) deformities, and frequently central nervous system defects (cerebellar, gyral, cortical defects, lissencephaly, hypogenesis or agenesis of corpus callosum, ventriculomegaly) which cause

mental disorders have been reported. In patients with Apert syndrome, upper respiratory tract infections, sleep apnea, and malnutrition can be seen. Respiratory distress can be severe requiring endotracheal intubation or tracheostomy. In patients with AS, true megalencephaly is seen, however generally mental disorders are rarely encountered” [2, 3, 4, 5, 6].

“Anteroposterior diameter of anterior cranial fossa is relatively shorter, because of forward displacement of greater wings of sphenoid bone, forehead is steep, wide, and flat, temporal regions are protruded, and occiput is flattened. Because of forward displacement of the sphenoid bone, and blockade of the frontal bone, maxillary bone can not develop on all three planes. Consequently, maxillary height, width of the nasal cavity, and nasopharyngeal height decrease, This anatomic configuration severely prevents development of oropharyngeal, and nasopharyngeal cavity. In these patients, usually oral respiration is seen with resultant impairment of respiratory functions. Ophthalmic symptoms have been explained by enlargement of middle cranial fossa towards anteroinferior direction because of the position of the greater wings of sphenoid bone, and decrease in the anteroposterior diameter of the orbita secondary to impingement of the orbita on lateral walls of the orbita” [8]. “Oral

symptoms are explained by decrease in especially anteroposterior diameter of the maxilla with resultant crowding of teeth, and increase in anterior opening of the oral cavity” [9].

“In patients with AS, hand, and foot deformities which effect daily life can be seen” [10]. “Pedal deformities which can be named in the literature as ‘Apert’s foot’ were divided in 3 types by Baluth and von Torne” [11]. “In AS patients with hand, and foot deformities, syndactyly should be corrected in order to increase quality of life of these patients. For this purpose surgical correction including partial amputation can be applied. Feet of the AS patients are not frequently suitable for wearing normal shoes because of pressure pain, and often surgery is required” [12].

## Conclusion

Alpert syndrome requires treatment by a multidisciplinary team. The priority of treatment is to combat brain compression in children and to manage cardiorespiratory problems. Facial anomalies most often require several surgical interventions at different ages of life.

## Ethical Approval:

As per international standards or university standards written ethical approval has been collected and preserved by the author(s).

## Consent

As per international standards, parental written consent has been collected and preserved by the author(s).

## **REFERENCES:**

1. APERT M.E. – Acrocephalosyndactyly. Bull. Same. Soc. Med. Hop. Paris 1906, 23: 1310-1330.
2. Bhatia PV, Patel PS, Jani YV, Soni NC. Apert’s syndrome: Report of a rare case. *J Oral Maxillofac Pathol.* 2013;17:294–7. [[PMC free article](#)] [[PubMed](#)] [[Google Scholar](#)]
3. Kumar GR, Jyothisna M, Ahmed SB, Sree Lakshmi KR. Apert’s Syndrome. *Int J Clin Pediatr Dent.* 2014;7:69–72. [[PMC free article](#)] [[PubMed](#)] [[Google Scholar](#)]

4. Varoli FP, Santos KCP, Costa C, Oliveira JX. Apert syndrome:clinical and radiographic features and case report. *Rev OdontoCienc.* 2011;26:96–9. [[Google Scholar](#)]
5. Cohen MM, Jr, Kreiborg S. Agenesis of the corpus callosum. Its associated anomalies and syndromes with special reference to the Apert syndrome. *Neurosurg Clin N Am.* 1991;2:5658. [[PubMed](#)] [[Google Scholar](#)]
6. Cohen MM., Jr Craniosynostosis and syndromes with craniosynostosis:incidence, genetics, penetrance, variability, and new syndrome updating. *Birth Defects Orig Artic Ser.* 1979;15:1363. [[PubMed](#)] [[Google Scholar](#)]
8. Katzen JT, McCarthy JG. Syndromes involving craniosynostosis and midface hypoplasia. *Otolaryngol Clin North Am.* 2000;33:1257–84. [[PubMed](#)] [[Google Scholar](#)]
9. Açıkgöz Y, Nurşen B, Yalın T, İncesu L, Küçüködük Ş. Apert Syndrome:A Case Report and Review of the Literature O.M.Ü *TıpDerg.* 2006;23:59–64. [[Google Scholar](#)]
10. Mason WH, Wymore M, Berger E. Foot deformities in Apert’s syndrome. Review of the literature and case reports. *J Am Podiatr Med Assoc.* 1990;80:540–4. [[PubMed](#)] [[Google Scholar](#)]
11. Blauth W, von Törne O. “Apert’s foot”(in acrocephalo-syndactyly) (author’s transl). [Article in German] *Z OrthopIhreGrenzgeb.* 1978;116:1–6. [Abstract] [[PubMed](#)] [[Google Scholar](#)]
12. Meyer JL. Apert’s syndrome:(acrocephalosyndactylism) *J Foot Surg.* 1981;20:210–3. [[PubMed](#)] [[Google Scholar](#)]
13. Koca TT. Apert syndrome: A case report and review of the literature. *Northern clinics of Istanbul.* 2016;3(2):135.