

## **Correlation between optical coherence tomography ganglion cell layer analysis and visual field in cases of benign intracranial hypertension**

### **Abstract**

**Background:** Benign intracranial hypertension (BIH) is a condition in which there is excessive cerebral spinal fluid (CSF) pressure in the subarachnoid space that surrounds the brain and spinal cord (intracranial pressure (ICP)) owing to an unexplained cause. It affects 1:100,000 persons yearly with a 20 times greater prevalence in young, obese girls. We wanted to correlate between optical coherence tomography ganglion cell layer analyses and visual field in patients of benign intracranial hypertension.

**Methods:** This cross-sectional clinical study that was carried out on 30 patients (60 eyes) who all had a recently diagnosed papilledema due to first episode of IHH. Goal of the study, and applied tests was done before obtaining an informed consent. Personal history, past medical and ocular history, possible risk factors for IHH were taken. Full ophthalmological examination including best corrected visual acuity (BCVA), intraocular pressure (IOP), color perception, pupillary reflexes, slit lamp bio microscopy examination including assessment of papilledema grade, blood pressure check and body mass index (BMI). All patients underwent automated perimetry in dim light to evaluate their visual field using SITA fast Standard 30-2 protocol by Humphrey Field Analyzer (Humphrey Field Analyzer I Carl Zeiss AG – Oberkochen – Germany).

**Results:** Average RNFL thickness had significant positive correlation with rim area ( $r=0.654$ ,  $P<0.001$ ) and disc area ( $r=0.665$ ,  $P<0.001$ ). Average RNFL thickness had no correlation with VA, IOP and average CD.

Average GCL complex had significant negative correlation with rim area ( $r= -0.283$ ,  $P=0.028$ ) and disc area ( $r= -0.328$ ,  $P=0.01$ ). Average GCL complex had no correlation with

VA, IOP and average CD. Minimum GCL complex had significant negative correlation with rim area ( $r = -0.272$ ,  $P = 0.036$ ) and disc area ( $r = -0.315$ ,  $P = 0.014$ ). Minimum GCL complex had no correlation with VA, IOP and average CD. Papilledema grading had significant positive correlation with average RNFL thickness ( $r = 0.461$ ,  $P < 0.001$ ). Papilledema grading had no correlation with average GCL complex, minimum GCL complex, VFI, MD and PSD.

**Conclusions:** There is a strong structure-function link between visual field indices and OCT parameters such as RNFL and GCC.

**Keywords:** Correlation, Optical Coherence Tomography, Ganglion Cell Layer , Visual ,Benign Intracranial Hypertension

## **Introduction:**

“Benign intracranial hypertension (BIH) is a disorder characterised by excessive cerebral spinal fluid (CSF) pressure in the subarachnoid space surrounding the brain and spinal cord (intracranial pressure (ICP)) for an unexplained reason. It affects 1 in 100,000 people each year, with a 20-fold greater prevalence in young, obese women”.<sup>(1)</sup>

“This syndrome is characterised by headache, pulsating tinnitus, and visual loss. Double vision resulting from 6th nerve palsy and/or transitory visual obscurations attributed to optic nerve head ischemia”.<sup>(2)</sup>

“Intracranial tumours of the midbrain, parieto-occipital area, and cerebellum are the most prevalent causes of papilloedema. PTC is often referred to as benign Intracranial Hypertension”<sup>(3)</sup>.

The visual field abnormalities caused by papilledema in Bosnia and Herzegovina are "disc-related deficiencies" similar to those seen in glaucoma. Blind spot expansion, widespread constriction, and loss of the nasal visual fields, particularly inferonasal, are the most frequent abnormalities seen in BIH.<sup>(4)</sup>

“Other common field defects described include inferior altitudinal loss, superonasal and superotemporal loss, arcuate defects, and scotomas (central, cecocentral, and paracentral)”<sup>(5)</sup>.

“Optical coherence tomography (OCT) is a non-invasive imaging method widely used in ophthalmology to provide high-resolution cross-sectional images of the retina”<sup>(6)</sup>. “Time domain OCT (TD-OCT), Fourier domain OCT (FD-OCT) or Spectral domain OCT (SD-OCT), Swept-source OCT (SS-OCT), and Full-Field OCT (en face imaging) are OCT classifications”.<sup>(7, 8)</sup>

“OCT has also shows promise for diagnosis and monitoring of BIH as it captures optic nerve head swelling that characterizes papilledema, retinal nerve fiber layer (RNFL) and retinal pigment epithelium/Bruch’s Membrane (RPE/BM) changes that are associated with acute and

chronic changes in intracranial pressure”<sup>(9, 10)</sup>. “Currently, spectral-domain OCT (SD-OCT) technology allows quantification of retinal individual layers. The Ganglion Cell layer (GCL) investigation has become one of the most useful tools from a neuro-ophthalmic perspective. It has a high correlation with perimetry”<sup>(9, 10)</sup>.

We aimed to correlate between optical coherence tomography ganglion cell layer analysis and visual field in cases of benign intracranial hypertension.

### **Patients and Methods:**

This clinical cross-sectional investigation was conducted on 30 patients (60 eyes) who had just been diagnosed with papilledema owing to a first episode of IIH. Before gaining informed permission, the study's objectives and tests were performed.

Patients having papilledema owing to reasons other than IIH, such as infection, cavernous venous sinus thrombosis, tumours, and other space-occupying lesions, were excluded from the research. Patients with persistent papilledema, neurological disorders, glaucoma, and those reluctant to provide informed permission were also eliminated.

Personal history, prior medical and ocular history, and potential IIH risk factors were collected for each patient. Best-corrected visual acuity (BCVA), intraocular pressure (IOP), colour perception, pupillary reflexes, slit-lamp biomicroscopy examination with papilledema grade evaluation, blood pressure check, and body mass index (BMI). All patients performed automated perimetry in poor light to analyse their visual field using the SITA quick Standard 30-2 methodology on the Humphrey Field Analyzer (Humphrey Field Analyzer I Carl Zeiss AG – Oberkochen, Germany). Spectral Domain OCT (SD-OCT) imaging of the optic nerve head was done to evaluate the ganglion cell layer and peripapillary RNFL thickness using the Zeiss 5000 cirrus HD OCT.

### **Image analysis**

Fundus examination was done especially for posterior segment for presence of any of the following :

- a. Bilateral disc oedema (may be asymmetry)
- b. Hemorrhage and exudate resolve
- c. Champagne cork (obliterated central cup)
- d. Milky gray nerve head
- e. Hard exudate on disc surface may simulate drusen
- f. Hyperaemia
- g. Ill defined edge of the disc
- h. Elevation of the disc margin
- i. Obscuration of vessels-edge on disc

#### **VF (Humphrey)**

Using central 30 -2 threshold test with SITA Fast standard strategy, the following finding are evaluated

**Reliability indices:** Name, demographics

Fixation loss: The HVF will frequently flash dots in the patient's physiological blind spot in order to determine whether or not the patient's attention is fixed on the centre. If the patient can see the target, it is not considered a fixation loss. Reliable tests have fixation loss below 20 percent (although many people have their own opinions about these upper limits). The person hit the button when there was no stimulation present. They were "impulsive shooters." There are less than 33 percent false positives in reliable tests. False negative: The user did not see a stimulus that was brighter than one they had previously encountered during the same test. Tests that are reliable have less than 33 percent false negatives.

The following are stimulant characteristics: 99 percent of visual fields (VFs) will use a white stimulus of size 3. Patients with late illness or retinal disease use other sizes and hues.

**Sensitivity blot:** The visual threshold is the stimulus intensity seen 50% of the time at each place. In the sensitivity plot, the threshold values for each tested point are indicated in dB. Higher scores indicate that the patient was able to see a more attenuated light and, thus, has more sensitive eyesight at that place.

**Total deviation:** The numerical total deviation map compares the patient's visual sensitivity to that of a normal person of the same age who is of typical normality. As sensitivity often declines progressively with age, it is good to compare with age-matched normal thresholds. Positive values represent areas of the field where the patient can see dimmer stimuli than the average individual of that age. Negative values represent decreased sensitivity from normalcy, and not the numerical dB plot.

**Pattern deviation:** The numerical pattern deviation map displays disparities within a patient's visual field by compensating for overall declines in visual sensitivity. It is beneficial to reveal specific pockets of sensitivity loss concealed within a diffusely depressed field.

The probability graphs at the bottom of the page are grayscale renditions of the total deviation and pattern deviation maps. These maps may be helpful for illustrating graphically the statistical importance of the total and pattern deviation computations. To prevent extrapolation, the grayscale maps should only be understood in combination with the numerical maps.

The mean deviation (MD) of the visual field is a statistical metric used to evaluate the average difference in visual field sensitivity compared to the mean sensitivity of an observer of the same age who is normal. MD has also been used to track the evolution of the visual field throughout time.

**Pattern standard deviation:** Pattern standard deviation (PSD) **measures irregularity by summing the absolute value of the difference between the threshold value for each point**

**and the average visual field sensitivity at each point** (equal to the normal value for each point + the MD).

**Optical coherence tomography:** Spectral domain OCT Zeiss 5000 retinal nerve fiber layer thickness, ganglion cell layer analysis was done after pupillary dilatation.

#### **The parameters used in the machine**

- The Cirrus HD-OCT (Carl Zeiss Meditec, Dublin, CA) device is a spectral-domain optical coherence tomography system that allows faster data acquisition than the previous generation.
- Based on macular cube or 512 in 128 or 200\_ time 200 scan, this analysis provides quantitative and qualitative evaluation of ganglion cell layer and inner plexiform layer.
- Maps for ganglion cell layer and inner plexiform layer thickness are shown in the fundus photo also showed in the elliptical measurement annulus centered about the fovea.
- Deviation map shows deviation from normal.
- Sector map deviate the elliptical annulus of the thickness map into six regions, values are compared to normative data.
- Thickness table: Shows average and minimum thickness within the elliptical annulus.
- Horizontal B scan.

#### **Statistical analysis**

SPSS version 25 was used for statistical analysis (IBM Inc., Chicago, IL, USA). Using the Shapiro-Wilks normality test and histograms, the distribution of quantitative data was examined in order to identify the appropriate kind of statistical testing: parametric or nonparametric. The mean and standard deviation (SD) of parametric variables were used to compare the three groups using an ANOVA test, followed by a post hoc (Tukey) test to compare each pair of groups. Categorical variables were reported in terms of frequency and percentage, and the Chi-square test was used to examine their statistical significance. The Linear Association Coefficient was used to determine the correlation between two

quantitative variables within a single group. A two-tailed P value of less than or equal to 0.05 was deemed statistically significant.

**Cases:**

Female patient, 20 years old diagnosed with papilloedema grade II. OCT RNFL shows:

OD: Increase thickness of inferior, superior, nasal quadrants.

OS: Increase thickness of inferior, superior quadrants.

OCT GCL complex (GCL+IPL) shows: OD: Average thickness.

OS: Average thickness.

VF shows: OD: Enlarged blind spot, mild lower nasal defect.

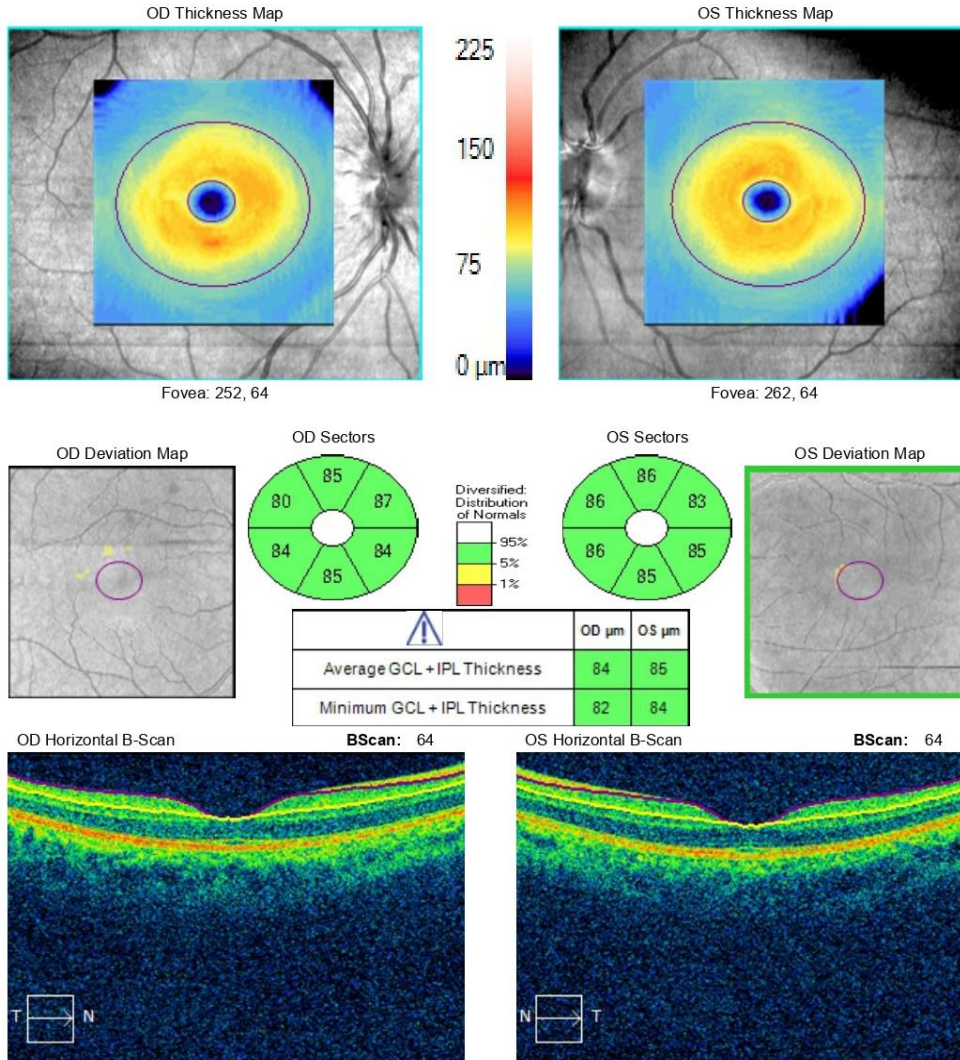
OS: Enlarged blind spot, Lower paracentral scotoma., Upper nasal defect.

UNDER PEER REVIEW

Name: **Abbas, Marium Osma** OD OS  
 ID: 21-01101502 Exam Date: 11/15/2021 11/15/2021 CZMI  
 DOB: 5/15/2002 Exam Time: 3:45 PM 3:40 PM  
 Gender: Female Serial Number: 5000-6350 5000-6350  
 Technician: Operator, Cirrus Signal Strength: 8/10 7/10



**Ganglion Cell OU Analysis: Macular Cube 512x128** OD ● ● OS



Comments

Doctor's Signature

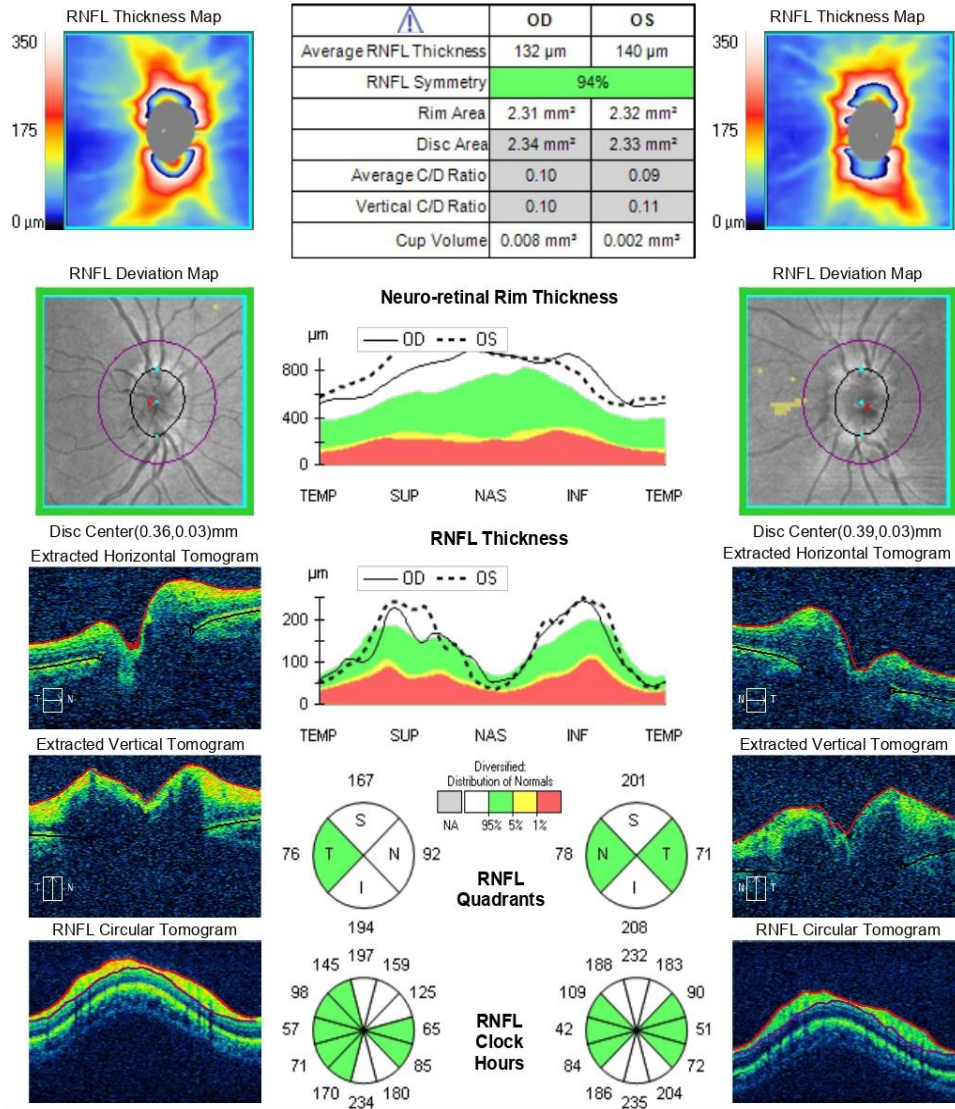
SW Ver: 11.0.0.29946  
 Copyright 2018  
 Carl Zeiss Meditec, Inc  
 All Rights Reserved  
 Page 1 of 1

Fig 1. Ganglion cell OU analysis

Name: **Abbas, Marium Osma** OD OS  
 ID: 21-01101502 Exam Date: 11/15/2021 11/15/2021 CZMI  
 DOB: 5/15/2002 Exam Time: 3:44 PM 3:42 PM  
 Gender: Female Serial Number: 5000-6350 5000-6350  
 Technician: Operator, Cirrus Signal Strength: 7/10 4/10



**ONH and RNFL OU Analysis: Optic Disc Cube 200x200 OD OS**



Comments

Doctor's Signature

SW Ver: 11.0.0.29946  
 Copyright 2018  
 Carl Zeiss Meditec, Inc  
 All Rights Reserved  
 Page 1 of 1

Fig 2. ONH and RNFL analysis

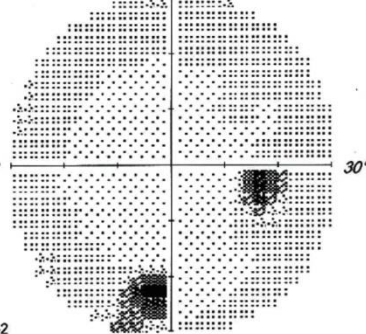

Patient: **Maryam, Osama**  
 Date of Birth: **May 28, 2007**  
 Gender: **Female**  
 Patient ID: **433\_009**



ibn sina

**OD** Single Field Analysis Central 30-2 Threshold Test

Fixation Monitor:	Off	Stimulus:	III, White	Date:	Nov 15, 2021
Fixation Target:	Central	Background:	31.5 asb	Time:	3:23 PM
Fixation Losses:	0/0	Strategy:	SITA Fast	Age:	20
False POS Errors:	6%	Pupil Diameter:			
False NEG Errors:	9%	Visual Acuity:			
Test Duration:	03:47	Rx:	+0.00 DS		
Fovea:	Off				





-2	-4	0	-3						
-2	-3	-1	-1	-1	0				
-2	-3	-1	-1	-1	-2	-1	-4		
-9	-2	-2	0	-2	-4	-1	-3	-3	
-4	-4	-1	-1	-1	-2	-4	-2		
-3	-3	-1	-2	-3	-2	-2	-3	-3	
-4	-6	-2	0	-2	-3	-3	-9	-4	-3
-7	-3	-2	-1	-1	-1	-3	-2		
-3	-4	-34	-1	-1	-4				
-10	-9	-1	-6						

-2	-3	1	-2						
-1	-2	0	0	0	0				
-2	-2	0	0	0	-1	-1	-3		
-8	-1	-2	1	-1	-1	-4	-1	-2	-2
-4	-3	0	0	0	0	-1	-3	-2	
-3	-2	0	-1	-2	-1	-2	-2	-2	
-3	-5	-1	0	-1	-2	-2	-8	-3	-2
-6	-2	-1	0	-1	0	-2	-2		
-2	-3	-33	0	0	-3				
-9	-8	0	-5						

Total Deviation

Pattern Deviation



GHT: Outside Normal Limits

VFI: 98%  
 MD30-2: -2.83 dB P < 2%  
 PSD30-2: 4.74 dB P < 0.5%

:: P < 5%  
 ☼ P < 2%  
 ☼☼ P < 1%  
 ■ P < 0.5%

Comments



© 2019 Carl Zeiss Meditec, Inc. All rights reserved.

HFA 3 850-18917/1.5.2.431

Version 1.5.2.431

Created: 1/3/2022 4:40:00 PM by Administrator

Page 1 of 1


Fig 3. Analytical result 1

Patient: **Maryam, Osama**  
 Date of Birth: **May 28, 2007**  
 Gender: **Female**  
 Patient ID: **433\_009**



**OS** Single Field Analysis Central 30-2 Threshold Test

Fixation Monitor:	Off	Stimulus:	III, White	Date:	Nov 15, 2021
Fixation Target:	Central	Background:	31.5 asb	Time:	3:28 PM
Fixation Losses:	0/0	Strategy:	SITA Fast	Age:	20
False POS Errors:	3%	Pupil Diameter:			
False NEG Errors:	13%	Visual Acuity:			
Test Duration:	04:26	Rx:	+0.00 DS		
Fovea:	Off				





-8	-3	-8	-7						
-1	-4	-2	-8	-4	-13				
-3	-1	-2	-2	-5	-4	-4	-11		
-4	-2	-2	-4	-3	-3	-4	-5	-11	-13
-1	-8	-5	-5	-3	-4	-7	-8	-7	
-2	-7	-5	-7	-6	-4	-5	-4	-7	
-5	-5	-6	-5	-5	-5	-3	-2	-3	-4
-5	-8	-7	-6	-9	-7	-4	-11		
-1	-7	-4	-4	-14	-20				
-23	-5	-4	-8						

-6	-1	-6	-4						
1	-1	0	-6	-2	-10				
-1	1	0	0	-3	-1	-2	-8		
-1	0	1	-1	0	-1	-1	-2	-9	-11
1	-6	-2	-2	-1	-1	-5	-5	-4	
0	-5	-3	-4	-3	-2	-2	-1	-5	
-3	-2	-4	-3	-3	-2	-1	0	0	-2
-2	-6	-5	-4	-6	-4	-2	-9		
2	-5	-1	-1	-12	-18				
-20	-3	-1	-6						

Total Deviation

Pattern Deviation



GHT: Outside Normal Limits

VFI: 93%  
 MD30-2: -5.42 dB P < 1%  
 PSD30-2: 3.82 dB P < 2%

:: P < 5%  
 ☼ P < 2%  
 ☼ P < 1%  
 ■ P < 0.5%

Comments



**Fig 4.** Analytical result 2

**Results:**

Error! Not a valid bookmark self-reference. showed among studied patients, 3 (10%) were males and 27 (90%) were females. Patients age ranged from 18 – 45 years with a mean ± SD

of  $35.267 \pm 7.75$ . BMI ranged from 22 – 38 kg/m<sup>2</sup> with a mean  $\pm$  SD of  $29.9 \pm 4.7$  kg/m<sup>2</sup>. VA ranged from 0.17 to 0.67 with a mean  $\pm$  SD of  $0.452 \pm 0.215$ . IOP ranged from 9 to 18 with a mean  $\pm$  SD of  $13.167 \pm 2.018$ . Average CD ranged from 0.05 to 0.37 with a mean  $\pm$  SD of  $0.097 \pm 0.078$ . Rim area ranged from 1.46 to 2.86 with a mean  $\pm$  SD of  $1.928 \pm 0.352$ . Disc area ranged from 1.48 to 2.94 with a mean  $\pm$  SD of  $1.948 \pm 0.289$ . Average RNFL thickness ranged from 63 to 441 with a mean  $\pm$  SD of  $133.2 \pm 84.887$ . Average GCL complex ranged from 29 to 110 with a mean  $\pm$  SD of  $75 \pm 18.3$ . Minimum GCL complex ranged from 18 to 98 with a mean  $\pm$  SD of  $68.9 \pm 21.781$ . VFI ranged from 0.54 to 1.14 with a mean  $\pm$  SD of  $0.870 \pm 0.136$ . MD ranged from -16.97 to 0.93 dB with a mean  $\pm$  SD of  $-6.125 \pm 4.995$  dB. PSD ranged from 1.39 to 13.02 dB with a mean  $\pm$  SD of  $5.111 \pm 3.422$  dB.

**Table 1: Demographic data and Clinical evaluation**

		<b>N=30</b>					
<b>Gender</b>	<b>Male</b>	3 10.00%)					
	<b>Female</b>	27(90.00%)					
<b>Age (Years)</b>	<b>Range</b>	18-45					
	<b>Mean <math>\pm</math>SD</b>	35.267 $\pm$ 7.750					
<b>BMI</b>	<b>Range</b>	22-38					
	<b>Mean <math>\pm</math>SD</b>	29.900 $\pm$ 4.700					
<b>Descriptive Statistics</b>							
		<b>Range</b>			<b>Mean</b>	<b><math>\pm</math></b>	<b>SD</b>
<b>VA</b>		0.17	-	0.67	0.452	$\pm$	0.215
<b>IOP</b>		9	-	18	13.167	$\pm$	2.018
<b>Average CD</b>		0.05	-	0.37	0.097	$\pm$	0.078
<b>Rim area</b>		1.46	-	2.86	1.928	$\pm$	0.352
<b>Disc area</b>		1.48	-	2.94	1.948	$\pm$	0.289
<b>Average RNFL thickness</b>		63	-	441	133.200	$\pm$	84.887
<b>Average GCL complex</b>		29	-	110	75.000	$\pm$	18.300
<b>Minimum GCL complex</b>		18	-	98	68.900	$\pm$	21.781
<b>VFI</b>		0.54	-	1.14	0.870	$\pm$	0.136
<b>MD "dB"</b>		-16.97	-	0.93	-6.125	$\pm$	4.995
<b>PSD "dB"</b>		1.39	-	13.02	5.111	$\pm$	3.422

**Table 2** 26 (43.33 percent) of the patients tested reported diplopia, 50 (83.33 percent) had headaches, 33 (55 percent) had TVO, and 30 (50 percent) had tinnitus. Regarding the anterior section, fifty (83.33%) patients had NAD, four (6.67%) had nebula, and six (10%) had weak lens opacity. All eyes exhibited an intact pupillary light reflex, edoema, hyperemia, and cup obliteration. In terms of colour vision and contrast sensitivity, 38 (63.33 percent) out of 22 (36.67%) eyes were normal. Regarding BVs, thirteen (21.67%) eyes were normal, eighteen (30%) were blocked, and twenty-nine (48.33%) exhibited venous dilatation and vascular tortuosity.

**Table 2: Symptoms and clinical evaluation of the studied patients**

		N	%
<b>Diplopia</b>	<b>Present</b>	26(43.33%)	
	<b>Absent</b>	34 (56.67%)	
<b>Headache</b>	<b>Present</b>	50 (83.33%)	
	<b>Absent</b>	10 (16.67%)	
<b>TVO</b>	<b>Present</b>	33(55.00%)	
	<b>Absent</b>	27(45.00%)	
<b>Tinnitus</b>	<b>Present</b>	30(50.00%)	
	<b>Absent</b>	30(50.00%)	
<b>Clinical</b>		N	%
<b>Anterior segment</b>	<b>NAD</b>	50(83.33%)	
	<b>Nebula</b>	4 (6.67%)	
	<b>Faint lens opacity</b>	6(10.00)	
<b>Pupillary Light Reflex</b>	<b>Intact</b>	60(100.00%)	
<b>Color vision and contrast sensitivity</b>	<b>Normal</b>	38(63.33%)	
	<b>Abnormal</b>	22(36.67%)	
<b>Swelling</b>	<b>Present</b>	60(100.00%)	
<b>Hyperemia</b>	<b>Present</b>	60(100.00%)	
<b>Obliteration of the cup</b>	<b>Present</b>	60(100.00%)	
<b>BVs</b>	<b>Normal</b>	13(21.67%)	
	<b>Obstructed</b>	18(30.00%)	

	<b>Venous dilatation &amp; vascular tortuosity</b>	29(48.33%)
--	--	------------

**Table 3 showed that, Regarding papilledema grading, 23 (38.33%) eyes were grad II, 26 (43.33%) were grad III and 11 (18.33%) were grad IV.)**

**Table 3: Papilledema grading of the studied patients**

<b>Papilledema grading</b>		
	<b>N</b>	<b>%</b>
<b>Grad II</b>		23(38.33%)
<b>Grad III</b>		26(43.33%)
<b>Grad IV</b>		11 (18.33%)
<b>Total</b>		60(100.00%)

**Table 4 showed that ,Average RNFL thickness was  $91.391 \pm 24.585$  (mean  $\pm$  SD) in grad II,  $141.462 \pm 83.73$  (mean  $\pm$  SD) in grad III and  $201.091 \pm 119.956$  (mean  $\pm$  SD) in grad IV. Average GCL complex was  $74.609 \pm 12.999$  (mean  $\pm$  SD) in grad II,  $76.115 \pm 20.233$  (mean  $\pm$  SD) in grad III and  $73.182 \pm 23.945$  (mean  $\pm$  SD) in grad IV. Minimum GCL complex was  $68.261 \pm 16.04$  (mean  $\pm$  SD) in grad II,  $68.269 \pm 23.808$  (mean  $\pm$  SD) in grad III and  $71.727 \pm 28.376$  (mean  $\pm$  SD) in grad IV. VFI was  $0.873 \pm 0.154$  (mean  $\pm$  SD) in grad II,  $0.866 \pm 0.134$  (mean  $\pm$  SD) in grad III and  $0.873 \pm 0.113$  (mean  $\pm$  SD) in grad IV. MD was  $-6.118 \pm 5.652$  (mean  $\pm$  SD) in grad II,  $-6.009 \pm 5.183$  (mean  $\pm$  SD) in grad III and  $-6.414 \pm 3.107$  (mean  $\pm$  SD) in grad IV. PSD was  $5.703 \pm 3.586$  (mean  $\pm$  SD) in grad II,  $4.948 \pm 3.420$  (mean  $\pm$  SD) in grad III and  $4.258 \pm 3.143$  (mean  $\pm$  SD) in grad IV.**

Regarding average RNFL thickness, there was a significant difference between the three papilledema grades (P-value = 0.001).

**Table 4: Correlation between papilledema grading and OCT parameters:**

	<b>Papilledema grading</b>			<b>ANOVA</b>	
	<b>Grad II</b>	<b>Grad III</b>	<b>Grad IV</b>	<b>F</b>	<b>P-value</b>
	<b>Mean <math>\pm</math> SD</b>	<b>Mean <math>\pm</math> SD</b>	<b>Mean <math>\pm</math> SD</b>		
<b>Average RNFL thickness</b>	$91.391 \pm 24.585$	$141.462 \pm 83.730$	$201.091 \pm 119.956$	7.94 5	0.001*

<b>Average GCL complex</b>	74.609 ± 12.999	76.115 ± 20.233	73.182 ± 23.945	0.105	0.901
<b>Minimum GCL complex</b>	68.261 ± 16.040	68.269 ± 23.808	71.727 ± 28.376	0.110	0.896
<b>VFI</b>	0.873 ± 0.154	0.866 ± 0.134	0.873 ± 0.113	0.021	0.979
<b>MD "dB"</b>	-6.118 ± 5.652	-6.009 ± 5.183	-6.414 ± 3.107	0.025	0.976
<b>PSD "dB"</b>	5.703 ± 3.586	4.948 ± 3.420	4.258 ± 3.143	0.708	0.497

**Table 5 showed that** ,VFI had significant positive correlation with average RNFL thickness (r=0.292, P=0.024), average GCL complex (r=0.383, P=0.003) and minimum GCL complex (r=0.297, P=0.021). VFI had no correlation with average CD, rim and disc area.

MD had significant positive correlation with average GCL complex (r=0.508, P<0.001) and minimum GCL complex (r=0.354, P=0.006). MD had no correlation with average CD, rim and disc area and average RNFL thickness. PSD had significant positive correlation with average CD (r=0.365, P=0.004) while it had significant negative correlation with average RNFL thickness (r= -0.257, P=0.048), average GCL complex (r= -0.612, P<0.001) and minimum GCL complex (r= -0.499, P<0.001). PSD had no correlation with rim and disc area.

**Table 5: Correlation between OCT parameters and visual field parameters:**

<b>Correlations</b>						
<b>Pearson Correlation</b>	<b>VFI</b>		<b>MD "dB"</b>		<b>PSD "dB"</b>	
	<b>r</b>	<b>P-value</b>	<b>r</b>	<b>P-value</b>	<b>r</b>	<b>P-value</b>
<b>Average CD</b>	-0.192	0.143	-0.227	0.082	0.365	0.004*
<b>Rim area</b>	0.128	0.331	-0.134	0.307	0.138	0.292
<b>Disc area</b>	0.240	0.064	-0.030	0.820	0.079	0.547
<b>Average RNFL thickness</b>	0.292	0.024*	0.094	0.476	-0.257	0.048*

<b>Average GCL complex</b>	0.383	0.003*	0.508	<0.001*	-0.612	<0.001*
<b>Minimum GCL complex</b>	0.297	0.021*	0.354	0.006*	-0.499	<0.001*

**Table 6** showed that Average RNFL thickness had significant positive correlation with rim area ( $r=0.654$ ,  $P<0.001$ ) and disc area ( $r=0.665$ ,  $P<0.001$ ). Average RNFL thickness had no correlation with VA, IOP and average CD.

Average GCL complex had significant negative correlation with rim area ( $r= -0.283$ ,  $P=0.028$ ) and disc area ( $r= -0.328$ ,  $P=0.01$ ). Average GCL complex had no correlation with VA, IOP and average CD. Minimum GCL complex had significant negative correlation with rim area ( $r= -0.272$ ,  $P=0.036$ ) and disc area ( $r= -0.315$ ,  $P=0.014$ ). Minimum GCL complex had no correlation with VA, IOP and average CD. **Table (6)**

**Table 6: Correlation between OCT parameters and clinical manifestations:**

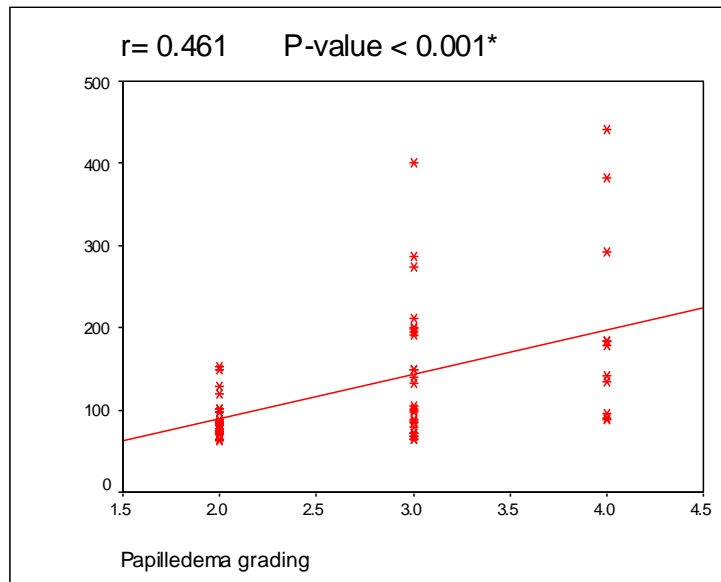
<b>Correlations</b>						
<b>Pearson Correlation</b>	<b>Average RNFL thickness</b>		<b>Average GCL complex</b>		<b>Minimum GCL complex</b>	
	<b>R</b>	<b>P-value</b>	<b>R</b>	<b>P-value</b>	<b>r</b>	<b>P-value</b>
<b>VA</b>	-0.046	0.727	-0.157	0.230	-0.125	0.342
<b>IOP</b>	-0.057	0.663	0.044	0.738	-0.142	0.280
<b>Average CD</b>	-0.235	0.070	-0.163	0.213	-0.070	0.597
<b>Rim area</b>	0.654	<0.001*	-0.283	0.028*	-0.272	0.036*
<b>Disc area</b>	0.665	<0.001*	-0.328	0.010*	-0.315	0.014*

**Table (7)** showed that ,Papilledema grading had significant positive correlation with average RNFL thickness ( $r=0.461$ ,  $P<0.001$ ). Papilledema grading had no correlation with average GCL complex, minimum GCL complex, VFI, MD and PSD.

**Table 7: Correlation between papilledema grading and OCT parameters:**

<b>Correlations</b>	
<b>Spearman's rho</b>	<b>Papilledema grading</b>

	<b>r</b>	<b>P-value</b>
<b>Average RNFL thickness</b>	0.461	<0.001*
<b>Average GCL complex</b>	0.049	0.711
<b>Minimum GCL complex</b>	0.170	0.194
<b>VFI</b>	-0.012	0.929
<b>MD "dB"</b>	-0.113	0.390
<b>PSD "dB"</b>	-0.177	0.176



**Figure 5: Correlation between average RNFL thickness and papilledema grading.**

## Discussion

“It is important to highlight that the decrease in RNFL thickness during therapy may occur from two separate causes, the first of which is the real resolution of edoema”.<sup>(11)</sup> “The second process is nerve fibre degeneration. If nerve fibres are destroyed, field perimetry as a functional test will reveal irreversible impairments corresponding to the nerve fibre loss. Therefore, it is proposed that both OCT and field perimetry be required for simultaneous qualitative and quantitative evaluation”.<sup>(12)</sup>

“It is difficult to diagnose optic neuropathy in patients with idiopathic intraocular hypertension because papilledema obscures the nerve, making it difficult to detect optic disc pallor, and because swollen axons of the optic nerve preclude proper evaluation of axonal loss by OCT”.<sup>(13)</sup>

In the present study, regarding average RNFL thickness, there was a significant difference between the three papilledema grades (P-value = 0.001).

In the same line, **Beheiry et al. (2021)** <sup>(13)</sup> 40 eyes (20 patients) newly diagnosed with a first bout of IIH with papilledema were evaluated prospectively. Perimetric mean deviation (PMD) and spectral domain optical coherence tomography (SD-OCT) measurements of peripapillary retinal nerve fibre layer (RNFL) thickness were taken at baseline and 1, 3, and 6 months following treatment initiation. They discovered that RNFL thickness varied considerably across papilledema grades and that there was a significant association between papilledema grade and RNFL thickness during the course of the trial ( $p < 0.0001$ ).

In agreement with our results, **Scott et al. (2010)** <sup>(14)</sup> Compared and contrasted optical coherence tomography (OCT) and the Modified Frisen Scale (MFS) for quantifying papilledema in 36 individuals with papilledema. They discovered a substantial correlation between papilledema severity and OCT RNFL ( $p < 0.001$ ).

In the present study, VFI had a significant positive correlation with average RNFL thickness ( $r = 0.292$ ,  $P = 0.024$ ), average GCL complex ( $r = 0.383$ ,  $P = 0.003$ ), and minimum GCL complex ( $r = 0.297$ ,  $P = 0.021$ ). There was no correlation between VFI and VA, the average CD, rim, or disc area of the IOP, nor was there any correlation between VFI and VA.

In agreement with comparably, **Rao et al. (2014)** <sup>(15)</sup> reported a positive correlation of the VFI was seen with average and superior RNFL thickness ( $b = 2.1$ ,  $P < 0.001$  and  $b = 1.8$ ,  $P = 0.03$ , respectively).

In their study, **Nogueira et al. (2021)** <sup>(16)</sup> reported “in patients with intracranial hypertension, the patients with IIH were found to have thinner GCC compared to controls. In addition, the thickness of the GCC was associated with optic nerve pallor. Although GCC is generally expected to be normal in patients with IIH, patients with abnormalities are expected to progress to optic atrophy and decreased visual acuity”.

According to our results, MD had significant positive correlation with average GCL complex ( $r=0.508$ ,  $P<0.001$ ) and minimum GCL complex ( $r=0.354$ ,  $P=0.006$ ). MD had no correlation with VA, average CD, rim and disc area and average RNFL thickness.

In the same context, **Vijay et al. (2020)** <sup>(17)</sup> studied “OCT of papilledema correlation with intracranial pressure levels in idiopathic intracranial hypertension. Their cohort study of 104 participants’ optic nerve head volume measures of central thickness, central volume, maximum height (any point), and maximum height (central slice) all correlated with intracranial pressure measured either by telemetry or lumbar puncture. The results showed that OCT GCL was positively correlated with MD ( $r = 0.19$ ;  $P = .13$ )”

Additionally, **Athappilly et al. (2018)** <sup>(18)</sup> evaluated IIH patients testing the gold standard in identifying future vision loss and documented that GCC thickness was significantly associated with MD ( $p = 0.01$ )

In agreement with our findings, **Tieger et al. (2017)** <sup>(19)</sup> Twenty-three patients diagnosed between 2010 and 2015 with chiasmal compression were examined using Cirrus high-definition OCT, retinal nerve fibre layer (RNFL) scan procedures, and automated (30-2 Humphrey) visual fields (VFs). The authors observed a correlation between MD and average GCC, with GCC thickness being the most highly connected with MD ( $r^2 = 0.25$ ).

In agreement with our results, **Khalil et al. 2015** <sup>(20)</sup> carried “a prospective observational study was carried out for 30 patients with confirmed IIH (age  $\geq 18$  years), BMI below 25, intracranial pressure (ICP) of at least 20 cm H<sub>2</sub>O, and normal neurological examination (except for papilloedema and horizontal diplopia). The most recent lumbar puncture opening pressure (latest ICP) was recorded for every patient who had a thorough neurological examination. Initial peripapillary RNFL was significantly negatively correlated with final MD ( $r = 0.368$ ,  $P = 0.004$ ). The discrepancy may be due to the fact that they studied

individuals with idiopathic intracranial hypertension, while our focus was on benign intracranial hypertension”.

However, **Khalil et al. 2015** <sup>(20)</sup> reported comparable results as regards GCC which showed a significant linear correlation with final MD ( $r = 0.710$ ,  $P = 0.000$ ) in IIH cases.

Compatible with our results, **Labib et al. (2015)** <sup>(21)</sup> investigated OCT and perimetry changes in patients with IIH at admission and 6 months later and highlight the relationship between OCT changes and severity of visual dysfunction measured by automated perimetry. They found a significant nonlinear correlation between RNFL with MD ( $r = -0.368$ ,  $P = 0.004$ ).

In the current study, PSD had significant positive correlation with average CD ( $r=0.365$ ,  $P=0.004$ ) while it had significant negative correlation with average RNFL thickness ( $r= -0.257$ ,  $P=0.048$ ), average GCL complex ( $r= -0.612$ ,  $P<0.001$ ) and minimum GCL complex ( $r= -0.499$ ,  $P<0.001$ ). PSD had no correlation with VA, IOP and rim and disc area.

Consistently, **Khalil et al. 2015** <sup>(20)</sup> found significant a negative linear correlation between initial peripapillary RNFL with s final PSD ( $r = -0.450$ ,  $P = 0.000$ ) in IIH cases. Also, as regards GCC, it showed significant linear correlation with PSD ( $r = -0.450$ ,  $P = 0.000$ ) in IIH cases.

Moreover, **Labib et al. (2015)** <sup>(21)</sup> recorded a significant nonlinear correlation between initial peripapillary RNFL and PSD ( $r = 0.359$ ,  $P = 0.005$ ).

Previous research assessed the significance of GCC or RNFL thickness in instances of IIH accompanied by papilledema. In general, OCT measures will be aberrant in individuals with active disease, with increases in neuroretinal rim thickness and optic disc area and decreases in physiologic excavation volume in all stages of papilledema. During the acute stage of papilledema, there must be an increase in RNFL thickness <sup>(22)</sup>; In contrast, RNFL thickness in patients with optic atrophy should rise less or not at all, while it should be normal in patients in remission from the illness without sequelae and in healthy controls. <sup>(23)</sup>.

Average GCL complex exhibited a significant negative connection with rim area ( $r = -0.283$ ,  $P = 0.028$ ) and disc area ( $r = -0.328$ ,  $P = 0.01$ ) in the current research. There was no association between average GCL complex and VA, IOP, or average CD. Minimum GCL complex had significant negative correlation with rim area ( $r = -0.272$ ,  $P = 0.036$ ) and disc area ( $r = -0.315$ ,  $P = 0.014$ ). There was no association between minimum GCL complex and VA, IOP, and average CD.

Similarly, **Nogueira et al. (2021)** <sup>(16)</sup> study results displayed that there was a significant association between GCC thickness and optic disc ( $p = 0.016$ ).

Also, **Bresciani-Battilana et al. (2015)** <sup>(24)</sup> reported that rim area showed the best correlation with average GCC ( $r = 0.583$ ).

Controversially, **Aydođan et al. (2020)** <sup>(25)</sup> found that average GCL complex had insignificant correlation with disc area but a significant negative correlation with rim area ( $p < 0.001$ ). Enrolling relatively higher number of patients with different diagnosis (glaucoma) along with different study design between both studies can provide a reasonable justification for this contradiction in results.

According to our results, papilledema grading had significant positive correlation with average RNFL thickness ( $r = 0.461$ ,  $P < 0.001$ ).

Compatible to our findings, **Beheiry et al. (2021)** <sup>(13)</sup> reported that papilledema grade showed a significant correlation with RNFL thickness ( $r = 0.590$ ,  $p < 0.001$ ).

Our results came in line with, **Labib et al. (2015)** <sup>(21)</sup> results displayed that the grade of papilledema significantly correlated with the average initial RNFL thickness.

Our results were in agreement with a recent study conducted by **Auinger et al. (2014)** <sup>(26)</sup> that has shown a significant positive correlation between grades of papilledema and peripapillary RNFL and total retinal thickness.

Moreover, **Nguyen et al. (2012)** <sup>(27)</sup> showed that total retinal thickness corresponds better with moderate papilledema grade than peripapillary RNFL thickness.

Our research has limitations, including a limited sample size, a lack of follow-up duration owing to the study design, and a single-center design.

### **Conclusion:**

There is a strong structure-function link between visual field indices and OCT parameters such as RNFL and GCC. These indicators reflect the severity of benign intracranial hypertension and may be used to monitor it. In clinical practise, RNFL thickness, GCL complex, MD, PSD, and VFI characteristics might provide further information. Further research with bigger patient cohorts is required to justify the use of GCC parameters in the assessment of BIH patients.

GCC measures are utilised clinically for the diagnosis, staging, and monitoring of BIH, assuming a high association between GCC and RNFL readings in this investigation.

### **Ethical Approval**

The research methodology adhered to the requirements of the Ethical Committee of the Faculty of Medicine at Tanta University Hospitals' Ophthalmology Department between December 2020 and November 2021.

### **Consent**

As per international standards or university standards, patient(s) written consent has been collected and preserved by the author(s).

### **Disclaimer**

**This paper is an extended version of a Thesis document of the same author.**

The Thesis document is available in this link:

[http://srv3.eulc.edu.eg/eulc\\_v5/Libraries/Thesis/BrowseThesisPages.aspx?fn=PublicDra  
wThesis&BibID=12982748](http://srv3.eulc.edu.eg/eulc_v5/Libraries/Thesis/BrowseThesisPages.aspx?fn=PublicDra<br/>wThesis&BibID=12982748)

**References:**

1. Kilgore KP, Lee MS, Leavitt JA, Mokri B, Hodge DO, Frank RD, et al. Re-evaluating the incidence of idiopathic intracranial hypertension in an era of increasing obesity. *Ophthalmology*. 2017;124(5):697-700.
2. Malhotra K, Padungkiatsagul T, Moss HE. Optical coherence tomography use in idiopathic intracranial hypertension. *Annals of eye science*. 2020;5.
3. Gantela Sirisha S, Chowdary NL. Evaluation of etiological factors and visual field defects in patients with papilloedema. *Vascular*. 2016;19:38.
4. Thurtell MJ. Idiopathic intracranial hypertension. *CONTINUUM: Lifelong Learning in Neurology*. 2019;25(5):1289-309.
5. Kedar S, Ghate D, Corbett JJ. Visual fields in neuro-ophthalmology. *Indian journal of ophthalmology*. 2011;59(2):103.
6. Ma D, Lu D, Heisler M, Dabiri S, Lee S, Ding GW, et al. Cascade Dual-branch Deep Neural Networks for Retinal Layer and fluid Segmentation of Optical Coherence Tomography Incorporating Relative Positional Map. *Proceedings of Machine Learning Research*. 2020;1:10.
7. Sikorski BL, Malukiewicz G, Stafiej J, Lesiewska-Junk H, Raczynska D. The diagnostic function of OCT in diabetic maculopathy. *Mediators of inflammation*. 2013;2013.
8. Ang M, Baskaran M, Werkmeister RM, Chua J, Schmidl D, Dos Santos VA, et al. Anterior segment optical coherence tomography. *Progress in retinal and eye research*. 2018;66:132-56.

9. Wang J-K, Kardon RH, Ledolter J, Sibony PA, Kupersmith MJ, Garvin MK. Peripapillary retinal pigment epithelium layer shape changes from acetazolamide treatment in the idiopathic intracranial hypertension treatment trial. *Investigative Ophthalmology & Visual Science*. 2017;58(5):2554-65.
10. Anand A, Pass A, Urfy MZ, Tang R, Cajavilca C, Calvillo E, et al. Optical coherence tomography of the optic nerve head detects acute changes in intracranial pressure. *Journal of Clinical Neuroscience*. 2016;29:73-6.
11. Bassi ST, Mohana KP. Optical coherence tomography in papilledema and pseudopapilledema with and without optic nerve head drusen. *Indian J Ophthalmol*. 2014;62(12):1146-51.
12. Rebolleda G, Muñoz-Negrete FJ. Follow-up of mild papilledema in idiopathic intracranial hypertension with optical coherence tomography. *Invest Ophthalmol Vis Sci*. 2009;50(11):5197-200.
13. Beheiry AS, El-Mohamady MN, Saeed AM, Zaghloul TM. Correlation between Automated Perimetry and Optical Coherence Tomography in Post Treatment Follow-up of Papilledema due to Idiopathic Intracranial Hypertension. *Benha Journal of Applied Sciences*. 2021;6(4):311-30.
14. Scott CJ, Kardon RH, Lee AG, Frisén L, Wall M. Diagnosis and grading of papilledema in patients with raised intracranial pressure using optical coherence tomography vs clinical expert assessment using a clinical staging scale. *Arch Ophthalmol*. 2010;128(6):705-11.
15. Rao A. Comparison of relation between visual function index and retinal nerve fiber layer structure by optical coherence tomography among primary open angle glaucoma and primary angle closure glaucoma eyes. *Oman J Ophthalmol*. 2014;7(1):9-12.

16. Nogueira PF, Caiado GC, Gracitelli CPB, Martins FM, Barros FCD, Matas SLDA, et al. Association between Optical Coherence Tomography Measurements and Clinical Parameters in Idiopathic Intracranial Hypertension. *Journal of Ophthalmology*. 2021;2021:1401609.
17. Vijay V, Mollan SP, Mitchell JL, Bilton E, Alimajstorovic Z, Markey KA, et al. Using Optical Coherence Tomography as a Surrogate of Measurements of Intracranial Pressure in Idiopathic Intracranial Hypertension. *JAMA Ophthalmology*. 2020;138(12):1264-71.
18. Athappilly G, García-Basterra I, Machado-Miller F, Hedges T, Mendoza-Santiesteban C, Vuong L. Ganglion Cell Complex Analysis as a Potential Indicator of Early Neuronal Loss in Idiopathic Intracranial Hypertension. *Neuro-Ophthalmology*. 2018;43:1-8.
19. Tieger MG, Hedges TR, 3rd, Ho J, Erlich-Malona NK, Vuong LN, Athappilly GK, et al. Ganglion Cell Complex Loss in Chiasmal Compression by Brain Tumors. *J Neuroophthalmol*. 2017;37(1):7-12.
20. Khalil D, Labib D. Correlation between optical coherence tomography parameters and retinal sensitivity in idiopathic intracranial hypertension. *Journal of the Egyptian Ophthalmological Society*. 2015;108(2):61-6.
21. Labib D, Abdel Raouf D. Diagnostic value of optical coherence tomography in patients with idiopathic intracranial hypertension. *The Egyptian Journal of Neurology, Psychiatry and Neurosurgery*. 2015;52(4):249-53.
22. Chen JJ, Thurtell MJ, Longmuir RA, Garvin MK, Wang J-K, Wall M, et al. Causes and prognosis of visual acuity loss at the time of initial presentation in idiopathic intracranial hypertension. *Investigative ophthalmology & visual science*. 2015;56(6):3850-9.

23. Huang-Link Y-M, Al-Hawasi A, Oberwahrenbrock T, Jin Y-P. OCT measurements of optic nerve head changes in idiopathic intracranial hypertension. *Clinical Neurology and Neurosurgery*. 2015;130:122-7.
24. Bresciani-Battilana E, Teixeira IC, Barbosa DT, Caixeta-Umbelino C, Paolera MD, Kasahara N. Correlation between the ganglion cell complex and structural measures of the optic disc and retinal nerve fiber layer in glaucoma. *Int Ophthalmol*. 2015;35(5):645-50.
25. Aydoğan T. Correlation Between Retinal Nerve Fiber Layer, Optic Nerve Head and Macular Parameters and Structure Function Relationship in Glaucoma. *Journal of Glaucoma and Cataract*. 2020.
26. Auinger P, Durbin M, Feldon S, Garvin M, Kardon R, Keltner J, et al. Baseline OCT measurements in the idiopathic intracranial hypertension treatment trial, part II: correlations and relationship to clinical features. *Invest Ophthalmol Vis Sci*. 2014;55(12):8173-9.
27. Nguyen A, Balmitgere T, Bernard M, Tilikete C, Vighetto A. Detection of mild papilloedema using spectral domain optical coherence tomography. *British journal of ophthalmology*. 2012;96(3):375-9.