

## Case report

### Cranial vault metastasis revealing a prostate cancer

#### Abstract

The skull serves as a frequent site for metastasis from systemic malignant tumors. Predominantly, prostate, breast, and lung cancers constitute the primary sources of cranial metastases, collectively accounting for over 70% of secondary skull tumors. These occurrences often target the base of the skull. While calvarial metastases typically remain asymptomatic, skull-base metastases tend to provoke significant symptoms. Their diagnosis is primarily reliant on CT and MRI imaging. The prognosis of individuals with secondary metastasis from prostate cancer hinges on the extent of disease spread. In this report, we present a case involving a 67-year-old man who developed a sizable metastatic lesion on the skull vault, uncovering underlying prostate cancer. The patient was effectively treated through surgical intervention.

**Key words:** skull metastasis; skull tumors; prostate adenocarcinoma

#### Introduction

The cranium is a common metastatic site from systemic malignancies, as described in 1889 by Paget, who reported skull metastases (SM) in 30 of 60 post-mortem examinations of breast cancer patients. Breast carcinoma is the first cause of SM in women, while prostate cancer (PCa) is the leading cause in men [1]. and: it often affects the base of the skull. Calvarial metastases are mostly asymptomatic. On the other hand, skull-base metastases are very symptomaticsymptomatic, their diagnosis is based on CT and MRI. The prognosis of patients with SM from PCa depends on the extent of disease dissemination. We present a case report report a case of a large skull vault metastatic lesion revealing prostate cancer in a 67-year-old man, successfully treated by surgery.

#### Case presentationreport

We report a case of He is a 67-year-old individual without any notable medical history. He presented to our medical service with a sizable mass in the median frontal region (Fig.1). The mass had a firm consistency, was non-tender to touch, and exhibited no mobility in relation to both the surface and deep layers. The skin above the mass displayed no signs of inflammation or other abnormalities. The restemainder of the physical examination revealed no significant findings. Radiological assessments revealed a large tissue lesion located in the median frontal area of the skull, displaying lytic features and infiltrating the superior longitudinal sinus (Fig.2).

Further biological evaluation indicated an elevated total PSA level. Subsequent ultrasound and prostate biopsy were conducted, leading to a diagnosis of prostatic adenocarcinoma. Thoraco-abdominal CT scan and scintigraphy did not reveal any additional secondary sites of prostate cancer (PCa). Consequently, the patient underwent a surgical procedure involving subtotal excision of the lesion followed by cranioplasty. The results of the pathological examination confirmed the presence of

**Commented [u1]:** I suggest to include the article written by Paget in the references list and also to cite it by indicating the the reference number in brackets.

metastatic prostate adenocarcinoma. The patient was subsequently referred to the oncology department for further management.

## Discussion

Similar to other bones in the body, the skull is susceptible to tumor metastasis. Predominantly, prostate, breast, and lung cancers are the primary contributors to cranial metastases, constituting over 70% of secondary skull tumors [2]. Prostate cancer (PCa) has an established pattern of metastasis, often affecting nearby lymph nodes and the axial skeleton [3]. In a retrospective study, it was observed that 20% of patients with secondary metastasis from PCa exhibited no additional metastatic sites [4].

Secondary lesions in the skull arise due to the dissemination of cancer cells through the bloodstream. In the context of prostate cancer (PCa), these lesions occur as a consequence of retrograde seeding facilitated by Batson's valveless venous plexus. This anatomical network connects the pelvic structures to the skull via the epidural and dural veins [5].

Calvarial metastases typically remain asymptomatic until they breach the dura mater, exert pressure on dural sinuses, or form a mass significant enough to induce cosmetic concerns, as observed in our case [6]. Conversely, metastases to the skull base often lead to gradual involvement of cranial nerves on the same side, pain, or heightened intracranial pressure, resulting in diminished quality of life (QoL). There are five notable syndromes linked to specific metastatic sites: the orbital, para-sellar, middle-fossa, jugular foramen, and occipital condyle syndromes [4]. The presence of any skull swelling without an apparent cause in men over 60 years of age should raise suspicions of prostate cancer [4]. According to Starc et al., secondary skull tumors usually present with a rapid onset and tend to be less painful [7]. Urinary symptoms may not be evident, and clinical manifestations may not readily indicate the primary source of the tumor. In our case, the patient did not exhibit urological symptoms during presentation. Enhanced MRI with contrast stands out as the most sensitive diagnostic tool, particularly for identifying and analyzing osteoblastic lesions and soft tissue components. On the other hand, CT scans are particularly effective in assessing lytic bone lesions. However, when it comes to detecting dural invasion, MRI exhibits superior accuracy compared to CT scans [8].

Surgical intervention is typically straightforward, encompassing the complete removal of the lesion along with subsequent cranioplasty. However, there are instances where total excision might not be feasible, leading to the consideration of radiotherapy as an alternative treatment option [9].

The prognostic outlook for patients with secondary metastasis (SM) from prostate cancer hinges on the extent of disease spread, with a median survival period of 21 months [8]. Those who present with symptoms tend to have a more unfavorable prognosis, experiencing an average survival of only 5 months following cranial nerve involvement [10].

## Conclusion

The occurrence of skull swelling can be an uncommon manifestation of prostate cancer. Any sudden and notable increase in skull swelling in a male aged 60 or above should trigger suspicion regarding potential hidden prostate cancer. It is imperative to actively investigate the possibility of skull metastasis in all patients with advanced prostate cancer.

## References :

Commented [u2]: I recommend to read again the general guidelines for authors and to respect the requirements for the reference style. I strongly suggest to use more recent references.

1. Long MA, Husband JE. (1999) Features of unusual metastases from prostate cancer. *Br J Radiol.* 1999;72:933-941.
2. Mitsuya K, Nakasu Y, Horiguchi S, Harada H, Nishimura T, Yuen S, Asakura K, Endo M. Metastatic skull tumors: MRI features and a new conventional classification. *J Neurooncol.* 2011;104:239-245. 2011
3. Rubin MA, Putzi M, Mucci N, Smith DC, Wojno K, Korenchuk S, Pienta KJ. Rapid ("warm") autopsy study for procurement of metastatic prostate cancer. *Clin Cancer Res.* 2000;6:1038-1045. 2000.
4. Greenberg HS, Deck MD, Vikram B, Chu FC, Posner JB. Metastasis to the base of the skull: clinical findings in 43 patients. *Neurology.* 1981;31:530-537. 1981.
5. Castaldo JE, Bernat JL, Meier FA, Schned AR. Intracranial metastases due to prostatic carcinoma. *Cancer.* 1983;52:1739-1747. 1983.
6. Michael CB, Gokaslan ZL, DeMonte F, et al. Surgical resection of calvarial metastases overlying dural sinuses. *Neurosurgery* 2001; 48: 745-55.
7. Stark AM, Eichmann T, Mehdorn HM. (2003) Skull metastases: Clinical features, differential diagnosis, and review of the literature. *Surg Neurol.* 2003;60:219-225.
8. Laigle-Donadey F, Taillibert S, Martin-Duverneuil N, Hildebrand J, Delattre JY. Skull-base metastases. *J Neurooncol.* 2005;75:63-69. 2005.
9. E. G. Clair EG, and I. E. McCutcheon IE. Skull tumors, in *Youmans Neurological Surgery*, H. R. Winn and R. Julian, Eds., Saunders, Philadelphia, Pa, USA, 2011.
10. Ransom DT, Dinapoli RP, Richardson RL. Cranial nerve lesions due to base of the skull metastases in prostate carcinoma. *Cancer.* 1990;65:586-589. 1990.

Formatted: English (United States)

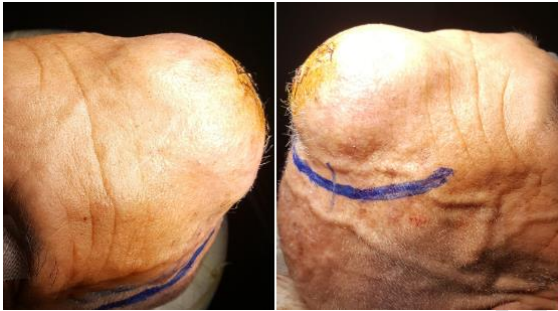Formatted: English (United States)

Formatted: English (United States)

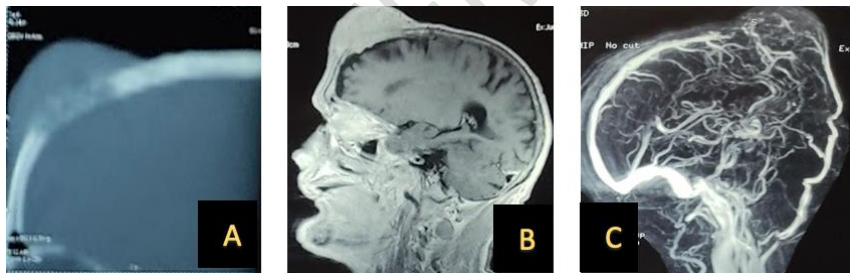
Formatted: English (United States)

Formatted: English (United States)

UNDER PEER REVIEW



**Figure 1:** pictures showing a sizable mass in the medial frontal region



**Figure 2:** A= cranial CT scan in sagittal section and bone window showing a lytic frontal lesion  
B= Brain MRI in sagittal section and in T1 sequence after taking contrast medium showing an —extra axial frontal lesion taking up the contrast  
C= Cerebral angio-MRI in venous phase showing the disappearance of the signal from the superior longitudinal sinus