

A novel approach to a rare case of Fournier's gangrene involving the space of Retzius

ABSTRACT

Fournier's gangrene is a type of necrotizing fasciitis involving the perineal, perianal or genital area that is rapidly progressive and life-threatening. Treatment involves urgent surgical debridement as well as antibiotic therapy. We report a rare case of Fournier's gangrene of the perianal region which extended up the left pararectal and paravesical space to involve the space of Retzius. This was managed in a novel and minimally invasive approach which avoided the need for a laparotomy and its associated morbidity.

Keywords: Fourniers, Retzius, Minimally, invasive

INTRODUCTION

Necrotizing fasciitis and Fournier's gangrene are rare but rapidly progressive, life-threatening bacterial infections that can destroy the epidermis, dermis, subcutaneous tissue, fascia, and muscle [1-4]. Necrotizing fasciitis has been shown to be strongly associated with diabetes, chronic alcoholism, human immunodeficiency virus (HIV), lympho-proliferative diseases, chronic steroid abuse and cytotoxic drugs [5]. Initial urgent management of necrotizing fasciitis relies on broad-spectrum antibiotic therapy, rapid surgical debridement of all infected tissues [6] and, when present, treatment of associated organ failures in the intensive care unit. Mortality ranges from 10 to 30% according to initial severity of disease, and morbidity among survivors can result in profound impact on long-term health-related quality of life [7-9].

PRESENTATION OF CASE

A 40 year old Indian male foreign worker with a past medical history of poorly controlled diabetes mellitus (HbA1c 12%) who presented to the emergency department a week prior for a right perianal abscess. Due to financial concerns, he declined surgical drainage and was discharged against medical advice. He subsequently represented to the emergency department a week later with a fever of 39.2°C, worsening perianal pain and new onset lower abdominal pain. His LRINEC [10] (laboratory risk indicator for necrotizing fasciitis) score was 9 based on his initial blood investigations which was highly suggestive of necrotizing fasciitis.

Hemoglobin	12 g/dL
White blood cell Count	23.2 (x10,000/ μ L)
C-reactive protein	385.2 mg/L
Sodium	127 mmol/L
Creatinine	116 μ mol/L
Glucose	16.1 mmol/L

Table 1: initial blood investigations

A CT abdomen and pelvis was also performed in view of the lower abdominal pain showing extensive air and stranding in the perineum which extended up the left pararectal and paravesical space into retzius space.

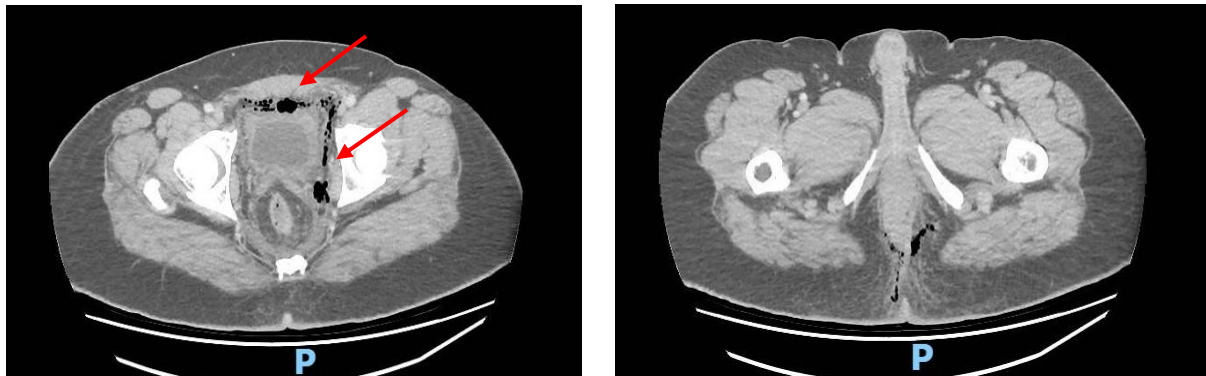


Figure 1: Axial CT images showing air in the perineal space bilaterally as well as air in the left pararectal/paravesical and retzius space.

He was started on intravenous Piperacillin-tazobactam (4.5g q8hly) and clindamycin (900mg q8hly) and brought to theater for urgent surgical intervention. Intraoperatively, he was found to have extensive necrotic tissue and copious amounts of pus involving his perineum. He also underwent drainage of his left pararectal and paravesical space and a drain was inserted to the left pararectal and paravesical spaces to facilitate daily irrigation.

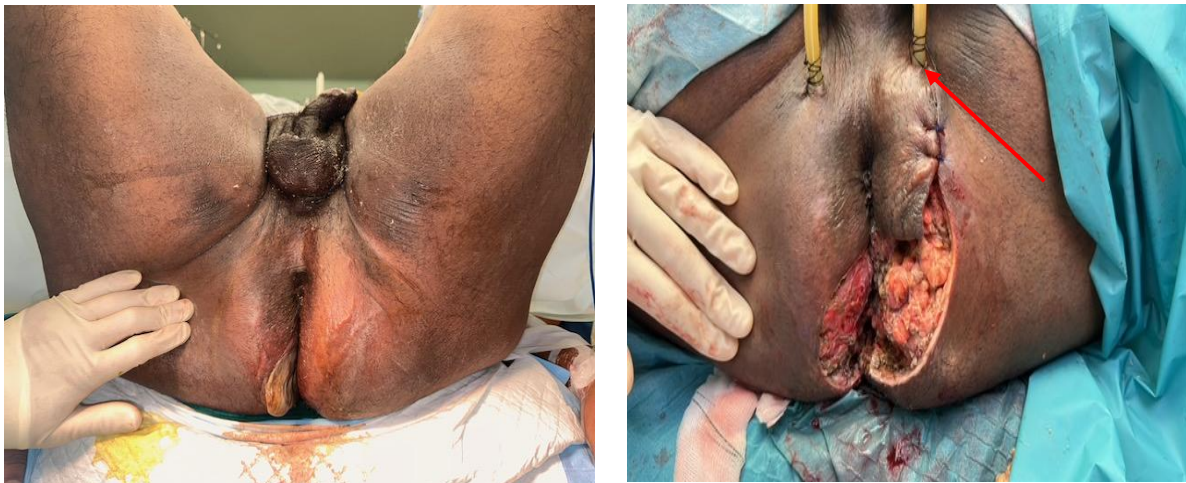

Figure 2: Showing extensive perineal debridement and drains being inserted into his left pararectal space as indicated by the arrow.

In order to address the infection in retzius space, we performed laparoscopic drainage and debridement of retzius space using a spacemaker balloon which was inserted into the preperitoneal space in a fashion similar to performing an extra-peritonealinguinal hernia repair. Intra-operatively, the space maker balloon was inserted into the pre-peritoneal space via an infraumbilical incision and insufflated under direct vision. After removal of the space maker balloon, 2 additional 5mm working ports were inserted in the right mid clavicular line to facilitate debridement and drainage. The choice to place the ports on the right side was because the patient would eventually require an interval sigmoid colostomy in the left iliac fossa. Intra-operatively, 20 mls of pus was aspirated and sent for culture. Necrotic fat was also debrided and a 19 Fr drain was inserted into the retzius space.

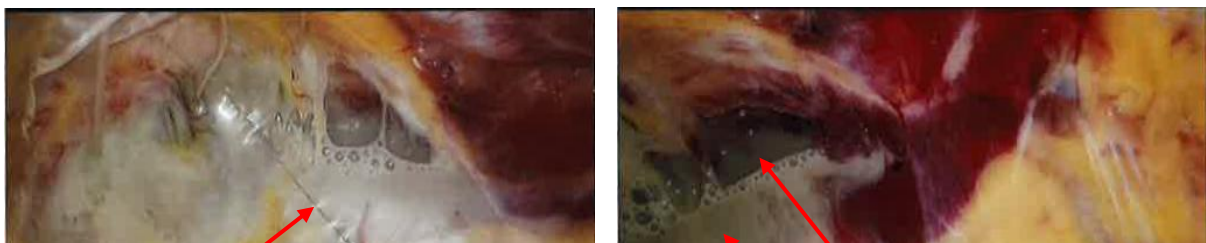


Figure 3: intraoperative pictures demonstrating pus and necrotic tissue in retzius space

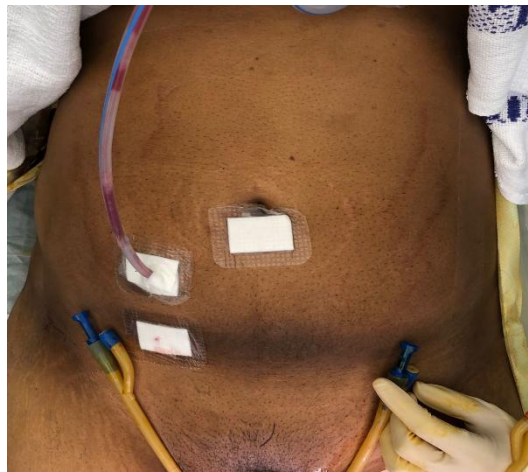


Figure 4: Post operative wound

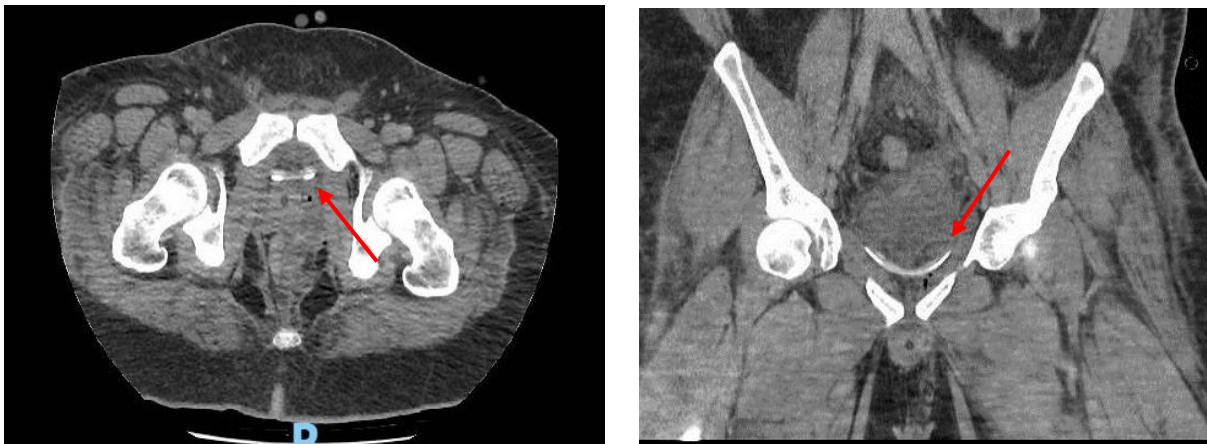


Figure 5: Axial and coronal CT images showing 19 Fr drain placed into retzius space.

Intra operative cultures from the pus and tissue from the perineum and Retzius space, both grew similar organisms which included Streptococcus constellatus, Streptococcus anginosus as well as Escherichia coli. These were sensitive to Piperacillin-tazobactam and consistent with type 1 necrotizing fasciitis[1].

The patient subsequently underwent multiple debridement's until there was no residual necrotic tissue or pus. A sigmoid colostomy was also subsequently created to help control fecal contamination into the perineal wound. An interval CT was performed which showed resolution of fluid collections in retzius, the pararectal, paravesical and prevesical spaces before his drains was removed. The patient required multiple cycles of vacuum-assisted closure and eventually underwent partial closure and split skin grafting of his perineal wound by a plastic surgeon and his colostomy was reversed 3 months later, after his perineal wound had completely healed over.

DISCUSSION

Fournier's gangrene is a specific form of necrotizing fasciitis involving the external genitalia, as well as the perianal region. Named after Dr. Alfred Fournier, the French dermatology and venereal specialist, it was initially described in 1883 as necrotizing fasciitis of the external genitalia, perineal, and perianal region in five of Dr. Fournier's patients[11]. It can be associated with manifestations of severe toxicity and multiple organ failure[12]. Early recognition, initiation of surgical debridement and appropriate antibiotic therapy is the key to treatment. Delays in treatment can result in high lethality rates of 90%, due to the development of septic shock and its associated complications[13].

Although the diagnosis of Fournier gangrene is primarily clinical, it may be assisted by a combination of both blood work and imaging (CT/MRI). To aid in the early identification of high-risk patients at an early stage and to be able to use an objective parameter to assess the severity of the disease[20], Wong et al developed the LRINEC score in 2004[10]. Wong et al themselves viewed the LRINEC score as a robust scoring system that can even detect early cases of necrotizing fasciitis although other studies show insufficient sensitivity[14,15,16]. An alternative to this scoring system is the one published by Harasawa et al which was recently established to enhance the sensitivity, specificity, and especially the negative prognostic value, compared with the LRINEC score[17]. Regardless of scoring systems, clinicians must still maintain a high index of suspicion for any inflammatory or infectious process involving the perineum or genitalia, particularly in older male diabetics and others at increased risk, as these scoring systems serve only as adjuncts with simultaneous consideration of all clinical parameters.

An understanding of the avascular spaces of the pelvis is also essential in aiding the surgical management of the patient. In general, there are 8 avascular spaces in the pelvis which can be divided into 2 paired lateral spaces and 4 midline spaces. The 2 lateral spaces are the pararectal and paravesical spaces while the midline spaces are the retrorectal, rectouterine, vesicouterine and prevesical spaces (Retzius space)[18].

In this patient, the infection spread from the right Ischio-rectal space into the left ischio-rectal space via the superficial postanal space, then up the pararectal space, up towards the paravesical space and finally into the prevesical space. As it was not possible to debride the prevesical space from the perineum, we elected to attempt a laparoscopic approach to access the preperitoneal space which is continuous with the prevesical space to help avoid the need for a large laparotomy wound. Using a spacemaker balloon which was inserted via an infraumbilical incision, we successfully drained and debrided the preperitoneal and prevesical spaces.

To our knowledge, there has only been 1 reported case of laparoscopic management of necrotising fasciitis of unique abdominal spaces. This was a case that was reported by Monerh et al involving the retroperitoneum[19]. However, there has not been any previously reported cases of severe Fournier's gangrene which has extended into the prevesical space, nor has there been any prior published laparoscopic approach to debridement of necrotizing fasciitis of retzius space

CONCLUSION

Fournier's gangrene is a rare and rapidly progressing condition that can be fatal. Early diagnosis, antibiotic therapy and surgical debridement are the fundamentals of management. Laparoscopy is a feasible option in young individuals to help reduce surgical morbidity from a laparotomy. The benefits of minimally invasive approach should be weighed against the level of experience of the surgical team in ensuring proper debridement and the clinic status of the patient.

COMPETING INTERESTS

The authors declare they have no competing interests.

CONSENT

Consent was taken from the patient for pictures and use of medical data for case report.

Ethical Approval:

As per international standards or university standards written ethical approval has been collected and preserved by the author(s).

REFERENCES

1. Stevens DL, Baddour LM. *Necrotizing soft tissue infections*. UpToDate. 2020. www.uptodate.com.
2. Wang J-M, Lim H-K. Necrotizing fasciitis: eight-year experience and literature review. *Braz J Infect Dis*. 2014;18(2):137–143. [[PMC free article](#)] [[PubMed](#)] [[Google Scholar](#)]
3. Stevens DL, Bryant AE. Necrotizing soft-tissue infections. *N Engl J Med*. 2017;377(23):2253–2265. [[PubMed](#)] [[Google Scholar](#)]
4. Wessels MR. Streptococcal infections. In: Longo DL, Fauci AS, Kasper DL, Hauser SL, Jameson JL, Loscalzo J, eds. *Harrison's Principles of Internal Medicine*. 18th ed. New York, NY: McGraw-Hill; 2012:1176. [[Google Scholar](#)]
5. Pastore AL, Palleschi G, Ripoli A, et al. A multi-step approach to manage Fournier's gangrene in a patient with unknown type II diabetes: surgery, hyperbaric oxygen, and vacuum assisted closure therapy: a case report. *J Med Case Rep*. 2013;7:1.
6. Nawijn F., Smeeing D.P.J., Houwert R.M., Leenen L.P.H., Hietbrink F. Time Is of the Essence When Treating Necrotizing Soft Tissue Infections: A Systematic Review and Meta-Analysis. *World J. Emerg. Surg*. 2020;15:4. doi: 10.1186/s13017-019-0286-6.
7. Urbina T., Hua C., Sbidian E., Bosc R., Tomberli F., Lepeule R., Decousser J.-W., Mekontso Dessap A., Chosidow O., de Prost N., et al. Impact of a Multidisciplinary Care Bundle for Necrotizing Skin and Soft Tissue Infections: A Retrospective Cohort Study. *Ann. Intensive Care*. 2019;9:123. doi: 10.1186/s13613-019-0598-4.
8. Urbina T., Canoui-Poitrine F., Hua C., Layese R., Alves A., Ouedraogo R., Bosc R., Sbidian E., Chosidow O., Dessap A.M., et al. Long-Term Quality of Life in Necrotizing Soft-Tissue Infection Survivors: A Monocentric Prospective Cohort Study. *Ann. Intensive Care*. 2021;11:102. doi: 10.1186/s13613-021-00891-9.
9. Hua C., Sbidian E., Hemery F., Decousser J.W., Bosc R., Amathieu R., Rahmouni A., Wolkenstein P., Valeyrie-Allanore L., Brun-Buisson C., et al. Prognostic Factors in Necrotizing Soft-Tissue Infections (NSTI): A Cohort Study. *J. Am. Acad. Dermatol*. 2015;73:1006–1012.e8. doi: 10.1016/j.jaad.2015.08.054.
10. Wong CH, Khin LW, Heng KS et al.. The LRINEC (laboratory risk indicator for necrotizing fasciitis) score: a tool for distinguishing necrotizing fasciitis from other soft tissue infections. *Crit Care Med* 2004; : 1,535–1,541.
11. Carroll PR, Cattolica EV, Turzan CW, McAninch JW. Necrotizing soft-tissue infections of the perineum and genitalia. Etiology and early reconstruction. *West J Med*. 1986 Feb;144(2):174-8.
12. Aliev SA, Rafiev SF, Rafiev FS, Aliev ES. Fournier's disease in surgeon practice. *Surgery J n.a. N.I.Pirogov*. 2008;11:58–63.
13. Ephimenko NA, Privolnee VV. Fournier's gangrene. *Clin Microbiol Antimicrob Chemother*. 2008;10:25–34.
14. Hsiao C.-T., Chang C.-P., Huang T.-Y., Chen Y.-C., Fann W.-C. Prospective Validation of the Laboratory Risk Indicator for Necrotizing Fasciitis (LRINEC) Score for Necrotizing Fasciitis of the Extremities. *PLoS ONE*. 2020;15:e0227748. doi: 10.1371/journal.pone.0227748.
15. Bansal N., Garg N. Evaluation of Laboratory risk indicators (LRINEC Score) for early diagnosis and prognosis in necrotizing fasciitis. *Surg. Update Int. J. Surg. Orthop*. 2020;6:181–188. doi: 10.17511/ijoso.2020.i03.07.

16. Bechar J., Sepehripour S., Hardwicke J., Filobos G. Laboratory risk indicator for necrotising fasciitis (LRINEC) score for the assessment of early necrotising fasciitis: A systematic review of the literature. *Ann. R. Coll. Surg. Engl.* 2017;99:341–346. doi: 10.1308/rcsann.2017.0053.
17. Harasawa T., Kawai-Kowase K., Tamura J., Nakamura M. Accurate and quick predictor of necrotizing soft tissue infection: Usefulness of the LRINEC score and NSTI assessment score. *J. Infect. Chemother.* 2020;26:331–334. doi: 10.1016/j.jiac.2019.10.007.
18. Laparoscopic Pelvic Anatomy—Series Two—The 8 Avascular Spaces. C. Nezhat, F. Nezhat, C. Nezhat, N. Lashay, M. Marzi. Center for Minimally Invasive Surgery, Palo Alto, CA
19. Successful Laparoscopic Management of Retroperitoneal Necrotizing Fasciitis: A Case Report Monerh Bin Mosa, Ali Alyami, Saad Abumelha, and Ali Alzahrani
20. The LRINEC Score – An indicator for the Course and Prognosis of Necrotizing Fasciitis? Vanessa Hoesl, Sally Kempa, Lukas Prantl, Kathrin Oschsenbauer, Julian Hoesl, Andreas Kehrer, Talia Bosselmann *J Clin Med.* 2022 Jul; 11(13): 3583. Published online 2022 Jun 22. doi: 10.3390/jcm11133583 PMCID: PMC9267597 PMID: 35806870

