

Original Research Article

Evaluation of functional outcome of arthroscopic capsular release in adhesive capsulitis (frozen shoulder)- A research study from North India

ABSTRACT:

Introduction: Frozen shoulder is a disabling and painful condition that is commonly managed in the primary care setting. Frozen shoulder has a protracted natural history that usually ends in resolution. It is a condition characterised by functional restriction of both active and passive shoulder motion for which radiographs of the glenohumeral joint are essentially unremarkable except for the possible presence of osteopenia or calcific tendonitis.

Aims & Objectives: To evaluate the functional outcome of arthroscopic release of capsule in adhesive capsulitis (frozen shoulder).

Materials & methods: A prospective study conducted on patients diagnosed as having frozen shoulder. A total of 25 patients were taken who underwent Arthroscopic capsular release.

Results: The mean forward elevation improved from 100.52 to 156.60 at final follow up. Mean abduction improved from 97.12 to 156.36 at final follow up. Mean external rotation 32.76 to 38.96 at final follow up. Mean internal rotation 18.88 to 37.0 at final follow up. The mean UCLA score improved from 13.16 to 32.16 at final follow. Excellent results were seen in 12 patients (48%), Good in 8 patients (32%), Fair in 4 patients (16%) and Poor in 1 patient (4%).

Conclusion: Arthroscopic release of capsule in frozen shoulder (adhesive capsulitis) is a safe and effective procedure with very few complications. It gives further advantage of evaluating any glenohumeral joint and subacromial pathology & rapid rehabilitation is possible in comparison to open procedures.

Keywords: Frozen shoulder, Arthroscopic release, Internal rotation, Calcific tendonitis

INTRODUCTION

Frozen shoulder is a disabling and painful condition that is commonly managed in the primary care setting. Frozen shoulder has a protracted natural history that usually ends in resolution.¹ Adhesive capsulitis is characterised by gradual increase in stiffness and pain.^{2,3,4} Adhesive capsulitis has a prevalence ranging from 2% to 5% in orthopedic clinics. The etiology of the condition is unknown. Women are affected more than men, and the peak age at onset is about 55 years (although this may range anywhere from 35 to 70 years).⁵ Although frozen shoulder has been considered a self-limiting condition on the basis of the natural history, some patients show little or no improvement, with residual limited ROM and continuing symptoms, even after a few years of conservative management.⁶ Evidence suggests that the underlying pathologic changes in adhesive capsulitis are synovial inflammation with subsequent reactive capsular fibrosis. Initial management with either benign neglect, supervised neglect, home stretching exercises, or physical therapy generally results in good outcomes; however, studies have shown that some residual deficits may remain.⁷ Surgical interventions mainly target the release of the thickened joint capsule, as it connects the humerus and glenoid.⁸ Arthroscopic release is an option when closed manipulation fails or for patients who have had prolonged, recalcitrant adhesive capsulitis, with marked improvement reported in 80% to 90% of patients.⁶ Arthroscopic capsular release has been purported to allow a more controlled release of the capsular restraints, and therefore decrease the possibility of iatrogenic proximal humerus fracture or rotator cuff tear, which are the potential complications associated with manipulation under anesthesia (MUA). Care must be taken to avoid damage to the axillary nerve traversing immediately inferior to the contracted inferior capsule.⁷ This study was done to evaluate the functional outcome of arthroscopic release of capsule in adhesive capsulitis (frozen shoulder).

Comment [A1]: Duplicate content is in the abstract of the article.

Comment [A2]: The references are old, please use the new ones.

Comment [A3]: The first time, the full phrase must be used: Range of motion (ROM)

Comment [A4]: Please use scientific materials.

Comment [A5]: "Studies" is mentioned, but only one study is referenced.

Formatted: Highlight

Formatted: Highlight

Comment [A6]: What is the gap of this study?

Comment [A7]: It is not written based on scientific principles. The process of the introduction is as follows:

- A summary of the problem, work methods, limitations and the reason for conducting the study
- Use up-to-date articles
- The use of scientific words, not slang

MATERIALS & METHODS

The present study was conducted in Post graduate Department of Orthopaedics, Govt. Hospital for Bone and Joint Surgery, an associated hospital of Govt. Medical College Srinagar, following approval by institutional ethical committee from August 2018 to September 2019. It was a prospective study conducted on patients diagnosed as having frozen shoulder irrespective of their age and fulfilling the inclusion criteria for the study. A total of 25 patients were taken who underwent Arthroscopic capsular release.

Inclusion criteria:

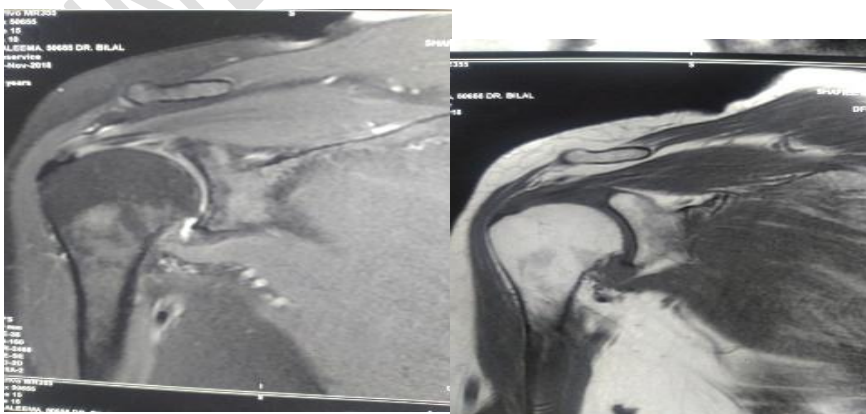
Patients upto 70 years of age, both males and females, failure of conservative treatment modalities for a period of 6 months and post traumatic stiffness were included.

Exclusion criteria:

Medically comorbid patients, patients with active joint infection and Joint instability, MRI documented or arthroscopic findings suggestive of major concomitant pathology like rotator cuff tear, Cervical radiculopathy, Cerebro-vascular accident, Neurological disorders, Humerus fracture or dislocation were excluded from the study.

Procedure:

Patients were evaluated clinically, radiographically and followed by MRI Fig 1(a),(b)& (c) to confirm frozen shoulder.



Comment [A8]: The type of study should be stated in the first sentence.

Comment [A9]: Completing the informed consent form is not mentioned.

Comment [A10]: The ethical approved number is not mentioned.

Formatted: Highlight

Comment [A11]: Please mention the age range of the study subjects.

Comment [A12]: What study (studies) is (are) the inclusion and exclusion criteria based on? It has no reference.

Fig. 1(a) & 1(b).1a showing obliteration of axillary recess& 1b showing thickening of inferior capsule.

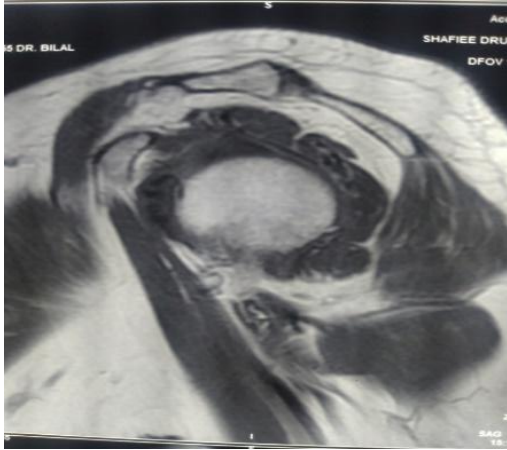


Fig.1 (c): coronal image show thickening if the Coracohumeralligament

Written informed consent from the patient was taken after properly explaining to him/her the procedure and its associated benefits and risks, in patient's own language. Pre **operative** antibiotic prophylaxis (Inj. Cefuroxime 50 mg/kg iv) was given one hour before surgery. Hypotensive general anaesthesia was used (to control bleeding), with systolic pressure generally being around 100mg.

Positioning and setup

The patient was placed under general anaesthesia for the operative procedure. The patient was placed supine on the operating table in the lateral decubitus position. In lateral decubitus position the patient was rotated approximately 15 to 20 degrees posteriorly from lateral to make the glenoid parallel to the floor.

Comment [A13]: In the first part, the implementation method should be mentioned.

Formatted: Highlight

Comment [A14]: Because the abbreviation is used in the rest of the article, in the first reference after the full phrase, the abbreviation should be given in parentheses.

Comment [A15]: No reference is used in this section, please revise it.

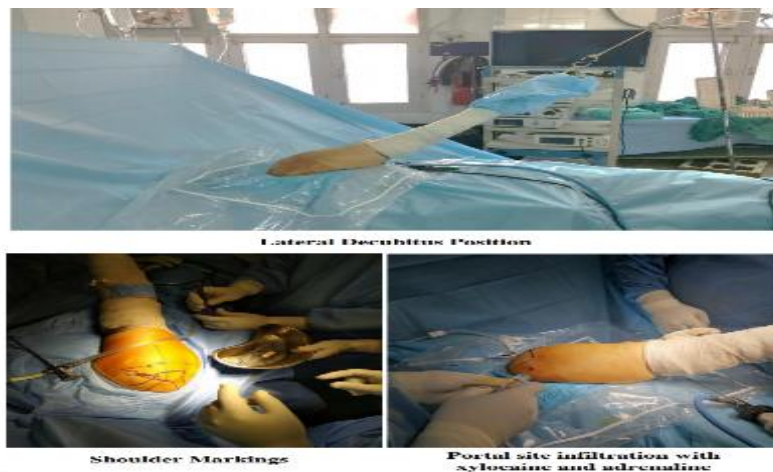

Fig: (2).Positioning of the patient& Portals used for shoulder arthroscopy

A well-padded axillary roll 2 finger breadths were placed. The peroneal nerve at the proximal fibula was well padded. The abduction pulley or pole was placed in such a position that the operating arm was in approximately 40 to 50 degrees of abduction and 15 degrees forward flexion (Fig.2). A standard method of draping the shoulder for arthroscopy was used. Epinephrine was added to the fluid bags to aid with haemostasis. Each 3 litre had 1 ampoule of 1:1000 concentration epinephrine added.

Instrumentation

The instrument which were used during the procedure included, a 4.5 mm or 5.5 mm shaver necessary for debridement of soft tissues, 5.5 mm of round or oval burr utilized for bone excision, unipolar or bipolar device was utilised for soft tissue debridement and haemostasis, 30 degree lens is used for subacromial visualisation and a 4 mm and 6mm cannula necessary for outflow.

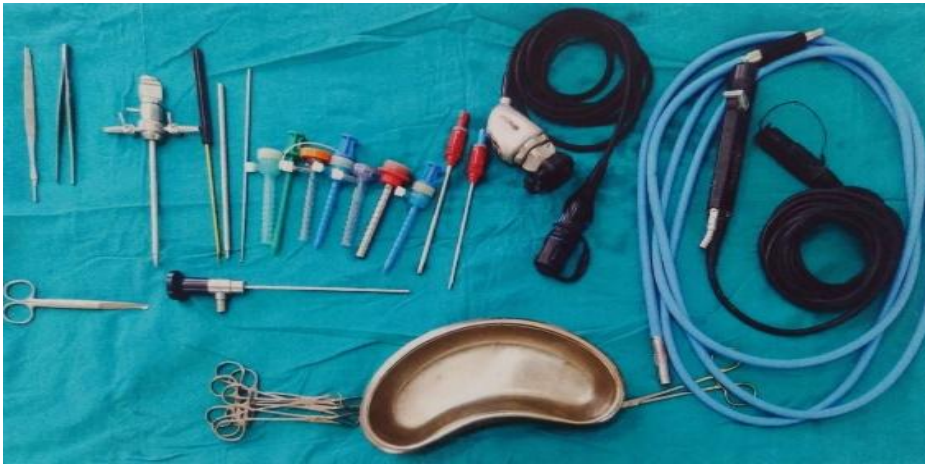

Fig: (3) Instrumentations used

Surgical technique

The shoulder was widely prepared and draped well medial to the coracoids anteriorly and to the medial scapular border posteriorly. The entire arm was prepared. All pertinent anatomy was drawn out on the patient's skin with a marker including the acromion, the clavicle, the AC joint and the coracoid process. The portal locations were also drawn on the shoulder. These included posterior, lateral and anterior portals. All portals were injected with a solution containing 0.5% xylocaine with epinephrine before the procedure to prevent excessive bleeding. To provide adequate haemostasis, the systolic blood pressure was maintained around 100mm Hg if medically permissible. An 18-gauge spinal needle was inserted into the joint and insufflated (usually 10 to 15 mL in a contracted joint) with sterile saline. Entry into the joint was confirmed by noting backflow of saline from the spinal needle. This step ensures proper portal placement and also distends the joint, thus lessening the risk of iatrogenic articular injury. An incision was made where the needle was inserted using a no. 11 blade, and

the arthroscope sheath was advanced into the gleno-humeral joint.

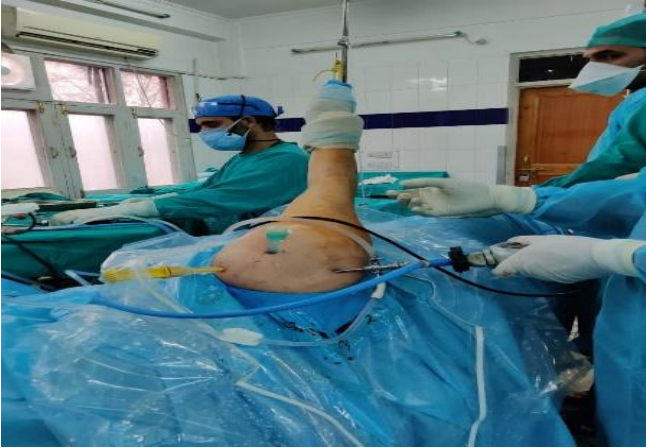

Fig. (4). Demonstration of Three portals- Anterior Posterior & Lateral

Entry into the joint is confirmed with backflow of saline through the sheath. With the arthroscope posteriorly, a spinal needle was inserted lateral to the coracoid through the rotator interval immediately underneath the biceps and above the subscapularis. An incision was made with a no. 11 blade and a 6-mm cannula is then placed through this portal. A radiofrequency device was passed through the cannula and used to remove synovium and soft tissue that obscured the view. The opening in the capsule was created with the regular radiofrequency device.

Anterior Capsular Release

Resection of contracted and thickened capsule (Fig. 5) was done with a radiofrequency device, shaver, or arthroscopic punch. Radiofrequency device was preferably used to avoid bleeding, resect in a controlled fashion, and benefit from the feedback of electrical stimulation to

nearby muscles and nerves. The resection of the anterior capsule was done systematically.

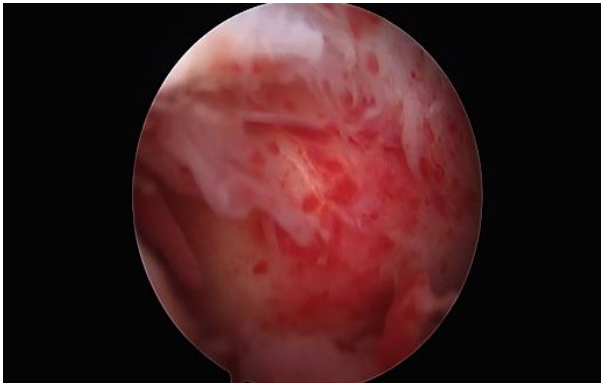


Fig: 5 .Thick Rotator cuff interval with congested capsule

The rotator interval capsule was noted between the biceps superiorly and the intra-articular subscapularis inferiorly. This comprises the superior glenohumeral and coracohumeral ligaments, started by cutting (ablating) the capsular tissue immediately inferior to the biceps tendon. The capsular tissue was released inferiorly until the superior border of the subscapularis was identified, thus releasing the rotator interval and its contents.

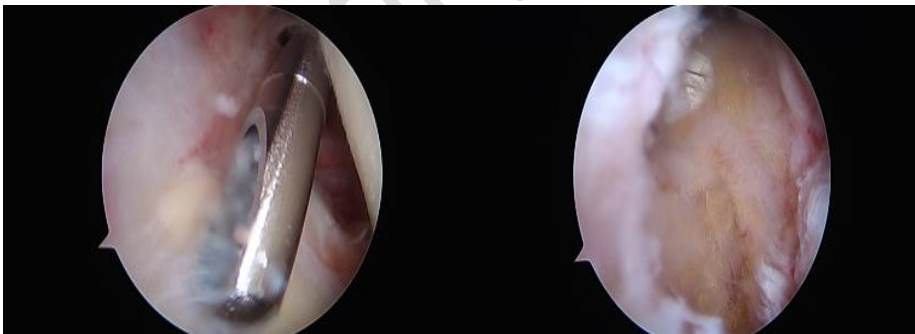

Fig. 6a & 6b: Rotator cuff interval release with shaver and Fig. 6b with released Rotator cuff interval

Further capsule from the deep surface of the subscapularis was dissected to create a defined interval. This capsule represents the middle glenohumeral ligament. The capsule overlying the subscapularis was then divided to the 6 o'clock position. Gentle external rotation was done to place the capsule under additional tension and facilitate its resection and the axillary nerve risk was prevented by staying close to the labrum and seeing for subscapularis

muscle. The shaver/radiofrequency device was introduced to resect the capsular tissue medially and laterally to provide a generous interval (10mm) to discourage the healing of capsular tissue in a contracted position.

Posterior Capsular Release

A subset of patients were presented with discrete loss of internal rotation, which was usually painful and was often seen in patients with non-outlet impingement symptoms.

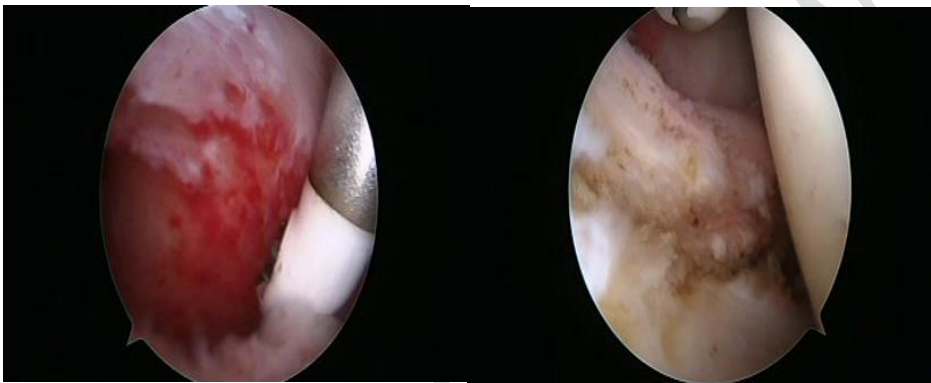


Fig.7a&7b:Posterior andInferior capsule release & 7b with released posterior capsule

The arthroscope was placed through the anterior 6-mm cannula. Inflow was attached to the anterior cannula. A switching stick was placed through the arthroscopic sheath posteriorly into the joint. A 6-mm cannula was exchanged for the arthroscope sheath over a switching stick posteriorly. The radiofrequency device was passed through the cannula and was used to release the posterior capsule from just posterior to the long head of the biceps to the 8 o'clock position. A shaver/radiofrequency device was introduced and used to further resect tissue medially and laterally, leaving a 10-mm capsule-free interval (fig7a&7b). The capsule intimate with the infraspinatus, and the release was terminated at the point at which muscle was encountered.

Inferior Capsular Release

With the arthroscope still in the anterior portal, the radiofrequency device was used through the posterior portal to divide the inferior capsule and posterior inferior glenohumeral ligament, completing the release from 8 o'clock to 6 o'clock position, connecting the posterior and anterior releases. As the safest position of the operative arm during inferior release is abduction and external rotation. The release was performed close to the glenoid insertion of the inferior capsule.

Subacromial and Subdeltoid Bursoscopy

The subacromial space and subdeltoid space was evaluated for bursitis as well as dense adhesions. The arthroscope was passed into the subacromial space through the posterior portal immediately inferior to the posterior acromion. A 6-mm smooth cannula was placed through the anterior portal. A radiofrequency device was passed through the anterior cannula to meet the arthroscopic lens and a subacromial decompression was initiated until the space adjacent to the lateral deltoid was free of adhesions. A spinal needle was used to locate the position of the lateral portal. A lateral portal was made with a no. 11 blade and a 6-mm cannula was introduced into the subacromial space.

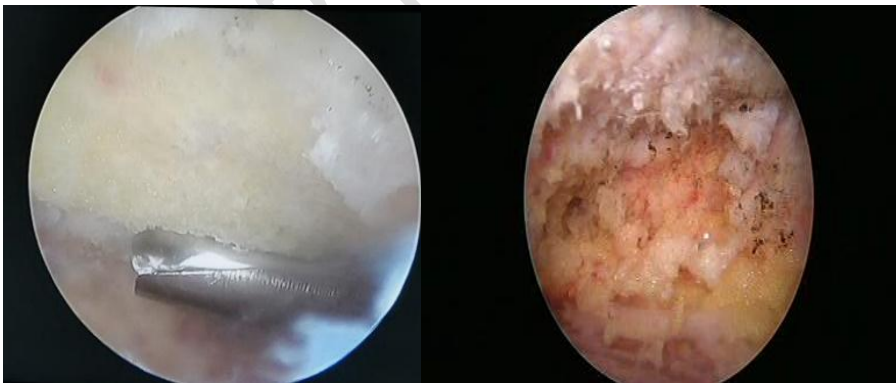


Fig.8a & 8b:Acromioplasty with a burr & Post subacromial Decompression respectively

The anterior and lateral cannula was alternately used to achieve an adequate subacromial decompression. An acromioplasty was done in cases with type 3 acromion.

Post release ROM assessment under Anaesthesia

Post release ROM was assessed sequentially as, External rotation in adduction, Abduction, External rotation in abduction, Internal rotation in abduction, Flexion and Internal rotation in adduction.

RESULTS

The mean age in our series was 52.76 with range from 35-66 years. Majority of the patients were female (52%) when compared with male patients (48%). Male to female ratio was 1:0.9. Majority of the patient had involvement on the left side (60%) as compared to the right side (40%). Majority of the patients had secondary (52%) cause for frozen shoulder as compared to idiopathic (48%). As far as etiology is concerned of 13 patients in our study, 4 patients were diabetic and 6 were post traumatic. Maximum no. of patients had association with impingement syndrome. Twenty-one (84%) had impingement syndrome and four (16%) with no association. All the patients (25) preoperatively had score of less than 24 with UCLA scoring system which is poor. Mostly (20) patients were operated under general anaesthesia (80%) and general anaesthesia with supraclavicular block were given to 5 patients (20%). Capsular release was done in all 25 patients, with complete release was done for 10 and partial release was done for 15 patients. Out of 25 patients 21(84%) had arthroscopic subacromial bursectomy and in 4 patients (16%) no bursectomy was done. Out of 25 patients in our study acromioplasty was done in 10 patients (40%) and in 15 patients (60%) no acromioplasty was done. In our study with 25 patients the mean time from symptoms to surgery was 10.76 months with minimum of 6 months and maximum was 30 months. The duration of surgery in our study was variable with mean duration was 73.44 minutes with minimum time of 45 minutes and maximum time of 98 minutes. The mean hospital stay in our study was 2.36 days with minimum of 2 days and maximum of 3 days. UCLA score at 6 months follow up in our study with 25 number patients with 02(8%) had poor score, 03 had fair (12%), 08(32%) had good and 1(48%) with 2 patients had excellent score. Preoperatively the mean total score in our study was 13.16 and at 3 months the mean total score was 27.60

Comment [A16]: All the contents are mentioned both in the text and the diagrams and are repetitive.

Comment [A17]: The full phrase must be added.

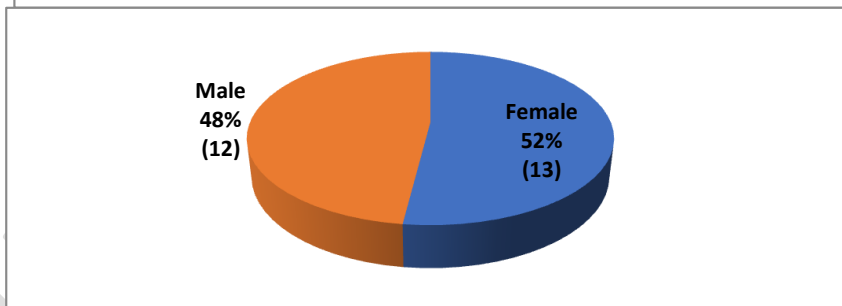
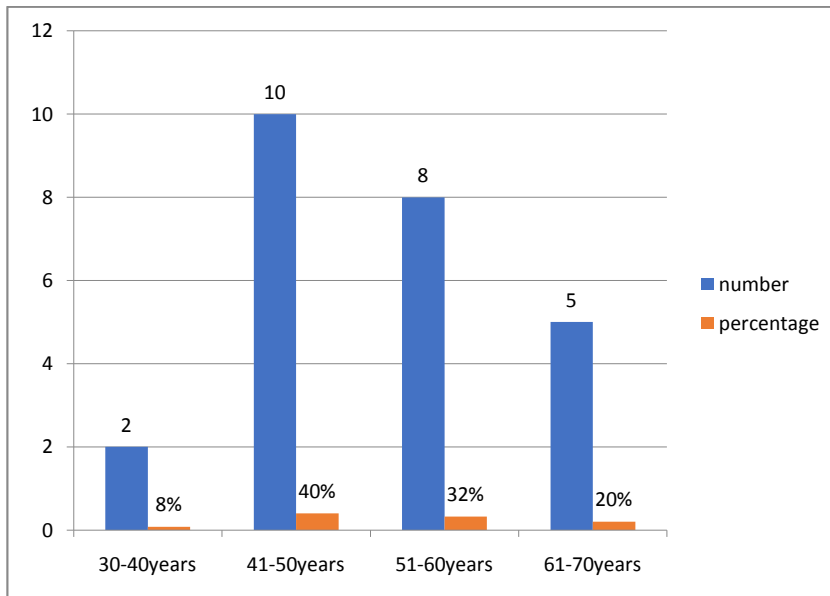
Comment [A18]: The percentage express next to the number.

Comment [A19]: The percentage express next to the number.

Formatted: Highlight

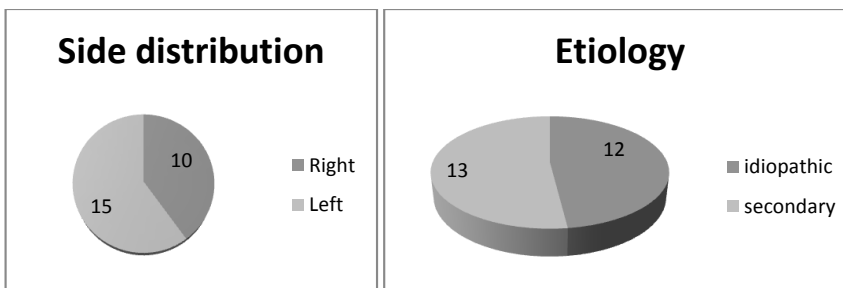
and at final follow up of 6 months it was 32.16. The preop. mean pain score was 3.32, at 3 months it was 7.84 and at 6 months it was 9.44. The preop. mean for function score was 2.96, at 3 months it was 7.52 and at 6 months it was 9.04. The preop mean for motion score was 2.80, at 3 months it was 4.64 and at 6 months the score was 4.68. The preop mean for strength score was 4.12, at 3 months the score was 4.12 and at 6 months it was 4.80. The preop satisfaction score was zero, at 3 months it was 3.60 and at 6 months final follow up it was 4.20. Preoperative mean UCLA score in our study was 13.16 and at 3 months it was 27.60. Preoperative mean UCLA score in our study was 13.16 and at 6 months final follow up it was 32.16. In our study of 25 patients mean preop. Forward flexion was 100.52 and at 3 months follow up it was 153.20. Mean Pre op. Extension was 18.28 and at 3 months follow up the mean extension was 30.96. The mean preop. Abduction was 97.12 and at 3 months follow up it was 154.32. The mean adduction preoperatively in our study was 26.84 and at 3 months follow up it was 32. The mean internal rotation pre op. was 18.88 and at 3 months follow up it was 37.16. The mean external rotation preop. was 32.76 and at 3 months follow up it was 53.72. In our study preop. mean forward flexion was 100.52 and the mean at 6 months follow up it was 156.60. The mean extension was 18.28 pre operatively and the mean at 6 months final follow up was 32.56. The mean abduction preoperatively was 97.12 and the mean abduction at final follow up of 6 months was 156.36. The mean adduction preoperatively was 26.84 and the mean adduction at final follow up of 6 months was 32.80. The mean internal rotation preoperatively was 18.88 and at 6 months final follow up it was 37. The mean external rotation preoperatively was 32.76 and at 6 months final follow up was 60.56. 4 females have excellent UCLA score with 8 males having excellent score. 5 females came under GOOD UCLA score along with 3 males. 2 females were with fair scores along with 1 male and 2 females were found to have poor UCLA score. Out of 25 patients in our study 15 patients with left shoulder and 10 with right shoulder involvement had excellent

score of UCLA. 8 patients with left sided involvement and 4 with right sided involvement had excellent outcome. 6 patients with left side and 2 of right side involvement had good UCLA score. 1 patient with left side involvement and 2 of right side involvement had fair outcome. 2 patients with right sided involvement had poor UCLA score.

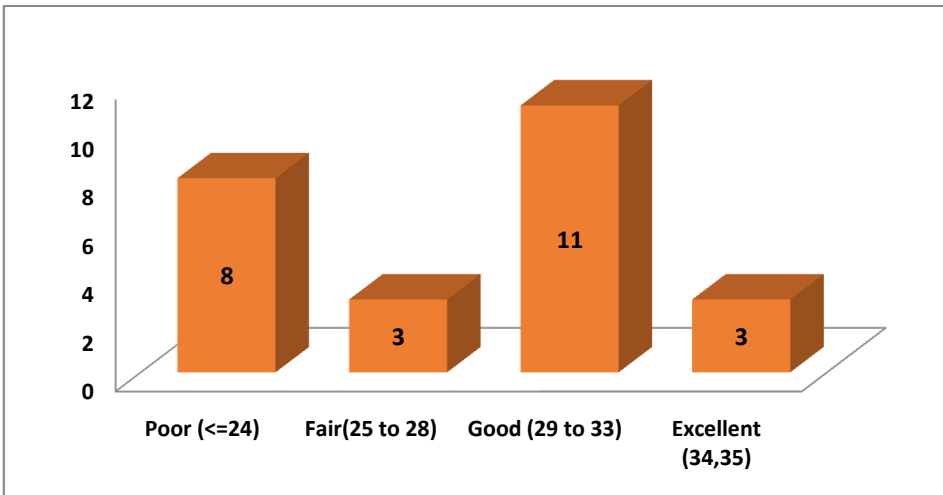


Graph. 1: Graph showing Age & Gender distribution

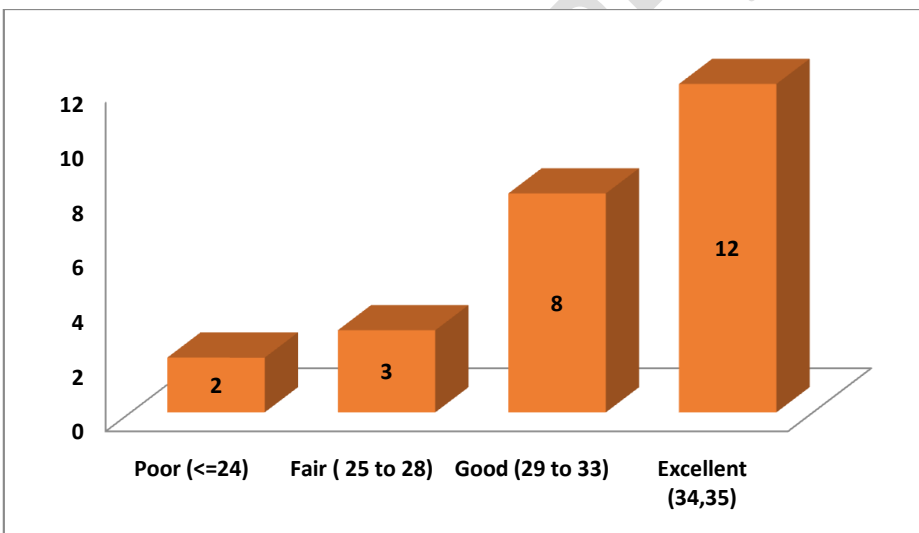
Comment [A20]: It is mentioned in the text. No need for the graph.



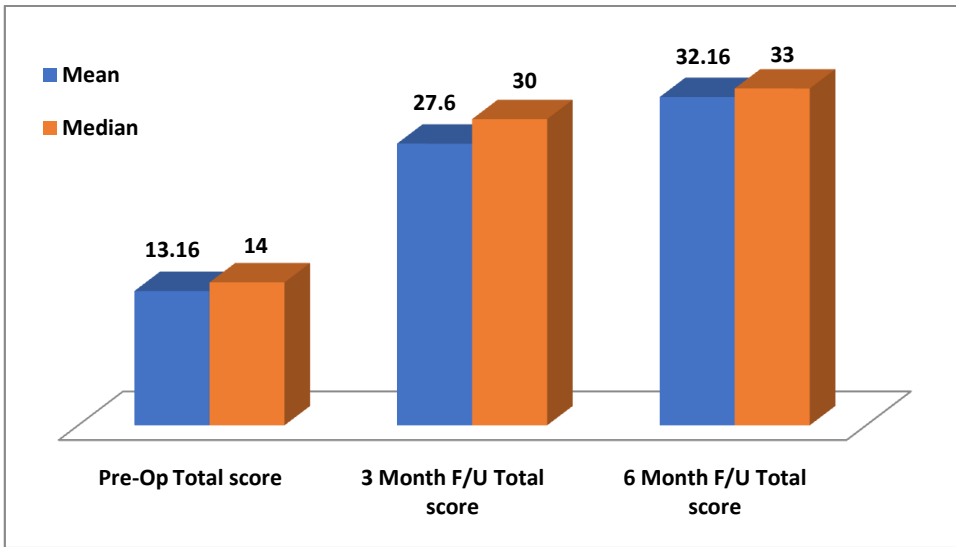
Graph 2: Graph showing side distribution and etiology



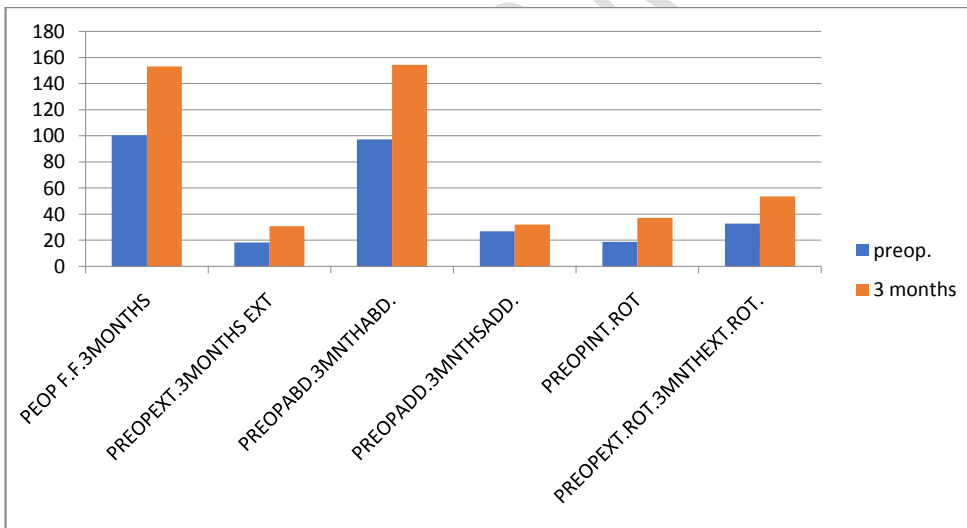
Graph 3: Bar chart depicting distribution of UCLA at 3 Months F/U



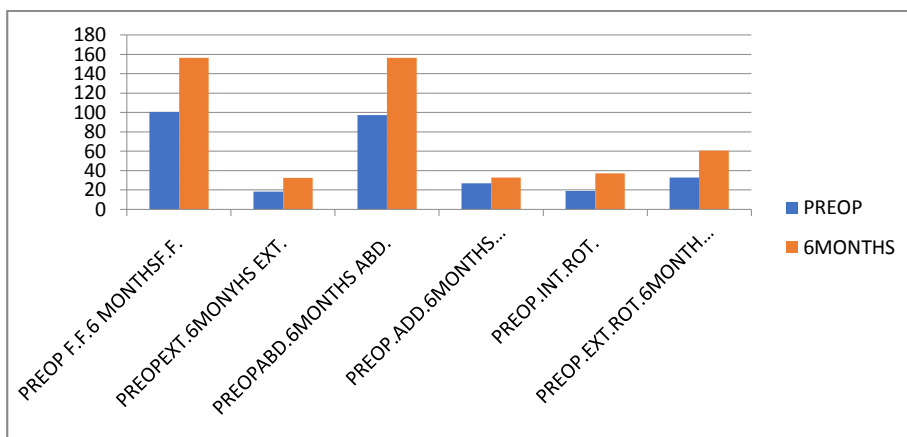
Graph 4: Bar chart depicting distribution of UCLA at 6 Months F/U



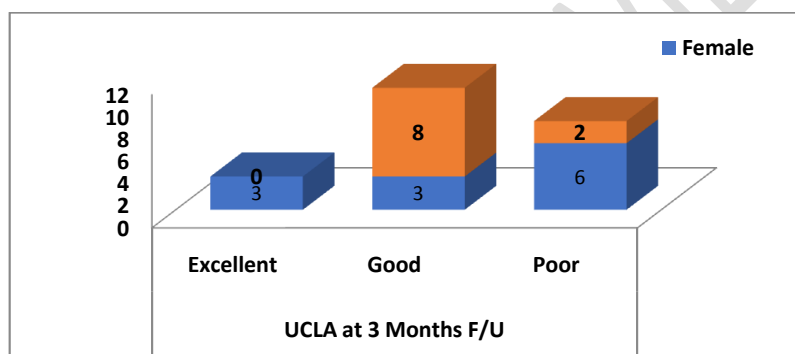
Graph5: Bar chart showing mean & median total UCLA score at Pre-op and different follow-ups



Graph6: Range of Motion Pre Op. &at 6 Months Follow up



Graph7: Relationship between UCLA Score & Gender



Graph8: Bar chart showing relationship between UCLA at 3 Months F/U & Gender

DISCUSSION

The age group involved in our series ranged from 35-65 years with a mean age of 52.76. Majority of the patient (44%) in our series were in group of 40-50 years with 32% in the age group of 51-60 years. No patients were in the group of 18-33yrs with the youngest patient was 35years old. Lafosse L et al., 2012 evaluated 10 patients with frozen shoulder and performed arthroscopic capsular release.⁹ The mean age was 47. Barnes CP et al. 2016 evaluated 133 patients with adhesive capsulitis (frozen shoulder) and performed arthroscopic release.⁸ The mean age was 56. Yildiz F et al. 2018 evaluated 46 patients with frozen shoulder and performed arthroscopic capsular release and subacromial decompression.¹⁰ The mean age was

Comment [A21]: There is no need to repeat the results in this section. Only important and significant content should be mentioned.

Formatted: Highlight

Formatted: Highlight

Comment [A22]: There is no scientific process, you just compared the results.

47.2 Hagiwara Y et al.2020 evaluated 60 patients with frozen shoulder and performed arthroscopic capsular release.¹¹The mean age was 57.4

Table 1.The male to female ratio in our study was 2.1:2 with 13 females (52%) and 12 (48%)males.

Study	BarnesCPet al.2016 ⁸	LafosseL et al.2012 ⁹	Hagiwara Y et al.2020 ¹¹	Yildiz Y et al.2018 ¹⁰	Present study
MeanAge (in years)	56	47	57.4	47.2	52.76

LafosseL et al.,2012 evaluated 10 patients with frozen shoulder and performed arthroscopic capsular release.⁹The series had 3 male and 7 female patients .The male and female ratio was 1:2.3. Barnes CP et al. 2016 evaluated 133 patients with adhesive capsulitis (frozen shoulder)and performed arthroscopic release.⁸The series had 45male and 88 female patients.The male and female ratio was 2:3.9. Yildiz F et al.2018 evaluated 46 patients with frozen shoulder and performed arthroscopic capsular release and subacromial decompression. The series had 2 male and 44 female patients.¹⁰The male and female ratio was 0.1:2.2. Hagiwara Y et al.2020 evaluated 60 patients with frozen shoulder and performed arthroscopic capsular release. The series had 25male and 35 female patients.¹¹The male and female ratio was 1:1.4.

Table 2.The results of gender comparison were comparable with other published series.

Study	Barnes CP et al, 2016 ⁸	Yildiz F et al.2018 ¹⁰	Hagiwara Y et al.2020 ¹¹	Lafosse L et al. 2012 ⁹	Present study
Males	45%	4%	41.7%	30%	48%
Females	66%	96%	58.3%	70%	52%

Male:female ratio	2:3.9	0.1:2.2	1:1.4	1:2.3	2:2.1
-------------------	-------	---------	-------	-------	-------

In our study of 25 patients right side was involved in 10 patients(40%) and 15 patients(60%)had left side involvement.Beauflis P et al.1999 evaluated 26 cases with adhesive capsulitis and performed capsular release.¹²The series had 6 male and 19 female patients.Right arm was involved in 17 patients (64%) and left arm was involved in 9 patients (36%).Barnes CP et al. 2016 evaluated 133 patients with adhesive capsulitis (frozen shoulder)and performed arthroscopic release.⁸Right arm was involved in 63 patients(45%) and left arm was involved in 77 patients(55%).¹⁰Yildiz F et al.2018 evaluated 46 patients with frozen shoulder and performed arthroscopic capsular release and subacromial decompression.Right arm was involved in 42 patients(91%) and left arm was involved in 4 patients(9%).¹¹Hagiwara Y et al.2020 evaluated 60 patients with frozen shoulder and performed arthroscopic capsular release.Right arm was involved in 20 patients(33.3%) and left arm was involved in 40 patients(66.7%).¹²

Table 3.The results of side comparison were comparable with other published series.

Study	Beauflis P et al.1999 ¹²	Barnes CP et al.2016 ⁸	YildizFet al. 2018 ¹⁰	Hagiwara Y et al.2020 ¹¹	Present study
Right arm	64%	45%	91%	33.3%	40%
Left arm	36%	55%	9%	66.7%	60%

Comparison of etiology-

Table 4. Comparison of etiology among the primary and secondary studies

Study	Beaufilis P et al.1999 ¹²	Lafosse L et al.2012 ⁹	YildizF et al.2018 ¹⁰	Hagiwara Y et al.2020 ¹¹	Present study
idiopathic/primary	50%	40%	65%	70%	48%
Secondary	50%	60%	35%	30%	52%

The majority of the patients in our study had secondary frozen shoulder (4 were diabetic and 3 had hypothyroidism and 6 were post traumatic). In other studies, also majority were having secondary frozen shoulder.

Duration of symptoms

Table 5. The duration of symptoms upto surgery ranged from 6 months to 30 months with a mean of 10.76 months.

Study	P.Beaufilis et al.1999 ¹²	Laurent Lafosse et al. 2012 ⁹	Callum p. Barnes et al.2016 ⁸	F.Yildiz et al. 2018 ¹⁰	Present study
Mean duration (months)	13	19	7	7.9	10.76

Beaufilis P et al.1999 evaluated 26 cases with adhesive capsulitis and performed capsular release. He reported the duration of symptoms ranging from 1 months to 27 months with a mean of 13 months.¹²

Barnes CP et al. 2016 evaluated 133 patients with adhesive capsulitis (frozen shoulder) and performed arthroscopic release. He reported the duration of symptoms ranged from 1 months to 40 months with a mean of 7 months.⁸

Yildiz F et al.2018 evaluated 46 patients with frozen shoulder and performed arthroscopic capsular release and subacromial decompression. He reported the duration of symptoms ranged from 1 month to 26 months with a mean of 7.9 months.¹⁰

Lafosse L et al.,2012 evaluated 10 patients with frozen shoulder and performed arthroscopic capsular release. He reported the duration of symptoms ranged from 6 months to 36 months with a mean of 19 months.⁹

Results at final follow up-

All the patients were followed up regularly. The follow up was done at 1 week,2 weeks, 4 weeks, 6 weeks,3months, and final follow up was done at 6 months.

Final evaluation was done on the basis of ROM and UCLA score.

ROM-

Mean active forward flexion improved from 100.52 degrees preoperatively to 156.60 degrees at final follow up. Mean abduction improved from 97.12 to 156.36 at final follow up. Mean external rotation 32.76 to 60.56 at final follow up. Mean internal rotation 18.88 to 37.0 at final follow up.

Lafosse L et al.,2012 evaluated 10 patients with frozen shoulder and performed arthroscopic capsular release. He reported that forward flexion improved from 55 preoperatively to 175 degrees at final follow up. Abduction improved from 40 degree to 165 degree. External rotation improved from 6 to 58 degree. Internal rotation improved from 10 degree to 34 degree.⁹

Barnes CP et al. 2016 evaluated 133 patients with adhesive capsulitis (frozen shoulder)and performed arthroscopic release. He reported that forward flexion improved from 96 degree

preoperatively to 156 degrees at final follow up. Abduction improved from 74 degree to 137 degree. External rotation improved from 21 degree to 48 degree and internal rotation improved from 15 degree to 36 degree.⁸

Yildiz F et al.2018 evaluated 46 patients with frozen shoulder and performed arthroscopic capsular release and subacromial decompression. He reported that forward flexion improved from 43 degrees preoperatively to 152 degrees on final follow up. Abduction improved from 45 to 137 degree. External rotation improved from -5 degree to 45 degrees and internal rotation improved from 15 degree to 36.3 degree.¹⁰

Hagiwara Y et al.2020 evaluated 60 patients with frozen shoulder and performed arthroscopic capsular release. He reported that forward flexion improved from 87.7 degree preoperatively to 162.6 on final follow up. External rotation improved from 4.7 degree to 48.2 degree and internal rotation improved from 13 degree to 33 degree.¹¹

Table 6. Results at final follow up

Study	Barnes CP et al.2016 ⁸	Lafosse L et al.2012 ⁹	YildizF et al. 2018 ¹⁰	Hagiwara Y et al. 2020 ¹¹	Present study
Preop Forward flexion	96	55	43	87.7	100.52
Post op forward flexion	156	175	152	162.6	156.60
Preop extension	*	*	*	*	18.28
Postop extension	*	*	*	*	32.56
Preop abduction	74	40	45	*	97.12
Postop abduction	137	165	137	*	156.36
Preop adduction	*	*	*	*	26.84
Postop adduction	*	*	*	*	32.80

Preop rotation	External	21	6	-5	4.7	32.76
Postop rotation	external	48	58	45	48.2	60.56
Preop rotation	Internal	15	10	15	13	18.88
Postop rotation	internal	36	34	36.3	33	37.00

UCLA SCORE-

Table 7. Study on UCLA Score

Study	Hagiwara Y et al. 2020 ¹¹	Present study
Pre op pain score	3.6	3.32
Post op pain score	9.8	9.44
Pre op function score	3	2.96
Post op function score	9.4	9.04
Pre op motion score	2.5	2.80
Post op motion score	4.9	4.68
Pre op strength score	4.8	4.12
Post op strength score	5	4.80
Pre op satisfaction score	0.0	0.00
Post op satisfaction score	5	4.20
Total UCLA pre op	13.9	13.16
Total UCLA at final follow up	34	32.16

The mean pre op Pain score was 3.32 and at post op. 6 months follow up it was 9.44. The mean pre op. function score was 3 and postop. it was 9.4 at final follow up. The mean preop.

Comment [A23]: Because it is an abbreviation, it should be written in capital letters.

Motion score was 2.5 and post op score at 6 months final follow up was 4.9. The mean preop. strength score was 4.8 and post op at 6 months final follow up was 5. The mean preop. satisfaction score was zero and post operative at 6 months is 5.¹¹Hagiwara Y et al.2020 evaluated 60 patients with frozen shoulder and performed arthroscopic capsular release. He reported that forward flexion improved from 87.7 degree preoperatively to 162.6 on final follow up. External rotation improved from 4.7 degree to 48.2 degree and internal rotation improved from 13 degree to 33 degree. The mean pre op. pain score in our study was 3.32 and ¹¹Yoshihiro Hagiwara et al.2020 reported preop pain score of 3.6. In our study post op. mean pain score at 6 months follow up was 9.44 and ¹¹Hagiwara Y et al.2020 reported it as 9.8. The mean pre op. function score in our study was 2.96 and Hagiwara Y et al.2020 reported it as 3. In our study, postop. function score at final follow up was 9.04 and in study by Hagiwara Y et al. done in 2020 it was 9.4. The mean preop. motion score was 2.80 and in study of Hagiwara Y et al.2020 it was 2.5. In our study, at post op 6 months final follow up, the motion score was 4.68. and in study by ¹¹Hagiwara Y et al. done in 2020 it was 4.9. The mean preop. strength score was 4.12 in our study, while ¹¹Hagiwara Y et al.2020 reported the mean pre op strength score as 4.8. The score for strength post op. at 6 months final follow up was 4.80 and in study of ¹¹Yoshihiro Hagiwara et al.2020 study it was 5. The mean preop. satisfaction score was zero in our study and in study by ¹¹Hagiwara Y et al.2020 it was also zero and post operatively at 6 months final follow up it was 4.20 and in the same study it was 5.

Formatted: Highlight

Formatted: Highlight

CONCLUSION

Arthroscopic release of capsule in frozen shoulder (adhesive capsulitis) is a safe and effective procedure with very few complications. The arthroscopic technique gives further advantage of evaluating any glenohumeral joint and subacromial pathology. Rapid rehabilitation is possible in comparison to open procedures as there is less soft tissue trauma permitting rapid

return to daily activities. The procedure is associated with less pain and improved cosmesis in comparison to open procedures. There is less chances of intraoperatively complications comparing to MUA.

REFERENCES:

1. De Carli A, Vadalà A, Perugia D, et al. Shoulder adhesive capsulitis: manipulation and arthroscopic arthrolysis or intra-articular steroid injections? *Int Orthop*. 2012; 36(1): 101- 106.
2. Zuckerman JD, Rokito A. Frozen shoulder: a consensus definition. *J Shoulder Elbow Surg*. 2011;20(2):322–325
3. Reeves B. The natural history of the frozen shoulder syndrome. *Scand J Rheumatol*. 1975;4(4):193–196
4. Grey RG. The natural history of idiopathic frozen shoulder. *J Bone Joint Surg*. 1978;60(4):564
5. Dias R, Cutts S, Massoud S. Frozen shoulder. *BMJ*. 2005 Dec 17;331(7530):1453–1456.
6. Hagiwara Y, Sekiguchi T, Ando A, Kanazawa K, Koide M, Hamada J, Yabe Y, Yoshida S, Itoi E. Effects of arthroscopic coracohumeral ligament release on range of motion for patients with frozen shoulder. *Open Orthop J*. 2018 Sep 18; 12: 373-379
7. Azar FM, Beaty JH, Canale T. *Cambell's Operative Orthopaedics*. 4 Volume set, 13th edition, Elsevier 2017
8. Barnes CP, Lam PH, Murrell GA. Short term outcomes after arthroscopic capsular release for adhesive capsulitis. *J Shoulder Elbow Surg*. 2016 Sep; 25(9):e256-64.
9. Lafosse L, Boyle S, Kordasiewicz B, Guttierrez-Arramberi M, Fritsch B, Meller B. Arthroscopic Arthrolysis for Recalcitrant Frozen Shoulder: A Lateral Approach. *Arthroscopy: The Journal of Arthroscopic and Related Surgery*, Vol 28, No 7 (July), 2012: pp 916-923
10. Yildiz F, et al., Effect of nonoperative concomitant intraarticular pathologies on the outcome of arthroscopic capsular release for adhesive capsulitis of the shoulder, *Acta OrthopTraumatolTurc* (2018) 1-4
11. Hagiwara Y, Kanazawa K, Ando A, Sekiguchi T, Yabe Y, Takahashi M, Koide M, Takahashi N, Sugaya H. Clinical outcomes of arthroscopic pan-capsular release with

Comment [A24]: The number of references is very few and not up to date.

or without entire coracohumeral ligament release for patients with frozen shoulder.
JSES International 4 (2020) 826e832

12. Beaufils P, Pre´vot N, Boyer T, Allard M, Dorfmann H, Frank A, Kelbe´rine F, Kempf JF, Mole´D, Walch G, and the French Society for Arthroscopy 1999. Arthroscopic Release of the Glenohumeral Joint in Shoulder Stiffness: A Review of 26 Cases. Arthroscopy: The Journal of Arthroscopic and Related Surgery, Vol 15, No 1 (January-February), 1999: pp 49–55

UNDER PEER REVIEW