

## Immunohistochemical expression of XIAP in mucoepidermoid carcinoma

### Abstract:

#### Objective:

The X-linked inhibitor of apoptosis protein (XIAP) immunohistochemical expression was employed to assess the anti-apoptotic activity of mucoepidermoid carcinoma (MEC) in relation to different clinicopathological variables to understand if XIAP immunoreactivity could reflect the histologic grade and the biologic activity and prognosis in MEC patients.

#### Materials and methods:

A retrospective study was accomplished on 16 MEC cases. The worked MEC cases involved the three histologic grades, low, intermediate, and high. Assessment of XIAP immunoreactivity was made in relation to different clinicopathological parameters. The analysis of data was done by Pearson's Chi-square test. Pearson correlation coefficient test was used to test the association between the different variables. The P-value  $<0.05$  was considered to be statistically significant.

#### Results:

There were statistically significant differences in XIAP immunoreactivity in relation to the following parameters; the TNM clinical stage ( $P=0.036$ ), and the histologic grade ( $P=0.008$ ). Conversely, the immunoreactivity of XIAP was not significantly correlated with patients' age ( $P=0.141$ ), patients' gender ( $P=0.471$ ), and the anatomical site of the tumor ( $P=0.827$ ) in MEC cases.

#### Conclusion:

The immunoreactivity of XIAP correlates with histologic grading of MEC. Additionally, XIAP immunoreactivity reflects the clinical and biological behavior of MEC.

Key words: Immunohistochemical expression, anti-apoptotic activity, mucoepidermoid carcinoma

## Introduction:

The biology and clinical behavior of malignant salivary gland tumors (MSGTs) vary widely, indicating their heterogeneity (Tranchito et al., 2022). Since salivary gland tumors have a wide range of morphological characteristics and many overlapping signs, they are among the most challenging cases in diagnostic pathology (Speight and Barrett 2020). The most frequent MSGT, accounting for over 50% of cases, is mucoepidermoid carcinoma (MEC) (Coleman et al., 2023), (Tchekmedyan 2021). MEC's biological behavior varies from being comparatively indolent (low grade) to being clinically aggressive (high grade). The prognosis for MEC varies significantly and is mostly based on the tumor's pathological grade (Xu et al., 2023), (Shafique et al. 2020).

Salivary gland carcinomas' (SGCs) histologic grading has been demonstrated to be a reliable indicator of the tumors' behavior and to be important in therapy optimization. It is not advisable to apply universal grading standards to SGCs because they typically exhibit intrinsic biological behavior (Xu et al., 2023), (Amin et al. 2017). New tools for immunohistochemical (IHC) diagnosis and prognostication, such as cell-proliferation markers, anti-apoptotic proteins, myoepithelial antigens, matrix metalloproteinases, steroid receptors, growth factors, and their receptors, have been combined with recent developments in histopathological classification. These have increased our options for treating a range of SGCs with more targeted therapies (Nishida et al., 2023), (Barnes et al., 2005), (Leivo 2006). Trials aimed at supplying more clues and indications regarding the identification of proteins that regulate biological processes like mitosis are therefore necessary for more accurate assessment and, as a result, contribute to improved management approaches (Nishida et al., 2023), (El-Naggar 2017).

Tumorigenesis involves a loss of balance between regulators of cell proliferation and apoptosis (Ferreira et al. 2001). Apoptotic cell death plays an important physiological role in normal development and tissue homeostasis. Dysregulation of apoptosis has been implicated in carcinogenesis, tumor progression, and resistance of tumor cells to chemotherapy (Ramp et al. 2004). XIAP is considered the most potent IAP as it inhibits caspases 3, 7, and 9, thereby blocking both the intrinsic (mitochondria-mediated) and extrinsic (death receptor-mediated)

apoptotic pathways (Schimmer et al. 2006), (Holcik, Gibson, and Korneluk 2001). The present research hypothesized that the level of XIAP immunoeexpression might correlate with the biological characteristics of MEC cases as a measure of apoptosis. Therefore, we investigated XIAP immunoeexpression in MEC cases in relation to clinicopathological factors of prognostic importance to clue the importance of this protein in predicting the biologic activity of MECs (Ning et al., 2014).

### **Materials and methods:**

The current work is a retrospective study, for which a total of 16 paraffin tissue blocks of MEC cases. All the included cases had a confirmed histopathological diagnosis of MEC by examining hematoxylin and eosin stained tissue sections. The selected cases had received surgical treatment, hadn't received any form of adjuvant therapy before their surgery, had arisen from both major and minor salivary glands, and had complete clinical records. Cases that had insufficient or inoperable biopsy specimens, or missing medical, clinical, or follow-up records were excluded from the study. The current work included 16 cases of MEC cases which were categorized into three histologic grades (low, intermediate, and high grade) following the criteria of Modified Healey classification (Seethala 2009).

Tissue blocks and records belong to the studied cases were obtained from the archive of Oncology unit of Oncology Center, Faculty of Medicine, Mansoura University.

### **Immunohistochemistry:**

From each paraffin block sections of four-microns thickness were cut. Tissue sections were mounted on D.P.X (a mixture of distyrene, a plasticizer, and xylene). Rehydration of the slides with varying alcohol and water concentrations comes after deparaffinization. The slides were stored in the microwave for ten minutes in a 0.01 M citric acid buffer (pH = 6.0) for antigen retrieval. Slides were incubated in methanol containing 3% H<sub>2</sub>O<sub>2</sub> for 15 minutes to inactivate endogenous peroxidase. After that, they were rinsed with distilled water.

Applying the primary antibody to XIAP and a rabbit polyclonal antibody against humans, which comes in a vial with 20 μ

of ready-to-use antibodies Abclonal Technology. The streptavidin-biotin complex technique and an overnight incubation period at 4°C were used to carry out the immunoreaction.

The streptavidin-biotin complex technique and an overnight incubation period at 4°C

Sections of kidney cancer were stained at the same batch and under the same conditions to serve as a positive control of the reaction with the employed antibody (XIAP). Negative control slides were produced by substituting plain PBS for the principal antibody. All specimens were evaluated and scored independently by three experienced pathologists, then the mean was calculated to get a final score. All staining was scored in epithelial cells but not in stromal cells or inflammatory cells.

Cytoplasmic and nuclear staining of XIAP was scored by a conventional four-tiered semi-quantitative scoring method described by Xu YC et al (Xu et al. 2014a). Staining intensity was graded on a semiquantitative scale (1+, weak; 2+, moderate; and 3+, strong). The extent of staining was scored as 0 (less than 5%); score 1, focal (6–25%); score 2, multifocal (26–50%); score 3, regional (51–75 %); and score 4, diffuse (76–100 %). Next, stain intensity was multiplied by the extent of the stain, and the cut-off was set as follows: scores 0–2 negative, 3–5 weak, 6–8 moderate, and greater than or equal to 9 strong.

### Statistical Analysis:

In order to identify any potentially significant differences or correlations between the various variables, the study's findings were statistically examined. The Statistical Package of Social Science (SPSS) version 22 program and the Excel program were used to perform the statistical analysis of the data. For quantitative data, the mean (+/-) Standard Deviation (SD) was used to describe the data; for qualitative data, frequency and proportion were used. The data was analyzed using Pearson's Chi-square test. To examine the relationship between the various variables, the Pearson correlation co-efficiency test was employed. A P-value of less than 0.05 was considered statistically significant.

### Results:

The presently studied MEC group (16 cases) was comprised of three males (18.75%) and 13 females (81.25%) with a mean age of 61 years, ranging from 37 to 76 years. Most of MEC cases were represented in the major salivary glands (87.5%), particularly the parotid. The reported clinical stage in most (81.25%) of the MEC group was among the stage groups III (11/16), while the rest of the cases were equally distributed among stage I (3/16) and II (2/16). Clinical characteristics of the worked MECs are illustrated in Table 1.

**Table1: Clinical parameters of the studied mucoepidermoid carcinoma (MEC) cases.**

MEC (n=16 cases)			
Patient's ages	Mean±SD	61.44±5	
	Minimum	37	
	Maximum	76	
<b>Clinical parameters</b>	<b>Groups</b>	<b>Number of cases</b>	<b>%</b>
<b>Gender</b>	Male	3	18.75
	Female	13	81.25
<b>Site</b>	Major SG	14	87.5
	Minor SG	2	12.5
<b>TNM stage</b>	I	3	18.75
	III	11	68.75
	IV	2	12.5
<b>TNM stage groups</b>	I	3	18.75
	III and IV	13	81.25

### Clinical and pathological characteristics of the worked MECs in relation to XIAP expression

XIAP IHC presented nuclear and cytoplasmic expression in the majority of the worked MECs. Upon correlating XIAP immunopositivity with different clinical parameters, Pearson's chi-square test revealed significant differences in its expression concerning the following parameters; the TNM clinical stage of MEC ( $P=0.036$ ), and the histologic grade ( $P=0.008$ ) of MECs. Conversely, the immunopositivity of XIAP was not significantly correlated with patients' ages ( $P=0.141$ ), patients' gender ( $P=0.471$ ), and the anatomical site of the tumor ( $P=0.827$ ).

Regarding age, patients who were older than 61 years showed equal expressions of 33.3% between weak (2 cases), moderate (2 cases), and strong (2 cases) XIAP expression while younger patients (<61 years old) had moderate (6 cases, 60%) and strong (4 cases, 40%) XIAP expression. (Pearson's chi-square test,  $P=0.141$ , **Table 2**). There was no statistically significant difference in XIAP expression in MEC between the two age groups ( $P=0.141$ ).

**Table2:XIAPIHCexpressionin relationtoage**

			XIAPfinalscore			Total	Pearson`s X <sup>2</sup>
			weak	Moderate	Strong		
MEC age groups	< or=61 years	Count % within MEC agegroups	0 0.0%	6 60.0%	4 40.0%	10 100.0%	0.141
	> 61 years	Count % within MEC agegroups	2 33.3%	2 33.3%	2 33.3%	6 100.0%	
Total		Count % withinMECage groups	2 12.5%	8 50.0%	6 37.5%	16 100.0%	

Regardingpatients’genderofMECcases,Pearson’sChisquaretestrevealednostatisticallysignificantdifferenceinXIAPexpressionbetweenmalesandfemales.Malespresented moderate(onecase,33.3%) tostrong(2cases,66.7%) XIAPexpressions,while femalesshowedweak(2cases,15.4%),moderate(7cases,53.8%),andstrong(4cases,30.8%)XIAP expressions(**table3**).

**Table3:XIAPIHCexpressionin relationtogender**

			XIAPfinalscore			Total	Pearson`s X <sup>2</sup>
			weak	Moderate	Strong		
MECgender groups	Male	Count % within MEC gendergroups	0 0.0%	1 33.3%	2 66.7%	3 100.0%	0.0471
	Female	Count % within MEC gendergroups	2 15.4%	7 53.8%	4 30.8%	13 100.0%	
Total		Count % withinMECgender groups	2 12.5%	8 50.0%	6 37.5%	16 100.0%	

According to the anatomical site of involvement, there were no statistically significant differences in XIAP immuno-expression considering the different sites of MECs using the Pearson Chi-square test ( $P=0.82$ , **Table 4**).

**Table 4: XIAP IHC expression in relation to the anatomical site**

		XIAP final score			Total	Pearson's $X^2$
		weak	Moderate	Strong		
MEC site groups	Major SG Count	2	7	5	14	0.827
	% within MEC site groups	14.3%	50.0%	35.7%	100.0%	
	Minor SG Count	0	1	1	2	
	% within MEC site groups	0.0%	50.0%	50.0%	100.0%	
Total	Count	2	8	6	16	
	% within MEC site groups	12.5%	50.0%	37.5%	100.0%	

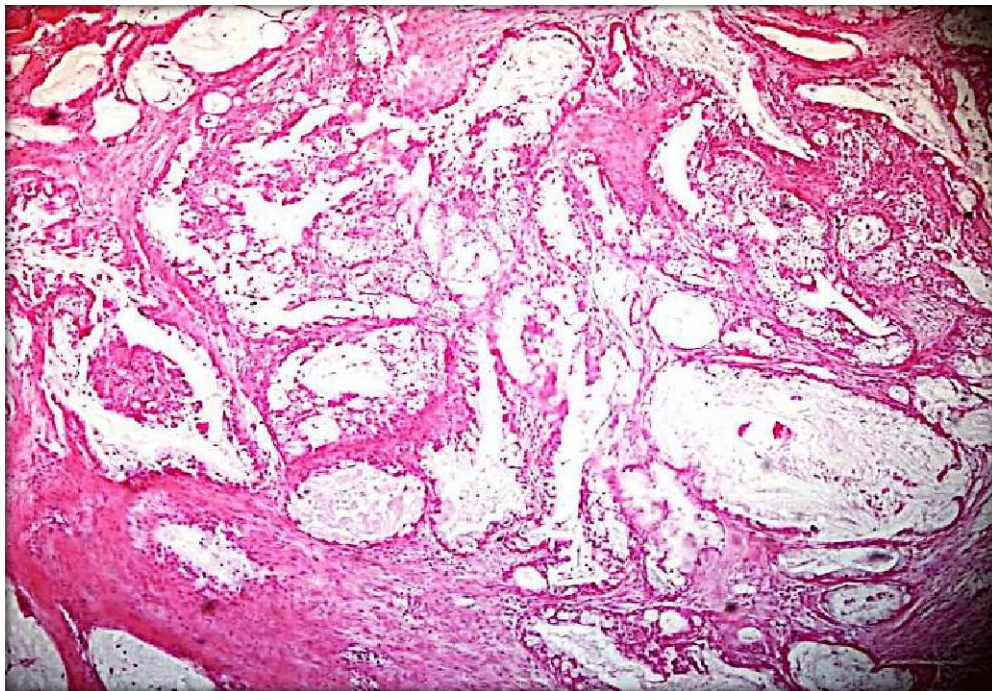
Moreover, the worked MEC cases that had an advanced clinical stage (III and IV) demonstrated significantly high XIAP immuno-expression. All the worked stage IV cases showed moderate (1 case, 50%) to strong (1 case 50%) XIAP expressions. Stage III showed moderate (6 cases, 54.5%) to strong (5 cases, 45.5%) XIAP expressions. Oppositely, all stage I cases showed weak (2 cases, 66.7%), and moderate (one case, 33.3%). Pearson's chi-square test demonstrated a high statistically significant difference in XIAP expression among the different TNM clinical stages in MEC ( $P=0.036$ , **Table 5**)

**Table 5: XIAP IHC expression in relation to TNM stage in MEC**

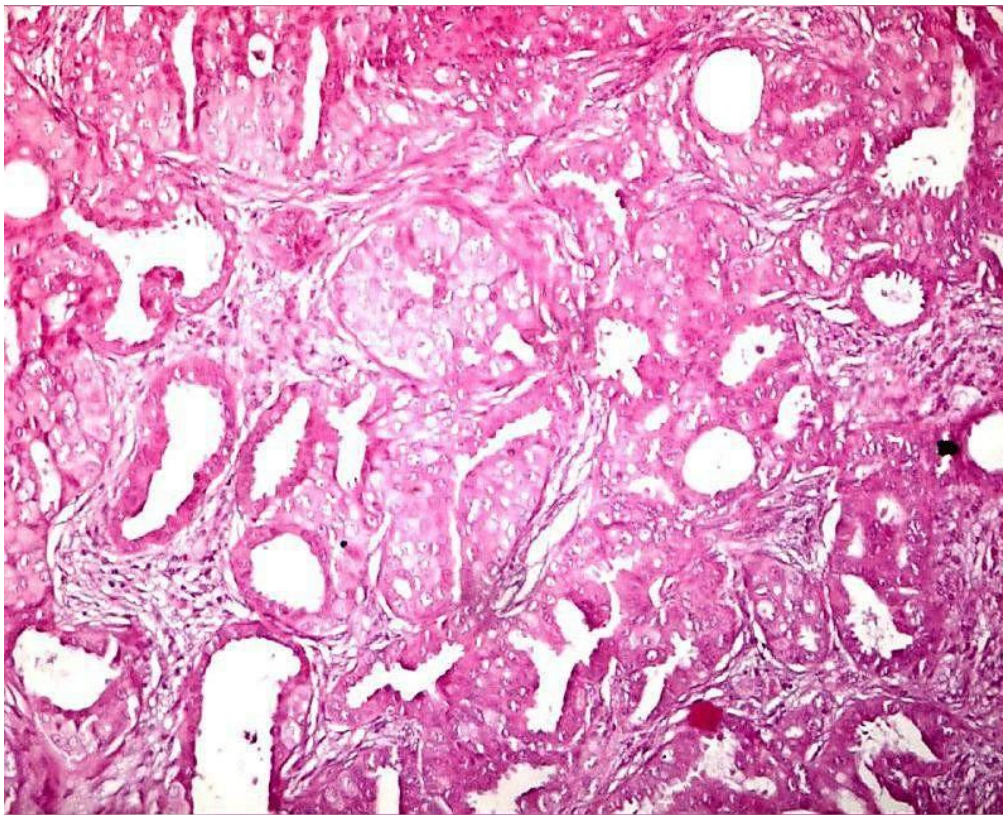
			XIAP final score			Total	Pearson's $X^2$
			weak	Moderate	Strong		
MEC TNM stages	stage I	Count	2	1	0	3	0.036
		% within MEC TNM stages	66.7%	33.3%	0.0%	100.0%	
	stage III	Count	0	6	5	11	
% within MEC TNM stages		0.0%	54.5%	45.5%	100.0%		
	stage IV	Count	0	1	1	2	
		% within MEC TNM stages	0.0%	50.0%	50.0%	100.0%	
Total	Count		2	8	6	16	
	% within MEC TNM stages		12.5%	50.0%	37.5%	100.0%	

### Pathological characteristics of the worked MECs in relation to XIAP expression

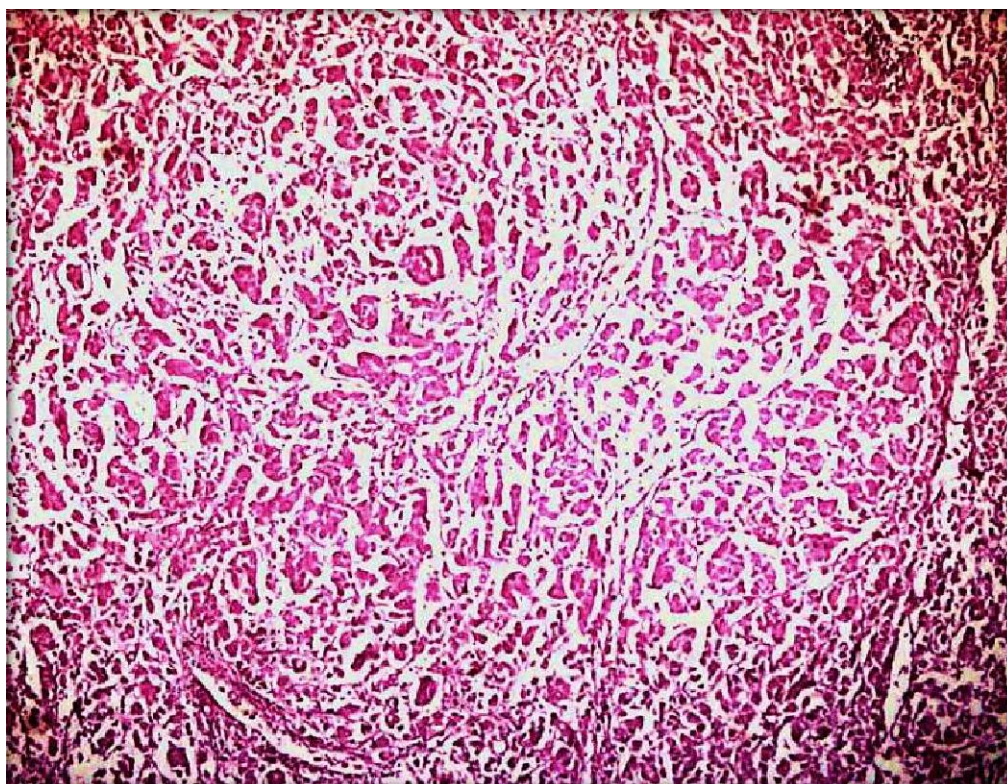
Mucoepidermoid carcinoma of the current work was characterized by the presence of variable proportions of three types of cells; mucous-secreting cells, epidermoid cells, and intermediate cells. This group was classified into three histologic grades (low, intermediate, and high) following the criteria of Modified Healey classification (Seethala 2009). The greater number of MEC cases was represented in the high grade (10 cases, 62.4%), while the low and intermediate grades of MECs were represented in three cases for each grade (18.8%). Grading of MEC revealed variation according to the relative number of cystic spaces, the relative proportion of the constituent cells, and the degree of cellular atypia. Low-grade carcinomas demonstrated numerous cystic spaces that were filled with mucin, increased proportion of mucous-secreting cells, and decreased cellular atypia. On the other hand, high-grade carcinomas demonstrated solid proliferation of cells, increased proportion of epidermoid cells, and marked cellular atypia. The histopathologic picture of intermediate-grade carcinoma was in the midway between low-grade and high-grade carcinomas (Figures 1-4)



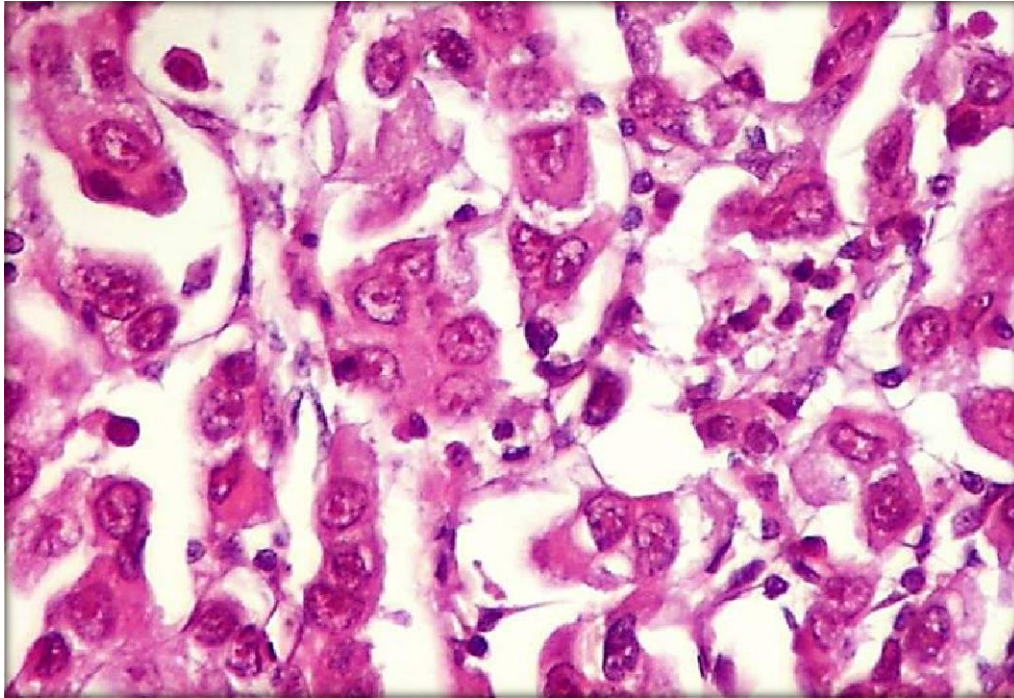
**Figure 1:** Low-grade mucoepidermoid carcinoma shows multiple cystic spaces filled with mucin (H&E x200).



**Figure2:** Intermediate-grade mucoepidermoid carcinoma shows nests of epidermoid cells, a few small-sized cystic cavities, and numerous sheets of intermediate cells in the connective tissue background (H&E x 200).



**Figure3:** High-grade mucoepidermoid carcinoma reveals minimal cystic spaces, solid nests of epidermoid cells with marked cellular atypia (H&E x 100).



**Figure 4:** High-grade mucoepidermoid carcinoma reveals minimal cystic spaces, and solid nests of epidermoid cells with marked cellular atypia (H&E x 400).

Regarding the MEC histologic grade, there was a strong positive correlation of XIAP expression with the MEC histologic grade ( $P=0.008$ ). Two cases (66.7%) of the low-grade MEC showed weak XIAP expression (Figure 5). All the worked intermediate-grade MEC (3cases) showed moderate XIAP expression (Figure 6). More than half (60%) of the high-gradeshowedstrongexpression(Figure7).UsingPearsons'chi-squaretest( $P=0.008$ )revealedahighstatisticallysignificantdifferenceinXIAPIHCexpressionamongthedifferentMEChistologicgrades. Moreover, a strong positive correlation was detected between XIAP expression andMEChistologicgrade(Pearson's  $R = 0.000$ , Table6,7).

**Table 6:XIAPexpressioninrelationtotheMEChistologicgrade**

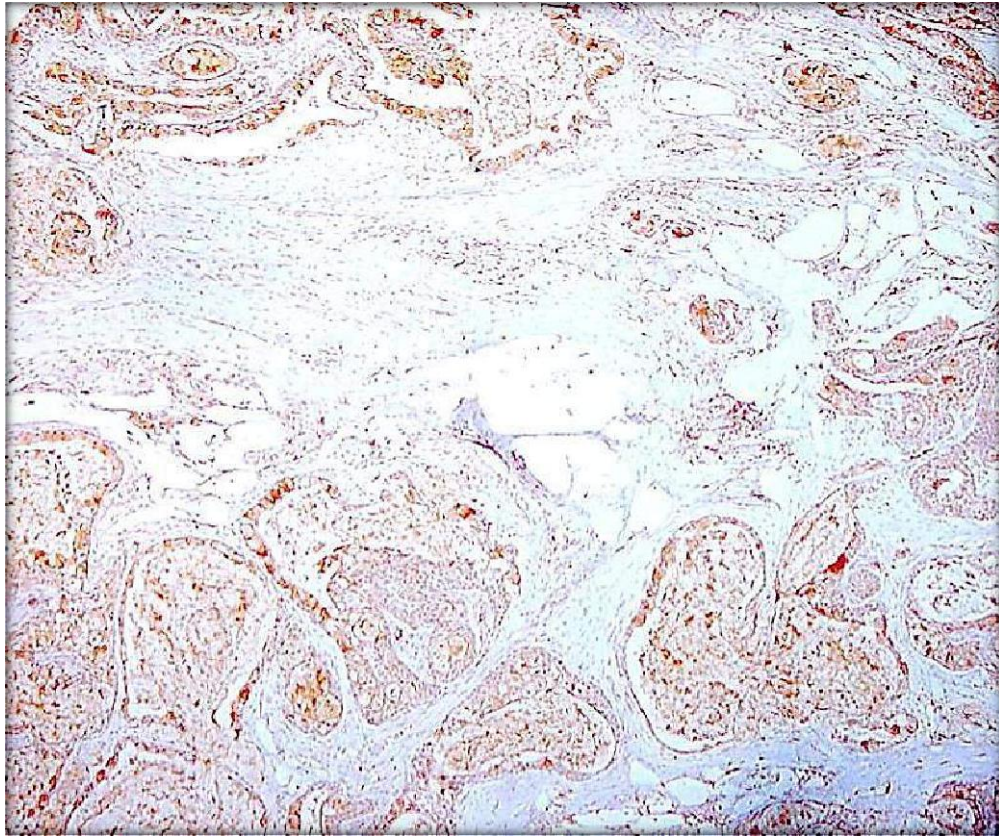
MEChistologicgrade(n=16)	XIAPfinalscore			% of Total	Pearson $\chi^2$ / Pvalue
	Weak	Moderate	Strong		
<b>Low-gradeMEC(n=3)</b>	2(66.7%)	1(33.3%)	0	18.75%	0.008
<b>IntermediategradeMEC(n=3)</b>	0	3(100%)	0	18.75%	
<b>High-gradeMEC (n=10)</b>	0	4(40%)	6(60%)	62.5%	
<b>Total(n=16)</b>	2(12.5%)	8(50%)	6(37.5%)	100%	

SignificanceisreachedwhenPvalue $\leq 0.05$ .

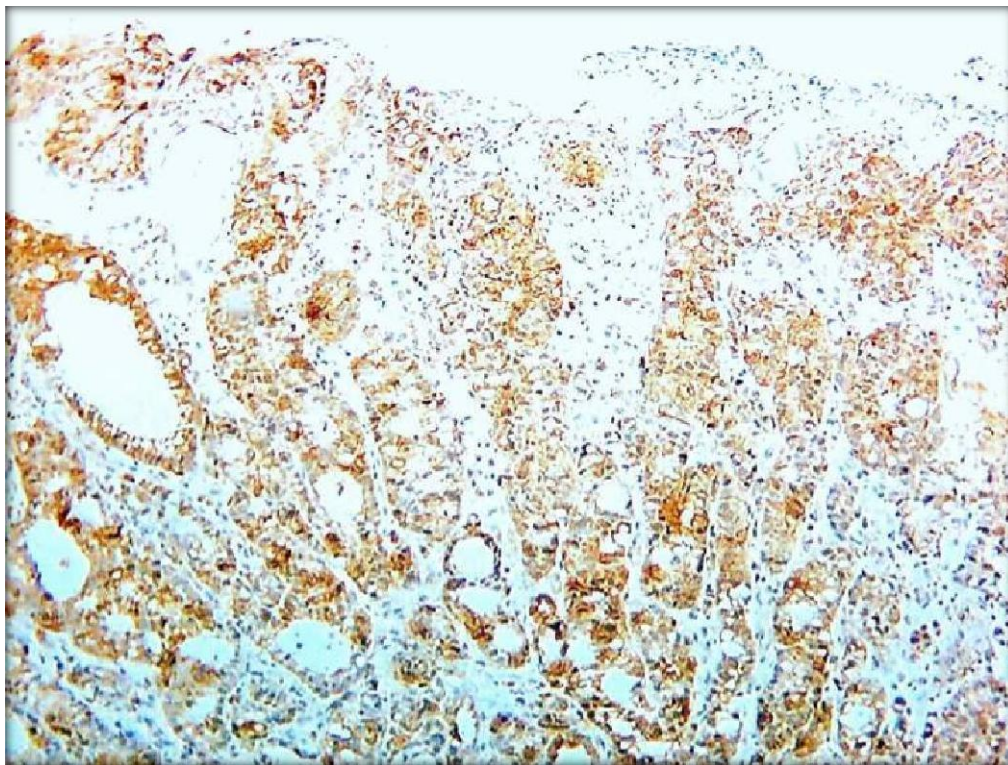
**Table7:CorrelationofXIAPexpressionwithMEChistologicgrade**

		Value	Asymp.Std. Error <sup>a</sup>	Approx.T <sup>b</sup>	Approx.Sig.
Intervalbyinterval	Pearson'sR	0.725	0.091	3.943	0.001 <sup>c</sup>
Ordinalbyordinal	SpearmanCorrelation	0.782	0.081	4.692	0.000 <sup>c</sup>
nofValidCases		16			

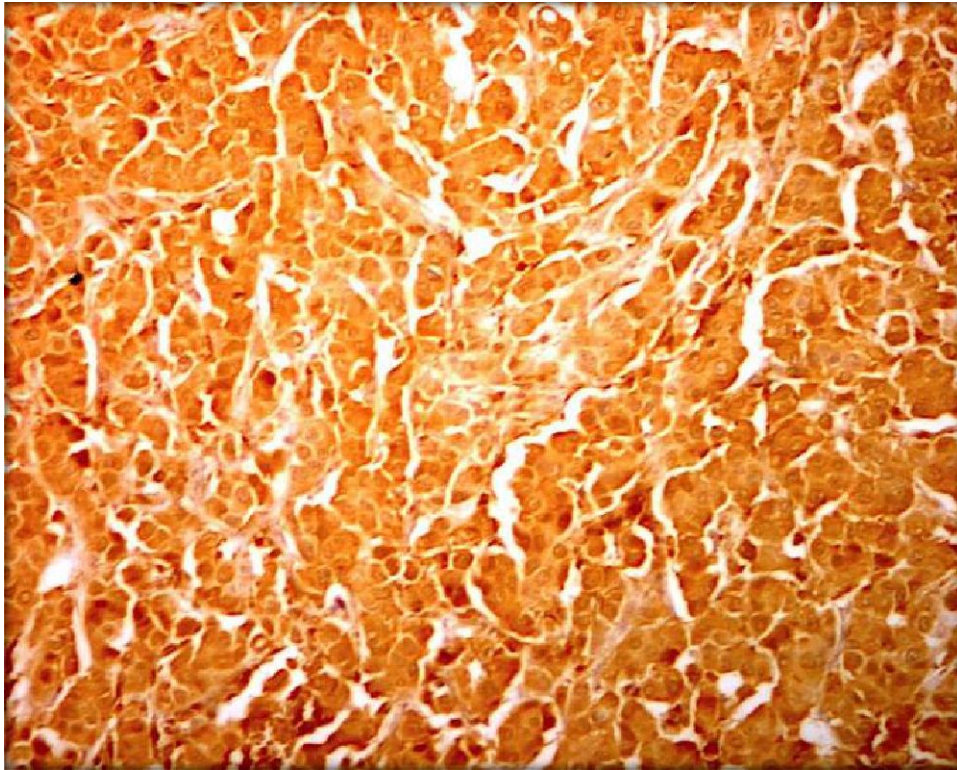
Pearsons $R < 0.5$ (weakpositivecorrelation), $R = 0.5-0.7$ (moderatepositivecorrelation), $R > 0.7$ (strongpositiveCorrelation).



**Figure5:** Low-grade MEC reveals weak XIAP expression (ABC-DAB, X250).



**Figure6:** Intermediate grade MEC reveals moderate XIAP expression (ABC-DAB, X250).



**Figure 7:** High grade MEC reveals strong XIAP expression (ABC-DAB, X250).

### **Discussion:**

Malignant salivary gland tumors are heterogeneous with significant morphological diversity and variable biology and clinical behavior (Speight and Barrett 2020). The current work investigated the tissue level of XIAP by immunohistochemistry in 16 MEC cases in a trial to understand if XIAP immunoreexpression is relevant to the histologic grading, biologic activity, and progression of mucoepidermoid carcinoma. In terms of patient's age, the mean age of the worked MEC cases was 61.44 years with almost 56.7% of the worked cases being older than 37 years. This search conducted by Binmadi et al. (2016) and Atallah et al. (2020) revealed a comparable age range (Binmadi, Elsissi, and Elsissi 2016), (Atallah et al. 2020). Regarding the anatomical location of the tumor, major salivary glands particularly the parotid gland presentation formed the majority of the currently studied MEC cases (87.5%). This result was consistent with earlier researches (Ga o et al., 2017), (Westergaard-Nielsen et al. 2021).

About 81.25% of handled MEC cases were discovered in advanced clinical stages (III and IV) according to TNM clinical staging. This aspect was previously discussed because the bulk of the cases under investigation were related to the parotid major salivary gland, which is known for having intra-glandular lymph nodes that may serve as a site for nodal metastasis (Wan et al. 2016). Further support for this interpretation was provided by the currently observed TNM stages I and II among the low-grade MEC patients. Similar results were reported in earlier researches (Belulescu et al. 2020), (van Weert et al. 2022).

The MEC histologic grade and XIAP expression showed considerable positive correlations (Pearson's  $R = 0.725$  and,  $P = 0.008$ ). This finding was supported by other studies as high XIAP expression was noted in the higher histologic grades of pancreatic cancer (Li et al. 2013) and breast ductal carcinomas (Jaffer et al. 2007), (de Moraes et al. 2015). In contradiction, opposite findings were documented in other studies on breast cancer (Xu et al. 2014a), and (Zhan et al. 2011). The high histologic grade of MEC cases of the current study was associated with both high XIAP expression and high clinical TNM stages. This might point to a possible relation between the high XIAP expression and the molecular changes occurring during tumor progression, leading to higher histologic grades. XIAP is an antiapoptotic protein that inhibits cell death, and its overexpression may contribute to the prolonged survival and continued growth of cancer cells, potentially leading to more aggressive tumor characteristics.

### **Conclusion:**

Based on the findings, the study concluded that the immunoexpression of XIAP correlates with the histologic grading of MEC. Additionally, XIAP immunoexpression reflects the clinical and biological behavior of MEC.

### **Ethical Approval and Consent:**

The present study was approved by IRB and the National Research Ethics Committee following the 1964 Helsinki Declaration and its later amendments (Faculty of Dentistry Ethical Committee, Mansoura University IRB). Informed consent was obtained from all participants involved in the study.

**Abbreviations:**

**MSGTs:** Malignant salivary gland tumors

**SGCs:** Salivary gland

carcinoma **MEC:** Mucoepidermoid

carcinoma **IHC:** Immunohistochemi

stry

**XIAP:** X-linked inhibitor of Apoptosis

**MSGs:** Major salivary glands

## References

1. Tranchito, Eve, et al. "Occult nodal metastasis in major salivary gland malignancy: an update from the National Cancer Database." *Oral Oncology* 128(2022): 105829.
2. Speight PM, Barrett AW. Salivary gland tumors: diagnostic challenges and an update on the latest WHO classification. *Diagnostic histopathology*. 2020 Apr 1; 26(4):147-158.
3. Coleman, Madison, et al. "Exploring the Epidemiology and Survival Trends in Pediatric Major Salivary Gland Malignancies: Insights from the National Cancer Database." *Current Oncology* 30.7 (2023): 6134-6147.
4. Tchekmedyian V. Salivary gland cancers. *Hematology/Oncology Clinics*. 2021 Oct 1; 35(5):973-990.
5. Xu, Bin, et al. "Critical Appraisal of Histologic Grading for Mucoepidermoid Carcinoma of Salivary Gland: Is an Objective Prognostic 2-tiered Grading System Possible?." *The American Journal of Surgical Pathology* 47.11 (2023): 1219-1229.
6. Shafique K, Zhang PJ, Montone KT, Song S, Livolsi VA, Baloch Z. Pathologic grading of mucoepidermoid carcinomas of the salivary gland and its effect on clinicopathologic follow-up: an institutional experience. *Human Pathology*. 2020 Apr 1; 98:89-97.
7. Amin MB, Greene FL, Edge SB, Compton CC, Gershenwald JE, Brookland RK, Meyer L, Gress DM, Byrd DR, Winchester DP. The eighth edition AJCC cancer staging manual: continuing to build a bridge from a population-based to a more "personalized" approach to cancer staging. *CA: a cancer journal for clinicians*. 2017 Mar; 67(2):93-99.
8. Nishida, Haruto, et al. "Histopathological aspects of the prognostic factors for salivary gland cancers." *Cancers* 15.4(2023):1236.
9. Barnes L, editor. *Pathology and genetics of head and neck tumors*. IARC; 2005.
10. Leivo I. Insights into a complex group of neoplastic disease: advances in histopathologic classification and molecular pathology of salivary gland cancer. *Acta Oncologica*. 2006 Jan 1; 45(6):662-668.
11. El-Naggar AK. What is new in the World Health Organization 2017 histopathology classification? *Current treatment options in oncology*. 2017 Jul; 18:1-4.
12. Ferreira Carlos G, Valk Paul van der, Span Simone W, Ludwig Inge, Smit Egbert F, Kruyt Frank AE, et al. Expression of X-linked Inhibitor of Apoptosis as a Novel Prognostic Marker in Radically Resected Non-Small Cell Lung Cancer Patients. *Clin Cancer Res*. 2001; 7:2468-74.
13. Ferreira, C. G., Van Der Valk, P., Span, S. W., Jonker, J. M., Postmus, P. E., Kruyt, F. A. E., & Giaccone, G. (2001). Assessment of IAP (inhibitor of apoptosis) proteins as predictors of response to chemotherapy in advanced non-small-cell lung cancer patients. *Annals of Oncology*, 12(6), 799-805. <https://doi.org/10.1023/A:1011167113067>
14. Ramp U, Krieg T, Caliskan E, Mahotka C, Ebert T, Willers R, Gabbert HE, Gerharz CD. XIAP expression is an independent prognostic marker in clear-cell renal carcinomas. *Hum Pathol*. 2004; 35(8):1022-28.

15. Schimmer AD, Dalili S, Batey RA, Riedl SJ. Targeting XIAP for the treatment of malignancy. *Cell Death Differ.* 2006;13:179–88.
16. Holcik M, Gibson H, Korneluk RG. XIAP: apoptotic brake and promising therapeutic target. *Apoptosis.* 2001;6:253–61.
17. Ning, Z. rong, Li, S., Guo, Y. wei, & Fang, D. ji. (2014). Expression and clinical significance of Cox-2 and XIAP in malignant tumors of the salivary gland. *Shanghai Kou Qiang Yi Xue = Shanghai Journal of Stomatology*, 23(3), 317–321.
18. Seethala RR. An update on grading of salivary gland carcinomas. *Head and neck pathology.* 2009Mar;3:69-77.
19. Xu, YC., Liu, Q., Dai, JQ. et al. Tissue microarray analysis of X-linked inhibitor of apoptosis (XIAP) expression in breast cancer patients. *Med Oncol* 31, 764 (2014). <https://doi.org/10.1007/s12032-013-0764-8>
20. Binmadi N, Elsissi A, Elsissi N. Expression of cell adhesion molecule CD44 in mucoepidermoid carcinoma and its association with the tumor behavior. *Head & Face Medicine.* 2016Dec;12(1):1-5.
21. Atallah S, Casiraghi O, Fakhry N, Wassef M, Uro-Coste E, Espitalier F, Sudaka A, Kaminsky MC, Dakpe S, Digue L, Bouchain O. A prospective multicentre REFCOR study of 470 cases of head and neck Adenoid cystic carcinoma: epidemiology and prognostic factors. *European Journal of Cancer.* 2020;1;130:241-249.
22. Gao M, Hao Y, Huang MX, Ma DQ, Chen Y, Luo HY, Gao Y, Cao ZQ, Peng X, Yu GY. Salivary gland tumors in a northern Chinese population: a 50-year retrospective study of 7190 cases. *International journal of oral and maxillofacial surgery.* 2017Mar1;46(3):343-349.
23. Westergaard-Nielsen M, Godballe C, Eriksen JG, Larsen SR, Kiss K, Agander T, Ulhøi BP, Charabi B, Klug TE, Jacobsen H, Johansen J. Salivary gland carcinoma in Denmark: a national update and follow-up on incidence, histology, and outcome. *European Archives of Oto-Rhino-Laryngology.* 2021Apr;278:1179-1188.
24. Wang HZ, Cao CN, Luo JW, Yi JL, Huang XD, Zhang SP, Wang K, Qu Y, Xiao JP, Li SY, Gao L. High-risk factors of parotid lymph node metastasis in nasopharyngeal carcinoma: a case-control study. *Radiation Oncology.* 2016;11:1-7.
25. Belulescu IC, Margaritescu C, Dumitrescu CI, Dăguci L, Munteanu C, Margaritescu OC. Adenoid cystic carcinoma of salivary gland: a ten-year single institute experience. *Current health sciences journal.* 2020;46(1):56.
26. van Weert S, Valstar M, Lissenberg-Witte B, Bloemena E, Smit L, van der Wal J, Vergeer M, Smeele L, Leemans CR. Prognostic factors in acinic cell carcinoma of the head and neck: The Amsterdam experience. *Oral Oncology.* 2022;1;125:105698.
27. LI, S., SUN, J., YANG, J., ZHANG, L., WANG, L., WANG, X., & GUO, Z. (2013). XIAP
28. expression is associated with pancreatic carcinoma outcome. *Molecular and Clinical Oncology*, 1(2), 305–308.
29. Jaffer, S., Orta, L., Sunkara, S., Sabo, E., & Burstein, D. E. (2007). Immunohistochemical detection of

antiapoptotic protein X-linked inhibitor of apoptosis in mammary carcinoma. *Human Pathology*,38(6), 864–870.

30. de Moraes, G.N., Delbue, D., Silva, K.L., Robaina, M.C., Khongkow, P., Gomes, A.R., ... Maia, R.C. (2015). FOXM1 targets XIAP and Survivin to modulate breast cancer survival and chemoresistance. *Cellular Signalling*, 27(12), 2496–2505.

31. Zhang, Y., Zhu, J., Tang, Y., Li, F., Zhou, H., Peng, B., ... Fu, R. (2011). X-linked inhibitor of apoptosis positive nuclear labeling: A new independent prognostic biomarker of breast invasive ductal carcinoma. *Diagnostic Pathology*, 6(1).

### **Figure legends:**

**Figure 1:** Low-

grade mucoepidermoid carcinoma shows multiple cystic spaces filled with mucin (H&E x 200)

**Figure 2:** Intermediate-grade mucoepidermoid carcinoma shows nests of epidermoid cells, a few small-sized cystic cavities, and numerous sheets of intermediate cells in the connective tissue background (H&E x 200).

**Figure 3:** High-grade mucoepidermoid carcinoma reveals minimal cystic spaces, solid nests of epidermoid cells with marked cellular atypia (H&E x 100).

**Figure 4:** High-grade mucoepidermoid carcinoma reveals minimal cystic spaces, and solid nests of epidermoid cells with marked cellular atypia (H&E x 400).

**Figure 5:** Low-grade MEC reveals weak XIAP expression (ABC-DAB, X250).

**Figure 6:** Intermediate-grade MEC reveals moderate XIAP expression (ABC-DAB, X250).

**Figure 7:** High-grade MEC reveals strong XIAP expression (ABC-DAB, X250).