

Immunohistochemical expression of XIAP in mucoepidermoid carcinoma

Abstract:

Objective:

The X-linked inhibitor of apoptosis protein IHC expression was employed to assess the anti-apoptotic activity of MECs in relation to different clinicopathological variables to understand if XIAP immunoexpression is reflecting the histologic grade and it can be utilised in assessing the biologic activity and prognosis in MEC patients.

Materials and methods:

A retrospective study was accomplished on 16 MEC cases. The worked MEC cases involved the three histologic grades, low, intermediate, and high. The XIAP immunoexpression was assessed in relation to the different clinicopathological parameters. The analysis of data was done by Pearson's Chi-square test, and One-Way ANOVA test to compare the difference between the studied groups. Pearson correlation co-efficiency test was used to test the association between the different variables. The P-value <0.05 was considered to be statistically significant.

Results:

The expression of XIAP was assessed concerning different clinicopathological parameters of MEC. There were statistically significant differences in XIAP immunoexpression in relation to the following parameters; the TNM clinical stage ($P=0.036$), and the histologic grade ($P=0.008$). Conversely, the immunoexpression of XIAP was not significantly correlated with patients' age ($P=0.141$), patients' gender ($P= 0.471$), and the anatomical site of the tumor ($P=0.827$) in MEC cases.

Conclusion:

- The immunoexpression of XIAP correlates with the histologic grading of MEC.
- XIAP immunoexpression reflects the clinical and biological behavior of MEC.

Introduction:

The biology and clinical behaviour of malignant salivary gland tumors (MSGTs) vary widely, indicating their heterogeneity (Tchekmedyian 2021). Since salivary gland tumors have a wide range of morphological characteristics and many overlapping signs, they are among the most challenging cases in diagnostic pathology (Speight and Barrett 2020). The most frequent MSGT, accounting for over 50% of cases, is mucoepidermoid carcinoma (MEC) (Tchekmedyian 2021), (Fonseca et al., 2012), (Bradley and McGurk 2013). According to Regezi and Sciubba (2017), MEC's biological behaviour varies from being comparatively indolent (low grade) to being clinically aggressive (high grade). The prognosis for MEC varies significantly and is mostly based on the tumor's pathologic grade (Regezi, Sciubba 2017), (Shafique et al. 2020).

Salivary gland carcinomas' (SGCs) histologic grading has been demonstrated to be a reliable indicator of the tumors' behaviour and to be important in therapy optimization. It is not advisable to attempt to apply universal grading standards to SGCs because they typically exhibit intrinsic biological behavior (Amin et al. 2017). New tools for immunohistochemical (IHC) diagnosis and prognostication, such as cell-proliferation markers, anti-apoptotic proteins, myoepithelial antigens, matrix metalloproteinases, steroid receptors, growth factors, and their receptors, have been combined with recent developments in histopathological classification. These have increased our options for treating a range of SGCs with more targeted therapies. (Barnes et al., 2005), (Leivo 2006) Trials aimed at supplying more cues and indications regarding the identification of proteins that regulate biological processes like mitosis are therefore necessary for more accurate assessment and, as a result, contribute in improved management approaches (El-Naggar 2017).

Tumorigenesis involves a loss of balance between regulators of cell proliferation and apoptosis (Ferreira et al. 2001). Apoptotic cell death plays an important physiological role in normal development and tissue homeostasis. Dysregulation of apoptosis has been implicated in carcinogenesis, tumor progression, and resistance of tumor cells to chemotherapy (Ramp et al. 2004). XIAP is considered the most potent IAP as it inhibits caspases 3, 7, and 9, thereby blocking both the intrinsic (mitochondria-mediated) and extrinsic (death receptor-mediated)

apoptotic pathways (Schimmer et al. 2006), (Holcik, Gibson, and Korneluk 2001). The present research hypothesized that the level of **XIAP expression** might correlate with the biological characteristics of MEC cases as a measure of apoptosis. Therefore, we investigated whether alterations in XIAP immunostaining in tumor cells could predict the clinicopathological factors of prognostic importance in MEC.

Materials and methods:

The current work is a retrospective study, for which a total of 16 paraffin tissue blocks of MEC. All the included cases had a **confirmed diagnosis** of MEC. The selected cases had received surgical treatment, hadn't received any form of adjuvant therapy before their surgery, had arisen from **salivary glands**, and had complete clinical and follow-up records. Cases that had insufficient or inoperable biopsy specimens, and missing medical, clinical, or follow-up records were excluded from the study. The current work included 16 cases of MEC cases which were categorized into three histologic grades (low, intermediate, and high grade) following the criteria of Modified Healey classification (Seethala 2009).

Tissue blocks and records belonging to the studied cases were obtained from the archive of the Oncology unit of the Oncology Center, Faculty of Medicine, Mansoura University. The present study was approved by IRB and the National Research Ethics Committee following the 1964 Helsinki Declaration and its later amendments (Faculty of Dentistry Ethical Committee, Mansoura University IRB). Informed consent was obtained from all participants involved in the study.

Immunohistochemistry:

From each paraffin block sections of 4 microns thickness were cut. Tissue sections were mounted on **coated slides**. Rehydration of the slides with varying alcohol and water concentrations comes after deparaffinization. The slides were cooked in the microwave for ten minutes in a 0.01 M citric acid buffer (pH = 6.0) for antigen retrieval. Slides were incubated in methanol containing 3% H₂O₂ for 15 minutes to inactivate endogenous peroxidase. After that, they were rinsed with distilled water. Applying the primary antibody to XIAP and a rabbit polyclonal antibody against humans, which comes in a vial with 20 µl

of ready-to-use antibodies Abclonal Technology. The streptavidin-biotin complex technique and an overnight incubation period at 4 °C were used to carry out the immunoreaction. Sections of kidney cancer were stained at the same batch and under the same conditions to serve as a positive control of the reaction with the employed antibody (XIAP). Negative control slides were produced by substituting plain PBS for the principal antibody.

Cytoplasmic and nuclear staining of XIAP was scored by a conventional four-tiered semi-quantitative scoring method described by Xu YC et al (Xu et al. 2014a). Staining intensity was graded on a semiquantitative scale (1+, weak; 2+, moderate; and 3+, strong). The extent of staining was scored as 0 (less than 5 %); score 1, focal (6–25 %); score 2, multifocal (26–50 %); score 3, regional (51–75 %); and score 4, diffuse (76–100 %). Next, stain intensity was multiplied by the extent of stain, and cut-off was set as follows: scores 0–2 negative, 3–5 weak, 6–8 moderate, and greater than or equal to 9 strong.

Statistical Analysis:

In order to identify any potentially significant differences or correlations between the various variables, the study's findings were statistically examined. The Statistical Package for Social Science (SPSS) version 22 program and the Excel program were used to perform the statistical analysis of the data. For quantitative data, the mean (+/-) Standard Deviation (SD) was used to describe the data; for qualitative data, frequency and proportion were used. The data was analyzed using Pearson's Chi-square test and One-Way ANOVA test to assess the differences between the study groups. To examine the relationship between the various variables, the Pearson correlation co-efficiency test was employed. A P-value of less than 0.05 was considered statistically significant.

Results:

The presently studied MEC group (16 cases) was comprised of three males (18.75%) and 13 females (81.25%) with a mean age of 61 years, ranging from 37 to 76 years. Most of the cases of MEC were presented in the major salivary glands (87.5%) particularly the parotid. The reported clinical stage in most (81.25%) of the MEC group was among the stage groups III (11/16), while the rest of the cases were equally distributed among stage I (3/16) and II (2/16). Clinical characteristics of the worked MECs are illustrated in Table 1.

Table 1: Clinical parameters of the studied MEC group (n=16)

MEC (n=16)			
Patient's ages	mean	61.44	
	minimum	37	
	maximum	76	
Clinical parameter	Groups	Number of cases	%
Gender	Male	3	18.75
	Female	13	81.25
Site	Major SG	14	87.5
	Minor SG	2	12.5
TNM stage	I	3	18.75
	III	11	68.75
	IV	2	12.5
TNM stage groups	I	3	18.75
	III and IV	13	81.25

Clinical characteristics of the worked MECs in relation to XIAP expression

XIAP IHC presented nuclear & cytoplasmic expression in the majority of the worked MECs. Upon correlating XIAP immunoexpression with different clinical parameters, Pearson's chi-square test revealed significant differences in its expression concerning the following parameters; the TNM clinical stage of MEC ($P=0.036$), and the histologic grade ($P=0.008$) of MECs. Conversely, the immunoexpression of XIAP was not significantly correlated with patients' ages ($P=0.141$), patients' gender ($P= 0.471$), and the anatomical site of the tumor ($P=0.827$).

Regarding age Patients who were older than 61 years showed equal expressions of 33.3% between weak (2 cases), moderate (2 cases), and strong (2 cases) XIAP expression while younger patients <61 had moderate 6 cases (60%) and strong 4 cases (40%) XIAP expression. (Pearson's chi-square test, $P= 0.141$) Table 1, Chart 6). There was no statistically significant difference in XIAP expression in MEC between the two age groups ($P=0.141$).

Regarding patients' gender of MEC cases, Pearson's Chi-square test revealed no statistically significant difference in XIAP expression between males and females. Males presented

moderate (one case 33.3%) to strong (2 cases 66.7%) XIAP expressions while the females showed weak (2 cases, 15.4%), moderate (7 cases 53.8), and strong (4 cases 30.8%) XIAP expressions.

According to the anatomical site of involvement, there were no statistically significant differences in XIAP immuno-expression considering the different sites of MECs using the Pearson Chi-square test ($P=0.827$).

Moreover, the worked MEC cases that had an advanced clinical stage (III and IV) demonstrated significantly high XIAP immuno-expression. All the worked stage IV cases showed moderate (1 case, 50%) to strong (1 case 50%) XIAP expressions. Stage III showed moderate (6 cases, 54.5%) to strong (5 cases 45.5%) XIAP expressions. Oppositely, all stage I cases showed weak (2 cases, 66.7%), and moderate (one case 33.3%). Pearson's chi-square test demonstrated a high statistically significant difference in XIAP expression among the different TNM clinical stages in MEC ($p=0.036$)

Pathological characteristics of the worked MECs in relation to XIAP expression

Mucoepidermoid carcinoma of the current work was characterized by the presence of variable proportions of three types of cells; mucous-secreting cells, epidermoid cells, and intermediate cells. This group was classified into three histologic grades (low, intermediate, and high) following the criteria of Modified Healey classification (Seethala 2009). The greater number of MEC cases was represented in the high grade (10 cases, 62.4%) while the low and intermediate grades of MECs were represented in three cases for each grade (18.8%). Grading of MEC revealed variation according to the relative number of cystic spaces, the relative proportion of the constituent cells, and the degree of cellular atypia. Low-grade carcinomas demonstrated numerous cystic spaces that were filled with mucin, increased proportion of mucous-secreting cells, and decreased cellular atypia. On the other hand, high-grade carcinomas demonstrated solid proliferation of cells, increased proportion of epidermoid cells, and marked cellular atypia. The histopathologic picture of intermediate-grade carcinoma was in the midway between low-grade and high-grade carcinomas (Figures 1-3).

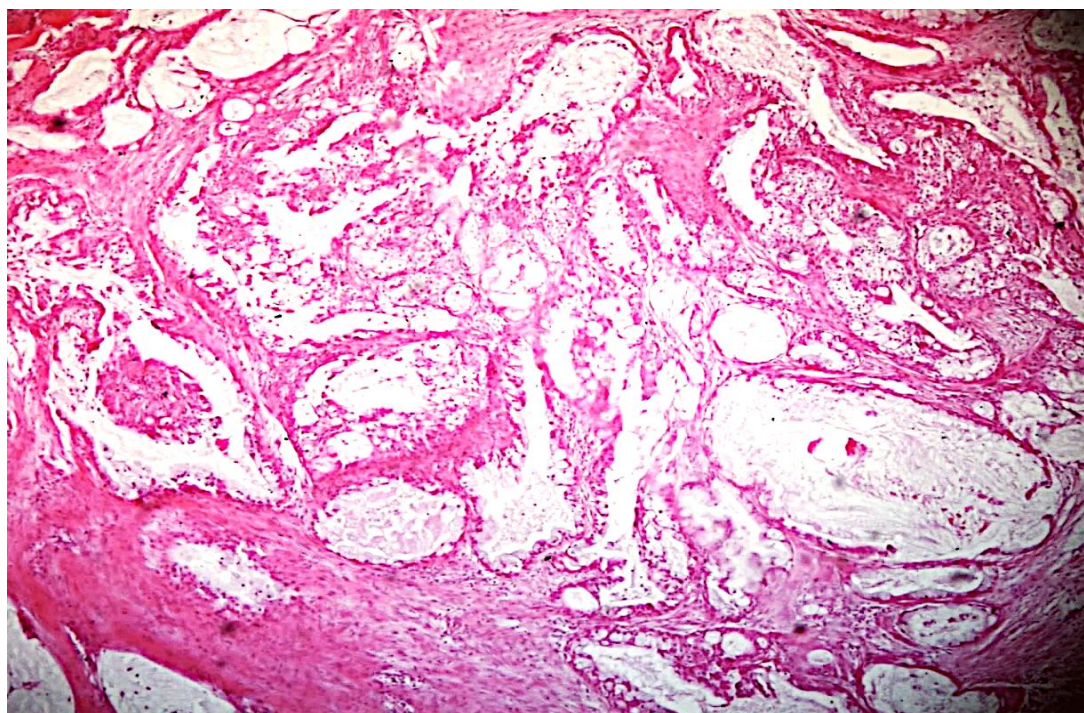


Figure 1: Low-grade mucoepidermoid carcinoma shows multiple cystic spaces filled with mucin (H&E x 200).

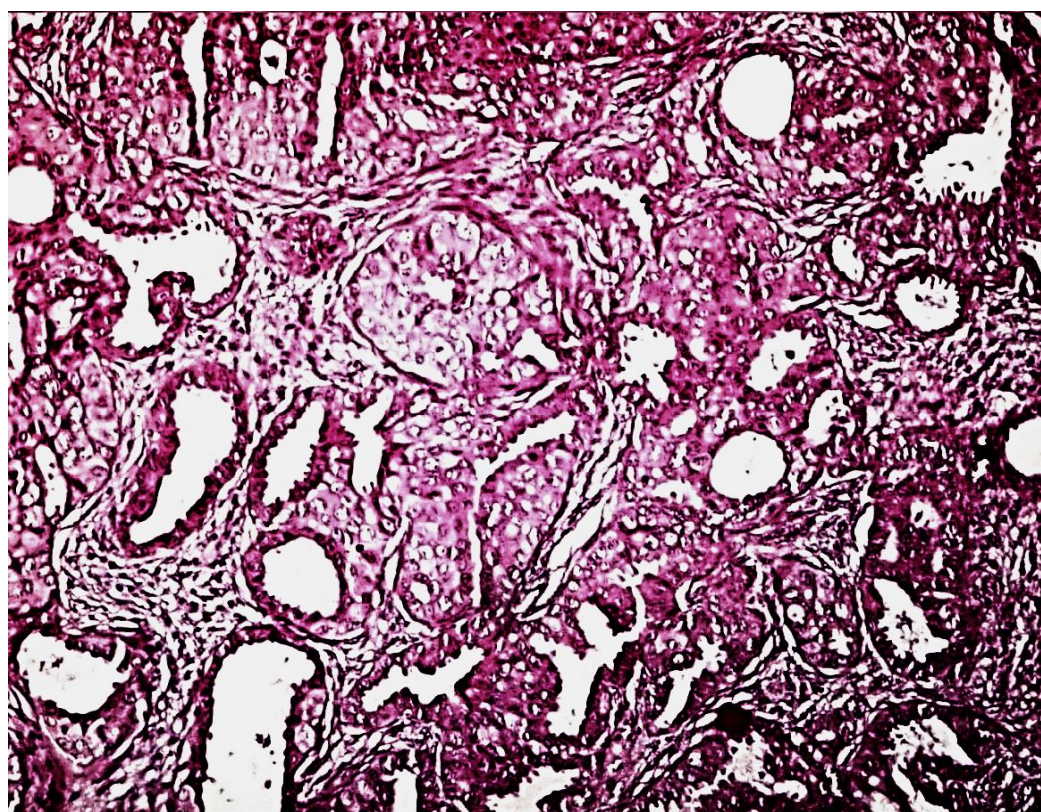


Figure 2: Intermediate-grade mucoepidermoid carcinoma shows nests of epidermoid cells, a few small-sized cystic cavities, and numerous sheets of intermediate cells in the connective tissue background (H&E x 200).

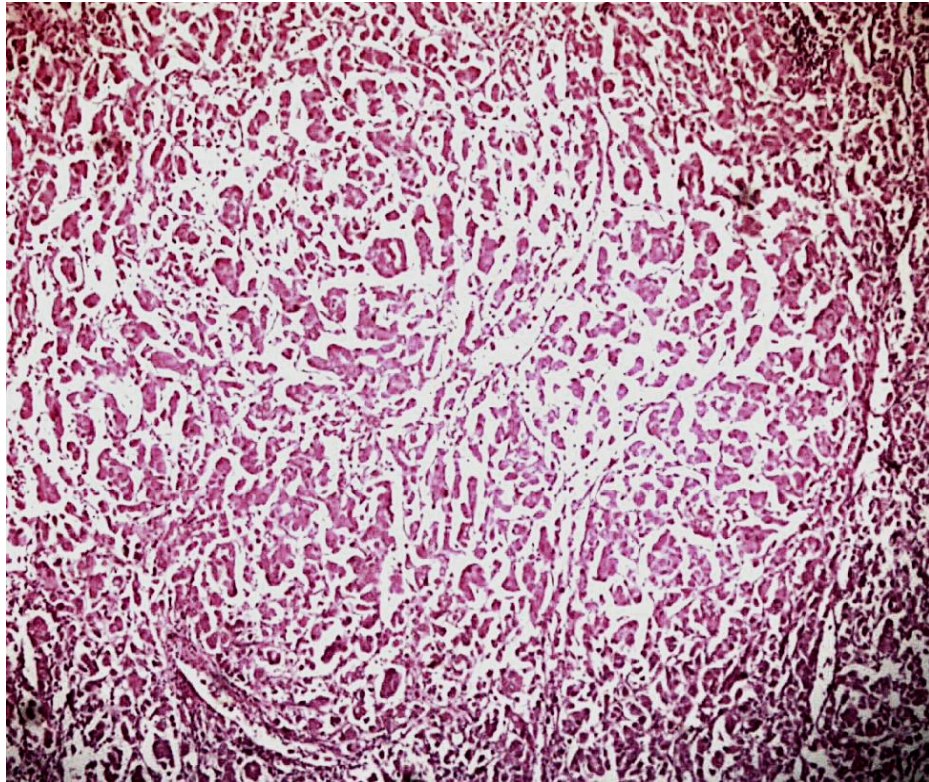


Figure 3: High grade mucoepidermoid carcinoma reveals minimal cystic spaces, solid nests of epidermoid cells with marked cellular atypia (H&E x 100).

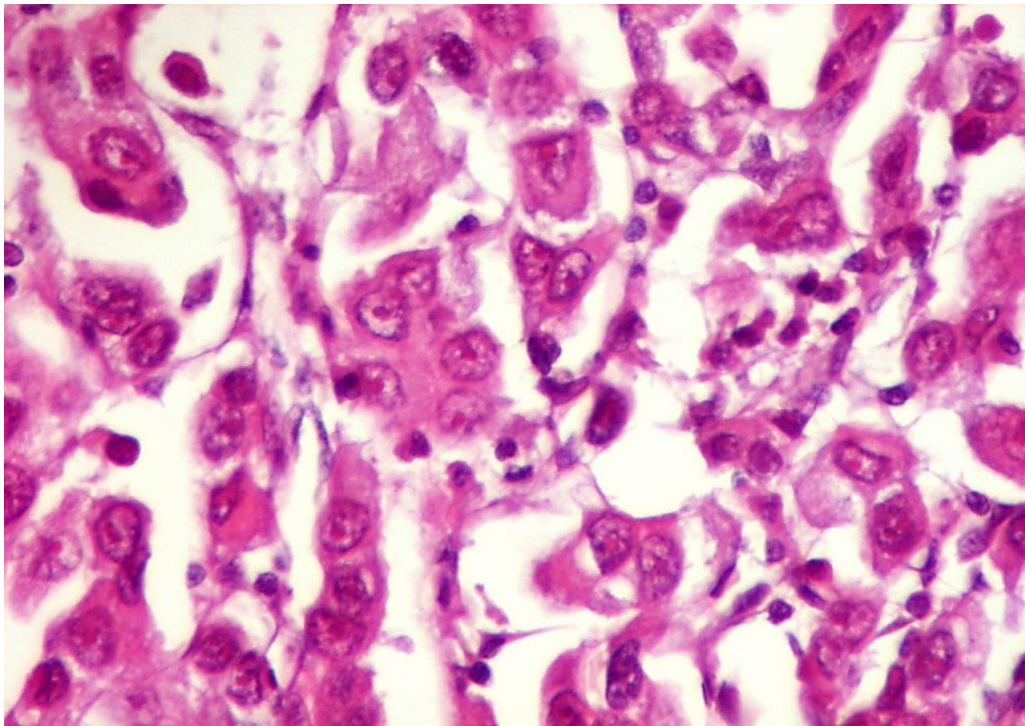


Figure 4: High-grade mucoepidermoid carcinoma reveals minimal cystic spaces, and solid nests of epidermoid cells with marked cellular atypia (H&E x 400).

Regarding the MEC histologic grade, there was a strong positive correlation of PHH3 expression with the MEC histologic grade ($P=0.008$). Two cases (66.7%) of the low-grade MEC showed weak XIAP expression (figure 4). More than half (60%) of the high-grade MEC showed strong expression (figure 6). All the worked intermediate-grade MEC (3 cases) showed moderate XIAP expression (figure 5). Using Pearsons' chi-square test ($p=0.008$) revealed a high statistically significant difference in XIAP IHC expression among the different MEC histologic grades. Moreover, a strong positive correlation was detected between XIAP expression and MEC histologic grade (Pearson's $R = 0.000$) (table 2-3).

Table 2: XIAP expression in relation to the MEC histologic grade

MEC histologic grade (n=16)	XIAP final score			% of Total	Pearson X^2 / P value
	weak	Moderate	Strong		
Low-grade MEC (n=3)	2(66.7%)	1(33.3%)	0	18.75%	0.008
Intermediate grade MEC (n=3)	0	3(100%)	0	18.75%	
High-grade MEC (n=10)	0	4(40%)	6(60%)	62.5%	
Total (n=16)	2(12.5%)	8(50%)	6(37.5%)	100%	

Significance is reached when P value ≤ 0.05 .

Table 3: XIAP expression in relation to the MEC histologic grade

		Value	Asymp. Std. Error ^a	Approx. T ^b	Approx. Sig.
Interval by interval	Pearson's R	0.725	0.091	3.943	0.001 ^c
Ordinal by ordinal	Spearman Correlation	0.782	0.081	4.692	0.000 ^c
n of Valid Cases		16			

Pearsons $R=0.5-0.7$ moderate positive correlation $R>0.7$ strong positive, $R<0.5$ weak positive

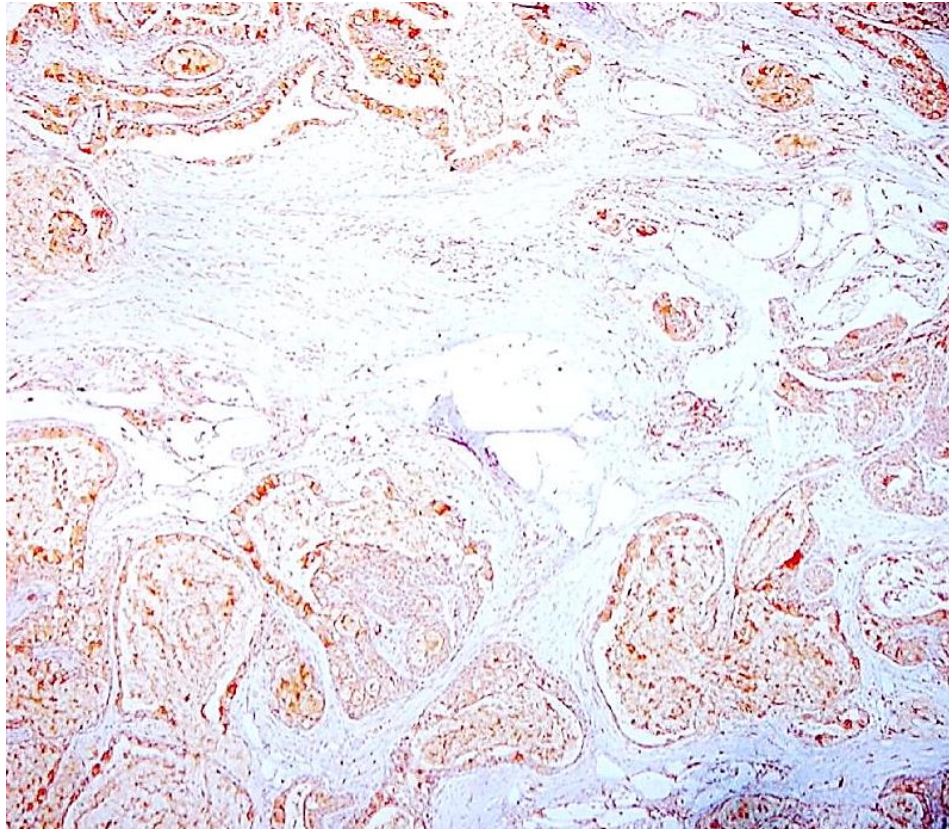


Figure 5: Low grade MEC reveals weak XIAP expression (ABC- DAB, X250).

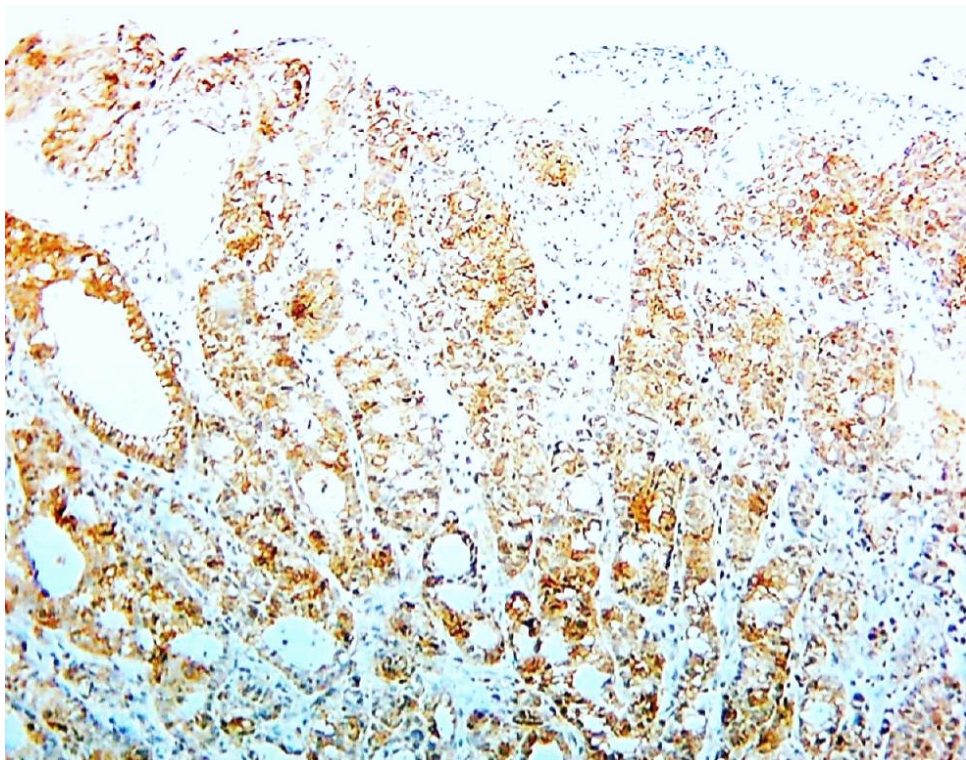


Figure 6: Intermediate grade MEC reveals moderate XIAP expression (ABC- DAB, X250).

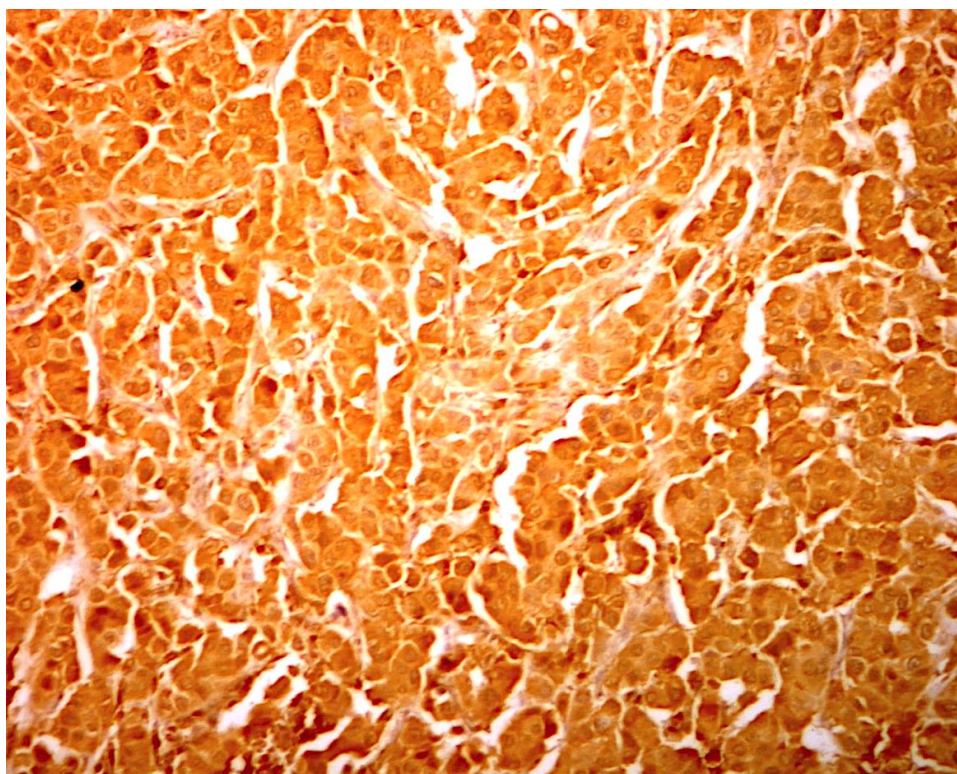


Figure 7: High grade MEC reveals strong XIAP expression (ABC- DAB, X250).

Discussion:

Malignant salivary gland tumors are heterogeneous with significant morphological diversity and variable biology and clinical behavior (Speight and Barrett 2020) The current work investigated the tissue level of XIAP by immunohistochemistry in 16 MEC cases in a trial to understand if XIAP immunoexpression is relevant to the histologic grading and if it can be utilized in assessing the progression and recurrence of MEC.

In terms of patient's age, the mean age of the worked MEC cases was 61.44 years with almost 56.7% of the worked cases being older than 37 years. The research conducted by Binmadi et al. (2016) and Atallah et al. (2020) revealed a comparable age range (Binmadi, Elsissi, and Elsissi 2016), (Atallah et al. 2020).

Regarding the anatomical location of the tumor, major salivary glands particularly the parotid gland presentation formed the majority of the currently studied MEC (87.5%). This result was consistent with earlier researches (Gao et al., 2017), (Westergaard-Nielsen et al. 2021).

About 81.25% of handled MEC cases were discovered in advanced clinical stages (III and IV) according to TNM clinical staging. This aspect was previously discussed because the bulk of the cases under investigation were related to the parotid major salivary gland, which is known for having intra-glandular lymph nodes that may serve as a site for nodal metastasis-(Wang et al. 2016). Further support for this interpretation was provided by the currently observed TNM stages I and II among the low-grade MEC patients. Similar results were reported in earlier researches (Belulescu et al. 2020), (van Weert et al. 2022).

The MEC histologic grade and XIAP expression showed considerable positive correlations (Pearson's $R= 0.725$ and, $P=0.008$). This finding was supported by other studies as high XIAP expression was noted in the higher histologic grades of pancreatic cancer (LI et al. 2013) and breast ductal carcinomas (Jaffer et al. 2007), (de Moraes et al. 2015). In contradiction, opposite findings were documented in other studies on breast cancer (Xu et al. 2014a) ,and (Zhang et al. 2011). The high histologic grade of MEC cases of the current study was associated with both high XIAP expression and high clinical TNM stages. This might point to a possible relation between the high XIAP expression and the molecular changes occurring during tumor progression, leading to higher histologic grades. XIAP is an antiapoptotic protein that inhibits cell death, and its overexpression may contribute to the prolonged survival and continued growth of cancer cells, potentially leading to more aggressive tumor characteristics.

Conclusion:

- The immunoexpression of XIAP correlates with the histologic grading of MEC.
- XIAP immunoexpression reflects the clinical and biological behavior of MEC.

Abbreviations:

MSGTs: Malignant salivary gland tumors

SGCs: Salivary gland carcinoma

MEC: Mucoepidermoid carcinoma

IHC: Immunohistochemistry

XIAP: X-linked inhibitor of Apoptosis

MSGs: Major salivary glands

References

1. Tchekmedyian V. Salivary gland cancers. *Hematology/Oncology Clinics*. 2021 Oct 1;35(5):973-990.
2. Speight PM, Barrett AW. Salivary gland tumours: diagnostic challenges and an update on the latest WHO classification. *Diagnostic histopathology*. 2020 Apr 1;26(4):147-158.
3. Fonseca FP, de Vasconcelos Carvalho M, de Almeida OP, Rangel AL, Takizawa MC, Bueno AG, Vargas PA. Clinicopathologic analysis of 493 cases of salivary gland tumors in a Southern Brazilian population. *Oral surgery, oral medicine, oral pathology and oral radiology*. 2012 Aug 1;114(2):230-239.
4. Bradley PJ, McGurk M. Incidence of salivary gland neoplasms in a defined UK population. *British Journal of Oral and Maxillofacial Surgery*. 2013 Jul 1;51(5):399-403.
5. Regezi JA, Sciubba J, Jordan RC. *Oral pathology: clinical pathologic correlations*. Elsevier Health Sciences;2016 Feb 25
6. Shafique K, Zhang PJ, Montone KT, Song S, Livolsi VA, Baloch Z. Pathologic grading of mucoepidermoid carcinomas of the salivary gland and its effect on clinicopathologic follow-up: an institutional experience. *Human Pathology*. 2020 Apr 1;98:89-97.
13. Amin MB, Greene FL, Edge SB, Compton CC, Gershewald JE, Brookland RK, Meyer L, Gress DM, Byrd DR, Winchester DP. The eighth edition AJCC cancer staging manual: continuing to build a bridge from a population-based to a more “personalized” approach to cancer staging. *CA: a cancer journal for clinicians*. 2017 Mar;67(2):93-99.
14. Barnes L, editor. *Pathology and genetics of head and neck tumours*. IARC; 2005.
15. Leivo I. Insights into a complex group of neoplastic disease: advances in histopathologic classification and molecular pathology of salivary gland cancer. *Acta Oncologica*. 2006 Jan 1;45(6):662-668.
16. El-Naggar AK. What is new in the World Health Organization 2017 histopathology classification?. *Current treatment options in oncology*. 2017 Jul;18:1-4.
17. Ferreira Carlos G, Valk Paul van der, Span Simone W, Ludwig Inge, Smit Egbert F, Kruijff Frank AE, et al. Expression of X-linked Inhibitor of Apoptosis as a Novel Prognostic Marker in Radically Resected Non-Small Cell Lung Cancer Patients. *Clin Cancer Res*. 2001;7:2468–74. [PubMed] [Google Scholar]
18. Ramp U, Krieg T, Caliskan E, Mahotka C, Ebert T, Willers R, Gabbert HE, Gerharz CD. XIAP expression is an independent prognostic marker in clear-cell renal carcinomas. *Hum Pathol*. 2004;35(8):1022–28. [PubMed] [Google Scholar]

19. Schimmer AD, Dalili S, Batey RA, Riedl SJ. Targeting XIAP for the treatment of malignancy. *Cell Death Differ.* 2006;13:179–88. [PubMed] [Google Scholar]
20. Holcik M, Gibson H, Korneluk RG. XIAP: apoptotic brake and promising therapeutic target. *Apoptosis.* 2001;6:253–61. [PubMed] [Google Scholar]
21. Seethala RR. An update on grading of salivary gland carcinomas. *Head and neck pathology.* 2009 Mar;3:69-77.
22. Xu, YC., Liu, Q., Dai, JQ. et al. Tissue microarray analysis of X-linked inhibitor of apoptosis (XIAP) expression in breast cancer patients. *Med Oncol* 31, 764 (2014). <https://doi.org/10.1007/s12032-013-0764-8>
23. Binmadi N, Elssissi A, Elssissi N. Expression of cell adhesion molecule CD44 in mucoepidermoid carcinoma and its association with the tumor behavior. *Head & Face Medicine.* 2016 Dec;12(1):1-5.
24. Atallah S, Casiraghi O, Fakhry N, Wassef M, Uro-Coste E, Espitalier F, Sudaka A, Kaminsky MC, Dakpe S, Digue L, Bouchain O. A prospective multicentre REFCOR study of 470 cases of head and neck Adenoid cystic carcinoma: epidemiology and prognostic factors. *European Journal of Cancer.* 2020;1;130:241-249.
25. Gao M, Hao Y, Huang MX, Ma DQ, Chen Y, Luo HY, Gao Y, Cao ZQ, Peng X, Yu GY. Salivary gland tumours in a northern Chinese population: a 50-year retrospective study of 7190 cases. *International journal of oral and maxillofacial surgery.* 2017 Mar 1;46(3):343-349.
26. Westergaard-Nielsen M, Godballe C, Eriksen JG, Larsen SR, Kiss K, Agander T, Ulhøi BP, Charabi B, Klug TE, Jacobsen H, Johansen J. Salivary gland carcinoma in Denmark: a national update and follow-up on incidence, histology, and outcome. *European Archives of Oto-Rhino-Laryngology.* 2021 Apr;278:1179-1188.
27. Wang HZ, Cao CN, Luo JW, Yi JL, Huang XD, Zhang SP, Wang K, Qu Y, Xiao JP, Li SY, Gao L. High-risk factors of parotid lymph node metastasis in nasopharyngeal carcinoma: a case-control study. *Radiation Oncology.* 2016;11:1-7.
28. Belulescu IC, Margaritescu C, Dumitrescu CI, DĂguci L, Munteanu C, Margaritescu OC. Adenoid cystic carcinoma of salivary gland: a ten-year single institute experience. *Current health sciences journal.* 2020;46(1):56.
29. van Weert S, Valstar M, Lissenberg-Witte B, Bloemena E, Smit L, van der Wal J, Vergeer M, Smeele L, Leemans CR. Prognostic factors in acinic cell carcinoma of the head and neck: The Amsterdam experience. *Oral Oncology.* 2022;1;125:105698.
30. LI, S., SUN, J., YANG, J., ZHANG, L., WANG, L., WANG, X., & GUO, Z. (2013). XIAP expression is associated with pancreatic carcinoma outcome. *Molecular and Clinical Oncology*, 1(2), 305–308.
31. Jaffer, S., Orta, L., Sunkara, S., Sabo, E., & Burstein, D. E. (2007). Immunohistochemical detection of antiapoptotic protein X-linked inhibitor of apoptosis in mammary carcinoma. *Human Pathology*, 38(6), 864–870.

32. de Moraes, G. N., Delbue, D., Silva, K. L., Robaina, M. C., Khongkow, P., Gomes, A. R., ... Maia, R. C. (2015). FOXM1 targets XIAP and Survivin to modulate breast cancer survival and chemoresistance. *Cellular Signalling*, 27(12), 2496–2505.

33. Zhang, Y., Zhu, J., Tang, Y., Li, F., Zhou, H., Peng, B., ... Fu, R. (2011). X-linked inhibitor of apoptosis positive nuclear labeling: A new independent prognostic biomarker of breast invasive ductal carcinoma. *Diagnostic Pathology*, 6(1).

Figure legends:

Figure 1: Low-grade mucoepidermoid carcinoma shows multiple cystic spaces filled with mucin (H&E x 200)

Figure 2: Intermediate-grade mucoepidermoid carcinoma shows nests of epidermoid cells, a few small-sized cystic cavities, and numerous sheets of intermediate cells in the connective tissue background (H&E x 200).

Figure 3: High grade mucoepidermoid carcinoma reveals minimal cystic spaces, solid nests of epidermoid cells with marked cellular atypia (H&E x 100).

Figure 4: High-grade mucoepidermoid carcinoma reveals minimal cystic spaces, and solid nests of epidermoid cells with marked cellular atypia (H&E x 400).

Figure 5: Low grade MEC reveals weak XIAP expression (ABC- DAB, X250).

Figure 6: Intermediate grade MEC reveals moderate XIAP expression (ABC- DAB, X250).

Figure 7: High grade MEC reveals strong XIAP expression (ABC- DAB, X250).