

Review Article

**PRE AND POST ENDODONTIC RESTORATIVE TECHNIQUES - A
REVIEW**

ABSTRACT:

Endodontic treatments are made much more difficult by the fact that teeth that need them frequently have damaged structures. For these teeth, pre-endodontic restoration is therefore an important strategy that dentists should take into account. Compared to a typical tooth restoration, an endodontic treatment necessitates a more sophisticated restoration because of things like significant cavities, post-treatment root canal dentin, and even the patient's financial situation. Thus the aim of the present paper summarizes on different pre and post endodontic restorative techniques based on the requirement of the case.

Key words: endodontic treatment, restoration, crowns, composite.

INTRODUCTION:

Maintaining an aseptic root canal system or disinfecting it if it has already been infected are the goals of endodontic treatment, which aims to prevent or treat apical periodontitis. Isolating the subject tooth with a rubber dam is deemed necessary because it stops saliva and oral bacteria from entering the mouth, avoids ingestion and inhalation of equipment, and stops irrigation solutions from seeping into the mouth[1]. Teeth that need endodontic treatment frequently have damaged structures as a result of root resorption, caries, or trauma. This makes Endodontic operations further complicated by the minimal amount of retained tooth tissue[2]. Endodontically treated teeth are at a higher risk of fracture as compared to vital teeth as root canal treatment leads to weakening of tooth structure as a result of changes in tooth architecture, changes in properties of dentin and changes in proprioception[3]

PRE ENDODONTIC RESTORATIONS:

For compromised teeth, taking into account pre-endodontic restoration prior to beginning endodontic therapy is beneficial since this method:

- i. Makes room for irrigation solutions to continue functioning for a longer period of time; [4]
- ii. Simplifies ideal rubber dam isolation for the ensuing endodontic visits.[5]
- iii. Facilitates efficient inter-appointment temporary closure to stop intracanal medication seepage, gingival ingrowth into the cavity, and bacterial microleakage. [6]
- iv. Prevents fractures of the compromised tooth structure, preserving repeatable reference points.[7]
- v. Enhances patient acceptance by improving aesthetics during the endodontic treatment phase.
- vi. Facilitates post-endodontic restoration.

Traditional non-adhesive pre-endodontic restoration techniques, like amalgam core build-up, copper bands, or temporary crowns, may still be helpful for some clinicians when used appropriately, but they have a number of drawbacks that, when combined with the advancement of adhesive techniques, have reduced their practical value.[8,9]

NON-ADHESIVE TECHNIQUES OF PRE-ENDODONTIC RESTORATION[2]

I. AMALGAM CORE BUILD-UP

Advantages:

1. Durable with long track record for restoring badly broken down teeth
2. May be useful for clinical situations where bonding is unpredictable

Disadvantages:

1. Amalgam is being phased out
2. Mechanical retention is required; this often necessitates additional tooth tissue removal or use of dentine pins
3. Endodontic treatment needs to be delayed due to the setting properties of amalgam

4. Amalgam particles may block root canal system
5. Aesthetics

II. COPPER/ORTHODONTIC BANDS WITH TEMPORARY CEMENTS

Advantages:

1. May increase fracture resistance of compromised teeth

Disadvantages:

1. Periodontal complications due to poor marginal adaptation and impaired oral hygiene
2. Suboptimal contours and occlusion
3. Risk of dislodgement
4. Root canal blockage by cement particles
5. Aesthetics and patient comfort

III. TEMPORARY CROWN

Advantages:

1. Restoration of occlusion and aesthetics

Disadvantages:

1. Sufficient residual tooth tissue required to retain a crown
2. Risk of dislodgement
3. Compromised visibility
4. Potential patency impairment by cement particles

MODERN CONCEPTS OF PRE ENDODONTIC RESTORATIONS

Teeth having at least a partial ferrule and cavity margins that allow moisture control without encroaching on the STA should be restored using a pre-endodontic procedure. Even if the final coronal restoration wasn't completed right away, there would still be a considerable chance that the tooth would stay in the mouth if its supporting structures were restored prior starting endodontic therapy [11]. As a temporary or poorly sealed coronal restoration can lead to tooth reinfection [12] because of the sealing material's lack of adherence and incompatibility with the dental structure, this could additionally decrease the need for endodontic

retreatment. These sections that follow provide an overview of contemporary techniques that use substances that can adhere to dental tissue.[2]

1. Cervical margin relocation

Dietschi and Spreafico²³ initially defined "cervical margin relocation" (CMR) as the use of resin composite to move a deep cervical margin to a supragingival position. This method has also been referred to as "proximal box elevation" or "deep margin elevation" by other researchers. When an adhesive ultimate repair is envisaged, this method is highly recommended. The primary drawback of CMR is the requirement for an acceptable margin seal with a well-fitting matrix under rubber dam isolation, which is often unachievable, particularly for subgingival margins. Furthermore, enough coronal walls ought to be left over to maintain the matrix. Cervical marginal elevation can be done either by the use of flowable or packable composite, but marginal integrity concerns are of concern with the use of packable composite.[13] (fig1)

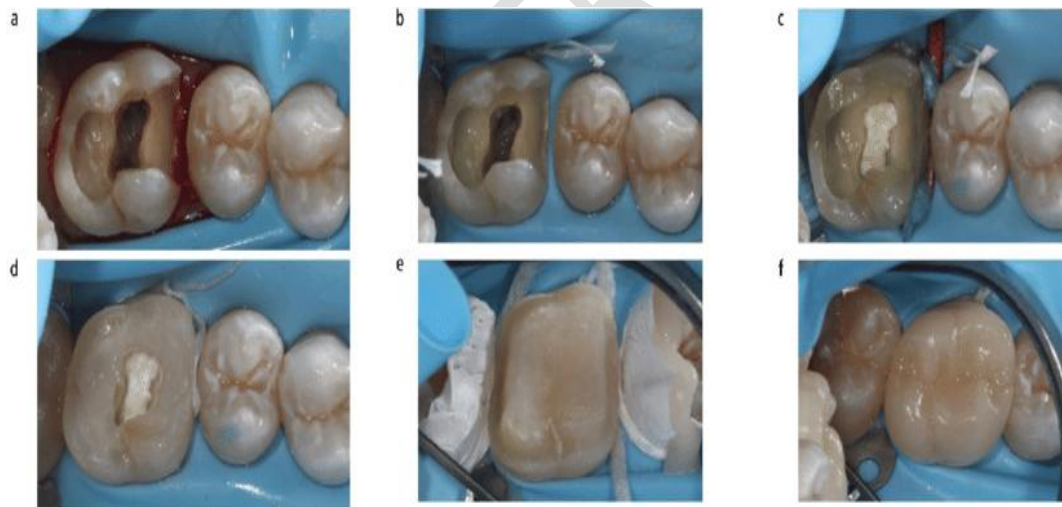


fig.1: Cervical margin relocation (CMR): from pre-endodontic to post-endodontic restoration. a) Non-vital upper right first molar after removal of caries and previous restorations. b) Isolation and c) mesial CMR with sectional matrix. d) Pre-endodontic restoration (including cusp reduction) completed. e) Preparation for adhesive restoration after completion of endodontic treatment. f) Ceramic onlay after adhesive cementation

2. Doughnut technique

Using an appropriate barrier (cotton pellet, thermoplastic gutta-percha, PTFE, liquid dam) to prevent root canal orifice blockage, the so-called "doughnut" approach entails circumferential build-up of the cavity walls. Various methods could be taken into account when planning a non-adhesive final restoration (for like as a traditional crown); for instance, in teeth with some walls missing as well as a big volume of the dentine's periphery. Under these circumstances, matrix stability is typically not achievable, or two steps (free-hand work is followed by secondary positioning of matrix) [14] Pre-endodontic core augmentations might be utilized. Benefits include a comparatively easy application process and the preservation of root canal system access, which guards against issues with canal location and patency.

Marginal adaptation and overhang management raise concerns, particularly when implemented haphazardly. [15] (fig 2)

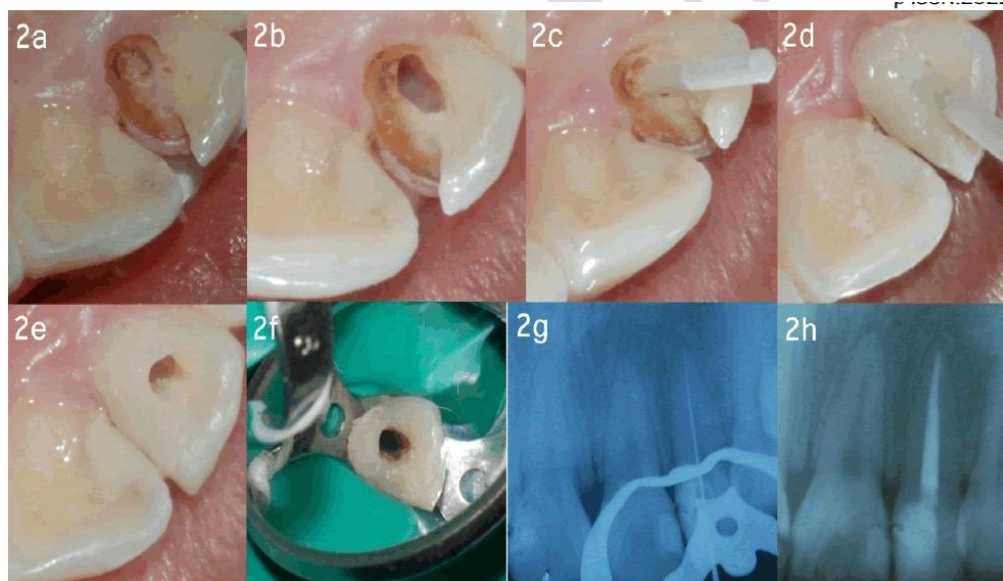


FIG.2: donut technique pre endobulid up using composite in a carious exposed lateral incisor

3. Canal projection

This method has been demonstrated using the specialized Projector Endodontic Instrument Guidance System (PEIGS; CJM Engineering, USA), which maintains canal patency by sliding a tapered plastic device onto an endodontic instrument. This procedure, which is an alternative to the previous one, entails core build-up together

with the projection of root canal orifices from the pulp chamber floor to the cavosurface.³³ Better visualisation and straight-line access to the canals are made possible by canal projection, which also allows for canal individualisation in situations where canal outlets are close together on the chamber floor, correction of misdirected access cavities, improved hydraulic condensation of obturation materials, and sufficient sealing and reinforcing of the chamber floor or perforation repair materials. One significant disadvantage in comparison to the "doughnut" could be the lengthier process required for both the build-up and the temporary closure of each projected canal as a distinct cavity in between endodontic visits.[16](fig. 3)

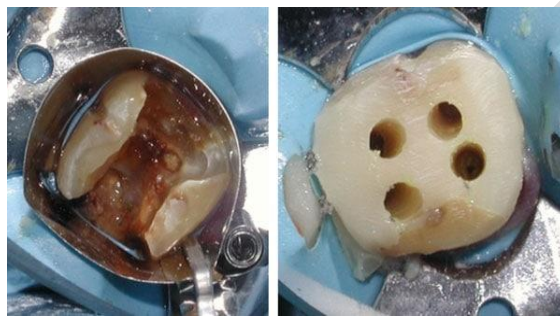

fig. 3: canal projection technique for pre endodontic build up of severely damaged molar

In several clinical scenarios, restorative procedures may be restricted (Fig. 1), particularly in cases where:

- Ferrule effect needs to be improved;
- STA violation is anticipated;
- Isolation of the cavity is not feasible (e.g., gingival ingrowth into cavity).

In these situations, methods that make tooth tissue visible may be used, either by itself or in conjunction with a restorative build-up. These include:

a. *Surgical crown lengthening*

In order to expose more tooth tissue in teeth with structural compromise, this method uses either an apically positioned flap (APF) (with or without osseous excision) or a flapless gingivectomy technique.

In general, gingivectomy has less morbidity after surgery than flap surgery (≥ 3 mm). It is recommended when there is sufficient keratinized tissue width (≥ 3 mm) and no expected STA violation.

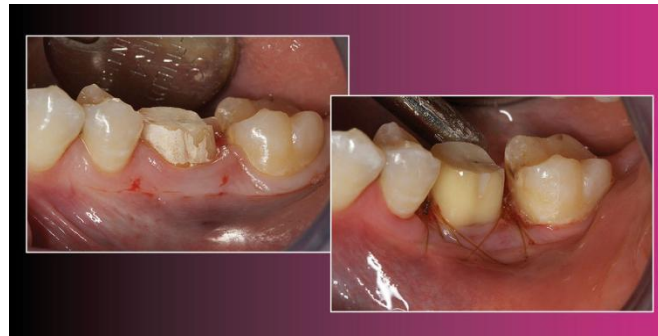

fig.4: surgical crown lengthening of a molar

b. *Orthodontic extrusion*

Orthodontic extrusion is generally favored over SCL, especially in the aesthetic zone, due to its conservative nature, ability to prevent bone resection, and ability to preserve the root contours and periodontal integrity of the treated and neighboring teeth. Additionally, it is highly recommended for patients whose medical condition makes surgical approaches impracticable[17]. When used under low-intensity forces (slow extrusion), this technique causes coronal migration of the supporting bone and soft tissues. This can be advantageous in some situations (angular bony defects, lack of keratinized tissues), but it can also result in aesthetic issues that need to be corrected surgically. However, coupled supracrestal fibrotomy during the extrusion stage can prevent this.[18]

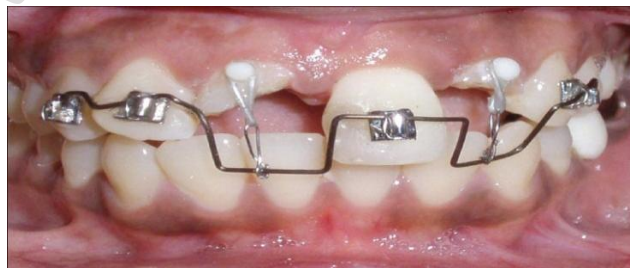

fig.5: orthodontic extrusion of laterals using stainless steel braces and resin tags

c. *Surgical extrusion*

With or without rotation, surgical extrusion entails the deliberate coronal displacement of the residual tooth structure within the socket. Using rotation can increase cervical width and prevent undesired black triangles caused by the decreased root diameter of extruded teeth. It can also shift subgingival fracture lines to a more advantageous position, reducing the amount of extrusion needed.1[19,20]

While this method is often not suitable for molars, in contrast to orthodontic extrusion, it is said to have similar outcomes in terms of periodontal healing.76 minimal bone loss and resorption of the roots[21]

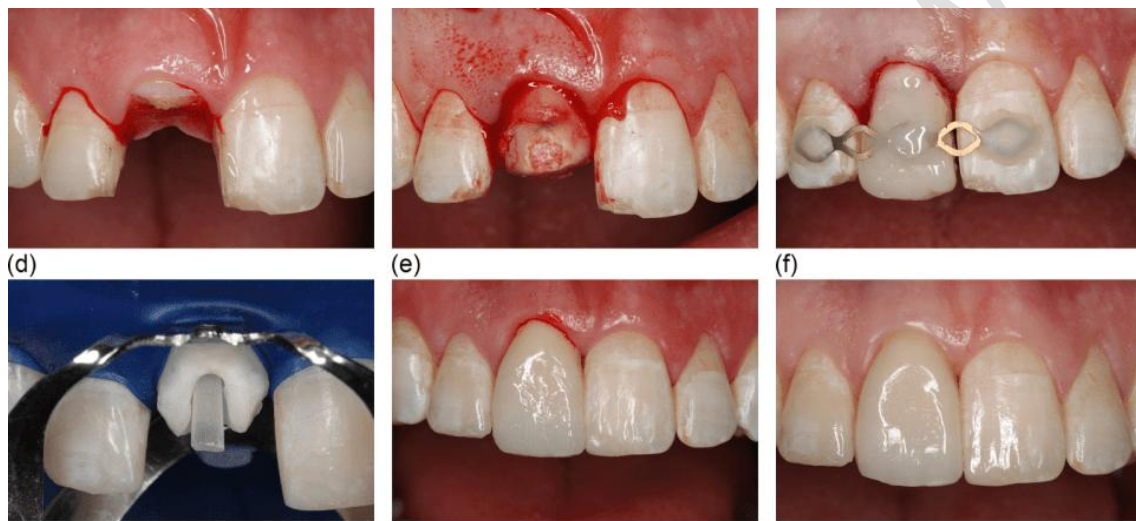


fig.6: surgical extrusion of central incisor followed by root canal treatment and crown placement

POST ENDODONTIC RESTORATIONS:

The quality and amount of remaining tooth structure should be taken into account while determining the optimum restorative approach for each individual patient, as excessive restorations cause the remaining tooth structure to be destroyed. Different post endodontic restorations are classified based on the cuspal coverage, type of the material used and aesthetics.

The development of endocrowns, zirconia post and core, and crownlays—which combine the intra-radicular post, the core, and the crown into a single component to create a monoblock effect—is a recent breakthrough.[22]

1. CAST POST AND CORE

Custom-cast posts and cores consisting of base metal alloys, gold, silver, and palladium have been utilized in the past. Non-metal posts have been introduced recently, including zirconia, carbon fiber, glass fiber, and fiber-reinforced composites [23]. Lately, PEEK (polyether ether ketone) has been utilized, encompassing glass fiber reinforced (GFR)-PEEK, carbon fiber reinforced (CFR)-PEEK, and PEKK (polyether ketone-ketone). These metal-free posts are less costly, take less time to complete, and in certain cases are less invasive than customized posts and cores. They also have advantages including biocompatibility, corrosion resistance, and mechanical qualities comparable to a natural tooth. [24]



Fig 7: different custom posts ranging from cast metal to zirconium posts

2. ENDOCROWNS:

The endocrown idea, which is similar to the traditional post and core, enhances retention by adding a pulp chamber extension without the need for root canal therapy. This design offers alternatives for teeth with calcified, short, or dilacerated root canals in addition to a technique for correctly sealing and restoring endodontically treated teeth. Following endodontic therapy, the pulp chamber should typically be adequately

sealed and leveled using flowable composite or glass ionomer cement. The use of rigid filler materials in the pulp chamber when an endocrown restoration is intended should be avoided. Furthermore, between 6° and 12° of divergence should be prepared for the pulp chamber's axial walls. For anterior teeth, the pulp chamber extension should range from 3 to 6 mm, depending on the restorative material that will be utilized.[25]

The accessible substrate is ONE parameter that the endocrown preparation can change. The ferrule, which is visible in traditional complete crowns, functions as the restoration's "bracing mechanism" around the cervical tooth structure. On the other hand, it may reduce the amount of enamel that is accessible at the edge, which is crucial for the endocrown to properly connect. Because its retention mostly depends on the adhesive cementation, the preparation of an endocrown differs from that of a whole crown.[26]

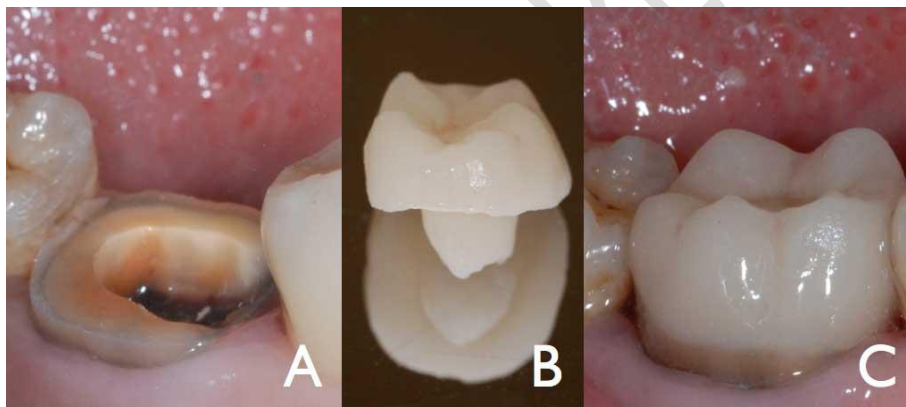


fig.8: endocrown for a severely damaged molar

3. **CROWNLAYS:**

A crownlay which is a variant of an endocrown is a hybrid dental restoration often placed over an endodontically treated tooth that is more conservative than a conventional full coverage crown, but less conservative than a normal onlay.

Crownlays make use of the additional surface area provided in the pulp chamber after root canal therapy to extend additional restorative material on the underside of the restoration into the hollowed-out pulp after the procedure. This reduces the amount of tooth reduction required on the external walls. More of the tooth's healthy, natural structure is preserved when a crownlay is used than would be possible

otherwise. They are easy to prepare and require less chairside time with good aesthetics. Esthetically they work on monoblock phenomenon.

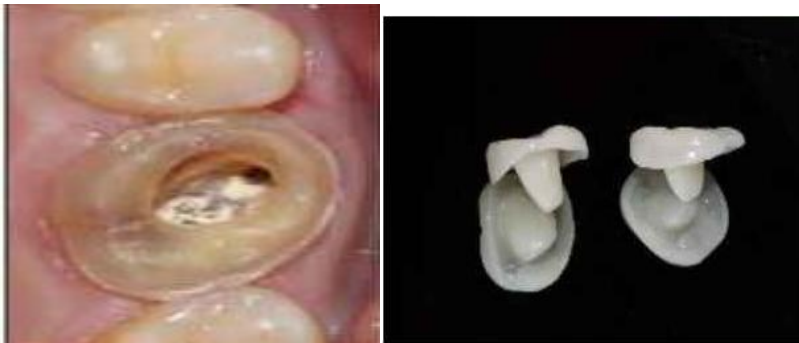

fig.9: crownlay preparation and fabricated crownlay

4. *VONLAYS*

Dr. Ronald E. Goldstein suggested the "Vonlay" or "Veener-lay" design. In the premolar region, where there is enough enamel to form a bond, vonlay is a combination of an onlay and an expanded buccal veneer surface. Although this restorative approach offers the same structural benefits as a full coverage crown, it involves a far less intrusive preparation. The components of an onlay and veneer together improve the maintained tooth structure's longevity and aesthetics at the same time. [27]

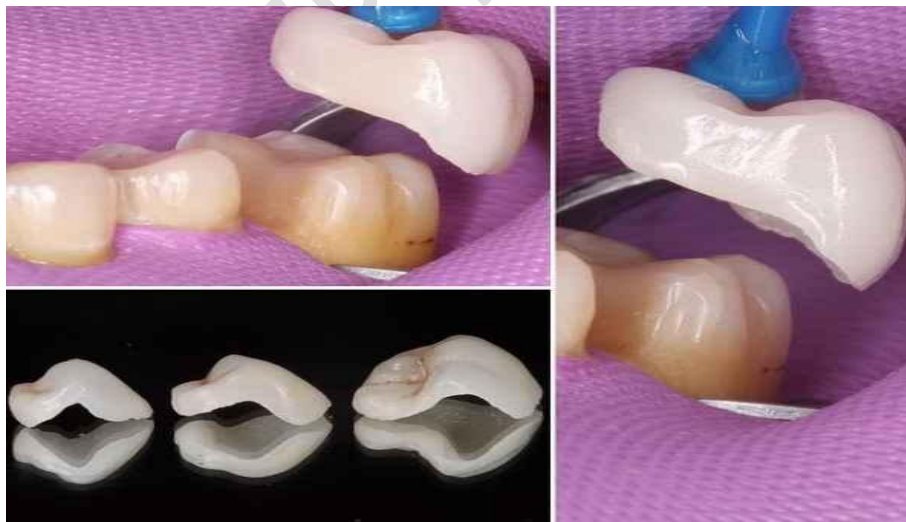

fig.10: vonlay preparation and vonlay on molar

5. OVERLAY

Dental overlays, sometimes known as "three-quarter crowns" or "lab made fillings," are a less common type of dental restoration that lie between a traditional filling and a full coverage dental crown made in a lab. The main advantage of having an onlay made is that it provides a middle-of-the-road approach to repairing the damaged area without covering the entire tooth; it is essentially a partial crown that bonds over the damaged area to rebuild it without sacrificing the risk of stability during everyday wear.[28]

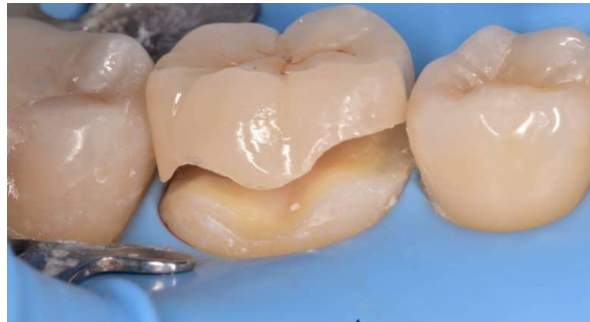

fig.11: lithium disilicate overlays on molar

CONCLUSION

It is clear that the predictability of endodontic treatment for teeth with structural compromises is greatly enhanced by pre-endodontic restoration, and doctors have a wide range of methods at their disposal. A particularly promising treatment option for teeth that have had endodontic treatment is bonded minimally invasive bonded ceramic restorations, which have evolved with post endodontic restorations. In addition to being aesthetically pleasing, it permits the preservation of tooth structure and is appropriate for the idea of bio-integration and minimally invasive dentistry.

REFERENCES:

1. European Society of Endodontology. Quality guidelines for endodontic treatment: consensus report of the European Society of Endodontology. *Int Endod J* 2006; **39**: 921–930
2. Gavriil D, Kakka A, Myers P, O' Connor CJ. Pre-endodontic restoration of structurally compromised teeth: current concepts. *British Dental Journal*. 2021 Sep;231(6):343-9

3. Heling I, Gorfil C, Slutzky H, Kopolovic K, Zalkind M, et al. Endodontic failure caused by inadequate restorative procedures: Review and treatment recommendations. *J Prosthet Dent*. 2002;87(6):674-678.
4. Tanikonda R. Canal projection using gutta-percha points: A novel technique for pre-endodontic buildup of grossly destructed tooth. *J Conserv Dent* 2016; **19**: 194-197.
5. Rao S, Ballal N V. Endodontic Buildups – A Case Series. *J Dentists* 2017; **5**: 6-12.
6. Naoum H J, Chandler N P. Temporization for endodontics. *Int Endod J* 2002; **35**: 964-978.
7. ElAyouti A, Serry M I, Geis-Gerstorfer J, Löst C. Influence of cusp coverage on the fracture resistance of premolars with endodontic access cavities. *Int Endod J* 2011; **44**: 543-549.
8. Gingell J C, Zeller G G, Whitaker G C. Potential hazards of copper band utilization: two case reports. *Gen Dent* 1982; **30**: 500.
9. Brady W F. Composite resin interim restorations for broken-down nonvital posterior teeth. *J Am Dent Assoc* 1983; **106**: 462-466.
10. Pane E S, Palamara J E, Messer H H. Stainless steel bands in endodontics: effects on cuspal flexure and fracture resistance. *Int Endod J* 2002; **35**: 467-471
11. Frota MMA, Carneiro LV, Frota LMA, Cruz SML, Vasconcelos BC: Análise da organização dos níveis de atenção em saúde bucal e a sua influência no sucesso da terapia endodôntica. *Dent Press Endod*. 2017, 7:43-9.
12. Spielman H, Schaffer SB, Cohen MG, et al.: Restorative outcomes for endodontically treated teeth in the practitioners engaged in applied research and learning network. *J Am Dent Assoc*. 2012, 143:746-55. [10.14219/jada.archive.2012.0262](https://doi.org/10.14219/jada.archive.2012.0262)
13. Magne P, Spreafco R C. Deep Margin Elevation: A Paradigm Shift. *Am J Esthet Dent* 2012; **2**: 86-96.
14. Heydrich R W. Pre-endodontic treatment restorations. A modification of the 'donut' technique. *J Am Dent Assoc* 2005; **136**: 641-642.
15. Frese C, Wolf D, Staehle H J. Proximal box elevation with resin composite and the dogma of biological width: clinical R2-technique and critical review. *Oper Dent* 2014; **39**: 22-31.

16. Bhomavat A S, Manjunatha R K, Rao R N, Kidiyoor K H. Endodontic management of badly broken down teeth using the canal projection system: two case reports. *Int Endod J* 2009; **42**: 76–83
17. Mavrogiannis M, Ellis J S, Seymour R A, Thomason J M. The efficacy of three different surgical techniques in the management of drug-induced gingival overgrowth. *J Clin Periodontol* 2006; **33**: 677–682.
18. Padbury Jr A, Eber R, Wang H L. Interactions between the gingiva and the margin of restorations. *J Clin Periodontol* 2003; **30**: 379–385.
19. Das B, Muthu M S. Surgical extrusion as a treatment option for crown-root fracture in permanent anterior teeth: a systematic review. *Dent Traumatol* 2013; **29**: 423–431.
20. Elkhadem A, Mickan S, Richards D. Adverse events of surgical extrusion in treatment for crown-root and cervical root fractures: a systematic review of case series/reports. *Dent Traumatol* 2014; **30**: 1–14.
21. Dietrich T, Krug R, Krastl G, Tomson P L. Restoring the unrestorable! Developing coronal tooth tissue with a minimally invasive surgical extrusion technique. *Br Dent J* 2019; **226**: 789–793.
22. Yoldas O, Akova T, Uysal H. An experimental analysis of stresses in simulated flared root canals subjected to various post-core applications. *J Oral Rehabil.* 2005;32(6):427-43
23. Kalra H, Sukhija H, Roy Rassawet R, Rani V: A review on post and core. *Sch J Dent Sci.* 2020, 7:51-6. 10.36347/sjds.2020.v07i03.002
24. Nokar S, Bahrami M, Mostafavi AS: Comparative evaluation of the effect of different post and core materials on stress distribution in radicular dentin by three-dimensional finite element analysis. *J Dent (Tehran).* 2018, 15:69-78
25. Zou Y, Zhan D, Xiang J, Li L. Clinical research on restorations using CAD/CAMfabricated monolithic zirconia endocrowns and post and core crowns after up to 5 years. *Int J Comput Dent* 2022;25:287–94. doi:10.3290/j.ijcd.b2599661.
26. Tribst JPM, Lo Giudice R, Dos Santos AFC, Borges ALS, Silva-Concílio LR, Amaral M, Lo Giudice G. Lithium disilicate ceramic endocrown biomechanical response according to different pulp chamber extension angles and filling materials. *Materials (Basel)* 2021;9:1307. doi:10.3390/ma14051307.

27. McLaren EA, Figueira J, Goldstein RE. Vonlays: a conservative es-
thetic alternative to full-coverage crowns. *Compend Contin Educ Dent.* 2015; 36(4).282,
284, 286-9
28. <https://medlifeassistance.com/en/overlay-filling>

UNDER PEER REVIEW