

Triorchidism, a rare genitourinary anomaly : A case report

Abstract

Polyorchidism is an exceedingly rare congenital urogenital anomaly characterized by the presence of more than two testicles. Triorchidism, a subtype of polyorchidism, is also an exceptionally uncommon congenital anomaly of the genitourinary tract, where three testicles are present. Triorchidism tends to be more prevalent than other forms of polyorchidism. Clinical manifestations may include a painless scrotal mass, an inguinal mass, or an undescended testis.

In cases of triorchidism, the supernumerary testicle may be located in various anatomical regions, with 66% found in the scrotum, 23% in the inguinal canal, and 9% in the abdomen. Interestingly, around 50% of reported cases occur in individuals aged between 15 and 40 years, with very few instances documented in children under 2 years of age. Notably, the left side of the testicles is the most common location for the supernumerary testicle, accounting for 65% of cases.

This report describes a 45-year-old man who presented with left-sided epididymitis. Upon further investigation through ultrasonography, a diagnosis of triorchidism was confirmed. The case was managed conservatively, and the patient was advised to undergo regular follow-up examinations.

Key words

Triorchidism, Polyorchidism, Supernumerary testicle

Introduction

“Triorchidism, a congenital anomaly involving the presence of three testicles, is a rare occurrence with its first documented case noted by Lane et al in 1895. The majority of cases are asymptomatic and are often incidentally discovered. Complications associated with polyorchidism include mal-descent (40%), torsion (15%), inguinal hernia (20%), hydrocele (9%), and malignancy (6%) when linked to non-scrotal testes”. [1,2,4,8]

Polyorchidism can also be associated with infertility, inguinal hernia, testicular torsion, epididymitis, hydrocele, and varicocele. Diagnosis is typically achieved through simple ultrasonography and if necessary, MRI scans in adults. However, confirmation of polyorchidism should involve histopathological examination. The condition commonly presents without symptoms, and an individual with polyorchidism is referred to as a polyorchid. [3,4,5,7]

“Management of Polyorchidism is still controversial. The management of Polyorchidism will depend upon the location, size and anatomical organization of the testicular drainage system and the age of the patient”. [4,5,6]

Case Report

A 45-year-old male was admitted to our centre on January 15, 2021, complaining of pain and swelling in the left hemiscrotum, which he had noticed over the past 8 days. Upon physical examination, the right testis appeared normal in size and shape, while the left hemiscrotum revealed the presence of two testicles. The left 3rd supernumerary testicle was observed to be small in size and attached superiorly to the left testis. The patient, who had three children's.

Ultrasonography revealed the presence of three testes in the scrotal sac, with one on right side and two testicles on left side. The 3rd supernumerary testis measured 18x12 mm and was situated at the upper pole of the left testis, displaying a homogenous echo texture. Colour Doppler ultrasonography indicated normal blood flow in all three testicles, and no hydrocele was observed. Two cord structures were identified, one on each side. Based on clinical and sonographic evaluations, the case was diagnosed as type II Polyorchidism.

Considering the patient's age and the desire to maintain fertility, a conservative management approach was chosen. The patient was counselled on self-examination and advised to undergo regular follow-ups, with instructions to report any changes in size, shape, or pain. (Fig 1-3)

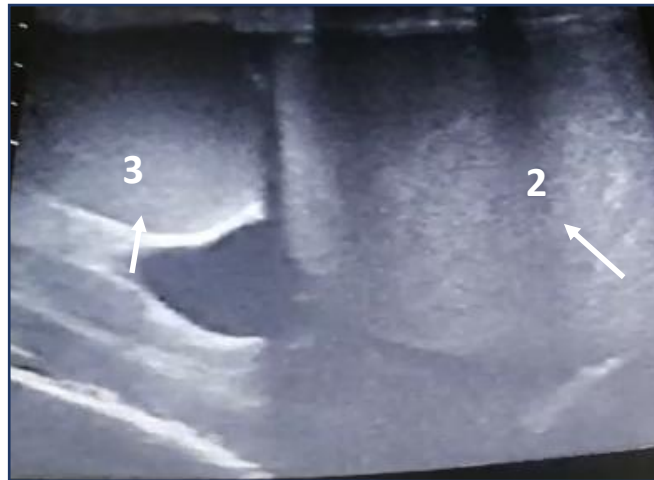


Fig-1 Ultrasonography of left hemiscrotum showing left supernumerary testicle
2. Normal left testicle 3. Third testicle, supernumerary

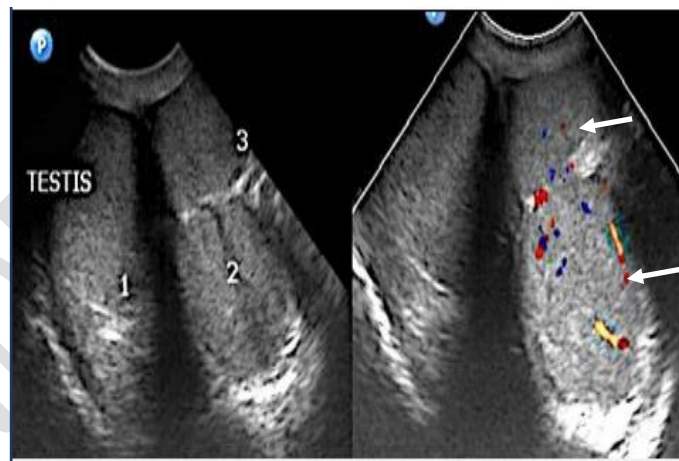


Fig-2 Color doppler study of scrotum showing three testicles
with normal blood flow

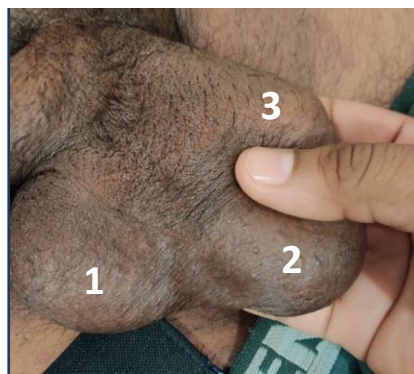

Fig-3 photographs showing three testicles

Discussion

“Triorchidism stands as a rare congenital anomaly, with fewer than 200 cases documented in the literature. The supernumerary third testicle is commonly found in the scrotum (66%), inguinal canal (23%), and retroperitoneum (9%). This anomaly is often identified in individuals aged 20-40 years, with a prevailing 65% occurrence on the left side compared to the right”. [2,4,9]

Polyorchidism can be diagnosed through imaging modalities such as ultrasonography or MRI. Typically discovered incidentally during surgical exploration for inguinal hernia or mass. “Polyorchidism supernumerary testis is more frequently located on the left side. Triorchidism usually presents as a non-tender swelling of the scrotum”. [4,5,6,10]

The embryological origins of Polyorchidism trace back to embryonic life, where the primordial testis begins developing around 6 weeks of gestational age. The development involves the primitive genital ridge and the wolffian duct, resulting in horizontal or longitudinal plan duplication and, subsequently, Polyorchidism. [2,3,4,8]

In 1988, Leung introduced the first classification of Polyorchidism based on embryological development, Later modified by Thum into four types:

1. Type I – Supernumerary testis lacking an epididymis or vas, with no attachment to the ipsilateral testicle.
2. Type II – The supernumerary testis shares a common epididymis and vas deferens with the primary testicle.
3. Type III – The supernumerary testis has its own epididymis but shares a common vas deferens with the ipsilateral testicle.
4. Type IV – Complete duplication of testes, epididymis, and vas.

Types 2 and 3 are the most common anomalies, constituting 90% of Polyorchidism, while type 4 is extremely rare. Management of Polyorchidism remains controversial and depends on factors such as age, location, and organ architecture. “A conservative approach with regular self-examinations and imaging is preferred when reproductive function maintenance is crucial. Resection is advised in cases suspected of malignancy. For Polyorchidism with an extra-scrotal testis, particularly in young patients of reproductive age, orchidopexy followed by observation is recommended”. [2,3,4,10]

Conclusion

Triorchidism is a rare congenital anomaly typically diagnosed incidentally through ultrasonography. The management of this condition remains conservative and is currently a subject of controversy. For polyorchidism, the approach to management is determined by factors such as the location, size, and anatomical organization of the testicular drainage system, as well as the age of the patient.

Ethical Approval:

As per international standards or university standards written ethical approval has been collected and preserved by the author(s).

Consent

As per international standards or university standards, patient(s) written consent has been collected and preserved by the author(s).

References

1. Tonape T, Singh G, Koushik P, Tumepalli T. Triorchidism: a rare genitourinary abnormality. *J Surg Tech Case Rep.* 2012 Jul;4(2):126-8. doi: 10.4103/2006-8808.110262. PMID: 23741593; PMCID: PMC3673357
2. Balawender K, Wiatr T, Wawrzyniak A, Orkisz S. Management of Incidental Finding of Triorchidism Diagnosed During Routine Hernia Repair. *Res Rep Urol.* 2021;13:127-131 <https://doi.org/10.2147/RRU.S291621>
3. Assefa HG, Erge MG, Gebreselassie HA. Triorchidism, a Rare Genitourinary Anomaly: A Case Series. *Res Rep Urol.* 2021 Jul 31;13:549-552. doi: 10.2147/RRU.S323558. PMID: 34368020; PMCID: PMC8336984.
4. Gune, A.R., Gune, R.P. Triorchidism: a rare case report. *Afr J Urol* 27, 15 (2021). <https://doi.org/10.1186/s12301-020-00113-x>
5. Badhaasaa B. Bayissa, Dhugasa Tesfaye, Triorchidism; an incidental finding at inguinal hernia repair: A case report, *International Journal of Surgery Case Reports*, Volume 77, 2020, <https://doi.org/10.1016/j.ijscr.2020.11.118>.
6. Athwal, S., Tailor, J. & Lakhoo, K. Triorchidism at orchidopexy: a case report. *J Med Case Reports* 2, 247 (2008). <https://doi.org/10.1186/1752-1947-2-247>
7. Artul, S., Habib, G. Polyorchidism: two case reports and a review of the literature. *J Med Case Reports* 8, 464 (2014). <https://doi.org/10.1186/1752-1947-8-464>
8. Parvathy P. Triorchidism- a case report of a rare congenital anomaly. *J Evolution Med Dent. Sci* 2020;9(32):2310-2313, DOI: 10.14260/jemds/2020/500
9. De Carli C, Guerra L, Leonard M. Bilobed testicle in children: diagnosis and management. *Can Urol Assoc J* 2009;3:E87 –8
10. Mandalia, Uday & Pakdemirli, Emre. (2020). A case of triorchidism. *Radiology Case Reports.* 15. 1643-1645. 10.1016/j.radcr.2020.06.027