

**NUTRITIONAL ATTRIBUTES OF *Moringa oleifera* VIA ANTIOXIDANTS AND ANTI-INFLAMMATORY RESPONSES ABATES ALUMINUM CHLORIDE INDUCED NEUROBEHAVIORAL DEFICITS, BIOGENICAMINES IMBALANCE AND HIPPOCAMPAL NEURODEGENERATION IN ADULT MALE WISTAR RATS**

**ABSTRACT**

**Background:** Chronic aluminum toxicity induces cellular alterations and oxidative stress thereby causing neurodegenerative disorders such as Alzheimer's disease. This study elucidated the nutritional constituents of *Moringa oleifera* (MO) on aluminum-chloride ( $\text{AlCl}_3$ ) induced AD in adult Wistar rats.

**Materials and methods:** Forty (40) adult male Wistar rats ( $160 \pm 20$ g) were divided into 4 groups ( $n=10$ ). Group A received normal saline as *placebo*; Group B received 200mg/kg bw of  $\text{AlCl}_3$  only; Group C received 100mg/kg bw of MO and 200mg/kg bw of  $\text{AlCl}_3$  and Group D received 100mg/kg bw of MO only. All administration was done orally per day for 45 days. After the last administration, the animals underwent behavioral tests (Morris Water maze, Y-Maze and Open field). Thereafter, animals were sacrificed via cervical dislocation and blood samples were collected to obtain serum and the brain was harvested for analysis.

**Results:** The antioxidant enzymes (CAT, GSH and SOD) levels, serum electrolyte (except  $\text{K}^+$ ) and neurotransmitter levels (except norepinephrine), behavioral tests (spatial memory and learning deficit) were significantly decreased with concomitant increase in oxidative stress markers (MDA,  $\text{H}_2\text{O}_2$  and NO) among  $\text{AlCl}_3$  intoxication compared to control.

**Conclusion:**MO preserves hippocampal neurons, antioxidant levels, neurotransmitters, learning and memory abilities induced by  $AlCl_3$ .

**Keywords:** Alzheimer's disease, Aluminum chloride, *Moringa oleifera*, Oxidative stress, hippocampus.

## 1. INTRODUCTION

“Alzheimer's disease (AD) is an irreversible, progressive, multifactorial genetic and environmental neurodegenerative disorder that affects more than 46 million people worldwide” [1, 2]. “The economic impact of AD on families and society presents a major challenge to public health. Among the earliest notable symptom of AD patients are characterized by impairments in learning, memory retrieval, reasoning, communication, and one's ability to carry out daily activities” [3]. “Morphologically, AD is characterized by extracellular deposition of amyloid-beta ( $A\beta$ ) protein combined with formation of senile plaques, intracellular neurofibrillary tangles (NFTs), and the death of cholinergic neurons” [4]. “The  $A\beta$  cascade hypothesis assumes that excessive accumulation of  $A\beta$  in the brain is the basic pathogenetic process accountable for neuronal degenerative changes and the compromise of cognitive functions in AD” [5]. Accordingly, “reducing the brain  $A\beta$  burden has become a key strategy in AD therapy and prevention. Furthermore, postmortem brain surveys of patients with AD disclosed low concentration of the neurotransmitter acetylcholine (ACh) and the enzyme choline acetyltransferase (ChAT), responsible for ACh synthesis” [6]. “Researchers have tried to regain the cholinergic equilibrium by inhibiting cholinesterase-mediated ACh breakdown to downturn the progression of AD and improve cognitive function” [7, 8]. “In AD, Aluminum (Al) is regarded a prospective etiological factor” [9, 10]. “Al is the third most abundant metal in the earth's crust and its function in AD's etiology and pathogenesis has become more perceptible, as a

result of well-documented animal experiments” [11] and clinical research [12]. Al is regarded to boost the formation and accumulation of extracellular A $\beta$  [13, 14], cholinotoxin [15] thereby causing changes in cholinergic function, a major occurrence in AD's neurochemistry [16]. Along with cognitive dysfunction, Al intoxication induces neurodegeneration and apoptotic neuronal loss [17] due to its powerful cholinotoxin [15]. “Various animal studies have shown that excessive aluminum consumption can trigger neurochemical, neurobehavioral, and neuropathological brain alterations that impair rats’ learning ability” [18, 19].

Some natural medicinal plants have gained significant publicity as alternative therapy for AD treatment due to their safety and effectiveness [20]. “One of such medicinal plant is *Moringa oleifera* (MO), regarded as an evergreen deciduous tree grown mainly in semi-arid, tropical and subtropical areas. The leaves of MO encompass a profile of vital trace elements and excellent sources of proteins, vitamins, beta-carotene, amino acids and a variety of phenolics and flavonoids” [21, 22]. “It is regarded as one of the World’s most beneficial trees, as almost every bit of the tree is useful either as food, medicinal purposes or industrial functions [23]. The medicinal attributes of MO includes antitumour, anti-epileptic, anti-diuretic, anti-inflammation and anti-venom” [24-26]. The herb is also reported to show positive anti-lead ameliorative effects and neuroprotective effects in focal cerebral ischemia [27, 28]. This study therefore aimed to investigate the neuroprotective and antioxidant properties of MO on aluminum-chloride (AlCl<sub>3</sub>) induced AD in adult Wistar rats.

## **2. MATERIALS AND METHODS**

### **2.1. Chemicals**

Aluminum Chloride ( $\text{AlCl}_3$ ) was obtained from Sigma Chemical Corporation (St. Louis, MO, USA). All other chemicals used in the study were of analytical grade.

## **2.2.Plant collection, identification and Extract preparation**

Fresh leaves of *Moringa oleifera* was collected from Research Farm, Federal University of Technology, Akure, Nigeria and were identified and authenticated by Omomoh Bernand in herbarium section of Centre for Research and Development (CERAD) of the Federal University of Technology, Akure, Nigeria. FUTA0190 voucher deposited for reference purpose. The leaves were thoroughly washed and oven dried at  $37^{\circ}\text{C}$  for 48 h and pulverized into smooth powder.

The pulverized sample (850g) was suspended in 1000ml of distilled water with regular agitation for 72hrs. The solution obtained was filtered and the resulting filtrate was concentrated over water bath ( $40^{\circ}\text{C}$ ) and yielded 463.21g crude extract corresponding to 58.12% of the residue.

The crude extract *Moringa oleifera*(MO)was kept air-tight and refrigerated before use.

## **2.3.Animals and experimental design**

A total of Forty (40) adult male Wistar rats weighing between 140 and 180 g were purchased from the breeding colony, School of Agriculture and Agricultural Technology, Federal University of Technology, Akure, Nigeria. The rats were housed in the Laboratory Animal house, Department of Human Anatomy, Federal University of Technology, Akure, Nigeria. The rats were acclimatized for 7 days; maintained under standard laboratory conditions (12- hour light/dark cycles) and had free access to a commercial pellet diet and water *ad libitum*. The animals were maintained under a controlled room temperature of  $25 \pm 2^{\circ}\text{C}$  and relative humidity of  $60 \pm 5\%$  degree. The rats were fed with growers marsh (pellets), purchased from a feed store-Agro feeds and flour mills, and water during the period of the experiment. The processes of protocols using the experimental animals were in accordance to the Guide for the Care and Use

of Laboratory Animals and approved by the Health Research Ethics Committee of the Federal University of Technology, Akure, Nigeria on the 19<sup>th</sup> June, 2019.

#### **2.4.Experimental Design**

The rats were divided into four groups ( $n = 10$ ), labelled as groups A, B, C, and D. Group A received normal saline as *placebo*; Group B received 200mg/kg bw of  $AlCl_3$  only; Group C received 100mg/kg bw of MO and 200mg/kg bw of  $AlCl_3$  and Group D received 100mg/kg bw of MO only. All administration was done via oral gavage once daily and the experiment span **duration of 45 days.**

“All animals were observed for any anomalies, illness and physical anomalies. The experimental procedures were in accordance with the provided recommendations in the “Guide for the Care and Use of Laboratory Animals” prepared by the National Academy of Sciences. The rats were fed with standard rat chow and drinking water was supplied *ad libitum*. The weights of the animals were recorded at procurement, during acclimatization, at commencement of the experiment, and weekly throughout the experimental period using a CAMRY electronic scale (EK5055, Indian). After the last administration, the animals were weighed and behavioral observations were conducted. At the end of the behavioral tests, animals were sacrificed through cervical dislocation. The rats were decapitated and blood samples were collected, centrifuged at 4°C for 10 min at 250×g and the serum obtained was stored at -20°C until assayed. The organ (Brain) was removed, cleaned and washed with saline (0.9% of sodium chloride)” [10].

#### **2.5.Behavioral parameters**

“Prior to the commencement of the experiment, the rats underwent neurobehavioral testing using Morris water maze and Y maze tests for spatial memory and working memory [29, 30]; and Open field test” [31, 32].

### **2.5.1. Morris Water Maze test**

“This test was carried out to assess the spatial learning and memory of the rats. A pool of water measuring about 100 cm in diameter and 30 cm in depth was used. An escape platform about an inch deep from the surface of the water was placed in one of the quadrants outside of which was a visual cue. The animals were trained 24 hours prior to the actual test. During the training, each rat was placed in each of the other three quadrants for a maximum period of 60 seconds to find the escape platform at intervals of 25 minutes between quadrants until the escape latency period reduced to less than 25 seconds. During the test, the pool was colored and the animals were placed in each of the three quadrants different from the escape platform quadrant at an interval of 25 minutes between quadrants. The time taken to find the escape platform was recorded as the escape latency period” [10].

### **2.5.2. Y-maze**

“This test was used to examine the working and cognitive memory of the rats. The animals were placed in a Y-maze whose arms measured 75 cm in length and 15 cm in breadth with an angle of 120° between the arms. The animals were allowed to explore the maze for duration of 5 minutes. The manner of arm entries was recorded. A correct alternation is scored when the animal successfully explored each of the three arms of the maze per triad of exploration (e.g., XYZ, ZXY, or YZX). Once two arms were explored per triad of exploration (e.g., XYX, ZXZ, YXY), it was considered an incorrect alternation. The percentage correct alternation of each rat was estimated as a ratio of the correct alternation to the total alternation multiplied by 100” [10].

### **2.5.3. Open Field Test (OFT)**

“The open field apparatus was constructed using plywood measuring 100 cm by 100 cm and height of 50 cm. The floor was divided into square grids each measuring 25 cm in length with a

blue marker and a centre square of the same length was drawn using a red marker. Each rat was picked by the tail and dropped in the centre square and allowed to explore for 5 minutes while the video was captured by a camera from above the apparatus. The two behavioral patterns assessed are number of lines crossed and rearing frequency. The number of lines crossed was the frequency with which the rat crossed one of the grid lines with all four paws; the rearing frequency was the number of times the rat stood on its hind limbs” [11].

## **2.6. Tissue collection and processing**

“After the behavioral tests were concluded, the rats were subjected to cervical dislocation, and the brain tissues were immediately excised and dissected into two hemispheres. All the right hemispheres were fixed in 4% paraformaldehyde for histological processing, while the left hemispheres were rinsed three times in 0.25 M sucrose for five minutes and stored in 30% sucrose at 4°C. Paraffin wax sections were obtained for histological analysis. The hippocampus were excised from the fixed brain and dehydrated in ascending grades of alcohol (50%, 70%, 90%, and 100%). The tissues were then cleared in xylene twice for 15 min each. Infiltration and embedding was done with paraffin wax in Leica hot air oven at 56°C with tissues eventually embedded in paraffin wax at similar orientations. Tissue sections were obtained serially using a rotary microtome (Leica RM2245) and then mounted on glass slides. Sections were taken at 30 µm for Hematoxylin and Eosin staining process using the method of Pearse [33] as modified by Fischer *et al.* [34]. The slides were analyzed using Leica®DM5000B microscope and photographed with Leica EC3 digital camera” [12].

## **2.7. Biochemical analysis**

### **2.7.1. Superoxide dismutase (SOD) assay**

“The brain tissues were placed in 0.25 M sucrose solution and homogenized. Tissue homogenate was collected in a 5 ml sample bottle and centrifuged at 3,000 rpm for 15 minutes using a

centrifuge (Model 90-1; Jiangsu Jinyi Instrument Tech, Jiangsu, China). The supernatant was collected with Pasteur pipettes into sample bottles and placed in a freezer at  $-4^{\circ}\text{C}$ . SOD was using spectrophotometric technique" [35]. The reaction mixture (3 ml) contained 2.95 ml carbonate buffer, 0.02 ml of homogenate and 0.03 ml of 2 mM SOD substrate in 0.005 N HCl, used to initiate the reaction. The reference cuvette contained 2.95 ml buffer, 0.03 ml of substrate and 0.02 ml of water. The absorbance was read at regular interval of 1 minute for 5 minutes at 480 nm. Values are expressed in U/mg of protein.

#### **2.7.2. Catalase (CAT) assay**

CAT activity was analyzed using the protocols of Clairborne [36], in a solution containing 50mM phosphate buffer, 19mM hydrogen peroxide and tissue homogenates. The reaction was ended by addition of dichromate/ acetic acid solution. Values are expressed as  $\mu\text{mole}$  of  $\text{H}_2\text{O}_2$  consumed/mg protein/min.

#### **2.7.3. Reduced glutathione level (GSH)**

GSH was assayed using the protocols of Jollowet *al.* [37] in a solution containing tissue homogenates, 4% sulfosalicylic acid, and subsequently DTNB. Values are expressed in nmol/mg of protein.

#### **2.7.4. Lipid peroxidation (LPO) level**

LPO was quantified as Malondialdehyde (MDA), using the protocols of Farombi *et al.* [38]. The reaction contained tissue homogenates, 5% (w/v) butylatedhydroxytoluene(BHT), 10% TCA and 0.75% TBA in 0.1 mol/L of HCl. MDA was calculated by using the following equation:  $R/1.56_{105}$  L/mol/cm, where R is the extinction coefficient. Values are expressed in nmol/mg of protein or U/mg protein.

#### **2.7.5. Determination of Nitric oxide (NO) level (nitrite)**

Nitric oxide measured as nitrite was determined using Griess reagent, according to the method of Moshageet *al.* [39]. Briefly, 100  $\mu$ L of sample were incubated with 100 mL of Griessreagent (Sigma) at room temperature for 20 min. Nitrite level was determined by measuring the absorbance at 550nm using a spectrophotometer. Values are expressed in  $\mu$ M/g.

#### **2.7.6. Determination of Hydrogen peroxide (H<sub>2</sub>O<sub>2</sub>) level**

H<sub>2</sub>O<sub>2</sub> level was assayed as described by the method of Aebi [40]. Values are expressed in mM/g.

#### **2.7.7. Brain monoamine neurotransmitters and serum electrolyte analysis**

Monoamine neurotransmitter (DA, 5-HT and NE) level was estimated using HPLC technique and the brain content of these neurotransmitters was made using the equation of Pagel *et al.* [41].

Serum electrolyte analysis (Na<sup>+</sup>, K<sup>+</sup>, Ca<sup>2+</sup>, Zn<sup>2+</sup>, and Cu<sup>2+</sup>) concentration were estimated according to Ogunlade *et al.* [42].

### **2.8. Statistical analysis**

Statistical analysis was performed by one-way analysis of variance (ANOVA) with Tukey's multiple comparisons test using Graph Prism® software. The data were reported as means  $\pm$  SEM, while differences between means at  $p < 0.05$  were considered significant.

## **3. RESULTS**

### **3.1. Effect of treatment on behavioral parameters**

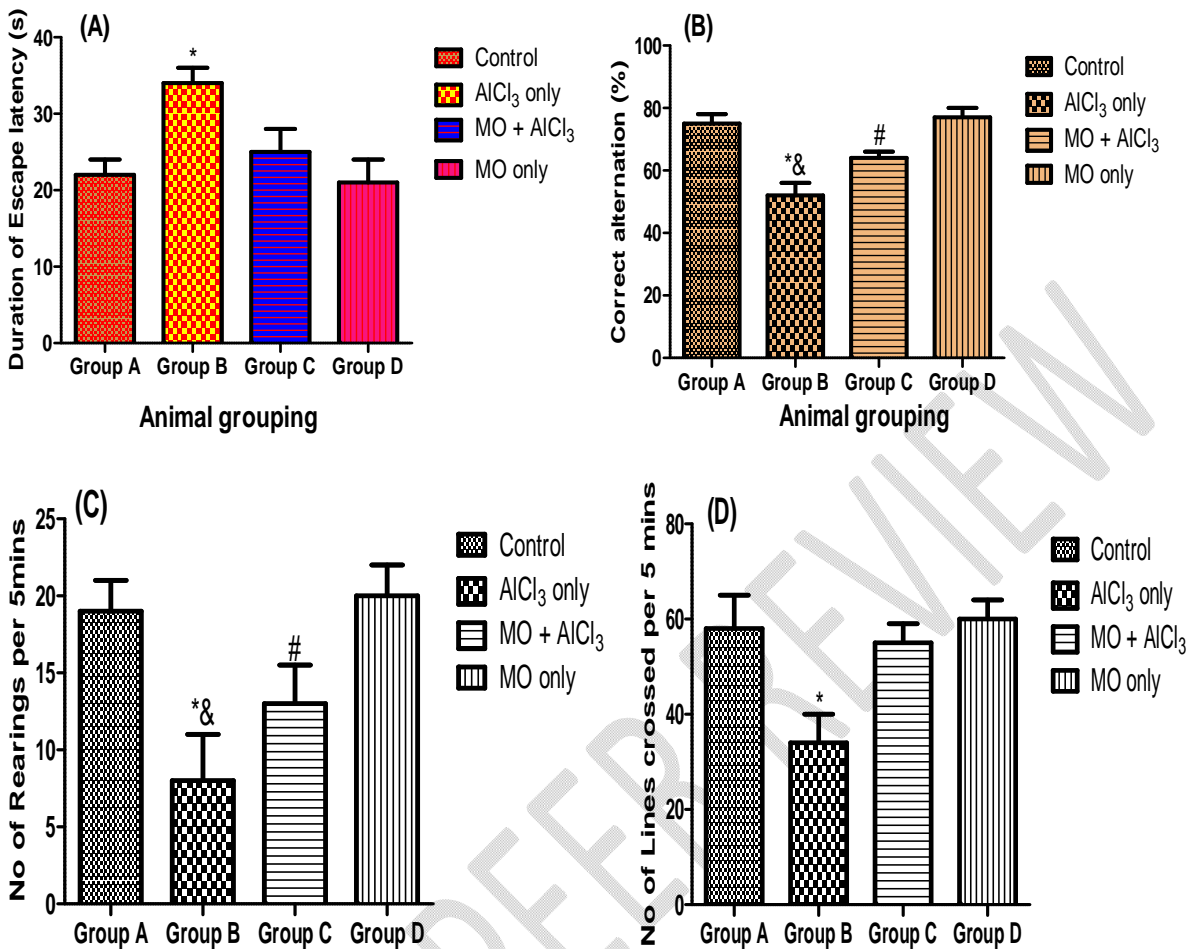
The learning and memory ability in the MWM test was determined using the duration of escape latency. The present study showed significant increase in duration of escape latency among AlCl<sub>3</sub> only group (group B) when compared to the control (group A) ( $p < 0.05$ ) (fig. 1A). However, MO and AlCl<sub>3</sub> treatment group (group C) showed a significantly decrease escape latency period compared with AlCl<sub>3</sub> treated group (Group B) ( $p < 0.05$ ) (fig. 1A). The duration of

escape latency of MO only group (group D) was similar when compared with the control (group A) (fig.1A).

In addition, the short term memory assessment using the Y-maze test showed a significant decrease in percentage correct alternation among AlCl<sub>3</sub> only group (group B) compared to control (group A) ( $p < 0.05$ ) (fig. 1B). The treated group that received MO and AlCl<sub>3</sub> (group C) showed significant increase in percentage correct alternation when compared to the AlCl<sub>3</sub> only treated rats (group B) ( $p < 0.05$ ) (fig. 1B). This revealed that MO prevents the short-term memory impairment induced by AlCl<sub>3</sub> exposure.

Furthermore, the assessment of exploratory drive and anxiety was determined using the open field test. The result showed a significant decrease in the number of lines crossed (exploratory drive) and rearing frequency (anxiety) among the AlCl<sub>3</sub> only group (group B) relative to the control group (group A) ( $p < 0.05$ ) (fig.1C and 1D). However, the combine treatment of MO and AlCl<sub>3</sub> (group C) showed a significant increase in the number of lines crossed (exploratory drive) and rearing frequency (anxiety) when compared to AlCl<sub>3</sub> only group (group B) ( $p < 0.05$ ) (fig.1C and 1D). The number of lines crossed and the rearing frequency was similar among the MO only group (group D) and control animals (group A) (fig.1C and 1D).

**Figure 1: *Moringa oleifera* response on Neurobehavioral stress tests (MWM, Y-Maze and Open Field tests) in Aluminum chloride induced neurotoxicity in normal and treated rats.**



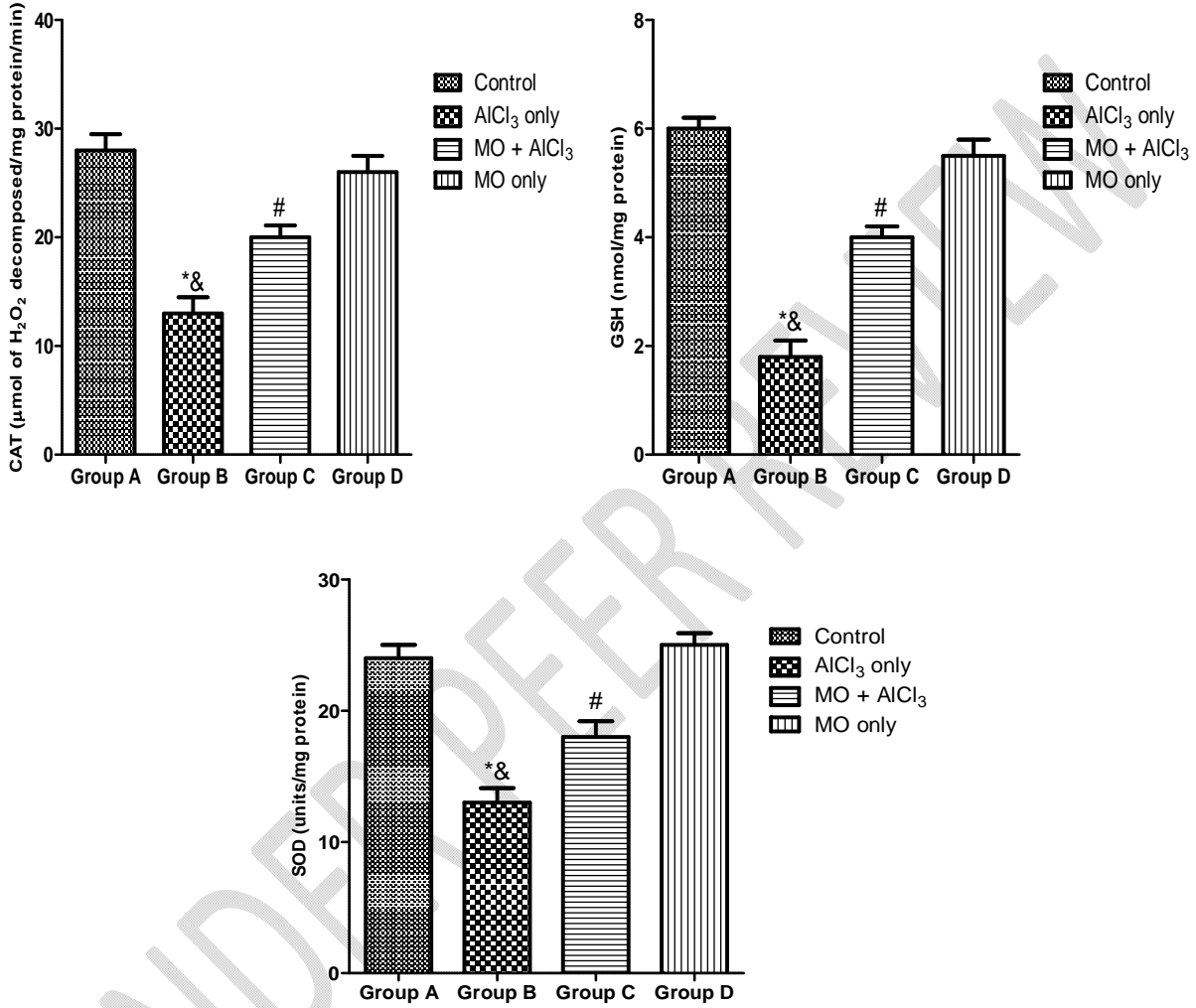
\*:  $p < 0.05$  as compared to group A and D; &:  $p < 0.05$  as compared to group C; #:  $p < 0.05$  as compared to groups A and D.

### 3.2. Effect of *Moringa oleifera* on brain antioxidant parameters (CAT, SOD, GSH)

The present results showed a significant decrease in the levels of antioxidant enzymes (CAT, SOD and GSH) in AlCl<sub>3</sub> only group (group B) when compared with the control (group A) ( $p < 0.05$ ) (fig. 2). However, there was a significant increase in the levels of CAT, SOD and GSH in the group that received MO and AlCl<sub>3</sub> (group C) relative to AlCl<sub>3</sub> only group (group B) ( $p < 0.05$ ) (fig. 2). In addition, there was a significant decrease in brain antioxidant enzyme levels (SOD, CAT and GSH) in the group that received MO and AlCl<sub>3</sub> (group C) in comparison with control and MO only groups (groups A and D) ( $p < 0.05$ ) (fig. 2). Although, the levels antioxidant

enzyme(SOD, CAT and GSH) was similar among the MO only (group D) animals and control group (group A) (fig. 2).

**Figure 2: *Moringa oleifera* response on brain Antioxidant enzymes (CAT, SOD and GSH) in Aluminum chloride induced neurotoxicity in normal and treated rats.**

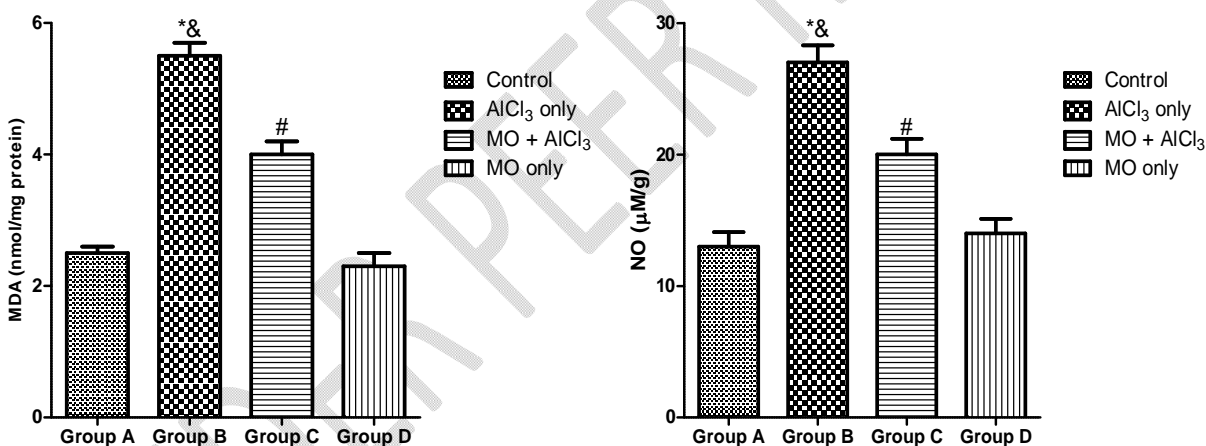


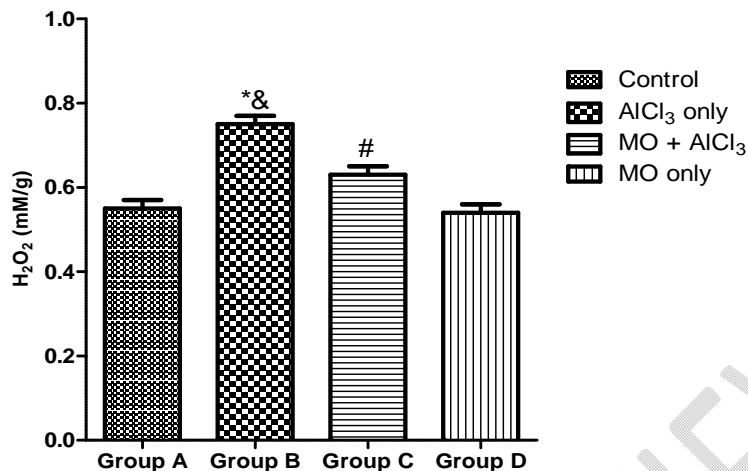
\*:  $p < 0.05$  as compared to group A and D; &:  $p < 0.05$  as compared to group C; #:  $p < 0.05$  as compared to groups A and D.

### 3.3.Effect of *Moringa oleifera* on brain oxidative stress markers (MDA, H<sub>2</sub>O<sub>2</sub> and NO)

In the present study, there was a significant increase in the levels of MDA, H<sub>2</sub>O<sub>2</sub> and NO in AlCl<sub>3</sub> only group (group B) relative to the control group (group A) ( $p < 0.05$ ) (fig. 3). However, there was a significant increase in the levels of oxidative stress parameters (MDA, H<sub>2</sub>O<sub>2</sub> and NO) among MO and AlCl<sub>3</sub> group (group C) when compared to AlCl<sub>3</sub> only group (group B) ( $p < 0.05$ ) (fig. 3). Additionally, there was a significant decrease in brain oxidative stress markers (MDA, H<sub>2</sub>O<sub>2</sub> and NO) in the group that received MO and AlCl<sub>3</sub> (group C) relative to the control and MO only group (groups A and D) ( $p < 0.05$ ) (fig. 3). There was no significant difference in the levels of oxidative stress markers between the MO only group (group D) and control animals (group A).

**Figure 3: *Moringa oleifera* response on oxidative stress markers (MDA, NO and H<sub>2</sub>O<sub>2</sub>) in Aluminum chloride induced neurotoxicity in normal and treated rats.**



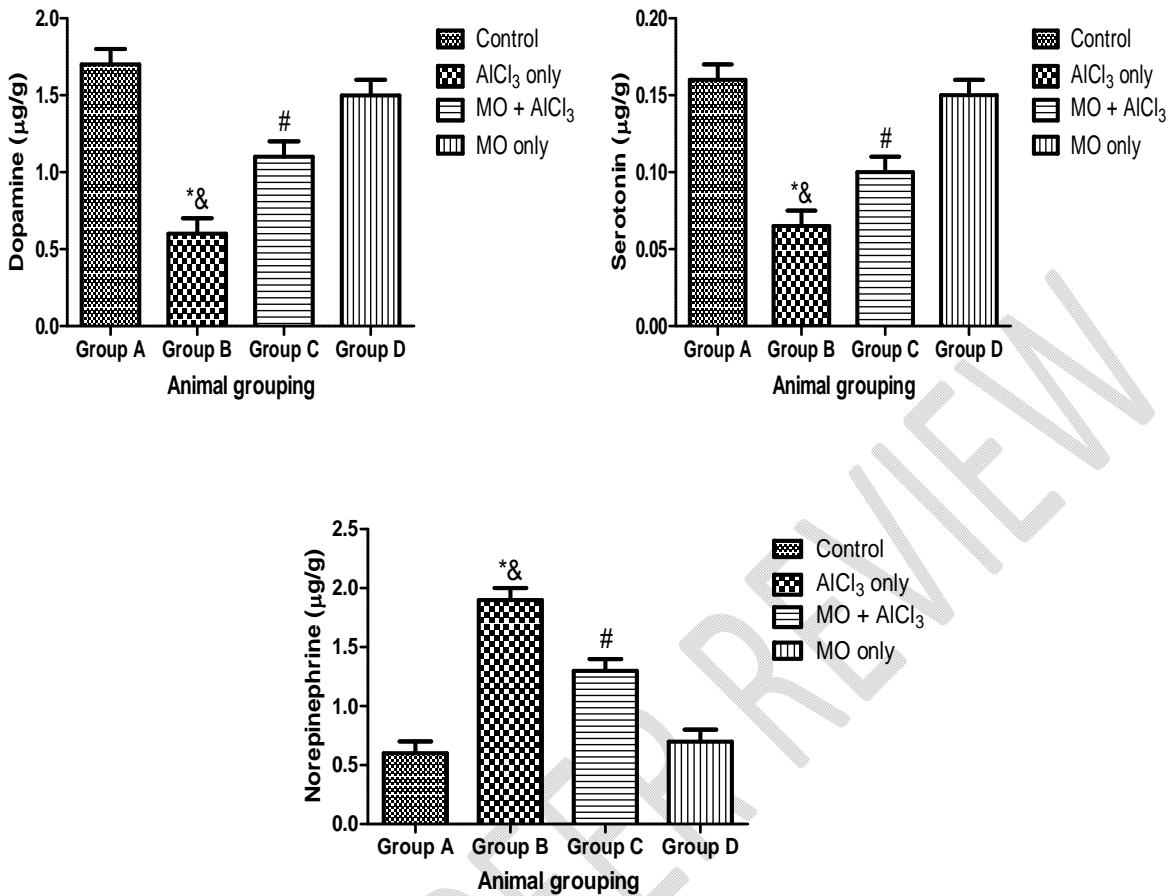


\*:  $p < 0.05$  as compared to group A and D; &:  $p < 0.05$  as compared to group C; #:  $p < 0.05$  as compared to groups A and D.

#### 3.4. Effect of *Moringa oleifera* in brain monoamine neurotransmitters (Dopamine, Serotonin and Norepinephrine)

In this study, AlCl<sub>3</sub> only group (Group B) recorded a significant decrease in the levels of dopamine and serotonin with concomitant increase in norepinephrine level when compared with control group (group A) ( $p < 0.05$ ) (fig. 4). However, there was a significant decrease in dopamine and serotonin levels with a corresponding increase in norepinephrine level within the group that received MO and AlCl<sub>3</sub> (group C) when compared with AlCl<sub>3</sub> only group (group B) ( $p < 0.05$ ) (fig. 4). In addition, there was a significant decline in the levels of monoamine neurotransmitters (Dopamine, serotonin) within concomitant elevation in norepinephrine level among MO and AlCl<sub>3</sub> group (group C) relative to the control and MO only groups (groups A and D) ( $p < 0.05$ ) (fig. 4).

**Figure 4: *Moringa oleifera* response on brain monoamine neurotransmitters (dopamine, serotonin and norepinephrine) in Aluminum chloride induced neurotoxicity in normal and treated rats.**



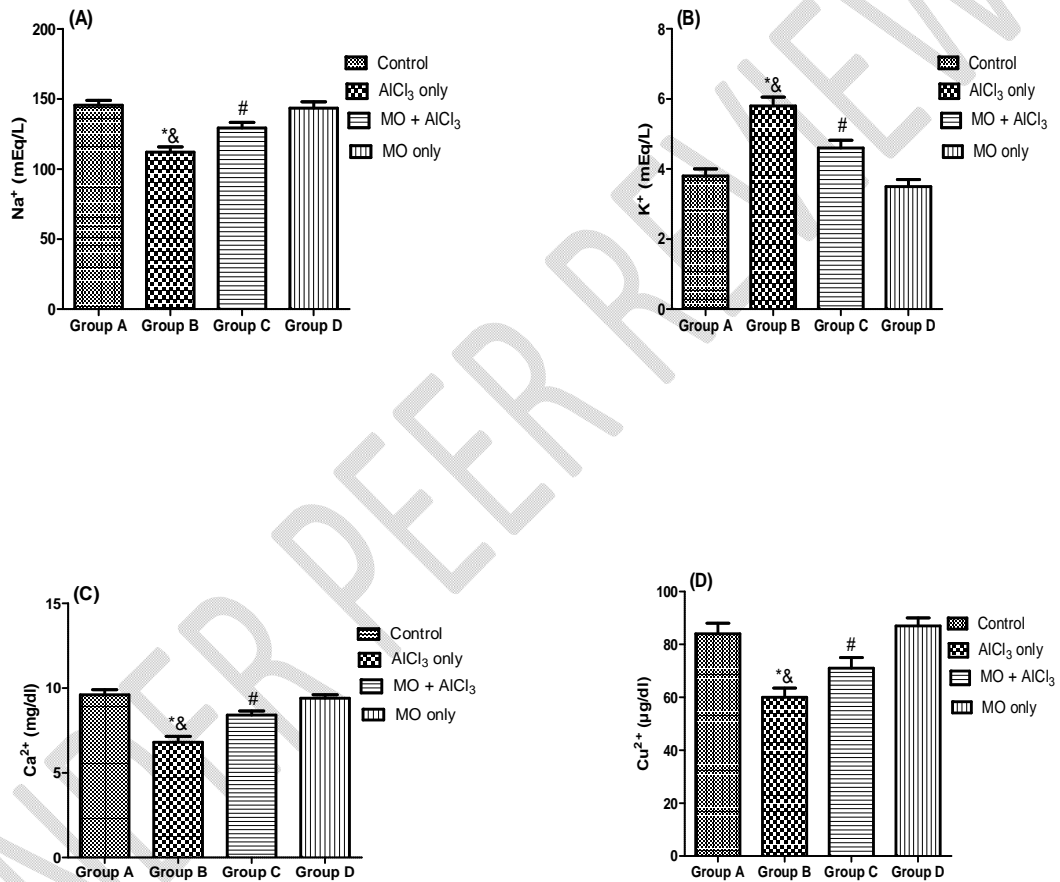
\*:  $p < 0.05$  as compared to group A and D; &:  $p < 0.05$  as compared to group C; #:  $p < 0.05$  as compared to groups A and D.

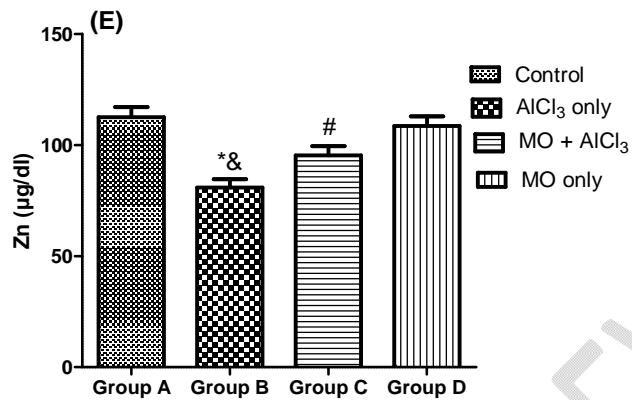
### 3.5. Effect of *Moringa oleiferain* serum electrolyte concentration in normal and Alzheimer's group rats

In this present study, there was a significant decrease in the concentration of  $\text{Na}^+$ ,  $\text{Ca}^{2+}$ ,  $\text{Cu}^{2+}$  and  $\text{Zn}^{2+}$  with concomitant increase in  $\text{K}^+$  level within the  $\text{AlCl}_3$  only group (Group B) when compared with control group (group A) ( $p < 0.05$ ) (fig. 5). However, a significant elevation in the concentrations of  $\text{Na}^+$ ,  $\text{Ca}^{2+}$ ,  $\text{Cu}^{2+}$  and  $\text{Zn}^{2+}$  with concomitant decline in  $\text{K}^+$  level among the MO and  $\text{AlCl}_3$  group (group C) when compared with  $\text{AlCl}_3$  only group (group B) ( $p < 0.05$ ) (fig. 5). In addition, the group that received MO and  $\text{AlCl}_3$  (group C) recorded significant

decrease concentrations of  $\text{Na}^+$ ,  $\text{Ca}^{2+}$ ,  $\text{Cu}^{2+}$  and  $\text{Zn}^{2+}$  with concomitant increase in  $\text{K}^+$  level relative to the control and MO only groups (group A and D) ( $p < 0.05$ ) (fig. 5).

**Figure 5: *Moringa oleifera* response on serum electrolytes ( $\text{Na}^+$ ,  $\text{K}^+$ ,  $\text{Ca}^{2+}$ ,  $\text{Cu}^{2+}$  and  $\text{Zn}^{2+}$ ) in Aluminum chloride induced neurotoxicity in normal and treated rats.**

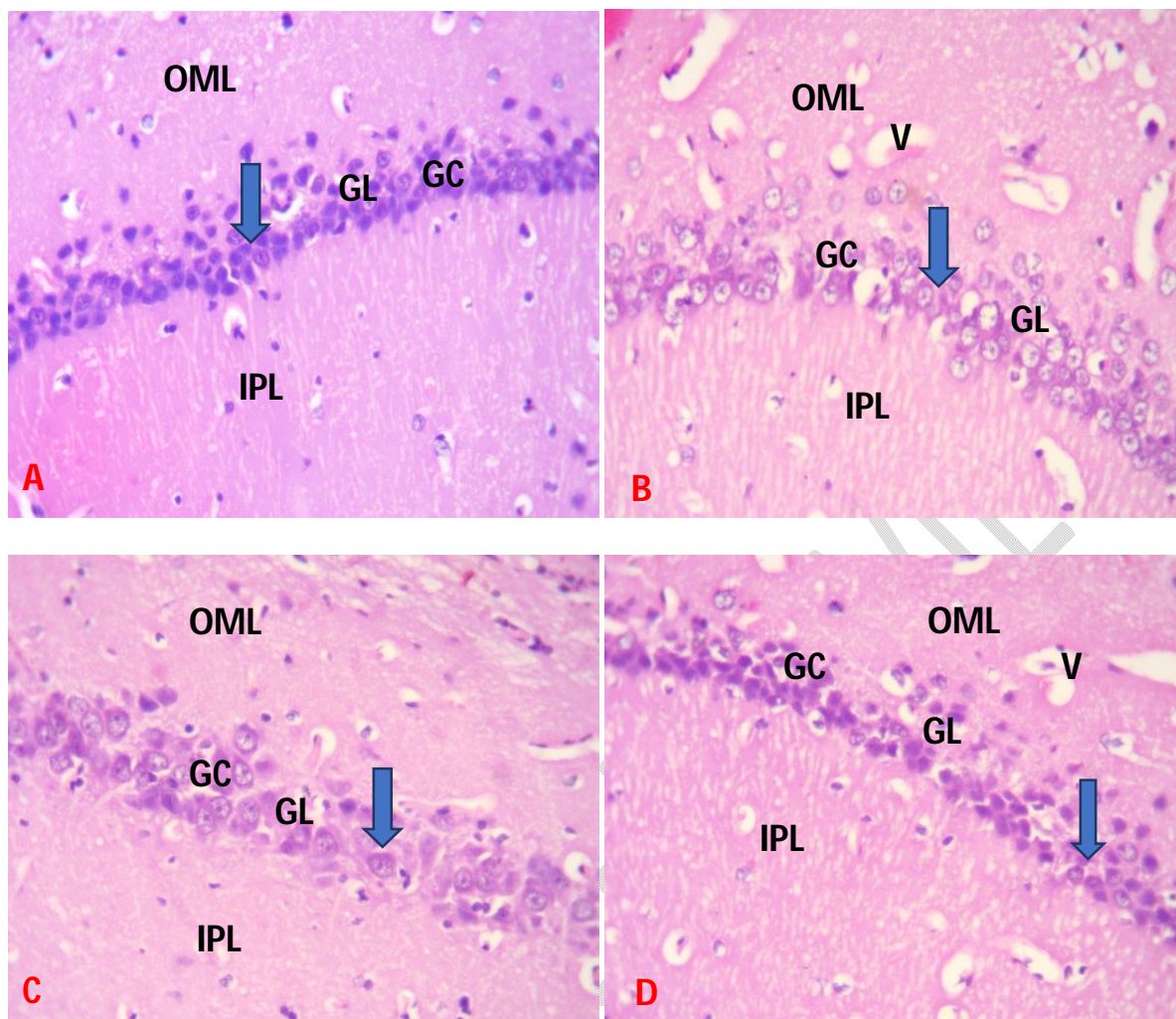




\*:  $p < 0.05$  as compared to group A and D; &:  $p < 0.05$  as compared to group C; #:  $p < 0.05$  as compared to groups A and D.

### 3.6. Effect of *Moringa oleifera* on hippocampal histomorphology against AlCl<sub>3</sub> exposure in normal and treated rats.

The photomicrograph of the AlCl<sub>3</sub>only group (Group B) showed decrease thickness in the granule layer (glial layer) with decline and shrinkage in cells that were arranged loosely, dilated blood vessels and large vacuole (distinctive attributes of hippocampal neurodegeneration) (fig. 6B) compared with the control (group A) (fig. 6A). However, the photomicrograph of the group administered with MO and AlCl<sub>3</sub>(group C) showed decreased incidence of pathological changes in the hippocampus with almost normal brain histomorphology, similar to the control and MO only groups (groups A and C) (fig. 6A, 6C and 6D respectively).



**Fig. 6:** A. Group A (Control): showing normal hippocampus morphology with numerous glial cells (GC) (arrow) within the glial layer (GL);  
 B. Group B (Lead acetate induced only group): showing few pyramidal cells with distorted glial cells (GC) (arrow) within the glial layer (GL) between the inner pyramidal layer (IPL) and outer marginal layer (OML) and Vacuolated neuropils (V);  
 C. Group C (SFN and Lead acetate group): showing preserved proliferation of glial cells (GC) (arrow) within the glial layer (GL) interspersed between the inner pyramidal layer (IPL) and outer marginal layer (OML) similar to control;  
 D. Group D (SFN only): showing normal orientation of glial cells (GC) within the glial layer (GL) between the inner pyramidal layer (IPL) and outer marginal layer (OML) similar to the control.

H and E: x400.

Scale bar-50 $\mu$ m

#### 4. Discussion

Neurodegenerative disorders such as AD are progressive diseases characterized by gradual neuronal loss with several etiologies such as genetic, metabolic process and environmental/toxic agents (neurotoxicants)[43, 44]. AD is categorized as a progressive, irreversible disorders characterized by learning and memory impairments caused by increased oxidative stress, disturbance in antioxidant enzymes levels, reduced mono amine neurotransmitters and pathological features in hippocampal neurons [45-47]. The global detrimental influence of neurodegenerative diseases in recent years has increase the discovery of natural (herbs or plants) compounds with numerous and significant pharmacological properties as an alternative method of addressing many brain disorders since they are abundant, affordable and reliable [48, 49]. Studies have shown that numerous plant-derived phytochemicals prevents the risk of cancer and some chronic diseases such as AD [50-52].

Since adequate learning capability is important for survival and social adaptation of humans and animals, rapid learning process is significant for day to day activities such as escaping from predators and other environmental problems [53]. A serious loss of cognitive function such as memory impairments, attention and problem solving has been recognized as a major medical challenges among AD people [44, 54]. Presently in this study, aluminum intoxication causes learning and memory impairments evident by decreased correct alternation in the Y-maze test, decreased in number of line crossed and rearing frequency in the open field test with concomitant increased duration of escape latency in the Morris water maze test when compared to the control. This observation was in agreement with previous studies after exposure of rat and mice to  $AlCl_3$  and other neurotoxicants [55-61]. Additionally, previous studies have also observed that oral administrations of Al to rodents cause learning and memory deficits [62-64]. Similarly, impairment of rats learning and memory after Al treatment in drinking water in the

passive avoidance task has been reported [65, 66]. However, administration of MO with Al exposure significantly improved acquisition and retention latencies; ameliorate memory declination compared to the AlCl<sub>3</sub> only group and this were in agreement with previous studies that reported increased percentage alternation, decreased duration of escape latency, increased rearing frequency and number of line crossed [67-69] thereby attributing the protective role of MO against aluminum intoxication to the numerous phytochemicals present within the plants such as flavonoids, phenols and vitamins.

Since the clinical manifestation of AD is characterized by progressive decline of cognition and behavior affecting thinking, planning, judgments and social skills culminating into inability to carry out daily activities, oxidative stress has been implicated in the occurrence of AD [70]. Aluminum exposure is an established environmental risk factor in inducing oxidative stress neurological damage similar to the manifestation of AD [42, 54]. In the present result, Aluminum intoxication induced an increase in MDA, NO and H<sub>2</sub>O<sub>2</sub> with concomitant decrease in SOD, CAT and GSH indicating an increase in oxidative stress. This was in agreement with previous studies that reported the intraperitoneal injection of AlCl<sub>3</sub> significantly increased oxidative stress marker (MDA) and decreased antioxidant enzymes levels (SOD, CAT, GSH) [54, 71, 72]. However, the combine administration of MO and Aluminum decreased the levels of oxidative stress and increased antioxidant enzymes levels probably attributed to the strong antioxidant, anti-inflammatory and neuroprotective activities of MO in mopping up excess ROS and free radicals that could elevate oxidative stress levels. This findings is in accordance with previous studies that reported medicinal plants rich in flavonoids and phenols are capable of increasing the reduced antioxidants levels (CAT, SOD and GSH) and decreasing elevated oxidative stress markers (MDA) caused by toxins/ agents capable of oxidative stress induced

damages [72,73]. The protective efficacy of MO against oxidative stress induced AD through aluminum exposure may be correlated to numerous phytochemicals present within the plants such as ascorbic acid and phenols (catechin, epicatechin, ferulic acid, ellagic acid, and myricetin) through scavenging the free radicals.

Previous research reported that decreased brain monoamine neurotransmitters were also associated with memory impairments as occurred in AD [42, 54, 75]. In this present study, aluminum intoxication significantly decreased dopamine and serotonin levels with concomitant increased in norepinephrine level when compared with the control. It was reported by previous studies that environmental neurotoxicants caused elevated neopterin levels in AD brain patients and also alters levels of brain neurotransmitters by depressing cerebrospinal fluid tetrahydrobiopterin levels required for neurotransmitters synthesis [76]. On the other hand, combine treatment of MO and Aluminum significantly elevated the decreased dopamine and serotonin levels but reduced the increased norepinephrine level which was in accordance with previous researchers that showed restorations of various neurotransmitters (such as glutamate, aspartate, gamma-aminobutyric acid, acetylcholine, glycine, dopamine and serotonin) after administration of plants rich in flavonoids and phenolic compounds in several animal models [77-79].

The dependent on Na-K ATPase for the homeostasis of membrane electrochemical gradients is usually altered by oxidative stress thereby causing potential misfiring of neuronal action potential [80, 81]. The present study showed that aluminum intoxication caused significant reduction in serum electrolyte levels (except potassium) when compared to the control. But the administration of MO restored the electrolytes levels ( $K^+$ ,  $Na^+$ ,  $Ca^{2+}$ ,  $Zn^{2+}$  and  $CU^{2+}$ ) probably

due to the potent antioxidants and anti-inflammatory phytochemicals that scavenge the excess free radicals.

Experimental studies have associated degeneration of hippocampal neurons to be influenced by oxidative stress, disturbance of calcium homeostasis, vascular supply reduction and program cell death (apoptosis) [82-86]. The present result showed that aluminum intoxication caused hippocampal neuronal degeneration, cytoplasmic vacuolization, gliosis and pyknosis changes with reduced granular cell layer thickness compared with the control. However, the co-treatment of MO and Aluminum showed preserved histomorphology of the neuronal hippocampus indicating that MO is capable of preventing pathological hippocampal neuronal damage induced by aluminum exposure similar to the control and MO only group. In accordance with previous observation, the improved neuronal dysfunction within the hippocampus could be attributed to the presence of flavonoids present within MO thereby suggesting its neuroprotective and cognitive enhancements potential against oxidative stress induced neurotoxicant [87].

## **5. Conclusion**

The treatment with *Moringa oleifera* possesses neuroprotective and memory enhancing potential by suppressing oxidative stress induced aluminum intoxication probably due to the presence of high level of polyphenols, flavonoids and other anti-oxidative compounds capable of activating cellular antioxidant system.

## **Ethics approval**

The experimental procedures were conducted in accordance with the NIH guidelines for the care and use of laboratory animals in line with guidelines of the Department of Human Anatomy, School of health and Health Technology, Federal University of Technology, Akure, Nigeria and

the Health Research and Ethical Committee of the Federal University of Technology, Akure, Nigeria on 19<sup>th</sup> June, 2019.

#### Disclaimer (Artificial intelligence)

Author(s) hereby declare that NO generative AI technologies such as Large Language Models (ChatGPT, COPILOT, etc.) and text-to-image generators have been used during the writing or editing of this manuscript.

#### REFERENCES

1. Alagiakrishnan K, Gill SS, Fagarasanu A (2012) Genetics and epigenetics of Alzheimer's disease. *Postgrad. Med. J* 88:522–529.
2. Prince MJ (2015) World Alzheimer Report 2015. The Global Impact of Dementia: an Analysis of Prevalence Incidence Cost and Trends.
3. Chin-Chan M, Navarro-Yepes J, Quintanilla-Vega B(2015) Environmental pollutants as risk factors for neurodegenerative disorders: Alzheimer and Parkinson diseases. *Front. Cell. Neurosci* 9:124.
4. Attems J, Thal DR, Jellinger KA (2012) The relationship between subcortical tau pathology and Alzheimer's disease. *Biochem. Soc. Trans* 40: 711–715.
5. Hardy J, and Selkoe DJ(2002) Medicine - The amyloid hypothesis of Alzheimer's disease: progress and problems on the road to therapeutics. *Science* 297: 353–356.
6. Gil-Bea FJ, García-Alloza M, Domínguez J, Marcos B, Ramírez MJ (2005) Evaluation of cholinergic markers in Alzheimer's disease and in a model of cholinergic deficit. *Neurosci. Lett.* 375: 37–41.
7. Francis PT, Palmer AM, Snape M, Wilcock GK (1999) The cholinergic hypothesis of Alzheimer's disease: A review of progress. *J. Neurol. Neurosurg* 66: 137–147.

8. Van Marum RJ. 2008. Current and future therapy in Alzheimer's disease. *Fundam. Clin. Pharmacol.* 22: 265–274
9. Flaten TP (2001) Aluminium as a risk factor in Alzheimer's disease with emphasis on drinking water. *Brain Research Bulletin* 55: 187–196.
10. Heininger K (2000) A unifying hypothesis of Alzheimer's disease. III. Risk factors. *Human Psychopharmacology* 15: 1–70.
11. Ribes D, Colomina MT, Vicens P, Domingo JL(2008) Effects of oral aluminum exposure on behavior and neurogenesis in a transgenic mouse model of Alzheimer's disease. *Exp Neurol* 214:293–300
12. Akila R, Stollery BT, Riihimaki V (1999) Decrements in cognitive performance in metal inert gas welders exposed to aluminium. *Occup Environ Med* 56:632–639
13. Drago D, Folini M, Baiguera S, Tognon G, Ricchelli F, Zatta P(2007) Comparative effects of Aβ<sub>1–42</sub>-Al complex from rat and human amyloid on rat endothelial cell cultures. *J Alzheimers Dis* 11:33–44
14. Zaky A, Mohammad B, Moftah M, Kandeel KM, Bassiouny AR(2013) Apurinic/aprimidinic endonuclease 1 is a key modulator of aluminum-induced neuroinflammation. *BMC Neurosci* 14:26.
15. Gulya K, Rakonczay Z, Kasa P (1990) Cholinotoxic effects of aluminium in rat brain. *J Neurochem* 54:1020–1026.
16. Rakonczay Z, Horváth Z, Juhaász A, Kálmán J (2005) Peripheral cholinergic disturbances in Alzheimer's disease. *Chem Biol Interact* 157–158:233–238.
17. Ghribi O, DeWitt DA, Forbes MS, Herman MM, Savory J(2001) Co-involvement of mitochondria and endoplasmic reticulum in regulation of apoptosis: changes in

cytochrome c Bcl-2 and Bax in the hippocampus of aluminum-treated rabbits. *Brain Res* 903: 66–73.

18. Kaur A, Gill KD(2006) Possible peripheral markers for chronic aluminium toxicity Wistar rats. *Toxicol. Ind. Health* 22: 39–46.
19. Prema A, Justin Thenmozhi A, Manivasagam T, Mohamed Essa M, Guillemin GJ(2017) Fenugreek seed powder attenuated aluminum chloride induced tau pathology oxidative stress and inflammation in a rat model of Alzheimer's disease. *J. Alzheimers Dis* 60:S209–S220.
20. Howes MJ, Perry E(2011) The role of phytochemicals in the treatment and prevention of dementia. *Drugs Aging* 28:439–468.
21. Anwar F, Latif S, Ashraf M, Gilani AH (2007) *Moringa oleifera*: a food plant with multiple medicinal uses. *Phytother Res* 21:17–25
22. Owolabi J, William F, Olanrewaju J, Etibor T, Fabiyi O(2014) Histomorphological evidences of *Moringa oleifera*'s ameliorative effects against lead toxicity in cerebral cortex. *World J Life Sci Med Res* 3(2):53–58
23. Khalafalla MM, Abdellatef E, Dafalla HM, Nassrallah AA, Aboul-Enein KM, Lightfoot DA, El-Deeb FE, El-Shemy HA(2010) Active principle from *Moringa oleifera* lam leaves effective against two leukemias and a hepatocarcinoma. *Afr J Biotechnol* 9(49):8467–8471
24. Ganguly R, Guha D(2008) Alteration of brain monoamines and EEG wave pattern in rat model of Alzheimer's disease and protection by *Moringa oleifera* *Indian J Med Res* 128(6):744–751

25. Akunna GG, Ogunmodede OS, Saalu CL, Ogunlade B, Bello AJ, Salawu EO(2012) Ameliorative effect of *Moringa oleifera* (drumstick) leaf extracts on chromium-induced testicular toxicity in rat testes *World J Life Sci and Medical Research* 2:20
26. Sutalangka C, Jintanaporn W, Wipawee T (2013) *Moringa oleifera* mitigates memory impairment and Neurodegeneration in animal model of age-related dementia. *Oxidative Med Cell Longev* 695936
27. Owolabi JO, Ogunnaike PO(2014) Histological evaluation of the effects of *Moringa* leaf extract treatment on vital organs of murine models. *Merit Res J Med Medical Sci* 2(10):245–257
28. Kirisattayakul W, Wattanathorn J, Tong-Un T, Muchimapura S, Wannanon P(2012) *Moringa Oleifera* lam mitigates oxidative damage and brain infarct volume in focal cerebral ischemia. *Am J Appl Sci* 9(9):1457–1463
29. Kim SM, Kim H, Lee JS, Park KS, Jeon GS, Shon J, Ahn SW, Kim SH, Lee KM, Sung J J, Lee KW(2013) Intermittent hypoxia can aggravate motor neuronal loss and cognitive dysfunction in ALS mice. *PLoS One* 8: 81808
30. Vorhees CV, Williams MT(2006) Morris water maze: procedures for assessing spatial and related forms of learning and memory. *Nat Protoc* 1:848–858
31. Kenney JW, Gould TJ (2008) Modulation of hippocampus-dependent learning and synaptic plasticity by nicotine. *Mol Neurobiol* 38 (1), 101–121
32. Gould TD, Dao DT, Kovacsics CE(2009) The open field test In: mood and anxiety related phenotypes in mice: characterization using behavioral tests *Neuromethods* 42:1–

33. Pearse AG(1975) The role of histochemistry in increasing objectivity in histopathology. Postgrad Med J 51: 708-10
34. Fischer AH, Jacobson KA, Rose J, Zeller R (2008) Hematoxylin and eosin staining of tissue and cell sections CSH Protoc pdbprot4986
35. Sun M, Zigman S(1978) An improved spectrophotometric assay for superoxide dismutase based on epinephrine autoxidation. Anal Biochem 90: 81-89
36. Clairborne A(1995) Catalase activity In: AR Greewald, ed Handbook of methods for oxygen radical research Boca Raton, Florida, USA: CRC 237–242
37. Jollow DJ(1974) Bromobenzene induced liver necrosis: protective role of glutathione and evidence for 3,4-bromobenzene oxide as the hepatotoxic metabolite. Pharmacology 11: 151–169
38. Farombi EO(2000) Chemoprevention of 2-acetylaminofluorene induced hepatotoxicity and lipid peroxidation in rats by kolaviron – a Garcinia kola seed extract Food and Chemical Toxicology 38: 535–541
39. Moshage H(1995) Nitrite and nitrate determinations in plasma: a critical evaluation Clinical Chemistry 41: 892–896.
40. Aebi HE (1984) Methods of enzymatic analysis, vol 105 Berlin: VerlagChem; 121–6
41. Pagel P, Blome J, Wolf HU(2000) High-performance liquid chromatographic separation and measurement of various biogenic compounds possibly involved in the pathomechanism of Parkinson's disease. J Chromatogr B Biomed SciAppl 746: 297–304
42. Ogunlade B, Adedokun SA, Agie JA(2020) Nutritional supplementation of gallic acid ameliorates Alzheimer-type hippocampal neurodegeneration and cognitive impairment

induced by aluminum chloride exposure in adult wistar rats. *Drug and Chemical Toxicology*.

43. Giacoppo S, Galuppo M, Montaut S, Iori R, Rollin P, Bramanti P, Mazzon E(2015) An overview on neuroprotective effects of isothiocyanates for the treatment of neurodegenerative diseases. *Fitoterapia* 106: 12–21
44. Prince M, Bryce R, Albanese E, Wimo A, Ribeiro W, Ferri CP(2013) The global prevalence of dementia: a systematic review and metaanalysis. *Alzheimer's Dementia* 9(1): 63–75.
45. Dobhal T, Bawa G, Kaur A, Kumar SLH(2013) Herbal medicines and their neuroprotective effects in Alzheimer's disease and associated symptoms *Inte J Pharmamedix India* 1(3): 510-28
46. Yin Y, Ren Y, Wu W, Wang Y, Cao M, Zhu Z, Wang M, Li W(2013) Protective effects of bilobalide on A $\beta$ 25–35induced learning and memory impairments in male rats. *Pharmacol Biochem Behav* 106: 77-84
47. Haider S, Saleem S, Perveen T, Tabassum S, Batool Z, Sadir S, Liaquat L, Madiha S (2014) Age-related learning and memory deficits in rats: role of altered brain neurotransmitters, acetylcholinesterase activity and changes in antioxidant defense system *Age (Dordr)* 36(3): 1291- 1302
48. Abalaka ME, Olonitola OS, Onaolapo JA, Inabo HI(2009) Evaluation of acute toxicity of *Momordica charantia* extract, using wistar rats to determine safety evels and usefulness of the plant in ethnochemotherapy *International Journal of Applied Science* 3: 1–6

49. Awodele O, Oreagbe IA, Odoma S, da Silva JAT, Osunkalu VO(2012) Toxicological evaluation of the aqueous leaf extract of *Moringa oleifera* Lam (Moringaceae) *J Ethnopharmacol* 139: 300–306
50. Calabrese V, Guagliano E, Sapienza M, Panebianco M, Calafato S, Puleo E, Pennisi G, Mancuso C, Butterfield DA and Stella AG(2007) Redox regulation of cellular stress response in aging and neurodegenerative disorders: role of vitagenes. *Neurochem Res* 32: 757–773
51. Fuentes F, Paredes-Gonzalez X, Kong A-NT(2015) Dietary glucosinolates sulforaphane, phenethyl isothiocyanate, indole-3-carbinol/3,3'-diindolylmethane: antioxidative stress/inflammation, Nrf2, epigenetics/epigenomics and in vivo cancer chemopreventive efficacy *Curr Pharmacol Rep* 1: 179–196
52. Alrawaiq NS, Abdullah A(2014) An evaluation of sulforaphane as a potential agent for disease prevention. *Res J Pharm Biol Chem Sci* 5: 1335–1349
53. Heckman JJ (2007) The economics, technology, and neuroscience of human capability formation *Proc Natl Acad Sci USA* 104(33): 13250-5
54. Abdelghany AK, Khalil F, Azeem NMA, El-Nahass ES, El-Kashlan AM, Emeash HH (2019) Ginseng and moringa olifera ameliorated cognitive impairments induced by aluminium chloride in albino rat *Adv Anim Vet Sci.* 7(7): 557-565.
55. Lal B, Gupta A, Gupta A, Murthy RC, Ali MM, Chandra SV (1993) Aluminum ingestion alters behaviour and some neurochemicals in rats. *Indian J Exp Biol* 31(1): 30-5
56. Yellamma K, Saraswathamma S, Kumari BN(2010) Cholinergic system under aluminium toxicity in rat brain. *ToxicolInt* 17(2): 106-12

57. Sharma DR, Wani WY, Sunkaria A, Kandimalla RJ, Verma D, Cameotra SS(2013) Quercetin protects against chronic aluminum induced oxidative stress and ensuing biochemical, cholinergic, and neurobehavioral impairments in rats. *Neurotox Res* 23(4): 336-57
58. Iqbal G, Iqbal A, Mahboob A, Farhat SM, Ahmed T(2016) Memory Enhancing Effect of Black Pepper in the AlCl<sub>3</sub> Induced Neurotoxicity Mouse Model is mediated through Its Active Component Chavicine *Curr Pharm Biotechnol* 17 (11): 962-73
59. Justin Thenmozhi A, Raja TR, Janakiraman U, Manivasagam T(2015) Neuroprotective Effect of Hesperidin on Aluminium Chloride Induced Alzheimer's Disease in Wistar Rats. *Neurochem Res* 40(4): 767-76
60. Xing Z, He Z, Wang S, Yan Y, Zhu H, Gao Y, Zhao Y, Zhang L(2018) Ameliorative effects and possible molecular mechanisms of action of fibrauretin from *Fibraurea recisa* Pierre on D-galactose/AlCl<sub>3</sub>-mediated Alzheimer's disease. *RSC Adv* 8(55): 31646-31657
61. Zghari O, Rezqaoui A, Ouakki S, Lamtai M, Chaibat J, Mesfioui A, El Hessni A, Rifi E, Essamri A, Ouichou A(2018) Effect of Chronic Aluminum Administration on Affective and Cognitive Behavior in Male and Female Rats. *JBBS* 8(4): 179-196
62. Sethi P, Jyoti A, Singh R, Hussain E, Sharma D(2008) Aluminium induced electrophysiological, biochemical and cognitive modifications in the hippocampus of aging rats. *Neurotoxicology* 29: 1069-79
63. Ribes D, Colomina MT, Vicens P, Domingo JL(2010) Impaired spatial learning and unaltered neurogenesis in a transgenic model of Alzheimer's disease after oral aluminum exposure. *Curr Alzheimer Res* 7(5): 401-8

64. Linardaki ZI, Orkoula MG, Kokkosis AG, Lamari FN, Margarity M(2013) Investigation of the neuroprotective action of saffron (*Crocus sativus* L) in aluminum-exposed adult mice through behavioral and neurobiochemical assessment. *Food Chem Toxicol* 52: 163-70
65. Abd-Elhady RM, Elsheikh AM, Khalifa AE(2013) Anti-amnestic properties of ginkgo biloba extract on impaired memory function induced by aluminum in rats. *Int J Dev Neurosci* 31(7): 598-607
66. Connor DJ, Harrell LE, Jope RS (1989) Reversal of an aluminum induced behavioral deficit by administration of deferoxamine *Behav Neurosci* 103(4): 779-83
67. Kim JM, Park CH, Park SK, Seung TW, Kang JY, Ha JS, Lee DS, Lee U, Kim DO, Heo HJ(2017) Ginsenoside Re Ameliorates Brain Insulin Resistance and Cognitive Dysfunction in High-fat Diet-induced C57BL/6 Mice. *J Agric Food Chem* 65(13): 2719-2729
68. Omotoso GO, Gbadamosi IT, Afolabi, TT, Abdulwahab AB, Akinlolu AA(2018) Ameliorative effects of Moringa on cuprizone induced memory decline in rat model of multiple sclerosis. *Anat Cell Biol* 51(2): 119-127
69. Zhu JD, Wang JJ, Zhang XH, Yu Y, Kang ZS(2018) Panax ginseng extract attenuates neuronal injury and cognitive deficits in rats with vascular dementia induced by chronic cerebral hypoperfusion. *Neural Regen Res* 13(4): 664-672.
70. Iulita MF, Cuello AC(2014) Nerve growth factor metabolic dysfunction in Alzheimer's disease and Down syndrome *Trends. Pharmacol Sci*35: 338-348
71. Bitra VR, Rapaka D, Mathala N, Akula A(2014) Effect of wheat grass powder on aluminum induced Alzheimer's disease in Wistar rats *Asian Pac J Trop Med* 7(1): 278-81

72. Lakshmi BV, Sudhakar M, Prakash KS(2015) Protective Effect of Selenium Against Aluminum Chloride-Induced Alzheimer's Disease: Behavioral and Biochemical Alterations in Rats. *Biol Trace Elem Res* 165: 67-74
73. Randriamboavonjy JI, Rio M, Pacaud P, Loirand G, Tesse A (2017) Moringa oleifera seeds attenuate vascular oxidative and nitrosative stresses in spontaneously hypertensive rats. *Oxid Med Cell Longev* 4129459
74. Omodanisi EI, Aboua YG, Oguntibeju OO(2017) Assessment of the anti-hyperglycaemic, anti-inflammatory and antioxidant activities of the methanol extract of Moringa oleifera in diabetes-induced nephrotoxic male Wistar rats. *Molecules*22:439
75. Lee CH, Hwang IK, Choi JH, Yoo KY, Park OK, Huh SO, Lee YL, Shin HC, Won MH. (2010) Age-dependent changes in calretinini and its protein level in the gerbil hippocampus. *Neurochem Res* 35(1): 122-9
76. Foster HD (2000) How Aluminum Causes Alzheimer's disease: The Implications for Prevention and Treatment of Foster's Multiple Antagonist Hypothesis. *J Orthomolecul Med* 15(1)
77. Xiang H, Liu Y, Zhang B, Huang J, Li Y, Yang B, Huang Z, Xiang F, Zhang H (2011) The antidepressant effects and mechanism of action of total saponins from the caudexes and leaves of Panax notoginsengin animal models of depression. *Phytomedicine* 18 (8-9): 731-8
78. Zhang Y, Pi Z, Song F, Liu Z(2016) Ginsenosides attenuate d-galactose-and AlCl<sub>3</sub>-inducedspatial memory impairment by restoring the dysfunction of the neurotransmitter systems in the rat model of Alzheimer's disease. *J Ethnopharmacol* 194: 188-95

79. Prabsattroo T, Wattanathorn J, Iamsa-ard S, Muchimapura S, Thukhammee W(2012) Moringa oleifera leaves extract attenuates male sexual dysfunction. *American Journal of Neuroscience* 3(1):17–24.
80. Graeff FG, Netto CF, Zangrossi H Jr (1998) The elevated T-maze as an experimental model of anxiety *Neurosci Biobehav Rev* 23: 237-46
81. Dhingra D, Parle M, Kulkarni SK(2006) b-Alanine protects mice from memory deficits induced by ageing, scopolamine, diazepam and ethanol *Indian J Pharm Sci* 68: 216-21
82. Candelario-Jalil E, Mhadu NH, Al-Dalain SM, Mart´inez G, Le´on OS(2001) Time course of oxidative damage in different brain regions following transient cerebral ischemia in gerbils. *Neuroscience Research* 41(3): 233–241.
83. Saito KI, Elce JS, Hamos JE, Nixon RA (1993) Widespread activation of calcium-activated neutral proteinase (calpain) in the brain in alzheimer disease: a potential molecular basis for neuronal degeneration. *Proceedings of the National Academy of Sciences of the United States of America* 90(7):2628– 2632.
84. Fukui K, Omoi NO, Hayasaka T(2002) Cognitive impairment of rats caused by oxidative stress and aging, and its prevention by vitamin E. *Annals of the New York Academy of Sciences* 959: 275–284.
85. Gorelick PB, Scuteri A, Black SE(2011) Vascular contributions to cognitive impairment and dementia: a statement for healthcare professionals from the American Heart Association American Stroke Association. *Stroke* 42(9):2672–2713.
86. Yu W, Mechawar N, Krantic S, Quirion R(2010) Evidence for the involvement of apoptosis-inducing factor-mediated caspase-independent neuronal death in alzheimer disease. *American Journal of Pathology* 176(5):2209–2218.

87. Youdim KA, Joseph JA(2001) A possible emerging role of phytochemicals in improving age-related neurological dysfunctions: a multiplicity of effects. Free Radical Biology and Medicine 30(6):583–594.

UNDER PEER REVIEW