

Case report

RADIOLOGICAL DIAGNOSIS OF THROMBOPHLEBITIS OF THE RIGHT OVARIAN VEIN: A CASE REPORT

ABSTRACT

Ovarian vein thrombosis (OVT) is a rare condition usually occurring in the postpartum period. Its incidence outside the postpartum period is not known. We reported a case of a 23-year-old patient at Amath DANSOKHO National Hospital Center in Kédougou, Senegal, she had no particular gestational history, she was non-febrile with overall negative laboratory tests apart a C-reactive protein (CRP) that was twice as high as normal. The abdominal CT scan made led to the diagnosis of thrombophlebitis of the right ovarian vein on probable pelvic inflammatory disease. Treatment combining anticoagulant, antibiotic and anti-inflammatory improved the clinical sign.

Keywords: Flank pain; ovary vein; thrombosis.

INTRODUCTION

Ovarian venous thrombosis (OVT) is a rare pathology, usually occurring in the postpartum period. However, it can occur in other circumstances, such as pelvic inflammatory disease, gynecological tumors, after pelvic surgery, during sepsis, during a state of hypercoagulability or even sometimes without an underlying cause. It usually manifests itself as non-specific abdominal pain, with or without fever, and must be recognized, because of its potential serious or even fatal complications (pulmonary embolism) (1).

Historically, OVT was identified during exploratory laparoscopy and its prognosis was guarded, with a mortality of nearly 50% (1).

When patients are outside the peripartum period, the diagnosis is challenging and requires a high suspicion index. OVT can also occur after abdominal surgeries rather than hysterectomy (2).

The incidence of OVT outside the postpartum period is not known in particular in this region, thus being the subject of isolated "case reports". It has been described in association with pelvic inflammatory diseases (salpingitis, ovarian tubo abscesses, pelvic abscesses). OVT develops frequently in post-hysterectomy and/or oophorectomy patients; also, it has been reported to occur in patients with malignancy (3). Coronavirus disease 2019 (COVID-19) is well known to cause a general hypercoagulable state and has been associated with many cases of stroke, myocardial infarction, and deep venous thrombosis. OVT was also reported with COVID-19 infection in a few case reports (4). Its diagnosis, once made difficult by the existence of misleading clinical signs, is now facilitated by new cross-sectional imaging data: ultrasound (US), computed tomography (CT) and magnetic resonance imaging (MRI)(5).

The treatment is mainly medical, combining heparin and antibiotic therapy, surgery being reserved for complicated forms (5).

We report the case of a patient who presented with this pathology outside the postpartum period, with a clinical sign of non-febrile right flank pain.

PRESENTATION OF THE CASE:

We present the case of a twenty-three-year-old patient, multiparous, with no known medical history of surgery, in particular of ovarian thrombophlebitis, referred to the surgery department for pain in the right flank and nausea. The patient reported that she had put on contraception (left arm) 15 days before, followed by a low abundance of metrorrhagia. On clinical examination the patient was non-febrile, with no signs of peritoneal irritation or palpable abdominal mass, there was no abnormal vaginal discharge, the urine dipstick revealed nothing particular, bacteriological examination of the urine was not carried out given the context, as well as blood cultures. Biologically, there was no leukocytosis or inflammatory syndrome apart a C-reactive protein (CRP) that was twice as high as normal ($<6\text{mg/l}$), X-ray and ultrasound examinations had not been performed.

A abdominopelvic CT scan was performed with no contrast and after contrast revealing the existence of thrombosis of the right ovarian vein which appeared dilated, with central hypodensity (**Figure 1A**), parietal enhancement after iodine venous injection and extensive infiltration of peripheral fat (**Figure 1B**). The thrombosis extended from the pelvis to the opening of the ovarian vein into the inferior vena cava, appearing to be discreetly invaded (**Figure 2A and B**).

On the sections passing through the pelvis, we noted the presence of a collection of low abundance in the Douglas-fir, lateralized to the right, testifying to a probably inflammatory adnexal origin of this thrombosis (**Figure 3B**). There was no noticeable abnormality in the urinary excretory tract, especially on the right. The liver, the spleen and the pancreas appeared normal, the appendix was visualized in the right iliac fossa without any abnormality, there was no abdominopelvic lymphadenopathy, nor any abnormality in the bone reconstruction.

The diagnosis was that of thrombophlebitis of the right ovarian vein on probable pelvic inflammatory disease, medical treatment was immediately initiated, combining low molecular weight heparins, antibiotic and analgesic. The clinical course was favorable and the patient was discharged from hospital seven days after admission.

For reasons of difficult access to the hospital for the patient, a CT scan was carried out two months later, revealing a repermeabilization of the right ovarian vein and a disappearance of the small collection in the Douglas. (**Figure 4A and B**)

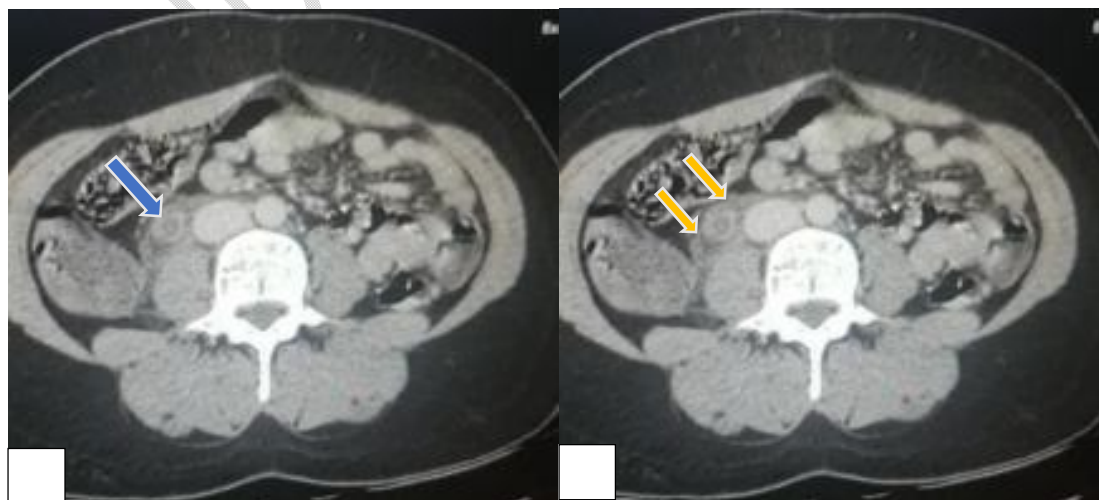


Figure 1.

A. Axial CT slice post contrast passing through the plane of the subrenal vena cava: thrombosis of the right ovarian vein with central hypodensity and parietal enhancement. (blue arrow)

B. Axial CT slice post contrast passing through the plane of the subrenal vena cava: strongly infiltrated appearance of the peripheral fat of the ovarian vein strongly suggestive of an inflammatory origin. (yellow arrows)

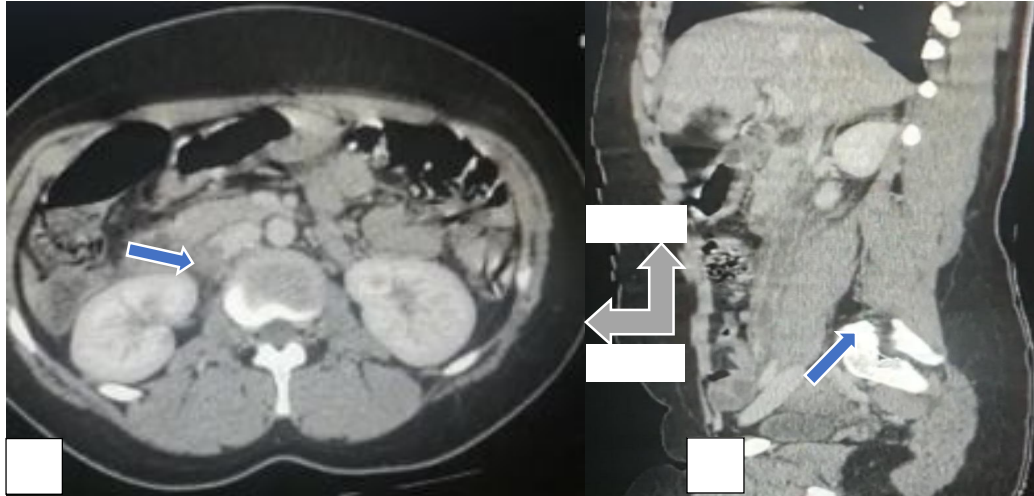


Figure 2.

A. Axial CT slice post contrast passing through the plane of the inferior vena cava at the level of the kidneys: thrombosis of the right ovarian vein extended to its outlet at the level of the inferior vena cava appearing to be discreetly invaded. (blue Arrow)

B. Sagittal CT slice post contrast: thrombosis extended from the pelvis to the opening of the ovarian vein into the inferior vena cava. (blue Arrow)

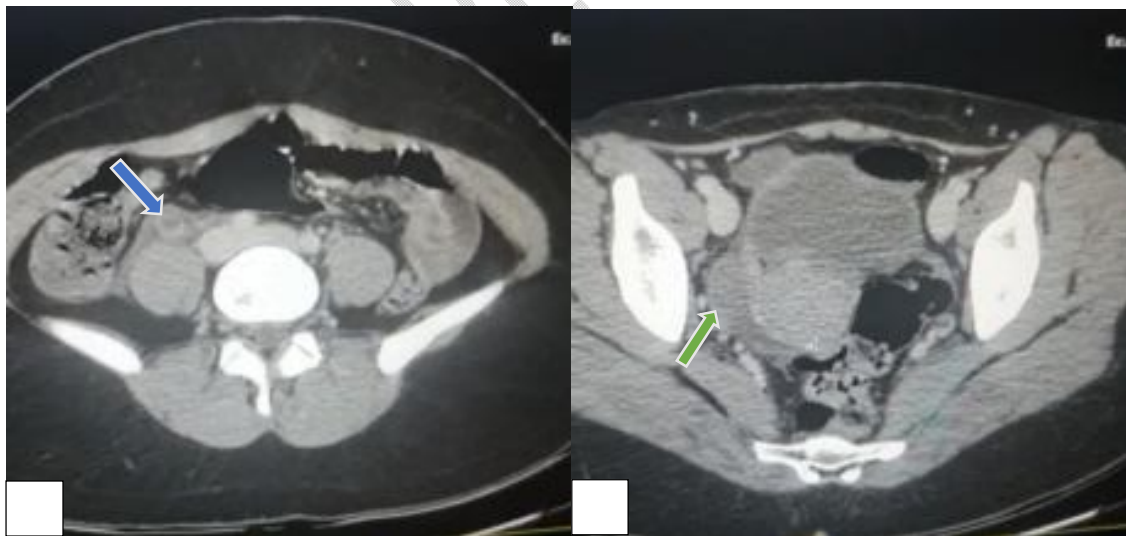


Figure 3.

A. Axial CT slice post contrast passing through the plane of the iliac wings in front of the bifurcation of the inferior vena cava, thrombosis of the right ovarian vein with dilation of the latter and parietal thickening. (blue Arrow)

B. Axial CT slice post contrast passing through the pelvis: fluid collection of low abundance of lateralized Douglas fir on the right, suggestive of an inflammatory pelvic disease probably adnexal. (green Arrow)

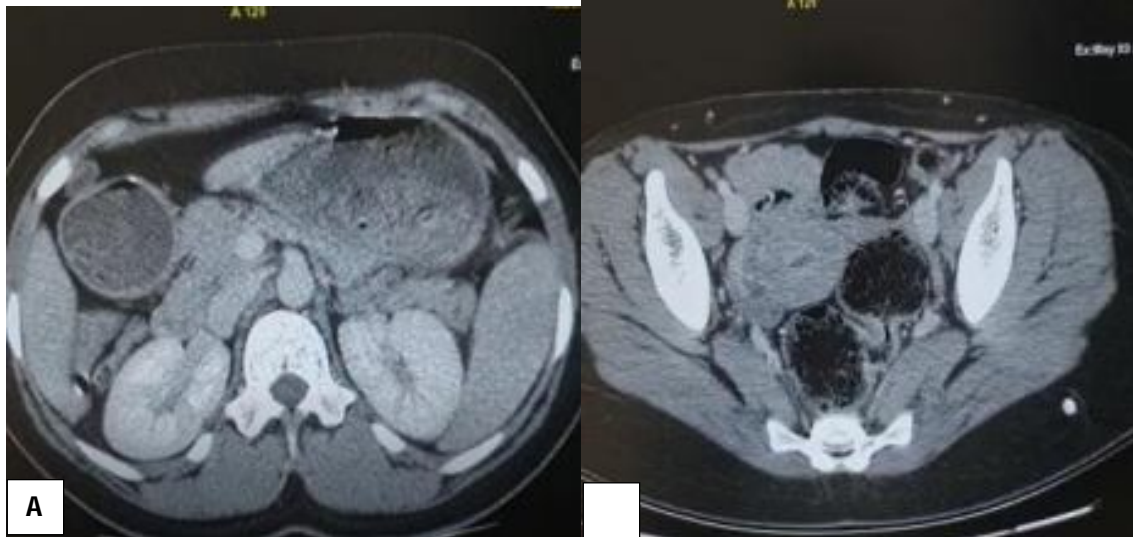


Figure 4. A follow-up CT scan after treatment

A. Axial CT section post contrast passing through the plane of kidney; there is a repermeabilization of the right ovarian vein.

B. Axial CT section post contrast passing through the plane of the iliac wings showing a free Douglas-fir.

DISCUSSION

Anatomy

The ovarian venous plexus is located in the broad ligament of the uterus around the ovary and near the fallopian tubes, which converges into the ovarian veins, and the ovarian veins ascend within the suspensory ligament of the ovaries (6,7). Then, they proceed in front of the psoas muscle and pass through the ureter at the level of the 3/4 vertebral body of the lumbar spine (8). The right ovarian vein diagonally drains into the inferior vena cava directly below the right renal vein, and the left ovarian vein flows into the left renal vein at a right angle in most individuals (9).

Pathology

OVT is a rare condition first described by Austin in 1956 and occurs very often in the postpartum period (10). However, it can occur in other circumstances: during inflammatory pelvic diseases, gynecological tumors, after pelvic surgery, during sepsis, during hypercoagulability or even sometimes without an underlying cause (1,10,11). Ovarian venous thrombosis is more likely to occur in multiparous women (12).

The increased levels of estrogen, coagulation factors, von Willebrand factor and platelet activating factors contribute to hypercoagulability. There is also greater chance of endothelial damage. If there is bacterial contamination of the ovarian vein in the course of the delivery, a variant of OVT (i.e. septic thrombophlebitis) may arise, which can in turn make the OVT diagnosis even more challenging (13).

Even though OVT arises mainly on the right side, the events on the left vein have been described and this possibility cannot be overlooked in patients with left-side symptoms and signs (14,15).

The digestive manifestations of OVT are represented by nausea, vomiting, tenesmus and spurting (by involvement of the rectal venous plexus), reflex ileus, and even abdominal pain. These signs may involve the iliac fossa (most often straight) and/or the lumbar fossa and the costo-vertebral angle and lead to a surgical abdominal picture with peritoneal defense and irritation. Pollakiuria (damage to the venous bladder plexus) is also often associated. Thus, OVT can simulate appendicitis, pyelonephritis, tubo-ovarian abscess or adnexal torsion.

Sometimes, the symptomatology is that of an inaugural renal colic due to extrinsic ureteral compression, for which the urologist may be consulted (16).

Given the non-specificity of clinical symptoms, paraclinical examinations are important to make a diagnosis.

Radiology

Since the clinical presentation is nonspecific, the diagnosis of ovarian vein thrombosis relies heavily on imaging studies (combined gray-scale and power or color Doppler study, CT or MRI); there is no consensus regarding the gold standard exam to be offered to the patients with suspected OTV(17).

On ultrasound, the appearance of OVT corresponds to that of acute venous thrombosis of other locations. A hypoechoic tubular structure is identified in the paravertebral position, between the inferior vena cava and an appendage. The classic criterion of non-compressibility of the thrombosed vein is difficult to apply in the case of OVT, due to the location of the ovarian veins. In addition, the deep location of the ovarian veins makes their ultrasound exploration difficult because of the frequent interposition of digestive gases. The identification in the US of a hypoechoic tubular structure in the right iliac fossa can also be confused with appendicitis. These limitations explain the limited performance of the US for the exploration of OVT, with a sensitivity of around 50 to 55% and a specificity of 41 to 99% (18).

Doppler ultrasound can find a laterocaval, cylindrical, hypoechoic retroperitoneal image corresponding to a large ovarian vein, whereas usually, it is not visualized because it is too small.

It is a completely safe examination, which is generally easy and quick to carry out in routine practice, in the context of an emergency. It is of great use for the follow-up of patients under treatment, although its main limitations are the operator-dependent nature and the difficulties of exploration in the event of meteorism (19).

Conventional CT scans have been well described by Dunning: the appearance of a large dilated ovarian vein whose walls are enhanced after intravenous injection of contrast agent, with a central lumen that appears hypodense (20).

There may be an aspect of fat infiltration of inflammatory origin, located in contact with the ovarian vein, behind the right parietocolic groove, which may simulate a tumor process. The presence of gas hypodensity inside the thrombus indicates the septic nature of the disease (21).

The study by Khelifi A et al. showed that CT had better sensitivity (100%) compared to MRI (92%) and Doppler ultrasound (50%). However, the MRI can also specify how old the thrombus are, thanks to the ferromagnetic properties of the hemoglobin. It also provides information about blood flow (slowed or not) (22).

The radiological assessment should also look for a dilation of the urinary excretory tract, this is part of the ovarian vein syndrome defined by compression of a ureter by an aberrant and dilated ovarian vein (23).

CONCLUSION

OVT is rare. It poses the problem of etiological diagnosis and emergency treatment of acute pseudo-surgical abdominal pain. The exhaustive interpretation of cross-sectional imaging not only makes it possible to make a positive diagnosis but most often to look for an etiological for adequate management.

DISCLAIMER (ARTIFICIAL INTELLIGENCE)

Authors hereby declare that NO generative AI technologies such as Large Language Models (ChatGPT, COPILOT, etc.) and text-to-image generators have been used during the writing or editing of this manuscript.

CONSENT

As per international standard or university standard, patient written consent has been collected and preserved by the author.

ETHICAL APPROVAL

As per international standard or university standard written ethical approval has been collected and preserved by the author.

COMPETING INTERESTS

Authors have declared that no competing interests exist.

REFERENCES

1. Meuwly JY, Kawkabani-marchini A, Sgourdos G. Ovarian venous thrombosis. Forum Med Suisse 2012;12(7):144–148.
2. Chandran T, Bani Hani M, Hain J: Simultaneous ovarian and renal vein thrombosis as a rare cause of postoperative pain after sigmoid colectomy. Am Surg. 2023, 89:3629-30. 10.1177/00031348231167409
3. Ahmed M, Mendha T, Do V, Carlan S, Madruga M: Ovarian vein thrombosis: an unusual cause of abdominal pain in breast cancer. Cureus. 2023, 15:e37363. 10.7759/cureus.37363
4. Patel SV, Shah S, Patel R, Bavishi S, Pethani Y, Shah K: Ovarian vein thrombosis: a sequela of COVID-associated coagulopathy. Cureus.2023, 15:e36437. 10.7759/cureus.36437
5. Sappey O, Mollier S. Puerperal thrombophlebitis of the ovarian vein revealed by renal colic. Progress in Urology(1999), 9, 313-318.
6. Drake RL, Vogl AW. Gray's Anatomy for Students. 4th ed. Canada: Elsevier 2020
7. Karaosmanoglu D, Karcaaltincaba M, Karcaaltincaba D, Akata D, Ozmen M. MDCT of the ovarian vein: Normal anatomy and pathology. AJR Am J Roentgenol 2009; 192(1): 295-9.[http://dx.doi.org/10.2214/AJR.08.1015] [PMID: 19098213]
8. Bhutta HY, Walsh SR, Tang TY, Walsh CA, Clarke JM. Ovarian vein syndrome: A review. Int J Surg 2009; 7(6): 516-20. [http://dx.doi.org/10.1016/j.ijvsu.2009.09.008] [PMID: 19818884]
9. Gupta R, Gupta A, Aggarwal N. Variations of gonadal veins: Embryological prospective and clinical significance. J Clin Diagn Res 2015; 9(2): AC08-10
10. Chennana A, Kouach J, Akharraz A et al. Thrombosis of the ovarian vein in the postpartum period, revealed by appendicular syndrome: a case report. Pan African Medical Journal. 2015 ;21 :187.
11. Desmots F, Cournac JM, Caze N et al. Ovarian vein thrombosis: a rare cause of febrile abdominal pain. Internal medicine journal. 2012; 33(S1): 98-9.
12. Munsik RA, Gillanders LA. A review of the syndrom of puerperal ovarian vein thrombophlebitis. Obstet. Gynecol. Surv., 1981, 36, 57.
13. Ferguson S, Arbona D, Furiato A. Postpartum Ovarian Vein Thrombosis: Case Report. Clinical Practice and Cases in Emergency Medicine. 2022

14. Tesfaye S, Tariku M, Hirigo AT. Postpartum left ovarian vein thrombosis. *SAGE Open Medical Case Reports*. 2020; 8:2050313X20962637.
15. Azhar E, Nguyen T, Waheed A. Left ovarian vein thrombosis presenting as acute postpartum pyelonephritis. *Cureus*. 2020;12(2)
16. Toland KC, Pelander WM, Mohs SJ. Postpartum ovarian vein thrombosis presenting as ureteral obstruction: a case report and review of the literature. *J. Urol.*, 1993; 149: 1538-40.
17. Riva N, Calleja-Agius J. Ovarian Vein Thrombosis: A Narrative Review. *Hamostaseologie*. 2021;41(4):257-66
18. Vandermeer FQ, Wong-You-Cheong JJ. Imaging of acute pelvic pain. *Clin ObstetGynecol*. 2009 ;52(1):2–20.
19. Ranchoup Y, Thony F, Dal Soglio S et al. Puerperal thrombophlebitis of the ovarian vein with inferior caval extension: ultrasound aspects, CT scan and MRI. *J. Radiol*. 1998 ; 79 : 127-31.
20. Dunnihoo DR, Gallaspy JW, Wise RB et al. Postpartum ovarian vein thrombophlebitis: a review. *Obstet. Gynecol. Surv.*, 1991; 46: 415-427.
21. Savader S, Otero RR, Savader BL. Puerperal ovarian vein thrombosis: evaluation with CT, US, and MR imaging. *Radiology*, 1988; 167: 637-639.
22. Khlifi A, Kebaili S. Thrombophlebitis of the ovarian vein : an emergency not to be ignored. *Imagery of Women*. 2010 ; 20(3) : 165-8.
23. El harrech Y, Janane A et al. The syndrom of the ovarian vein, about 4 case. *Maroc Urol*. 2006;3: 22-26. PubMed | Google Scholar. French