

Original Research Article

Role of X-ray, CT and MRI in decision making of Thoracolumbar fractures: Prospective Inter-Observer Reliability Analysis

UNDER PEER REVIEW

ABSTRACT

Background: Thoracolumbar fractures have a varied clinical presentation and surgeons mainly depend on radiological investigations for planning management. Most modern classifications like TLICS (Thoraco-Lumbar Injury Classification and Severity score) and AO classification rely on additional data from CT and MRI which are expensive and not easily available. There are not many studies to document whether addition of CT and MRI changes the classification by an experienced surgeon and his decision-making process. **Methods:** 40 patients with thoracolumbar spine fractures ranging in severity from the simple to the most complex were selected. Four surgeons of varied experience in spine surgery (15 years, 8 years, 3 and 2 years) assessed these fractures with x-ray radiographs, followed by CT and MRI. The interobserver reliability of each classification, and the reason for the change with addition of CT and MRI was studied. **Results:** Addition of CT scan to plain radiographs involved a change in classification in 25% of cases in McAfee and AO classification, and 27% in TLICS. This led to a 10% change in management decision amongst surgeons. Assessment with MRI did not produce any major change in McAfee and AO classification but, there was change in classification and management in 47.5 % of cases in TLICS all of which were displaced fractures. The PLC status correlation among the surgeons is moderate with X-ray and CT group ($k=0.51$), but with addition of the MRI ($k=0.92$) correlation became very good. **Conclusion:** X-rays are helpful in initial evaluation of thoracolumbar spine injuries. CT scan provides additional information like fracture pattern, fracture morphology and indirectly determine PLC tear by the presence of displacement of the fragments into the spinal canal. MRI confirms spinal cord compression and PLC injury. PLC was torn in all displaced fractures, so displacement is a criteria to diagnose PLC injury. Hence, Xray, CT Scan and MRI are investigations of choice in that serial order in making decision regarding their management.

Key words: Thoracolumbar; fracture; interobserver; reliability; MRI

INTRODUCTION

Spine fractures represent 6% of all fractures worldwide.¹ The most affected segment is the thoracolumbar spine, which accounts for approximately 50%.¹ Their importance is significant in view of potential spinal cord injury, spinal instability and also the resultant problems. Evaluation of the spinal injury patient includes careful clinical assessment and appropriate radiological investigation.² Standard anterior posterior and lateral radiographs are the initial imaging modalities for all patients.³

Computed Tomography (CT) scan reveals bony anatomy in detail and in an expedite manner.^{4,5} With advent of MRI (Magnetic Resonance Imaging), its ability to accurately detect spinal cord compression, epidural hemorrhage, soft tissue injury and ligamentous insufficiency has motivated physicians to use MRI on a larger scale.^{4,5} However the increased cost, availability, delay in the treatment and lack of clear evidence that can improve management decision & outcomes makes us contemplate its mandatory use.

Classification of thoracolumbar fracture has been in vogue since 1929 after Bohler provided the first morphological classification. An ideal classification should be easy to understand and use, facilitate accurate exchange of information and guide treatment plan and diagnosis. Even though many classifications like Nicoll's classification, Dennis classification, Allen Ferguson classification, McAfee classification, TLICS, Load shearing classification and AO classification have been described from time to time, but none of them were proved to be reliable. Recent classifications such as TLICS strongly advocate the use of MRI in the classification and treatment plan.⁶ McAfee classification which is commonly used has potential significant variation depending on whether X-ray alone or CT scan is also used for classification.⁶

There is a dearth of studies to assess the specific role of CT and MRI in fracture classification and management and also whether addition of CT and MRI actually changes the classification and decision-making process of spine surgeons. Based on this premise, we undertook this study to evaluate the usefulness of the CT scan and MRI in classifying the fractures according to the commonly used classifications (McAfee, TLICS, AO classification). Also changes in the treatment

plan based on CT scan, MRI and inter-observer reliability among four spine surgeons with different grades of experience in fracture classification were studied.

UNDER PEER REVIEW

MATERIALS AND METHODS

Forty patients admitted to a tertiary level trauma center with fractures of thoracolumbar spine ranging in severity from the simple to the most complex were selected. The X-ray (AP and Lateral), CT scan (sagittal, coronal and axial) and MRI (T1W, T2Wsagittal and axial) images of all the patients were selected from the picture archiving system. Four spine surgeons (two consultants and two senior spine fellow) with different grades of experience (consultant A: 15 years, consultant B: 8 years, fellow A: 3 years and fellow B: 2 years) were provided with these images in sequence i.e. first X-ray images were given then X-ray and CT scans were provided and finally X-ray, CT and MRI were shown together. All the data were tabulated on excel sheet (Fig. 1).

In step 1, the patient's clinical history, neurological status and X-ray alone were provided to the observers along with the description of the classification system and were asked to classify the fracture type, assess the posterior ligamentous complex (PLC) integrity and management plan. (Fig. 2)

The management plan was divided into conservative and surgical groups. In conservative group, treatment options provided were complete bed rest, mobilization with brace, and mobilization without brace. The surgical options were anterior surgery, posterior surgery and anterior-posterior combined approach. Posterior surgery was again divided into fusion and non-fusion group. Both groups were further divided into short segment and long segment fixation.

In step 2, the next set of images (same forty patients' clinical history, X-ray and relevant CT images) were provided. The observers were asked to classify the fracture, provide the management plan and assess PLC status based on X-ray and CT scan images. (Fig. 3)

In step 3, a new set of images with the patients' clinical history, X-ray, CT scan and MRI images were provided to the observers to assess similar parameters. (Fig. 4)

Based on the observations given by the four spine surgeons, the inter observer agreement of various classification systems, PLC status and management plan was assessed. This was performed independently for X-ray, X-ray - CT scan and with X-ray, CT scan and MRI. The usefulness of the CT scan or MRI in fracture classification, management and PLC status assessment was evaluated. Their reliability was assessed by calculating kappa values between the consultants (Table 1) and

between the fellows (Table 2). Kappa values of groups < 0.2 , $0.21-0.40$, $0.41-0.60$ and $0.61-0.80$, $0.81-1$ were considered as a poor, fair, moderate, good and very good inter-observer agreement respectively.

UNDER PEER REVIEW

RESULTS

There were forty patients (9 females and 31 males). Mean age of the patients was 41.8 years (16 - 74 years). Road traffic accident was the most common mode of injury (n=13) followed by fall from height (n=11) and others (n=16) which included a combination of trivial fall at home, manual labour accidents, athletic injuries in contact sports.

A. Classification reliability:

i. McAfee classification

The consultants had only fair agreement classifying fractures based on the McAfee classification ($k=0.3$). For X-rays alone, the agreement was 0.30. The addition of the CT scan increased the agreement to 0.35, but after adding MRI information, the kappa value again decreased to 0.28.

- Addition of the CT scan converted 20% cases of compression fracture to burst fracture. There was also a wide interchange among burst, flexion distraction and chance fracture groups among all four observers.

- Consultants had a moderate to good reliability in all the three steps of assessment while classifying wedge compression ($k=0.44$ to 0.58) and translation ($k=0.63$ to 0.69) subgroups. For unstable burst fracture, there was a good agreement ($k=0.63$) based on X-ray and CT scan but only fair agreement with X-ray ($k=0.3$) and addition of MRI ($k=0.31$). Consultants agreed poorly while classifying stable burst ($k=0.2$), flexion distraction ($k=0.1$) and chance fracture ($k=-0.1$) group.

- There was a moderate to good reliability among the fellows for McAfee's classification. Fellows had very good correlation while classifying wedge compression ($k=1$), stable burst ($k=0.54$ to 0.8), unstable burst ($k=0.45$ to 0.9) and translation ($k=0.86$ to 0.9) injury. Similar to the consultants, fellows agreed poorly in classifying chance ($k=0$ to 0.2) and flexion distraction ($k=0.2$ to 0.3) injury.

ii. TLICS classification

TLICS classification had only fair inter-observer reliability among the fellows ($k=0.3$ to 0.4) and consultants ($k=0.31$ to 0.35) on X-rays. After addition of CT scan and MRI, TLICS score changed in 27 % cases and 47.5% of the cases respectively.

- On addition of CT scan, all observers made significant changes in morphological type and PLC status except Fellow B. Changes made by the three observers in TLICS classification were 25% by consultant A, 17.5% by consultant B and 45% by fellow A.

- On addition of the MRI, Consultant A changed his scoring system in 30 %, Consultant B in 43 %, Fellow A in 48 % of cases and Fellow B in 62.5 % of cases. These changes were due to variations in PLC status with MRI for all four observers and additional variation in morphological classification for fellow B. The consultants and fellows had very good inter observer correlation on addition of MRI.

iii. AO classification

AO classification had only poor to fair reliability ($k=0.12$ for X-ray, $k=0.21$ for X-ray-CT group, $k=0.15$ for X-ray, CT & MRI group) among the consultants and the fellows.

- Similar to the McAfee classification, the simplest type A1 ($k=0.35$ to 0.5) and most severe injuries type C3 ($k=0.5$ to 0.65) had a moderate to good reliability as compared to other sub groups which had only poor to fair reliability among the consultants. Among the fellows too, type A1 ($k=0.4$ to 0.8) and C3 ($k=0.3$ to 0.35) had a fair to good correlation but other subgroups had only poor to fair reliability.

- On addition of CT, Consultant A made changes in 17.5 % of cases, consultant B 25%, Fellow A 32.5% & Fellow B 25%, cases. Most of the changes happened in the major subgroup (among A, B and C).

AO classification is least changed after adding MRI among consultant A, consultant B and fellow A. For Fellow B it was changed in 20 % of cases.

B. PLC status

- On X-ray alone, Consultants had only fair inter-observer reliability to diagnose PLC status ($k=0.4$).

- On addition of CT scan, inter-observer reliability was good ($k= 0.51$). Consultants changed their PLC status comment in 7.5 % of case and Fellows in 6.25% cases.

- On addition of the MRI, surprisingly the inter-observer reliability increased ($k=0.92$).

Consultant A noted PLC injury and changed his decision in 30% of the cases while Consultant B has changed his decision in 43 % of cases, Fellow A in 48% and Fellow B in 62% of the cases.

Fellows had moderate inter observer reliability for detecting PLC status injury with X-rays alone ($K=0.65$). This did not change after providing CT along with X-rays ($k=0.71$). Again, paradoxically the agreement increased when MRI was also provided to assess the PLC integrity ($K=0.95$).

C. Management:

- On X-ray alone the Consultants had poor to fair agreement in terms of treatment options.

- On addition of CT scan, the management was changed 10% of cases. For Consultant A, 2 patients (5%) had moved to surgical management from conservative group. For Consultant B, 4 patients (10%) had shifted to surgical from conservative and 2 patients (5%) were converted into conservative management from surgical management. For Fellow A, 3 patients (7.5%) were converted to surgical from conservative care and (5%) patients to conservative from surgical management. For Fellow B, management remained the same.

- On addition of MRI, management was altered for all the four observers, who changed their management plan in 47.5 % of cases. Out of 19 cases in which management is changed, 14 cases (35%) were converted from conservative to surgical groups and in other 5 cases (12.5%) a different modality of same conservative or surgical treatment was selected.

Summarizing the changes in management decisions with CT and MRI scan, for Fellow B, after addition of the CT scan, only McAfee and AO classification has changed in 15 and 10 cases respectively. Otherwise there was a no difference for PLC status, TLICS and management. But after addition of the MRI he has changed his decision in 6, 9 & 8 cases for McAfee, TLICS & AO classification respectively and management in 7 cases.

For Consultant A, PLC status was changed in 15(37%) cases after MRI evaluation. Eight cases without displaced fracture were converted from injured to intact group and 7 cases with displaced fracture fragments were converted from intact to injured group.

Except for Fellow B, all other observers feel that MRI is not adding any additional information after having an X-ray and CT scan details. PLC was intact in all undisplaced fractures. In less than 10% cases they had changed their classification grade. Except for Fellow B, nobody had changed their management after seeing MRI.

Most commonly performed surgery was spanning Pedicle screw-rod fixation of adjoining intact vertebra in cases with confirmed PLC injury which had undisplaced and mildly displaced fractures without neurological deficit. Decompression and TLIF (Transforaminal Lumbar Interbody Fusion) with cage fixation was done in cases with moderate to severe displacement. Conservative management was done in all PLC intact cases without neurological deficit.

DISCUSSION

Management of the thoracolumbar fracture depends on proper classification of the injury as stable or unstable. Even though fracture classification has evolved significantly in the last 20 years, the original morphological classification of Böhler still seems adequate in modern scenario. More sophisticated attempts at improving the fracture classification adds to complexity and confusion.⁷ Presently with advent of modern technology, CT and MRI scan are frequently performed in the evaluation of the fracture spine. The present study indicates that there is only poor to fair reliability among the observers for the TLICS and AO classification. Similar to previous studies, simple and complex injuries are classified reliably while the injuries that fall into middle grade are still not reliably classified.⁸

The study also has evaluated the additive role of the CT scan and the fracture classification and management. Plain radiographs are the initial imaging modality for **screening** of the thoracolumbar fractures. But plain films have been shown to be inferior to CT with respect to fracture detection in a number of studies.⁹⁻¹¹ Brown et al.,¹² Hauser et al.,¹³ and Sheridan et al.,¹⁴ have performed similar analyses comparing plain radiography and CT in trauma of the thoracolumbar spine. Combined sensitivities for detection of injury are 67% for plain film when compared with 98% for spiral CT. Unlike CT, the accuracy of conventional radiographs decreases with select patient characteristics, in particular high-risk mechanism of injury and advanced age^{15,16}.

In our study, with addition of the CT scan to X-ray, there were approximately 25% changes in classifying the fractures according to McAfee, TLICS and AO classification system. **CT scan provides more information as compared to X-ray alone in fracture detection, outlining morphology of fracture, pre-operative planning and indirectly determine PLC tear by the presence of displacement of the fragments into the spinal canal. In case of displaced fractures without neurological deficit, MRI may not be necessary presuming obvious PLC injury and taking the decision to operate with instrumentation and fusion. In cases of undisplaced fractures and clinically suspected PLC or spinal cord injury MRI can be done as an additional confirmatory investigation.**

After addition of CT scan to the X-ray, in 10 % of cases, the management plan had been changed. Except for fellow B, every observer had some more information from CT scan to change their decision. While CT is central to treatment planning, intraoperative reductions and fixations are usually controlled with fluoroscopy or conventional radiographs, and most operative follow-up imaging relies on conventional radiography. Therefore, it is advisable to include conventional radiograph along with CT scan. Although imaging costs are much greater for CT than for conventional radiography, CT screening of the cervical & thoracolumbar spine is cost effective and cost-dominant especially in victims of blunt-force trauma.¹⁴ An interesting observation from our study is that all the four observers did not vary significantly while changing their subgroup of the AO classification based on the CT scan.

The role of magnetic resonance imaging (MRI) in acute spinal trauma is to evaluate neurological symptoms, spinal cord injury and suspected ligamentous disruption.^{17, 18} MRI can also offer prognostic information regarding potential recovery post spinal cord injury.¹⁹ Imaging factors associated with poor functional recovery are hemorrhage, long segments of edema, and high cervical location of injury.

However as documented in a study by Holmes et al., for the NEXUS group, the low fracture detection rate of 8.5/15 fractures (55%) suggest MRI is not an appropriate screening modality for detection of pattern of fractures.²⁰ Although MRI adds phenomenally to the cost of the treatment, it provides significant information regarding spinal cord compression and also aids in diagnosis of PLC injury, which is the cornerstone in preventing long term complications, spinal instability and in acute management of neurological symptoms.

In our study, all observers found more information with regard to PLC injury and spinal cord compression and to change their classification or management plan after having an MRI in addition to X-ray & CT scan.²¹ McAfee and AO classification did not show significant change but TLICS classification showed considerable change after addition of MRI to CT scan. **In displaced fractures without neurological deficit, MRI showed torn PLC and hence the management did not change in**

such injuries and surgical management was confirmed. This further adds evidence that MRI may not be necessary in such displaced fractures without neurological deficit as we can presume the presence PLC injury.

PLC injury is given a significant importance in TLICS classification. According to the classification, confirmed complete PLC disruption has been given three points which is equivalent to rotational injury or incomplete cord injury. So, the status of PLC influences long term prognosis and also the treatment plan. All observers found considerable difference after having MRI in addition to CT scan & X-ray. Literature suggests that MRI appearance of the posterior ligamentous structures cannot be used in isolation for decision making.²² Rather, the MRI appearance of the PLC components should be considered along with associated findings (i.e., epidural hematoma, superficial soft tissue edema), plain film or CT findings, and clinical suspicion and findings consistent with ligamentous injury. However, the sensitivity of MRI is clearly higher than its specificity for PLC status while the pattern of fracture is more evident on CT.²³ So MRI is usually complementary to CT rather than a substitute.⁶ MRI mainly helps in diagnosis of injury to spinal cord and PLC, and the need for surgical decompression and fixation, while CT scan helps in classifying the pattern of fracture and aids in the planning of the surgical process.

Most commonly performed surgery was spanning Pedicle screw-rod fixation of adjoining intact vertebra in cases with confirmed PLC injury which had undisplaced and mildly displaced fractures without neurological deficit. Decompression and TLIF (Transforaminal Lumbar Interbody Fusion) with cage fixation was done in cases with moderate to severe displacement. Conservative management was done in all PLC intact cases without neurological deficit.

CONCLUSION

The study indicates that among the three commonly used classifications, TLICS classification has relatively better inter-observer reliability than McAfee and AO classification. In all classifications, the agreement was better for the simple and complex fractures with poor correlation for the “in-between” fracture groups.

X-rays are helpful in initial evaluation of thoracolumbar spine fractures and their postsurgical prognosis. CT scan provides additional information like fracture pattern, fracture morphology and indirectly determine PLC tear by the presence of displacement of the fragments into the spinal canal. In displaced fractures with or without neurological deficit, MRI may be omitted and surgery can be done directly. MRI confirms spinal cord compression and PLC injury. Hence, Xray, CT Scan and MRI are investigations of choice in that serial order in making decision regarding their management.

Consent

As per international standards or university standards, patient(s) written consent has been collected and preserved by the author(s).

Disclaimer (Artificial intelligence)

Author(s) hereby declares that NO generative AI technologies such as Large Language Models (ChatGPT, COPILOT, etc.) and text-to-image generators have been used during the writing or editing of this manuscript.

UNDER PEER REVIEW

REFERENCES:

1. Checiu G, Filip C, Serban D, et al. Thoracic spine type C injuries: injury profile, management and outcome. *Romanian Neurosurgery*. 12/30 2014;21.
2. Almidad A, Alazaydeh S, Mustafa MB, Alshawish M, Abdallat AA. Thoracolumbar spine fracture patterns, etiologies, and treatment modalities in Jordan. *J Trauma Inj*. 2023 Jun;36(2):98-104. doi: 10.20408/jti.2022.0068. Epub 2023 Apr 14. PMID: 39380694; PMCID: PMC11309452.
3. Diaz JJ, Cullinane DC, Altman DT, et al. Practice management guidelines for the screening of thoracolumbar spine fracture. *J Trauma*. 2007/09// 2007;63(3):709-718.
4. Hussain O, Kaushal M, Agarwal N, Kurpad S, Shabani S. The Role of Magnetic Resonance Imaging and Computed Tomography in Spinal Cord Injury. *Life (Basel)*. 2023 Aug 3;13(8):1680. doi: 10.3390/life13081680. PMID: 37629537; PMCID: PMC10455833.
5. Imaging of Thoracic and Lumbar Spine Fractures; Mark W. Anderson, MD *Semin Spine Surg* 22:8-19 . 2010 Published by Elsevier Inc.
6. Rothman & Someone's The Spine Texbook, sixth edition; chapter XII spinal trauma, volume 1, page no1366.
7. Burstein AH. Fracture classification systems: do they work and are they useful? *J Bone Joint Surg Am*. 1993/12// 1993;75(12):1743-1744.
8. Filgueira ÉG, Imoto AM, da Silva HEC, Meves R. Thoracolumbar Burst Fracture: McCormack Load-sharing Classification: Systematic Review and Single-arm Meta-analysis. *Spine (Phila Pa 1976)*. 2021 May 1;46(9):E542-E550. doi: 10.1097/BRS.0000000000003826. PMID: 33273433.
9. Tins BJ. Imaging investigations in Spine Trauma: The value of commonly used imaging modalities and emerging imaging modalities. *J Clin Orthop Trauma*. 2017 Apr-Jun;8(2):107-115. doi: 10.1016/j.jcot.2017.06.012. Epub 2017 Jun 13. PMID: 28720986; PMCID: PMC5498756.

10. Coats AC, Nies MS, Rispler D. Cervical spine computed tomography imaging artifact affecting clinical decision-making in the traumatized patient. *Open Orthop J*. 2014 Oct 17;8:372-4. doi: 10.2174/1874325001408010372. PMID: 25352931; PMCID: PMC4209502.
11. Berritto D, Pinto A, Michelin P, Demondion X, Badr S. Trauma Imaging of the Acute Cervical Spine. *Semin Musculoskelet Radiol*. 2017 Jul;21(3):184-198. doi: 10.1055/s-0037-1602713. Epub 2017 Jun 1. PMID: 28571084.
12. Brown CVR, Antevil JL, Sise MJ, Sack DI. Spiral computed tomography for the diagnosis of cervical, thoracic, and lumbar spine fractures: its time has come. *J Trauma*. 2005/05// 2005;58(5):890-895; discussion 895-896.
13. Patel, S.H., Moore, T.A. Motion artifact on computed tomography scan suggesting an unstable 3-column spine injury: case report of a "near miss" root cause of unneeded surgery. *Patient Saf Surg* 7, 35 (2013). <https://doi.org/10.1186/1754-9493-7-35>
14. Expert Panel on Neurological Imaging and Musculoskeletal Imaging; Beckmann NM, West OC, Nunez D Jr, Kirsch CFE, Aulino JM, Broder JS, Cassidy RC, Czuczman GJ, Demertzis JL, Johnson MM, Motamedi K, Reitman C, Shah LM, Than K, Ying-Kou Yung E, Beaman FD, Kransdorf MJ, Bykowski J. ACR Appropriateness Criteria® Suspected Spine Trauma. *J Am Coll Radiol*. 2019 May;16(5S):S264-S285. doi: 10.1016/j.jacr.2019.02.002. PMID: 31054754.
15. Lu Y, Heller DN, Zhao S. Receiver operating characteristic (ROC) analysis for diagnostic examinations with uninterpretable cases. *Stat Med*. 2002/07/15/ 2002;21(13):1849-1865.
16. Yokogawa, N., Kato, S., Sasagawa, T. et al. Differences in clinical characteristics of cervical spine injuries in older adults by external causes: a multicenter study of 1512 cases. *Sci Rep* 12, 15867 (2022). <https://doi.org/10.1038/s41598-022-19789-y>.
17. Kumar Y, Hayashi D. Role of magnetic resonance imaging in acute spinal trauma: a pictorial review. *BMC Musculoskelet Disord*. 2016 Jul 22;17:310. doi: 10.1186/s12891-016-1169-6. PMID: 27448661; PMCID: PMC4957861.

18. Harris MB, Reitman CA. Spinal trauma-initial evaluation and imaging. In: Reitman CA, ed. Management of Thoracolumbar Fractures. Rosemont: American Academy of Orthopaedic Surgeons, 2004:27-34.
19. Heather Kate Moriarty, Roisin O Cearbhaill, Peter D Moriarty, Emma Stanley, Leo P Lawler, Eoin C Kavanagh, MR imaging of spinal haematoma: a pictorial review, British Journal of Radiology, Volume 92, Issue 1095, 1 March 2019, 20180532.
20. Schoenfeld AJ, Bono CM, McGuire KJ, Warholc N, Harris MB. Computed tomography alone versus computed tomography and magnetic resonance imaging in the identification of occult injuries to the cervical spine: a meta-analysis. J Trauma. 2010 Jan;68(1):109-13; discussion 113-4. doi: 10.1097/TA.0b013e3181c0b67a. PMID: 20065765.
21. Gharekhanloo, F., Gharekhanloo, M., Golmohammadi, H., Jalili, E., Pirdehghan, A. Accuracy of plain radiography in cervical spine injury. Archives of Trauma Research, 2021; 10(2): 80-85.
22. Lee GY, Lee JW, Choi SW, Lim HJ, Sun HY, Kang Y, Chai JW, Kim S, Kang HS. MRI Inter-Reader and Intra-Reader Reliabilities for Assessing Injury Morphology and Posterior Ligamentous Complex Integrity of the Spine According to the Thoracolumbar Injury Classification System and Severity Score. Korean J Radiol. 2015 Jul-Aug;16(4):889-898. <https://doi.org/10.3348/kjr.2015.16.4.889>
23. Smith HE, Rihn JA, Radcliff KE, Vaccaro AR. Imaging in the Setting of Thoracolumbar Trauma: The Use of Magnetic Resonance Imaging to Diagnose Injury to the Posterior Ligamentous Complex. *Seminars in Spine Surgery*. 2012/12/01/ 2012;24(4):216-220.

Figure 1 – Flow chart showing the investigations made available to the observers at each step.

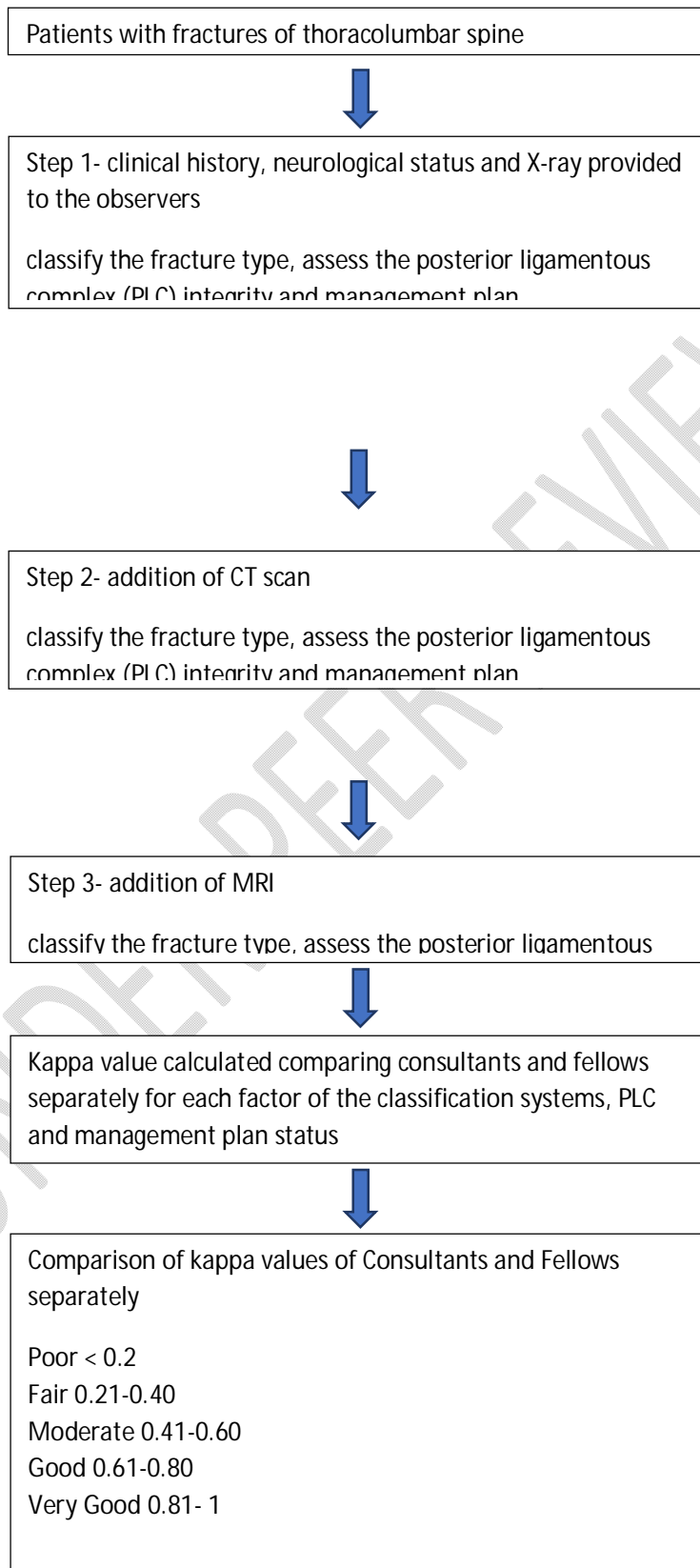


Figure 2 – 63 year old male with history of road traffic accident, presented with back pain and chest pain. On examination neurology was ASIA E status & associated distal radius and diaphragmatic hernia. After looking at the x ray, the observers noted their inference. Consultant A, fellow A and B - unstable burst, consultant B- chance fracture. PLC status- consultant A-injured, consultant B and fellow A and B- intact.

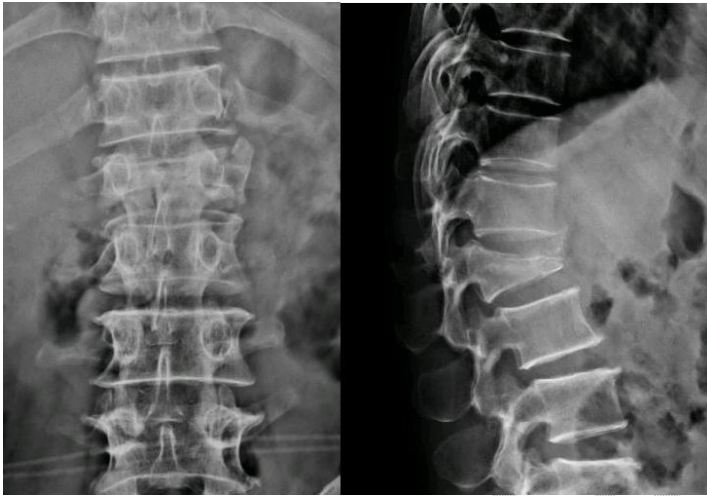


Figure 3 - CT scan of the same patient. Consultant A- unstable burst, consultant B – chance, fellow A & B – flexion distraction injury. PLC status- consultant A and B, fellow A and B – injured

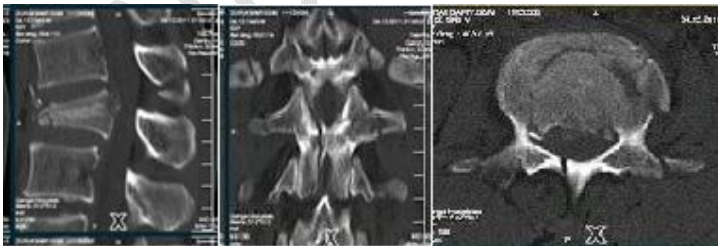

Figure 4 - MRI of the same patient. PLC status - injured for all observers. Morphological classification is as of CT scan

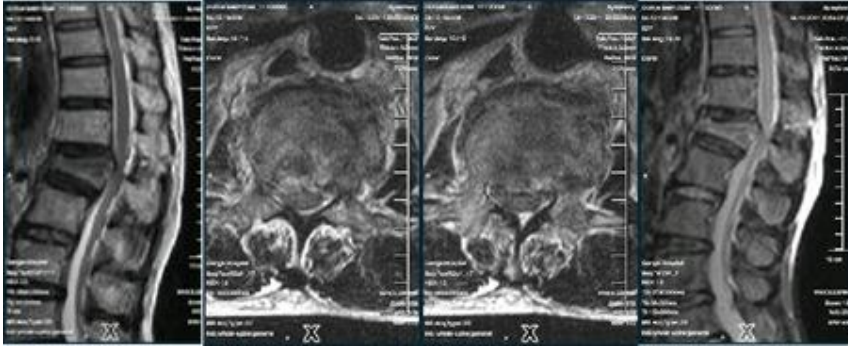


Table 1 – Kappa values of different variables for consultants.

Variables for consultants A & B	Kappa value for X ray	Kappa value for X ray & CT scan	Kappa value for X ray, CT & MRI
PLC status	Fair	Good	Very Good
McAfee wedge compression	Moderate	Moderate	Moderate
McAfee stable burst	Fair	Fair	Poor
McAfee unstable burst	Fair	Good	Fair
McAfee chance	Poor	Poor	Poor
McAfee flexion distraction	Poor	Poor	Poor
McAfee translation	Good	Good	Good
TLICS total score	Fair	Moderate	Very Good
AO spine classification compression impaction	Fair	Moderate	Moderate

AO spine classification compression split	*	*	*
AO spine classification compression burst	Poor	Fair	Fair
AO spine classification ant + post + distraction post-ligamentous	Poor	Poor	Poor
AO spine classification ant + post + distraction post-osseous	Poor	Poor	Poor
AO spine classification ant + post + distraction ant-hyper extension	*	*	*
AO spine classification ant + post + rotation type A + rotation	Poor	Poor	Poor
AO spine classification ant + post + rotation type B + rotation	Poor	Fair	Fair
AO spine classification ant + post + rotation shear injury	Moderate	Good	Good
Treatment plan conservative mobilization with brace	Moderate	Fair	Good
Treatment plan conservative no brace , no bed rest	Poor	Poor	Good
Posterior surgery fixation only short segment	Fair	Fair	Very Good
Posterior surgery fixation only long segment	Poor	Poor	Good

Posterior surgery fixation & fusion long segment	Poor	Poor	Very Good
--	------	------	-----------

Table 2 – Kappa value of different variables for fellows.

Variables for Fellow A & B	Kappa value for X ray	Kappa value for X ray& CT	Kappa value for X ray, CT & MRI
PLC status	Moderate	Moderate	Very Good
McAfee wedge compression	Very good	Moderate	Good
McAfee stable burst	Moderate	Moderate	Moderate
McAfee unstable burst	Moderate	Good	Very Good
McAfee chance	Poor	Poor	Fair
McAfee flexion distraction	Fair	Fair	Fair
McAfee translation	Very good	Very good	Very good
TLICS total score	Moderate	Fair	Very Good
AO spine classification compression impaction	Very good	Moderate	Moderate
AO spine classification compression split	Poor	Poor	Poor
AO spine classification compression burst	Good	Fair	Moderate
AO spine classification ant + post + distraction post-ligamentous	Poor	Poor	Poor
AO spine classification ant + post + distraction post-osseous	Poor	Fair	Fair
AO spine classification ant + post + distraction ant-hyper extension	Poor	Poor	Poor
AO spine classification ant + post + rotation type A + rotation	Poor	Poor	Poor

AO spine classification ant + post + rotation type B + rotation	Fair	Moderate	Moderate
AO spine classification ant + post + rotation shear injury	Fair	Fair	Fair
Treatment plan conservative mobilization with brace	Moderate	Moderate	Good
treatment plan conservative no brace , no bed rest	Poor	Poor	Good
Posterior surgery fixation only short segment	Fair	Fair	Very Good
Posterior surgery fixation only long segment	Moderate	Moderate	Good
Posterior surgery fixation & fusion long segment	Poor	Poor	Very Good

UNDER PEER REVIEW