

## Mirroring Mystery: Bilateral Spontaneous Perinephric Urinoma Unveiled

### ABSTRACT

**Background:** Urinomas are accumulations of urine located in the retroperitoneal area, most frequently in the perirenal space. These collections typically result from leakage within the urinary tract, often due to obstruction, trauma, or post-procedural instrumentation. Bilateral spontaneous urinomas without an underlying cause are extremely uncommon. **Case Presentation:** An 18-year-old male presented with left flank pain and episodes of vomiting but without any history of trauma, surgery, or significant comorbidities. Clinical examination was unremarkable, and laboratory investigations, including urine analysis and culture, were normal. Ultrasonography of the abdomen revealed bilateral heterogeneous subcapsular collections, which were further characterized on contrast-enhanced computed tomography (CT) as mild-to-moderate subcapsular fluid collections with debris and hemorrhagic foci. Fluid analysis from the aspirated collections showed normal findings, with no evidence of infection. A diagnosis of bilateral spontaneous perinephric urinoma was established, and the patient was successfully managed conservatively. **Discussion:** This case highlights the rarity of bilateral spontaneous perinephric urinomas in patients without typical risk factors, emphasizing the diagnostic value of imaging in such unusual presentations. Conservative management was effective in resolving the urinomas, supporting a non-invasive approach in cases without infection or obstruction. This report contributes to the limited knowledge on spontaneous urinomas and underscores the importance of individualized treatment planning. **Conclusion:** This case underscores the importance of imaging in diagnosing rare presentations of perinephric urinoma, especially in patients without obvious risk factors. It highlights that conservative management can be effective in cases without infection or obstruction, offering a safe alternative to surgical intervention.

**Keywords:** Spontaneous urinoma, perinephric collection, conservative management, renal imaging, bilateral urinoma

### INTRODUCTION

Urinoma is a rare pathological condition characterized by the extravasation of urine around the kidney due to a disruption in the urinary collecting system, which can occur anywhere from the calyx to the urethra.[1,2] This pathology can manifest in various locations, including the perirenal and retroperitoneal spaces, peritoneal cavity, pleural cavity, and even the mediastinum.[3] Urinomas are typically associated with obstructive uropathy, trauma, or surgical interventions [4] Most commonly, renal urine leaks result from blunt or penetrating renal trauma.[4] They may accompany any form of renal trauma, ranging from a simple renal laceration to a renal vascular pedicle injury.[4] However, spontaneous urinomas, particularly in the absence of identifiable risk factors such as trauma or surgical history, are exceedingly rare.[5]

Spontaneous perinephric urinoma presents a diagnostic challenge due to its nonspecific clinical manifestations. Symptoms often include flank pain and nausea, which can be mistaken for other renal pathologies.[6] In patients without predisposing factors, diagnosis relies heavily on imaging studies, where ultrasound and contrast-enhanced computed tomography

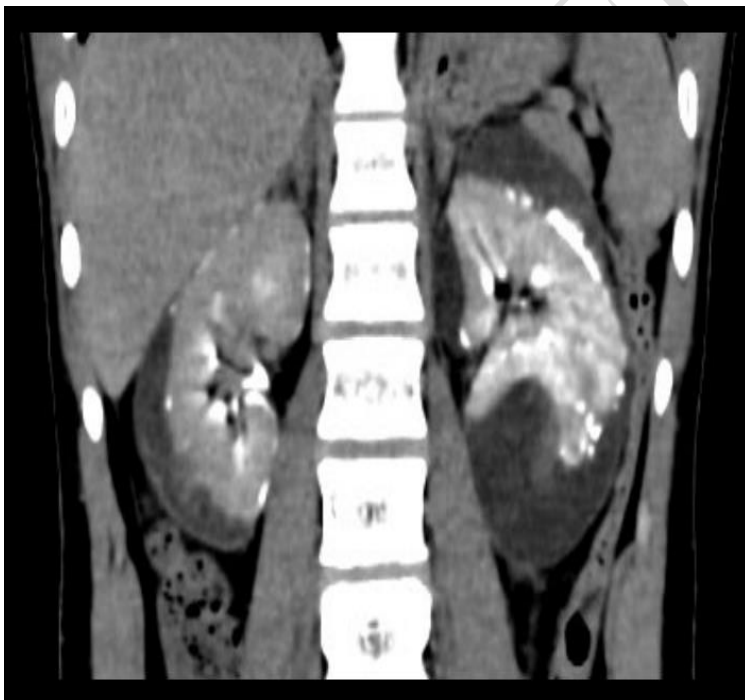
(CT) play a crucial role in identifying perinephric collections and assessing their nature.[4,7] In this report, we present the rare case of an 18-year-old male with bilateral spontaneous perinephric urinoma in the absence of any apparent precipitating factors, highlighting the diagnostic process and successful conservative management approach.

## CASE PRESENTATION

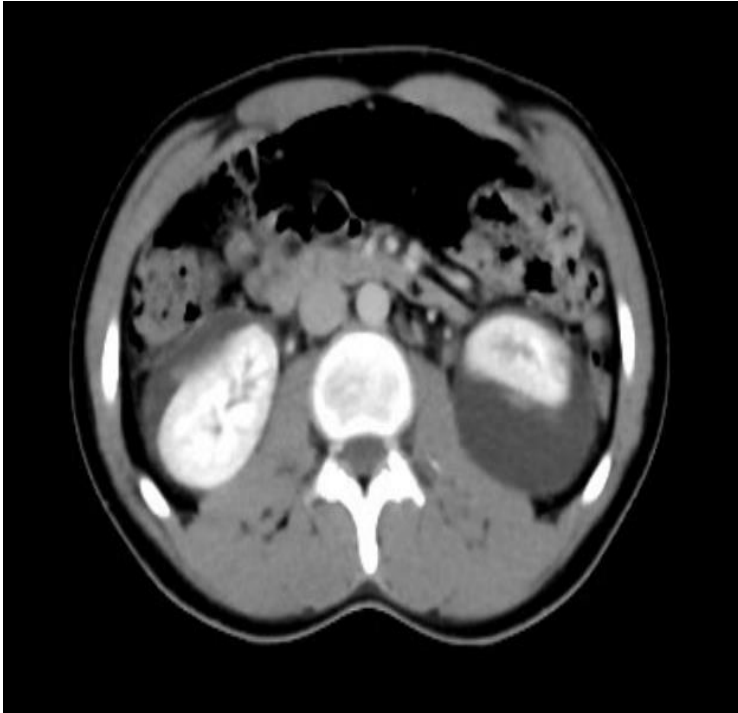
An 18-year-old male presented to the nephrology outpatient department with complaints of pain in the left flank region persisting for the past 3-4 days, accompanied by a few episodes of vomiting. There was no history of fever, strenuous exercise, trauma, previous abdominal surgery, or significant medical comorbidities.

On clinical examination, the patient was found to be normotensive with all systemic examination findings within normal limits. Routine laboratory investigations, including complete blood count, renal function tests, and serum electrolytes revealed results within the normal range. Urine analysis showed no abnormalities and urine culture was negative for bacterial growth, further ruling out infection as an underlying cause.

Given the patient's persistent symptoms and absence of systemic findings, imaging studies were conducted. Ultrasonography of the abdomen demonstrated bilateral heterogenous subcapsular collections measuring 2.8cm on the right side and 3.5cm on the left side. For a more detailed evaluation, a contrast-enhanced CT of the abdomen was performed, which demonstrated bilateral mild to moderate renal subcapsular collections with debris and haemorrhagic foci, suggesting a complex perinephric fluid collection (Figure 1 and 2).



**Figure 1: Contrast-enhanced computed tomography Coronal view showing urinoma**



**Figure 2: Contrast-enhanced computed tomography Axial view showing perinephric collection**

To further assess the nature of the fluid, aspiration was performed under ultrasound guidance. The aspirated fluid analysis showed a normal biochemical profile (fluid creatinine 4 mg/dL), with triglyceride levels within the normal range (<10 mg/dL). Microbiological tests, including Gram staining, acid-fast staining, and culture, showed no evidence of bacterial or mycobacterial infection.

Based on the clinical, laboratory, and imaging findings, the diagnosis of bilateral spontaneous perinephric urinoma was established. The patient was managed conservatively, with close monitoring of renal function and fluid intake. After initiating conservative management, the patient's clinical condition improved significantly, with preservation of renal function and normal urine output [21].

## DISCUSSION

Spontaneous perinephric urinoma is a rare clinical condition, typically resulting from leakage in the urinary tract due to factors such as obstruction, trauma, or post-procedural instrumentation [8]. The presentation of bilateral perinephric urinoma in the absence of any precipitating cause, as seen in this case, is exceptionally uncommon. Urinoma is characterised by encapsulated collection of extravasated urine in the perirenal space.[9,10] Urinomas in children are usually secondary to obstructive uropathies, such as posterior urethral valve, pelviureteric junction, or vesico-ureteric junction obstruction, ureteric calculus, or trauma.[11-14]

Several hypotheses have been proposed for mechanism of urinoma the most convincing is that whenever intrapelvic pressure rises to 35 to 40 cm H<sub>2</sub>O or greater, pyelosinus backflow occurs, leading to rupture of caliceal fornices [15,16]. Urinomas thus act as a pop-off mechanism to decompress the high-pressure system, protecting the kidney from further

injury. Extravasated urine can collect either extra-peritoneally, intraperitoneally, or in both locations.[15] Extraperitoneal collections are of two types, sub- capsular and perirenal. Subcapsular urinomas are situated between the renal parenchyma and renal capsule, whereas perirenal urinomas (also referred to as uriniferous perirenal pseudocyst) are located between the renal capsule and Gerota's fascia.[15]

Urine leaks and urinomas have a variety of appearances and may be misdiagnosed as ordinary ascites, abdominal or pelvic abscesses or hematomas, cystic masses, or pancreatic pseudocysts.[17] Diagnostic imaging plays a crucial role in promptly identifying these leaks and determining their cause and extent.[4] In this case, the lack of known risk factors, including trauma or recent surgery, along with normal laboratory findings, highlights the importance of imaging in identifying and managing spontaneous perinephric urinoma. Ultrasonography and contrast-enhanced CT are essential tools in diagnosing urinomas, as they can reveal the presence, extent, and characteristics of perinephric collections. The imaging findings in this case, including bilateral subcapsular collections with areas of haemorrhagic debris, suggested a non-infectious etiology. The normal results from fluid analysis, including the absence of bacteria or mycobacteria on cultures, further supported a diagnosis of spontaneous urinoma without an infectious or obstructive cause.

Voiding cystourethrography is mandatory in these cases to exclude posterior urethral valve obstruction and vesicoureteral reflux.[18] The spine should be evaluated for neurogenic bladder. Technetium-99m DTPA is useful in providing functional as well as anatomic details in these patients.[19] Urinomas initially display decreased activity but fill in the delayed scans, thereby documenting continuity between the collecting system and the urinoma. Urodynamics is required in occasional cases.[19] In spontaneous urinomas, voiding histories should be clearly elicited, and detailed urodynamic evaluation should be done, otherwise urinomas can recur.

Management of perinephric urinomas often depends on the underlying etiology, the size of the collection, and the presence of symptoms. Effective treatment of urinoma involves timely diagnosis and identification of the underlying cause. In most cases, urinomas resolve on their own once the obstruction is addressed. In most instances, small urinomas will reabsorb spontaneously, and drainage is not necessary.[9] However, if urinomas are larger or persist over several days, or if the patient develops fevers or sepsis irrespective of urinoma size, imaging guided drainage is clinically warranted.[4] Therapeutic tap can be performed under ultrasonography guidance, along with placement of pigtail catheters in the most dependent point of the urinoma. While large or infected urinomas may require drainage, conservative management with close monitoring is often effective for small, collections, as observed in this case. At the time of writing this case report, the patient was treated with a short course of oral antibiotics and supportive medications. He was monitored regularly through follow-up visits and showed a good recovery. The patient's improvement with conservative treatment aligns with reports indicating that spontaneous urinomas without infection or obstruction may resolve without invasive intervention.[5]

Spontaneous perinephric urinomas are rarely documented in the literature. Kennelly and Ritchey reported a case of spontaneous perinephric urinoma due to elevated intravesical storage pressure in a girl with myelodysplasia.[20] Our rare case of perinephric urinoma adds to the limited literature on bilateral spontaneous perinephric urinomas, underscoring the role of advanced imaging in diagnosing such rare presentations and highlighting the potential for successful conservative management in cases without infectious or obstructive complications.

Further studies are needed to understand the pathophysiology underlying spontaneous urinoma formation in patients without typical risk factors.

### **PATIENT PERSPECTIVE**

The patient expressed considerable relief upon receiving a definitive diagnosis after experiencing persistent flank pain. He particularly appreciated the non-invasive approach to diagnosis through ultrasound and contrast-enhanced CT, which provided clarity without causing discomfort. The conservative management strategy was also reassuring to him, as it eliminated the need for surgical intervention, a significant source of anxiety for him. Additionally, the cost-effective nature of the treatment plan was valued by both the patient and his family, who found comfort in knowing that his condition could be managed effectively with minimal physical and financial burden.

### **CONCLUSION**

This case highlights the rare occurrence of bilateral spontaneous perinephric urinoma in a young patient without any identifiable precipitating factors. It underscores the importance of imaging studies, such as ultrasound and CT, in diagnosing perinephric collections when laboratory findings are unremarkable. Conservative management proved effective in this case, leading to the patient's complete recovery without the need for invasive intervention. This case contributes to the limited literature on spontaneous urinomas and reinforces that, in the absence of infection or obstruction, a non-surgical approach can be both safe and effective.

### **ACKNOWLEDGEMENTS**

Authors would like to acknowledge Dr Shahu Ingole from 'Science Plus' for support in data analysis, manuscript review and editing.

### **COMPETING INTERESTS**

Authors have declared that no competing interests exist.

### **AUTHORS' CONTRIBUTIONS**

- Dr Sunil Dharmani: Served as the primary investigator and was directly involved in the clinical management of the patient, including diagnosis, treatment, and follow-up. He also took the lead in drafting and revising the manuscript.
- Dr Varun Sharma: Provided expertise in imaging interpretation and analysis. He contributed to the conception and design of the study, involved in the clinical management of the patient. He also provided critical insights during the manuscript revision process.

- Dr. Pranita Dharmani: Assisted in data collection and analysis, and contributed to the interpretation of clinical findings. She played a key role in reviewing and refining the manuscript to enhance its quality and accuracy.
- Dr. Amit Turkar: He contributed to the preparation of imaging figures, conducted the literature review, and assisted in drafting the manuscript. and offered critical feedback during the manuscript preparation and review stages.

All authors have read and approved the final version of the manuscript and agree to be accountable for all aspects of the work.

## CONSENT

All authors declare that written informed consent was obtained from the patient for the publication of this case report and accompanying images. The patient was informed that all identifiable information would be excluded to maintain confidentiality, and patient consented to the use of his clinical information for academic and research purposes.

## ETHICAL APPROVAL

Ethical approval was not required for this case report, as it is a single case study involving de-identified patient data with no experimental intervention. All clinical procedures adhered to standard care protocols.

### Disclaimer (Artificial intelligence)

#### Option 1:

Author(s) hereby declare that NO generative AI technologies such as Large Language Models (ChatGPT, COPILOT, etc.) and text-to-image generators have been used during the writing or editing of this manuscript.

#### Option 2:

Author(s) hereby declare that generative AI technologies such as Large Language Models, etc. have been used during the writing or editing of manuscripts. This explanation will include the name, version, model, and source of the generative AI technology and as well as all input prompts provided to the generative AI technology

Details of the AI usage are given below:

1.

2.

## REFERENCES

1. Phillips B, Holzmer S, Turco L, Mirzaie M, Mause E, Mause A, et al. Trauma to the bladder and ureter: a review of diagnosis, management, and prognosis. *Eur J Trauma Emerg Surg.* 2017;43(6):763-773. doi: 10.1007/s00068-017-0817-3.
2. McGeady JB, Breyer BN. Current epidemiology of genitourinary trauma. *Urol Clin North Am.* 2013;40(3):323-34. doi: 10.1016/j.ucl.2013.04.001.
3. Puri A, Bajpai M, Gupta AK. Bilateral spontaneous perinephric urinomas: case report and review of the literature. *Urology.* 2004;64(3):590-1. doi: 10.1016/j.urology.2004.04.057.
4. Tilton RL, Gervais DA, Hahn PF, Harisinghani MG, Arellano RS, Mueller PR. Urine Leaks and Urinomas: Diagnosis and Imaging-guided Intervention. *RadioGraphics.* 2003;23(5):1133–1147. doi:10.1148/rg.235035029
5. Finnegan PS, Proctor T, Pennington B. Spontaneous Urinoma Without Trauma or Obstruction in a 64-Year-Old Female. *Cureus.* 2020;12(7):e9241. doi: 10.7759/cureus.9241
6. Kajić M, Boras M, Tipurić M, Šutalo N, Bevanda D, Mišković J. Spontaneous Urinoma Surgeon's Pitfall - Case Report. *Psychiatr Danub.* 2021;33(Suppl 13):327-329.
7. Moradkhani A, Zangi M, Azami M, Ghasemi-Rad M, Pakniyat A. The role of point-of-care ultrasound in the assessment of pelvic urine leakage and diagnosis of urinoma. *Int J Emerg Med.* 2023;16(1):91. doi: 10.1186/s12245-023-00571-4.
8. Goldwasser J, Wahdat R, Espinosa J, Lucerna A. Urinoma: Prompt Diagnosis and Treatment Can Prevent Abscess Formation, Hydronephrosis, and a Progressive Loss of Renal Function. *Case Rep Emerg Med.* 2018;2018:5456738. doi: 10.1155/2018/5456738.
9. Lang EK, Glorioso L. Management of urinomas by percutaneous drainage procedures. *Radiol Clin North Am.* 1986;24:551–559.
10. McInerney D, Jones A, Royslance J. Urinoma. *Clin Radiol.* 1977;28:345–351. doi: 10.1016/s0009-9260(77)80195-5.
11. Krane RJ, Retik AB. Neonatal perirenal urinary extravasation. *J Urol.* 1974;111(1): 96 – 99. doi: 10.1016/s0022-5347(17)59898-5.
12. Morgan CL, Grossman H. Posterior urethral valves as a cause of neonatal uriniferous perirenal pseudocyst. *Pediatr Radiol.* 1978;7(1):29-32. doi: 10.1007/BF00975334.
13. Paulter EE, Garvey FK. Perinephric cyst: report of case associated with ureteropelvic occlusion and congenital hydronephrosis. *J Urol.* 1953;70(6):840-845. doi: 10.1016/S0022-5347(17)67993-X.

14. Kirchner SG, Braren V, Heller RM, Kirchner FK Jr. Uriniferous perirenal pseudocyst: an unusual cause of calcified abdominal mass in neonate. *Pediatr Radiol.* 1980;9(1):43–44. doi: 10.1007/BF00973970.
15. Macpherson RI, Gordon L, Bradford BF. Neonatal urinomas: imaging considerations. *Pediatr Radiol.* 1984;14:396–399. doi: 10.1007/BF02343427.
16. Reinberg Y, Fleming T, Gonzalez R. Renal rupture after the Crede maneuver. *J Pediatr.* 1994;124(2):279–281. doi: 10.1016/s0022-3476(94)70320-5.
17. Sorgman JA, Langevin E, Banks PA. Urinoma masquerading as pancreatic pseudocyst. *Int J Pancreatol.* 1992 Jun;11(3):195-8. doi: 10.1007/BF02924186.
18. Özen MA, Taşdemir M, Gündoğdu G, Bilge I, Büyükcinal C, Eroğlu E. Does Voiding Cystourethrogram Exclude Posterior Urethral Valves in Late Presenting Cases? *Eur J Pediatr Surg.* 2019;29(1):85-89. doi: 10.1055/s-0038-1672146.
19. Jang SJ. Nuclear Medicine in Pediatric Urology. *Child Kidney Dis.* 2015;19(1):14-22. doi: 10.3339/chikd.2015.19.1.14
20. Kennelly JM, Ritchey LM. Perinephric urinoma secondary to neurogenic bladder in myelodysplasia. *J Urol.* 1995;153(2):458–460. doi: 10.1097/00005392-199502000-00056.
21. David, Vlad Laurentiu, Ramona Stroescu, Calin Marius Popoiu, Marioara Boia, Simona Cerbu, Alexandra L. Scarlett, Aniko Manea, Corina Maria Stanciulescu, Teofana Bizerea, Eugen Sorin Boia, and Otilia Marginean. 2016. "Urinary Obstruction Due to Fungal Infection in Two Preterm Siblings". *International Journal of Medical and Pharmaceutical Case Reports* 6 (4):1-5.