

Comparative study on Cellan Jones repair and Modified Graham patch repair (omentoplasty) in the surgical management of perforated duodenal ulcer

Abstract

Introduction Duodenal ulcer perforation, a complication of peptic ulcer disease, has been treated surgically for over a century. Out of the various repair methods, Cellan Jones repair and Modified Graham Patch repair remain the most preferred approaches for small sized perforations <1.5cm. This study compares the postoperative outcomes, including wound infection rates, leak rates and morbidity, between the two techniques in a cohort of patients.

Methods This prospective, randomized controlled study was conducted on 52 patients presenting with duodenal perforation at Government Medical College and Hospital, Chandigarh, from December 2022 to April 2024. To achieve an unbiased comparison group and a balanced randomization, permuted block randomization with fixed block size was used. Follow-up was conducted for a minimum of 30 days post-surgery to assess wound infection, leak rates, and other complications.

Results Both techniques had similar wound infection rates, with Cellan Jones at 38.5% and MGPR slightly higher at 57.7% with a p value of 0.16. MGPR required longer operative times compared to Cellan Jones at a mean of 81.35 min vs 66.35 min respectively with a p value of < 0.01. MGPR also showed higher rates of certain postoperative complications, though overall morbidity and mortality rates were comparable between the two techniques which was overall statistically insignificant. Also, MGPR had a 0% leak rate, indicating superior sealing compared to the 7.7% leak rate in Cellan Jones Repair, however it was statistically insignificant (p value 0.49)

Conclusion While both Cellan Jones Repair and MGPR are effective techniques for managing duodenal ulcer perforations, MGPR offers a marginally better outcome in preventing leaks but at the cost of a longer surgery and a higher rate of specific complications.

Keywords: Duodenal ulcer perforation, Cellan Jones Repair, Modified Graham Patch Repair, Omentoplasty, Postoperative complications.

Introduction

Peptic ulcer disease (PUD) is a common gastrointestinal condition, with duodenal perforations occurring in 2-14% of cases. ¹Available literature suggests cases which have been reported for more than 2000 years, earliest dating back to 167 BC.²Surgery is the mainstay of treatment to reverse the pathological process by removing contamination, source control and preventing recontamination.³

Non operative management had a success rate of more than 50 % in patients without generalized peritonitis and in a stable condition. However, such presentations are very few and majority of patients land up in sepsis and deteriorate rapidly unless surgically treated.⁴

One of the first surgical procedures described was primary repair of the perforation by Mikulicz-Radecki in 1894. This was unsuccessful and the patient died.⁵ Cellan Jones described the most popular one in 1929, in which three sutures are first placed around the perforation, following which a piece of omentum is tied in place using these sutures to cover the duodenal perforation. This piece of omental graft provides the stimulus for fibrin formation through the combined sequence of inflammation, granulation, vascularization, fibrosis and finally healing the obliterated perforation site.⁶ It is widely considered as the gold standard in dealing with duodenal ulcer perforations in the emergency setup.⁷

In 1931, Roscoe Graham suggested a new technique which involved placing and tying three sutures directly over a piece of free omentum without attempting primary closure of the perforation. It was aimed at reducing the incidence of duodenal stenosis.⁸ Further modification came about in the form of Modified Graham patch repair (MGPR) also known as omentoplasty, which primarily aimed to close the perforation by taking two layers of knots and sandwiching the omentum between these knots to prevent re-leaking (a major concern with Graham's omental patch).⁹ Karanjia technique (Modified Cellan Jones) is also used in which omental pedicle is secured to the tip of a nasogastric tube passed through the perforated duodenal ulcer.¹⁰ Newer modalities including laparoscopic and endoscopic repair have also evolved having its own set of advantages and disadvantages.¹¹

All the above-mentioned techniques have been used in patients with duodenal perforation often having unstable hemodynamics and gross peritoneal contamination at the time of admission. In many institutes, the most widely used and popular techniques are Cellan Jones repair and MGPR for small sized duodenal perforations. However, there is paucity of data which directly compares Cellan Jones repair and MGPR in terms of leak rate, morbidity, success rate and post operative complications. This study was aimed to assess the efficacy and benefits of MGPR over Cellan Jones repair and whether one technique has any direct advantage over the other. Attempt was made to ascertain if closure of the perforation by either technique affects the overall outcome. Complication rates of the two alternative surgical techniques were compared.

Aim

The aim of this study was compare the efficacy of Cellan Jones repair and Modified Graham patch repair in the management of duodenal ulcer perforations.

Material and Methods

The study was a prospective, randomized controlled trial conducted on 52 patients with duodenal ulcer perforations (<1.5 cm) at the Government Medical College and Hospital, Chandigarh, from December 2022 to April 2024. Patients were randomly assigned to undergo either Cellan Jones repair or Modified Graham patch repair, with 26 patients in each group.

Inclusion Criteria

Patients 18 – 90 years of age fit for surgery who are diagnosed with duodenal perforation of size < 1.5 cm intraoperatively.

Exclusion criteria

- Patients who refuse to give consent for participation in the study
- Patients not willing for surgery
- Patients diagnosed with duodenal perforation > 1.5 cm
- Patient unfit for general anaesthesia
- Iatrogenic perforations
- Traumatic perforations
- Suspected malignant ulcer perforation
- Gastric ulcer

- Unavailability/ lack of omentum due to necrosis or previous surgery

Allocation was achieved using permuted block randomization and opaque, sealed envelopes for concealment. Both procedures were performed under general anesthesia via a midline incision, with the type of repair decided intraoperatively based on the random assignment.

The study ensured double-blinding by concealing the repair type from both participants and outcome assessors. Postoperative follow-up was conducted for at least 30 days to monitor wound infection, leak rates, morbidity, and mortality.

Statistical Analysis

Data was analysed using SPSS 26.0 software, with significance set at p value < 0.05 (95% confidence interval). Variables like wound infection, leak rate, and complications were compared between the two groups using appropriate tests, including the Chi-square test for categorical variables and the Mann-Whitney U test for skewed data.

Results

The study documented the age and gender distribution, with the mean age of participants around 44.5 years and the majority being male (98%). The age distribution was similar across both groups, as was gender, with no significant statistical difference. Each patient was evaluated for existing comorbidities, with approximately 46.2% having pre-existing conditions such as hypertension or diabetes, but again, no significant difference in comorbidities was observed between the two groups.

The MGPR group showed a higher, though not statistically significant, incidence of certain complications, like pleural effusion and urinary tract infection. Notably, two cases of bile leak occurred in the Cellan Jones repair group but none in the MGPR group. This slight variance was thought to be due to differences in repair techniques, with MGPR potentially offering a more secure closure due to its approximation of perforation margins. However, these differences were not statistically significant, likely due to the study's small sample size.

The study reported higher wound infection rates in the MGPR group (57.7%) compared to the Cellan Jones repair group (38.5%). Although MGPR showed a greater incidence of infection, this difference was not statistically significant. Both groups experienced wound infections as a common complication. The observed rates suggest that both techniques have associated risks of postoperative infection. There was also a significant difference in operative time between the two groups. The Cellan Jones repair had an average operative time of 66.35 minutes, while the Modified Graham Patch Repair (MGPR) took an average of 88.35 minutes.

This study also evaluated hospital stay and the need for ICU care post-surgery. The MGPR group had a significantly longer median hospital stay of 9 days compared to 6.5 days for the Cellan Jones repair group. This extended stay may be linked to the higher rates of contamination and complications observed in the MGPR patients. ICU stay was required in a few cases in both groups, but this difference was not statistically significant. Overall, the hospital stay duration and ICU care were influenced by the extent of contamination and the individual health conditions of the patients. In terms of mortality, each group attributed to septic shock, resulting in an overall mortality rate of 3.84%.

Table 1: Age distribution among the study participants in the two intervention groups

	Procedure done		Total
	Cellan Jones repair	MGPR	
≤30 Years	3 (39.4%)	6 (23.1%)	9 (17.3%)
31-40 Years	9 (29.6%)	5 (19.2%)	14 (26.9%)
41-50 Years	4 (15.4%)	6 (23.1%)	10 (19.2%)
51-60 Years	5 (19.2%)	5 (19.2%)	10 (19.2%)
>60 Years	5 (19.2%)	4 (15.4%)	9 (17.3%)
Total	26 (50.0%)	26 (21.1%)	52 (100%)
			p-value: 0.66*

**Fisher's exact test*

Table 2: Gender distribution among the study participants in the two intervention groups

	Procedure done		Total
	Cellan Jones repair	MGPR	
Male	25 (96.2%)	26 (100%)	51 (98.1%)
Female	1 (3.8%)	0 (0.0%)	1 (1.9%)
			p-value: 1.00

**Fisher's exact test*

Table 3: Distribution of type of comorbidities among the study participants in the two intervention groups

Comorbidity	Procedure done		Total
	Cellan Jones repair	MGPR	
Type 2 DM	1 (7.7%)	3 (27.3%)	4 (16.7%)
Type 2 DM & HTN	0 (0.0%)	1 (9.1%)	1 (4.2%)
Type 2 DM & stroke	1 (7.7%)	0 (0.0%)	1 (4.2%)
HTN	1 (7.7%)	2 (18.2%)	3 (12.5%)
HTN & stroke	0 (0.0%)	1 (9.1%)	1 (4.2%)
HTN & arthritis	1 (7.7%)	0 (0.0%)	1 (4.2%)
Asthma/ COPD	2 (15.4%)	1 (9.1%)	3 (12.5%)
Hypothyroidism	1 (7.7%)	1 (9.1%)	2 (8.3%)
Stroke	1 (7.7%)	1 (9.1%)	2 (8.3%)
Arthritis/ Joint pain	4 (30.8%)	1 (9.1%)	5 (20.8%)
Oral cancer	1 (7.7%)	0 (0.0%)	1 (4.2%)

Table 4: Distribution of the study participants according to type of complication in the two intervention groups

Type of Complication pre-sent	Cellan Jones re-pair	MGPR	Total
Abdominal collection	5 (19.2%)	5 (19.2%)	10 (19.2%)
Pleural effusion or Pneumonia	7 (26.9%)	10 (38.5%)	17 (32.7%)

Surgical site infection	10 (38.5%)	15 (57.7%)	25 (48.1%)
Septic shock	5 (19.2%)	4 (15.4%)	9 (17.3%)
Deep Venous Thrombosis	0 (0%)	2 (7.7%)	2 (3.8%)
Ileus	5 (19.2%)	7 (26.9%)	12 (23.1%)
Urinary tract infection	3 (11.5%)	6 (23.1%)	9 (17.3%)
Biliary leak	2 (7.7%)	0 (0%)	2 (3.8%)

Table 5: Duration of surgery in the two intervention groups (in minutes)

Cellan Jones repair		MGPR		
Mean \pm SD	Median (IQR)	Mean \pm SD	Median (IQR)	p-value
66.35 \pm 17.75	62.50 (50.00-81.25)	81.35 \pm 21.98	80.00 (63.75-95.00)	<0.01 [^]

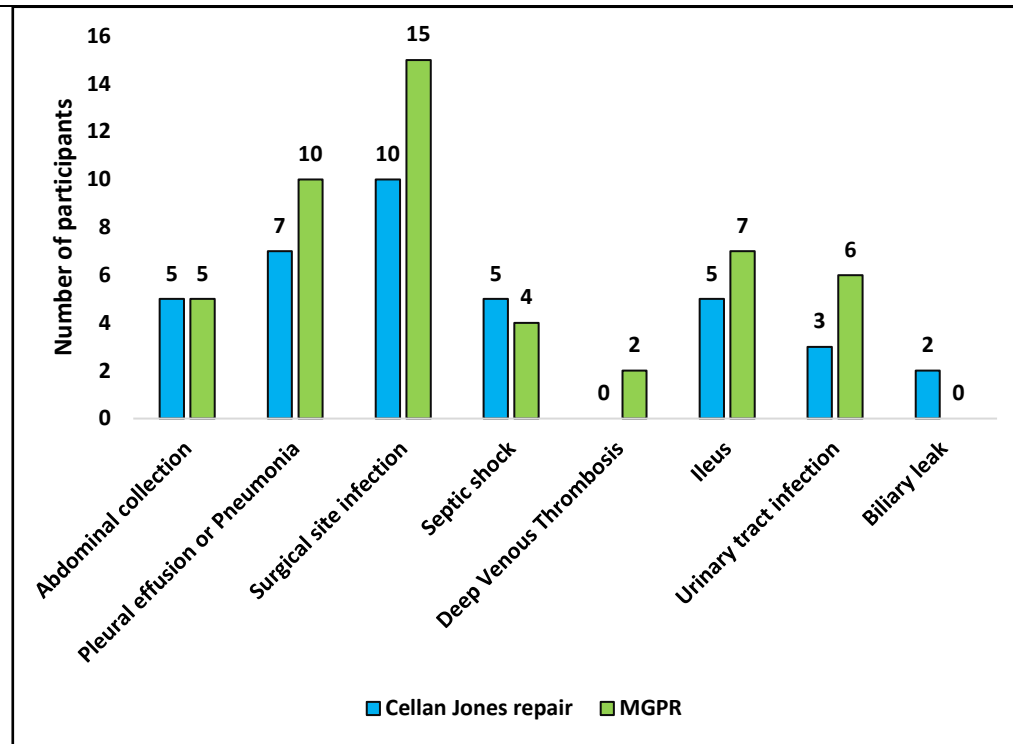
[^]t test

Table 6: Association between post operative ICU stay and type of repair done

ICU stay	Procedure done		p-value
	Cellan Jones repair	MGPR	
Present	2 (7.7%)	4 (15.4%)	0.67*
Absent	24 (92.3%)	22 (84.6%)	

*Fisher's exact test

Figure 1 : Distribution of the study participants according to type of complication



Discussion

Over the last few decades, the number of operations being performed for duodenal ulcer perforation have reduced significantly following the use of proton pump inhibitors.¹² However, there is a little decline in the incidence of peptic ulcer disease overall and it still accounts for approximately 33 % of gastroduodenal surgeries performed as per study conducted by George et al.¹³ Patients having pre-existing comorbidities, delayed presentation with septicemia, shock and a larger size of perforation have a higher mortality.³

Although both Cellan Jones repair and MGPR are done widely for small sized duodenal perforations all over the world, there is no previous study which exclusively compares these two techniques in available literature.

In both repair techniques, initial steps are the same. After making an upper midline incision, abdomen is opened. Once peritoneal cavity is entered, through lavage is given and site of perforation is identified. A biopsy is taken from the margin of the perforation if needed and margins are freshened as per requirement. Also, mobilization of omentum is done.

In Cellan Jones repair, a strand of pedicled omental patch is drawn over the perforation, which is secured by placing three to four sutures on either side of the perforation and tying them over the omentum. The omental tissue provides a physical seal and promotes healing by stimulating fibrin formation and tissue repair.⁶ The simplicity and quick execution of the Cellan Jones repair make it popular, especially for patients with unstable conditions, as it minimizes operative time and reduces the risk of postoperative complications.^{7,14}

On the other hand, MGPR is particularly known for providing a secure closure. In this procedure, sutures are first placed at the perforation site to approximate its edges first. Then a pedicled omental patch is placed and these sutures are tied again over the omental patch. Omentum sandwiched between two layers of these sutures helps to strengthen the seal. This additional layer helps prevent re-leakage by creating a more stable closure than traditional methods.⁹ The MGPR technique takes more operative time than Cellan Jones repair due to these extra steps, but it is considered effective for patients needing a robust repair, as it lowers the risk of postoperative leak complications.¹⁵⁻¹⁶ Similar results were obtained for large scale systematic review and meta-analysis which show comparable postoperative complication

rates and higher operative time for Grahams omentopexy compared to simple closure.¹⁷ Studies comparing minimally invasive approaches to open surgeries also show similar postoperative complication rates and a longer operative time for minimally invasive methods.¹⁸

This study aimed to address that gap by assessing both methods to determine if either technique provides superior outcomes in terms of success rate, postoperative complications, morbidity, and mortality. Patient demographics aligned with previous studies, with an average age of 44.5 years and a predominantly male sample, as lifestyle factors contribute to higher rates among males. Consistent with earlier research, the study found that age and gender distributions did not significantly differ between the two groups.¹³⁻¹⁹ Additionally, preoperative factors such as delayed presentation and comorbidities were acknowledged as influential in surgical outcomes for patients with duodenal perforations.

Large scale studies comparing various methods for management of duodenal ulcer perforations In comparing postoperative complications, MGPR was associated with higher incidences of pleural effusion and urinary tract infection, contributing to extended recovery times. Cellan Jones Repair had fewer complications in this study, including no pleural effusion cases. This outcome suggests a slight advantage for Cellan Jones Repair in terms of fewer postoperative issues, though the MGPR technique provides a more robust seal at the perforation site, potentially reducing leak risks. However, similar large scale studies showed statistically insignificant postoperative complication rates regardless of the method used which could be a limitation of this study owing to its small sample size.

Overall limitations of this study include a small sample size which limits definitive conclusions and a need for further research with larger, multicentric studies to validate findings. Also, all patients not being operated by the same surgeon can affect parameters such as operating time, postoperative wound infections and bile leak. Minimally invasive methods were not studied for these surgeries which could have different results altogether. However this study was the first in available literature which directly compared Cellan Jones repair to MGPR.

Conclusion

The study concluded that both techniques are effective surgical techniques for managing small duodenal perforations (less than 1.5 cm). The results showed no significant difference in overall complication rates, though Cellan Jones Repair had a slightly higher rate of postoperative bile leaks, which may relate to its lack of perforation margin approximation. MGPR, while requiring longer operative time, provided a more secure repair without postoperative leaks in this sample. Due to the study's limited sample size, further research with larger, multicenter trials is recommended to validate these findings and better understand any potential advantages between the two techniques.

Consent

As per international standards or university standards, patient(s) written consent has been collected and preserved by the author(s).

Disclaimer (Artificial intelligence)

Option 1:

Author(s) hereby declare that NO generative AI technologies such as Large Language Models (ChatGPT, COPILOT, etc.) and text-to-image generators have been used during the writing or editing of this manuscript.

Option 2:

Author(s) hereby declare that generative AI technologies such as Large Language Models, etc. have been used during the writing or editing of manuscripts. This explanation will include the name, version, model, and source of the generative AI technology and as well as all input prompts provided to the generative AI technology

Details of the AI usage are given below:

1.

2.

3.

References

1. Lau JY; Sung J; Hill C; Henderson C; Howden CW; Metz DC Systematic review of the epidemiology of complicated peptic ulcer disease incidence, recurrence, risk factors and mortality. *Digestion* 2011; 84:102-13.
2. Lau WY, Leow CK. History of perforated duodenal and gastric ulcers. *World J Surg.* 1997; 21:890-96.
3. Lagoo S, McMahon RL, Kakihara M, Pappas TN, Eubanks S. The sixth decision regarding perforated duodenal ulcer. *JLS.* 2002; 359-68.
4. Mouly C, Chati R, Scotté M, Regimbeau JM. Therapeutic management of perforated gastro-duodenal ulcer: literature review. *J Visc Surg.* 2013 Nov;150(5):333-40.
5. Dean HP. A case of perforation of a chronic ulcer of the duodenum successfully treated by excision: Death two months later from acute intestinal obstruction by a band. *Br Med J* 1894; 1014-5.
6. Cellan-Jones C. A rapid method of treatment in perforated duodenal ulcer. *Br Med J.* 1929; 1:1076.
7. Arora BK, Arora R, Arora A. Modified Graham's repair for peptic ulcer perforation: reassessment study. *Int J Surg* 2017; 4:1667-71
8. Graham RR. The surgeon's responsibility in the treatment of duodenal ulcer. *Can Med Assoc J* 1936; 35:263.
9. Rajput IA, Munawar S, Manzar S. Comparison of omentopexy technique for duodenal ulcer perforation. *Pak J Surg* 2000; 16:1-5.
10. Karanjia ND, Shanahan DJ, Knight MJ. Omental patching of a large perforated duodenal ulcer: a new method. *Br J Surg* 1993; 80:65.
11. Malkov IS, Zaynutdinov AM, Veliyev NA, Tagirov MR, Merrell RC. Laparoscopic and endoscopic management of perforated duodenal ulcers. *J Am Coll Surg.* 2004; 198 :352-55.
12. Bertleff M, Lange J. Perforated peptic ulcer disease: a review of history and treatment. *Dig Surg* 2010; 27; 161–69.
13. Serin A, Tankurt E, Şarkış C, Simsek I. The prevalence of *Helicobacter pylori* infection in patients with gastric and duodenal ulcers - a 10-year, single-centre experience. *Prz. Gastroenterol.* 2015; 10: 160–63.
14. Jani Kalpesh, Saxena Vaghasia, Rasik. Omental Plugging for large sized duodenal peptic perforations: A Prospective Randomized study of 100 Patients. *Southern Med Jou,* 2006; 99: 467-71.
15. Satapathy MC, Dash D, Panda C. Modified Graham's omentopexy in acute perforation of first part of duodenum; A tertiary level experience in South India. *Saudi Surg J* 2013; 1:33-6.
16. Mukhopadhyay M, Banerjee C, Sarkar S, Roy D, Rahman QM. Comparative study between omentopexy and omental plugging in treatment of giant peptic perforation. *Ind J Surg.* 2011;73 :341-45.
17. Demetriou G, Chapman M. Primary closure versus Graham patch omentopexy in perforated peptic ulcer: A systematic review and meta-analysis. *Surgeon.* 2022 Jun;20(3):e61-e67.

18. Mohamedahmed AYY, Albendary M, Patel K, Ayeni AA, Zaman S, Zaman O, Ibrahim R, Mobarak D. Comparison of Omental Patch Closure Versus Simple Closure for Laparoscopic Repair of Perforated Peptic Ulcer: A Systematic Review and Meta-Analysis. *Am Surg.* 2023 May;89(5):2005-2013.
19. Shivaji H Vidyarthi, Mahesh Kumar Jangir, Amit Singh. A prospective study for comparison between Graham's omentopexy v/s figure of eight closures in cases of peptic perforation. *Int J Surg Sci* 2020; 4:142-45.

UNDER PEER REVIEW