

Subgaleal Hemorrhage with Periorbital Hematoma in a 6-Year-Old Boy Following a Road Traffic Accident: A Case Report

Abstract

Subgaleal hemorrhage is a rare yet potentially life-threatening condition in pediatric patients, characterized by bleeding in the subgaleal space and is often associated with head trauma. Although it is commonly observed in neonates following vacuum extraction, its occurrence following road traffic accidents is rare and under-reported. This case report presents a 6-year-old Nigerian boy who developed subgaleal hemorrhage and periorbital hematoma following a road traffic accident. Owing to the unavailability of a CT scan, diagnosis was achieved using skull X-ray and ultrasound. Tranexamic acid was administered as part of the medical management. Surgical intervention was performed to control the hemorrhage, with approximately 320ml of blood evacuated, and no drainage catheter was left in situ. The patient responded well to treatment, with full recovery observed during follow-up. This case highlights the importance of early recognition and intervention in subgaleal hemorrhage, particularly in resource-limited settings.

Keywords: Pediatric head trauma, Pediatric trauma care, Road traffic accident, Subgaleal hemorrhage, Periorbital hematoma

Introduction

Subgaleal hemorrhage is an uncommon but serious condition in pediatric patients, particularly following head trauma [1]. It is characterized by bleeding into the subgaleal space, located

between the galea aponeurotica and the periosteum [2]. This condition is most frequently observed in neonates, particularly following instrumental deliveries such as vacuum extraction, although it can also occur after normal vaginal delivery or cesarean section [3-5]. In older children, trauma such as road traffic accidents can result in subgaleal hemorrhage, with the potential for severe complications, sometimes presenting spontaneously without any clear traumatic event [3].

The scalp is composed of five layers: the skin, dense connective tissue, fibrous galea aponeurotica (galea aponeurosis), loose connective tissue, and pericranium (periosteum). Bleeding in the subgaleal space is typically caused by the rupture of emissary veins, which drain blood from the scalp into the dural sinuses, often as a result of external forces. If not managed promptly, subgaleal hemorrhage can lead to severe complications, such as intraorbital hematoma, ecchymosis, and potential vision loss from intraorbital hemorrhage [6,7].

Case Presentation

A 6-year-old Nigerian boy was brought to the emergency department following a road traffic accident. The boy was travelling with his parents when the accident occurred; the father, who was driving, was uninjured, while the mother sustained a forearm injury. The boy, however, suffered bruises on his scalp after hitting his head on the car door. Passers rescued the family and took them to a nearby clinic where initial first aid was administered. The patient was then transferred to the hospital about 30 minutes after the accident when the father noticed fluctuant swelling on the right side of the scalp.

On arrival at the hospital, the boy presented with left periorbital swelling, fluctuant scalp swelling, and contusion on the scalp (Figure 1). His Glasgow Coma Scale (GCS) score was 14,

indicating mild head injury. The child was hemodynamically stable, but a physical examination revealed significant scalp swelling extending from the right forehead to the right occipital region, a ballotable lesion crossing the suture lines, and pitting edema extending over the head and in front of the right ear, all of which were suggestive of subgaleal hemorrhage. The neurological examination was unremarkable, with no focal deficits.

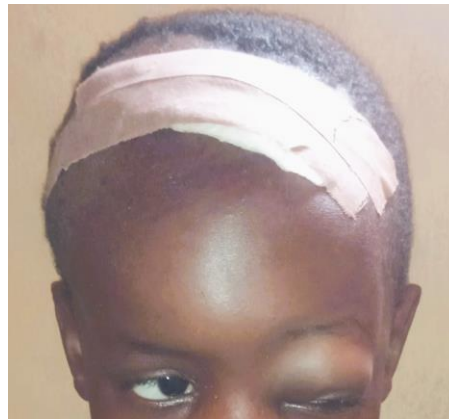

Figure 1 shows left periorbital swelling along with a fluctuant scalp swelling localized to the right frontal and temporal regions, with a plaster applied to a scalp contusion.

A full blood count (FBC) and prothrombin time(PT) were within normal limits (Table 1). There was no history of bleeding disorders or systemic diseases, and the patient had no prior history of trauma or surgery. Despite the presence of ptosis due to a periorbital hematoma, the boy's visual acuity was normal, ruling out optic nerve involvement and **no diplopia**. Intraocular pressure could not be measured because a Goldmann applanation tonometer was unavailable.

TEST NAME	Value	UNIT	NORMAL_RANG	TEST RESULT
Hb	11.2	g/dl	10.3 - 14.3	

PCV	33.7	%	31-43	
RBC	4.95	x 10 ¹² /L	3.4-5	
MCV	68.2	fl	75-99	L
MCH	22.8	pg	25-32.5	L
MCHC	33.5	g/dl	30-36	
RDW	14	%CV	11.5-16	
Platelet	201,000	/mm ³	150000-400000	
MPV	8.4	fl	9.4-12.3	L
PDW	15.2	fl	9.2-16.7	
Total WBC Count	6200	/mm ³	6000-17000	
Neutrophils	21.7	%	20-42	
Lymphocytes	69.2	%	40-70	
Monocyte	5.1	%	3-6	
Eosinophil	3.9	%	0-3	H
Basophil	0.1	%	0-1	
Prothrombin Time	11.0	Seconds	10-14	

Table 1 showing full blood count (FBC) and prothrombin time (PT) lab results

Since a CT scan was not available, a skull X-ray was done to rule out fractures, and an ultrasound scan was used to confirm subgaleal hemorrhage and periorbital hematoma. X-ray revealed no evidence of skull fractures (Figure 2). However, the swelling of the scalp rapidly increased in size, suggesting the need for urgent surgical intervention.

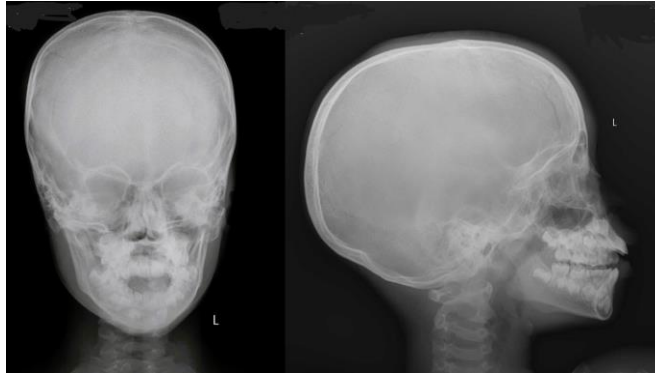

Figure 2 shows the anterior and lateral view of the skull X-ray

The patient was taken to the operating theatre for surgical drainage, during which approximately 320 ml of blood was evacuated and no drainage catheter was left in situ. However, sterile eye pads were applied to both eyes during the procedure to distribute pressure evenly and prevent blood accumulation in the unaffected right eye. Pressure was applied to the scalp contusion using a compression bandage to achieve hemostasis and prevent further bleeding after drainage. Postoperatively, the left periorbital swelling significantly reduced, and the left eye pad was kept in place for 12 hours, while the pad on the right eye was removed. The patient was placed on oral tranexamic acid at a dose of 15 mg/kg every 8 hours for three days.

After three days of hospitalization, the patient's condition improved rapidly, and the patient was discharged. On follow-up five days later, the patient was found to be doing well, with no residual complications observed.

Discussion

Subgaleal hemorrhage is rare outside the neonatal period but can occur in older children and adults following trauma. This case aligns with previous literature emphasizing the importance of early recognition and prompt surgical intervention in preventing life-threatening complications

and highlights the critical challenges in managing subgaleal hemorrhage and its complications, particularly in resource-limited settings where advanced imaging modalities such as CT scans are unavailable [8,9]. This case complements Aubert et al. who emphasized the need for adaptable diagnostic and management strategies tailored to available resources [9]. In this scenario, a skull X-ray, though less sensitive, was crucial in excluding fractures, whereas an ultrasound provided valuable confirmation of subgaleal hemorrhage and periorbital hematoma.

Prompt surgical intervention and conservative management, including the use of tranexamic acid, were pivotal for controlling hemorrhage and preventing further complications. Although subgaleal hemorrhage is often self-limiting in mild cases as noted by Chen et al, endovascular surgery has been documented as a viable option for expanding or refractory hemorrhages [3,4,10].

Bleeding in the subgaleal space is typically caused by the rupture of emissary veins, which drain blood from the scalp into the dural sinuses as shown in Figure 3, if the hemorrhage is linked to active bleeding from the emissary veins, an endovascular procedure may be necessary for precise embolization of the damaged vein to control hemorrhage. However, this specialized expertise and technology are often lacking in resource limited settings, posing significant challenges to optimal patient care. This disparity highlights a critical gap in patient care, particularly in low-resource environment.

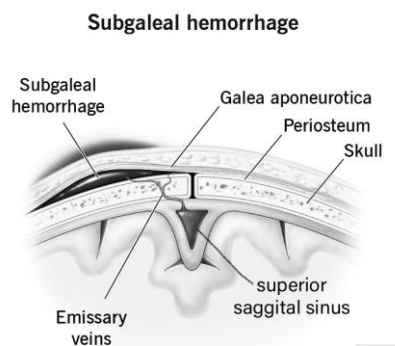


Figure 3 Modified schematic of Subgaleal hemorrhage illustrating the subgaleal space and emissary veins draining into the superior sagittal sinus. Original image adapted from Cleveland Clinic website [11]

This case also highlights the utility of a multidisciplinary approach in managing paediatric trauma, with prompt surgical consultation and close postoperative monitoring. Further studies are needed to explore alternative management strategies and long-term outcomes in similar cases, particularly in settings where advanced imaging and surgical resources may not be readily available.

Conclusion

Subgaleal hemorrhage, though rare in pediatric patients outside the neonatal period, presents significant challenges in terms of diagnosis and management, especially in resource-limited settings. This case demonstrates the effectiveness of clinical assessment and basic imaging modalities in the absence of advanced technology. Early surgical intervention and appropriate medical management can lead to favourable outcomes, as evidenced by the successful recovery of these young patient.

Limitations

The primary limitation was lack of advanced imaging, such as CT scan, which could have provided more accurate information on the extent of the hemorrhage and potential underlying injuries. Relying on X-ray and ultrasound, although necessary in this case, may have delayed diagnosis and lacked sensitivity for detecting subtle injuries. The absence of the advanced neuroimaging limited the ability to rule out other complications, which could have impacted management decisions. This case highlights the challenges of trauma care in settings with limited resources, underscoring the need for better access to diagnostic tools.

Declaration

Ethics approval

Our institution does not require ethical approval for reporting individual cases or case series.

Informed consent

Written informed consent was obtained from a legally authorized representative(s) for anonymized patient information to be published in this article.

Disclaimer (Artificial intelligence)

Author(s) hereby declare that NO generative AI technologies such as Large Language Models (ChatGPT, COPILOT, etc.) and text-to-image generators have been used during the writing or editing of this manuscript.

References

1. Chang HY, Peng CC, Kao HA, Hsu CH, Hung HY, Chang JH. Neonatal subgaleal hemorrhage: clinical presentation, treatment, and predictors of poor prognosis. *Pediatr Int*. 2007;49(6):903-907. doi:10.1111/j.1442-200X.2007.02482.x
2. Colditz MJ, Lai MM, Cartwright DW, Colditz PB. Subgaleal haemorrhage in the newborn: A call for early diagnosis and aggressive management. *J Paediatr Child Health*. 2015;51(2):140-146. doi:10.1111/jpc.12698

3. Koizumi K, Suzuki S, Utsuki S, Nakahara K, Niki J, Mabuchi I, Kurata A, Fujii K. A case of non-traumatic subgaleal hematoma effectively treated with endovascular surgery. *Interv Neuroradiol*. 2010 Sep;16(3):317-21. doi: 10.1177/159101991001600315.

4. Wajima D, Nakagawa I, Kotani Y, Wada T, Yokota H, Park YS, Kichikawa K, Nakase H. A case of refractory subgaleal hematoma in adolescence treated with aspiration and endovascular surgery. *Acta Neurochir (Wien)*. 2017 Aug;159(8):1565-1569. doi: 10.1007/s00701-017-3207-z. Epub 2017 May 9.

5. Babata, K., Vadlamudi, G., Bailey, N. A., Gill, S., Viswanathan, P., Sillero, R., Seidu, T., Mangona, K. L., Leon, R., & Angelis, D. (2024). Subgaleal hemorrhage in neonates: a comprehensive review and summary recommendations. *Journal of perinatology : official journal of the California Perinatal Association*, 10.1038/s41372-024-02116-w. Advance online publication. <https://doi.org/10.1038/s41372-024-02116-w>

6. Kim SY, Cha HG, Jang SY, Hwang SC. Delayed Massive Expansion of Subgaleal Hematoma Complicated with Proptosis in Hemophilia B. *Korean J Neurotrauma*. 2021 Jul 15;17(2):149-155. doi: 10.13004/kjnt.2021.17.e14. PMID: 34760826; PMCID: PMC8558023.

7. Pope-Pegram LD, Hamill MB. Post-traumatic subgaleal hematoma with subperiosteal orbital extension. *Surv Ophthalmol*. 1986;30(4):258-262. doi:10.1016/0039-6257(86)90122-0

8. Chen, C. E., Liao, Z. Z., Lee, Y. H., Liu, C. C., Tang, C. K., & Chen, Y. R. (2017). Subgaleal Hematoma at the Contralateral Side of Scalp Trauma in an Adult. *The Journal of emergency medicine*, 53(5), e85–e88. <https://doi.org/10.1016/j.jemermed.2017.06.007>

9. Aubert, B., Cadoux, M., & Sahyoun, C. (2023). Traumatic subgaleal hematoma drainage in an adolescent: a case report and review of the literature. *Frontiers in pediatrics, 11*, 1182899.

<https://doi.org/10.3389/fped.2023.1182899>

10. Xie, Y., Lu, Q., Lenahan, C., Yang, S., Zhou, D., & Qi, X. (2020). A Comparison of Subperiosteal or Subgaleal Drainage with Subdural Drainage on the Outcomes of Chronic Subdural Hematoma: A Meta-Analysis. *World neurosurgery, 135*, e723–e730.

<https://doi.org/10.1016/j.wneu.2019.12.116>

11. Cleveland Clinic. Subgaleal hemorrhage in newborns Retrieved from

<https://my.clevelandclinic.org/health/diseases/22219-subgaleal-hemorrhage> Accessed December 4, 2024