

Posterior placoid chorioretinitis secondary to syphilis: A case report

ABSTRACT

There has been a resurgence of syphilis in recent times, despite a consistent decline in incidence over the past decade. Its estimated global prevalence of 1.11% has been increasing since mandatory reporting ended in 2000. The diagnosis of syphilis can be clinically challenging, and ocular manifestations of syphilis present in a multitude of ways and with varying degrees of severity. Ocular syphilis can manifest at any stage of the disease and may also be the sole presenting sign of syphilis.

KEY WORDS

Ocular syphilis, posterior placoid chorioretinopathy, uveitis, Chorioretinitis

INTRODUCTION

Syphilis, also known as the great simulatrix, is caused by the spirochete *Treponema pallidum*. Currently on the rise, it is once again a public health problem. Ophthalmological involvement is typically found in the secondary or tertiary phases of the disease [5-7]. It can present in a number of ways, including granulomatous anterior uveitis, interstitial keratitis, periphlebitis, hyalitis, focal retinitis, papillitis, retinal serous detachment, oculomotor paralysis, retinal necrosis, and chorioretinitis. The most common form of macular damage in HIV-infected patients is posterior placoid maculopathy, as described by Gass et al. in 1990 (1). This involves damage to the choriocapillaris and pigment epithelium due to the deposition of immune complexes.

Case presentation

We report the case of a 25-year-old single patient with a history of unprotected sexual intercourse who presented with a progressive decrease in visual acuity in the left eye over the last two weeks, with perception of central scotoma. The patient reported a similar episode in the same eye two months ago, which resolved spontaneously.

The clinical examination revealed a visual acuity of 10/10ths in the right eye and 1/10ths in the left eye, examination of the adnexa is normal, and examination of the anterior segment reveals a few rare cells in the anterior chamber of the left eye. The fundus showed no hyalitis in either eye, but the left eye had posterior placoid chorioretinitis in the form of a yellowish plaque at the posterior pole due to changes in the pigment epithelium. FIGURE 2

Autofluorescence imaging of the left eye showed macular hyperautofluorescence in the form of a patch with irregular borders FIGURE 2, and macular OCT showed disruption of the outer limiting membrane and disorganization of the ellipsoid line, as well as hypersignals in the choriocapillaris FIGURE 3 .

The patient's visual field demonstrated a diffuse decrease in sensitivity in the left eye, accompanied by a central scotoma. A comprehensive biologic work-up for uveitis was conducted, including TPHA-VDRL serologies, which were positive with elevated CRP. This led to the diagnosis of posterior placoid chorioretinitis being maintained. Additionally, a lumbar puncture with a biological analysis of the LCR and cerebral MRI were performed to investigate the possibility of neurosyphilis, which were found to be normal.

The diagnosis was syphilitic neuroretinitis with macular placoid lesions. Treatment with intravenous (IV) penicillin G for 14 days was started .Giving the fact that there were no vitritis,vasculitis or posterior scleritis we did not use steroids in addition to antibiotics and the evolution after 14 days of treatment was good with VA :4/10.

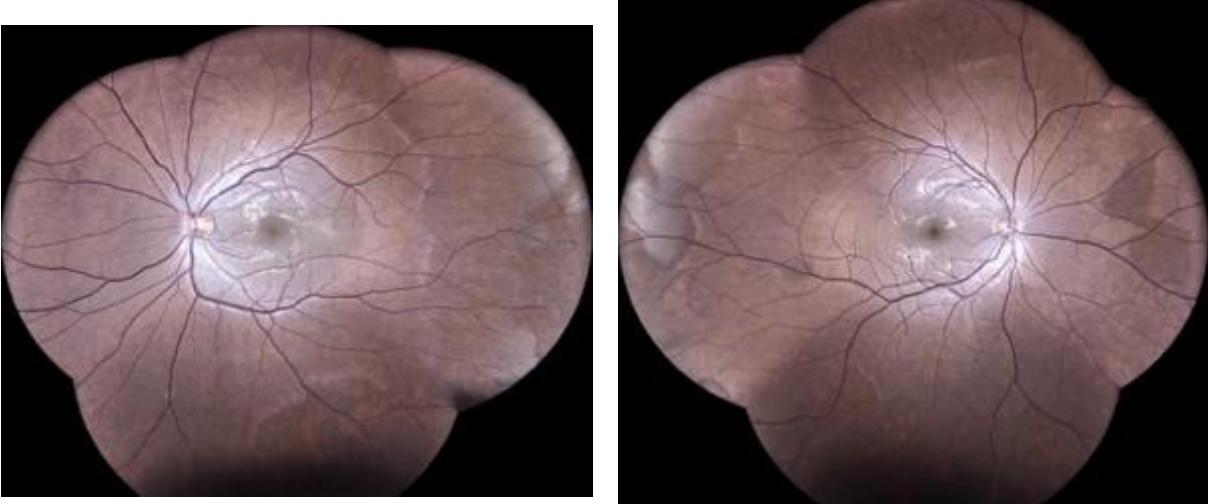


Figure 1 : Fundoscopic retinophotos of right and left eyes .

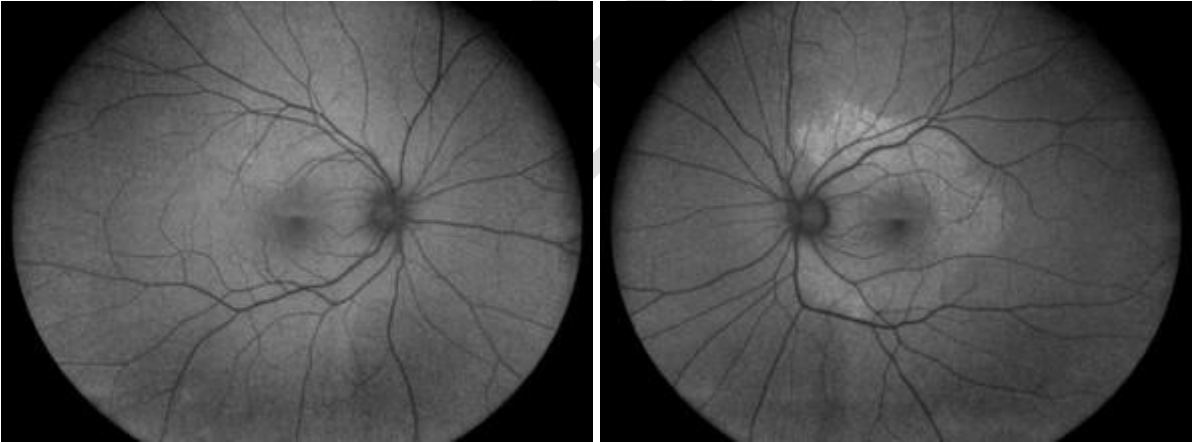


Figure 2 :Autofluorescence captures of both eyes, note the hyperautofluorescence in the macula of the left eye

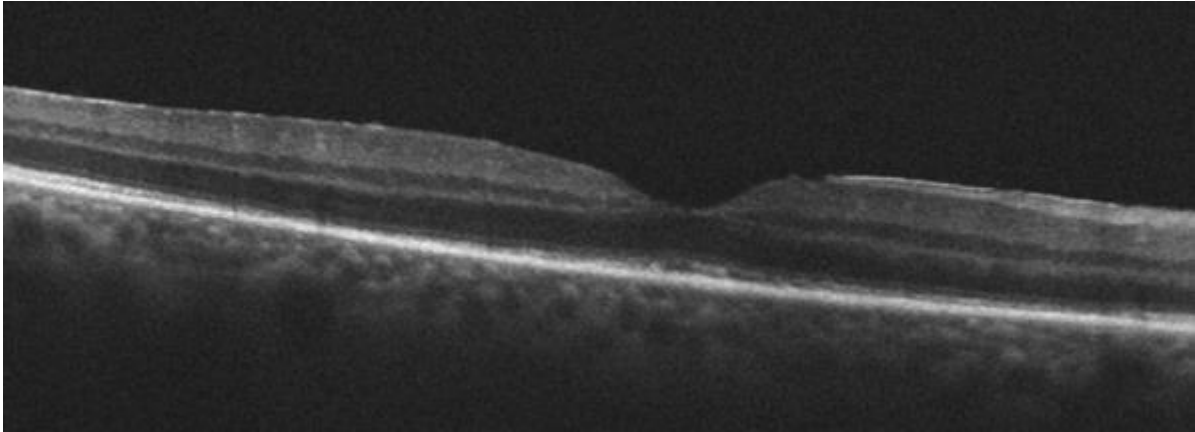


Figure 3 : Macular oct of the left eye with disruption of the external limiting membrane and desorganisation of the ellipsoid zone

DISCUSSION

Syphilitic posterior placoid chorioretinitis, first described by CitationGass and colleagues in 1990(2), is characterised by yellowish, ill-defined, placoid lesions that are confluent in the posterior pole or mid-periphery of the fundus. These lesions typically exhibit a pale centre and stippled hyperpigmentation of the retinal pigment epithelium (RPE), with the potential for coalescence to form large, confluent lesions(3).

The discrete placoid lesion, which is consistent with syphilitic posterior placoid chorioretinitis, is an uncommon manifestation that is typically observed among individuals who are immuno-compromised (1) but was not the case of our patient.

Early diagnosis of ocular syphilis is challenging due to the presence of several other conditions that may present similarly. These include infectious conditions such as tuberculosis or toxoplasmosis, as well as non-infectious inflammatory conditions such as sarcoidosis or Vogt-Koyanagi-Harada syndrome. It is therefore essential to rule out these potential causes before making a diagnosis of ocular syphilis [8-10].

Given the absence of established criteria for ophthalmologists directing when to suspect syphilis and order serological tests, it is crucial for the differential diagnosis of ocular syphilis that high index of suspicion and early accurate diagnostic intervention are employed.(4)

EVOLUTION

Three months following treatment, the patient has demonstrated a complete recovery. Visual acuity was measured at 10/10, the fundus was unremarkable, and the macular OCT demonstrated the recovery of the photoreceptors in their entirety, with the persistence of a discrete irregularity of the pigmented epithelium.(figure 4)

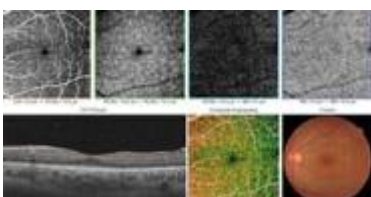


FIGURE 4 : macular oct at the follow up after three months.

CONCLUSION

Syphilis, also known as the great simulatrix, can affect all eye structures. It is therefore essential to systematically look for syphilis in any ocular inflammation, especially if the uveitis is chronic, resistant to anti-inflammatory treatment, the aetiology is not obvious and there are associated risk factors. Early diagnosis will lead to a cure in the vast majority of cases.

Disclaimer (Artificial intelligence)

Option 1:

Author(s) hereby declare that NO generative AI technologies such as Large Language Models (ChatGPT, COPILOT, etc.) and text-to-image generators have been used during the writing or editing of this manuscript.

Consent

As per international standards or university standards, patient(s) written consent has been collected and preserved by the author(s).

References

- [1] Gass JD, Braunstein RA, Chenoweth RG. Acute syphilitic posterior placoid chorioretinitis. *Ophthalmology*. 1990;97(10):1288-97.
- 2- Donald M. Gass MD, Robert A. Braunstein MD ^b, Richard G. Chenoweth MD , Acute Syphilitic Posterior Placoid Chorioretinitis
- 3-JDM Gass - Diagnosis and treatment, 1997 - cir.nii.ac.jp Stereoscopic atlas of macular diseases |
- 4- Kiss S, Damico FM, Young LH. Ocular manifestations and treatment of syphilis *Semin Ophthalmol*. 2005;20:161–7
5. Eandi CM, Neri P, Adelman RA, Yannuzzi LA, Cunningham Jr ET, International Syphilis Study Group. Acute syphilitic posterior placoid chorioretinitis: report of a case series and comprehensive review of the literature. *Retina*. 2012 Oct 1;32(9):1915-41.
6. Gass JD, Braunstein RA, Chenoweth RG. Acute syphilitic posterior placoid chorioretinitis. *Ophthalmology*. 1990 Oct 1;97(10):1288-97.

7. Joseph A, Rogers S, Browning A, Hall N, Barber C, Lotery A, Foley E, Amoaku WM. Syphilitic acute posterior placoid chorioretinitis in nonimmunocompromised patients. *Eye*. 2007 Aug;21(8):1114-9.
8. Zamani M, Garfinkel RA. Corticosteroid-induced modulation of acute syphilitic posterior placoid chorioretinitis. *American journal of ophthalmology*. 2003 Jun 1;135(6):891-4.
9. Chen J, Lee L. Posterior placoid chorioretinitis: An unusual ocular manifestation of syphilis. *Clinical Ophthalmology*. 2008 Sep 1;2(3):669-73.
10. Pichi F, Ciardella AP, Cunningham Jr ET, Morara M, Veronese C, Jumper JM, Albin TA, Sarraf D, McCannel C, Voleti V, Choudhry N. Spectral domain optical coherence tomography findings in patients with acute syphilitic posterior placoid chorioretinopathy. *Retina*. 2014 Feb 1;34(2):373-84.

UNDER PEER REVIEW