

ANALYSIS OF RIGHT VENTRICULAR STRAIN IN HEART FAILURE WITH PRESERVED EJECTION FRACTION

ABSTRACT :

Introduction:

The complexity of the geometry and the unique architecture of the right ventricular (RV) myocardial fibers make the study of its function a significant challenge. However, the advent of new imaging techniques, such as RV strain imaging, has improved our understanding of its function. The aim of our study is to specify the principles of studying right ventricular deformation and its impact on the prognosis of patients with heart failure with preserved ejection fraction (HFpEF).

Materials and Methods:

This is a two-year prospective study comparing echocardiographic parameters of right ventricular function in 87 patients followed in our unit for HFpEF at the Cardiology Department of ERRAZI Hospital, CHU Mohammed VI, Marrakech.

Results:

Over the past two years, our unit has hosted 87 patients diagnosed with HFpEF. The average age was 68 years and 5 months, with a female predominance. The most common cardiovascular risk factors were hypertension and obesity (BMI > 30). Symptomatic presentations were dominated by exertional dyspnea, observed in 84% of cases, with resting dyspnea and cough affecting about half of the patients. Signs of left heart failure, such as crackling rales, were present in 44% of patients, while signs of right heart failure, such as lower limb edema, were noted in 41%, with jugular distension and hepatojugular reflux in 19%. Echocardiography revealed left ventricular hypertrophy in 57% of patients and left atrial dilatation in 65%. Right ventricular function was markedly impaired, with significant abnormalities in TAPSE (Tricuspid Annular Plane Systolic Excursion), S' wave, and Tei index values, highlighting a marked correlation between the Tei index and the deformation of the right ventricular lateral wall. Rehospitalization for heart failure occurred in 40.2% of the cohort, emphasizing the severe clinical implications of right ventricular dysfunction in this patient population.

Discussion and Conclusion:

RV strain in HFpEF is an analysis that has not yet revealed all its intricacies. This study demonstrates that there is an alteration in RV strain in patients with HFpEF, which has a prognostic impact on mortality and rehospitalization for cardiac decompensation. This suggests that this parameter should be integrated into routine evaluations of RV systolic function.

Key words : Heart failure, Preserved ejection fraction, Right ventricle, Prognosis

Introduction :

The complex geometry and unique myocardial fiber architecture of the right ventricle (RV) make the study of its

function a significant challenge. However, the advent of new imaging techniques such as RV strain imaging has enhanced our understanding of its function.

The objective of our study is to delineate the principles of right ventricular deformation analysis and its prognostic contribution in patients with heart failure with preserved ejection fraction (HFpEF).

Materials and methods:

1- Methodology :

This two-year prospective study evaluated echocardiographic parameters of right ventricular function in 87 patients diagnosed with heart failure with preserved ejection fraction. The study was conducted in the Cardiology Department of Errazi Hospital, Mohammed VI University Hospital in Marrakech. Ethical clearance was obtained prior to the study, and the sample size was determined based on predefined statistical considerations. While the study was prospective, certain historical data were referenced from department archives for cross-verification and completeness. Regarding inclusion criteria, patients were selected based on their documented history of cardiac decompensation within the month prior to inclusion in the database, ensuring consistency in clinical evaluation.

This article focuses on analyzing echocardiographic parameters in patients with heart failure with preserved ejection fraction (HFpEF).

2- Evaluationcriteria:

2.1. Clinical and paraclinical evaluation criteria:

The parameters evaluated encompassed age, sex, comorbidities, and the clinical history of patients diagnosed with heart failure with preserved ejection fraction (HFpEF). Functional symptoms at the time of diagnosis were specifically analyzed, including exertional dyspnea, rest dyspnea, and paroxysmal nocturnal dyspnea.

Clinical examination findings highlighted signs of both right and left heart failure. Transthoracic echocardiography data were carefully reviewed, focusing on left ventricular ejection fraction (LVEF), assessment of right ventricular (RV) kinetics, longitudinal function (TAPSE,

S'VD), radial function (RV strain), and the presence of pulmonary arterial hypertension (PAH).

Particular attention was given to the left ventricle in terms of kinetics and the presence of associated valvular diseases.

2.2. Inclusion and exclusion criteria:

The inclusion criteria for our study specified that no patient should have experienced cardiac decompensation within the month preceding their inclusion in our database. Additionally, patients who had undergone cardiac surgery or the implantation of right ventricular devices were excluded. Furthermore, it is preferable to exclude patients suffering from acute heart failure, cardiomyopathies, hemorrhages, or significant coronary artery disease due to the differing progression of these conditions.

3- Statisticalanalysis:

A descriptive analysis of the study population was performed. Quantitative variables were expressed as medians and ranges, while qualitative variables were presented as frequencies and percentages.

Results :

Over the past two years, we documented 87 patients hospitalized in our unit, all diagnosed with heart failure with preserved left ventricular ejection fraction (LVEF). The mean age of the participants was 68 years and 5 months, with a range spanning from 55 to 79 years. Notably, the majority of the patients (63%) were aged between 60 and 70 years, as illustrated in Figure 1. A significant female predominance was also observed in this cohort.

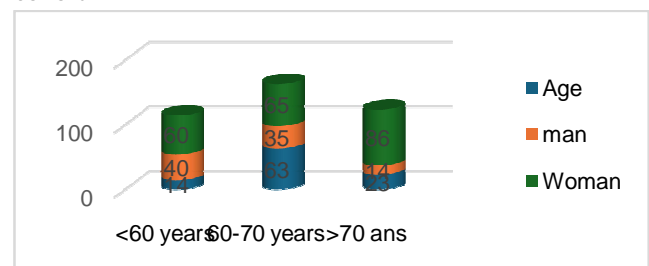


Figure 1: Epidemiological profile of our patients.

In this cohort, hypertension was identified as the most prevalent cardiovascular risk factor, followed by obesity, defined as a body mass index (BMI) exceeding 30. Additionally, diabetes was observed in 10% of the patients, while sleep apnea syndrome was noted in 15% of cases, as illustrated in Figure 2.

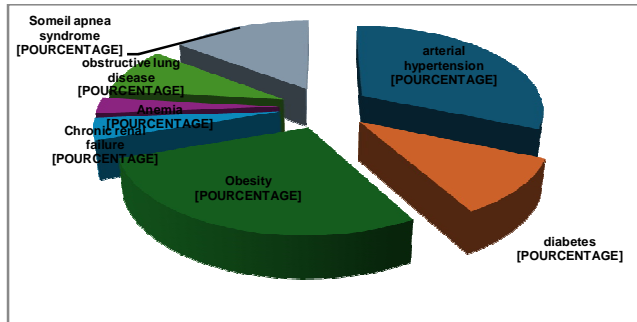


Figure 2: Comorbidity in our patients

All patients in our study presented with functional symptoms, with exertional dyspnea being the predominant reason for consultation, observed in 84% of cases. Resting dyspnea and cough were also reported in nearly half of the patients. Regarding physical examination findings, 44% of patients exhibited signs of left-sided heart failure, such as crackles. Signs of right-sided heart failure included lower limb edema in 41% of cases, while jugular venous distension and hepatojugular reflux were noted in 19% of cases, as summarized in Table 1.

Table 1: Functional and physical signs in our patients

Signs and symptoms	Patients	%
Dyspnea on exertion	27	84%
Dyspnea at rest	13	41%
Paroxysmal nocturnal dyspnea	6	19%
Cough	13	41%
Edema of lowerlimbs	13	41%
Tachycardia	14	43%
Galloping noise	4	13%
Cracklingrales	14	44%
Sibilant rales	2	6%
Hepatomegaly	9	28%
Jugularveinturgidity	6	19%
Hepato-jugular reflux	6	19%

All patients underwent transthoracic echocardiography, which revealed left ventricular hypertrophy in 57% of cases, with an average left ventricular mass of $114.40 \pm 27 \text{ g/m}^2$. Additionally, left atrial dilation was observed in 65% of patients, with an average volume of $28.6 \pm 10 \text{ ml/m}^2$. Mitral flow patterns were classified as pseudonormal, restrictive, or indicative of relaxation abnormalities in 13 (41%), 10 (31%), and 9 (25%) patients, respectively.

Table 2: Cardiographic echoparameters

	PARAMETRE
PAPS: MMHG	30 +/- 10 mmhg
MASSE VG	114 +/- 27 g/m2
TDE, MS	236 +/- 91
VITESSE E CM/S	87 +/- 11
E/E'	14 +/- 5
VOLUME OG	28,6 +/- 10 ml/m2

Most of our patients had a left ventricular ejection fraction (LVEF) between 60-70%, with a range from 51% to 85%. The LVEF was calculated using systolic blood pressure (SBP) and automated fractional ejection (Auto FE) measurements.

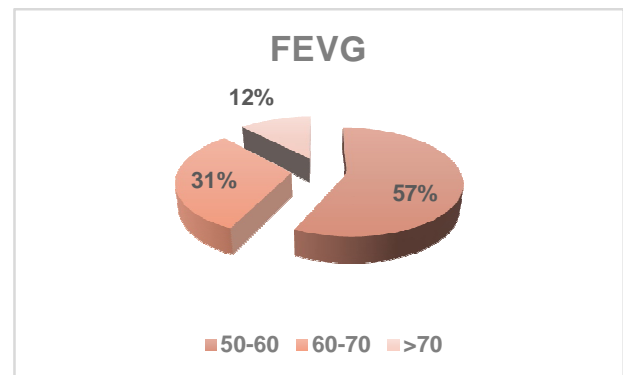


Figure 3: Left ventricular EF in our patients

The analysis of right ventricular function showed dysfunction rates of 35% for TAPSE, 33% for S', and 41% for the Tei index. It is important to note that TAPSE evaluates a

single segment, while S' measurements are angle-dependent and similarly limited to a single segment. The Tei index, although a valuable parameter, is infrequently analyzed and is typically invalid in cases of irregular cardiac rhythm.

Table 3: Echocardiographic parameters of the right ventricle

	S'VD	TAPSE	INDICE TEI
VALUES	9+/- 3,5 cm/s	16+/- 5mm	0,48±0,24
PERCENTAGE	33%	35%	41%

The mean global right ventricular (RV) strain was notably reduced in 55% of patients, with a longitudinal strain alteration of the RV lateral wall observed in 68%. Segmental analysis revealed impairments in the apical, median, and basal segments at rates of 59%, 63%, and 69%, respectively. A significant correlation was established between the Tei index and the lateral wall strain of the RV.

Normal strain values are $19 \pm 6\%$ for the basal segment, $27 \pm 6\%$ for the median segment, and $32 \pm 6\%$ for the apical segment. Additionally, data interpretation for the parasternal short axis poses challenges due to the thin RV free wall and limited available literature. Suboptimal RV wall visibility and varying loading conditions may also contribute to inaccurate measurements.

Table 4: Right ventricular strain echocardiography parameters

	SGVD(%)	SLVD(%)	SLAVD(%)	SLMVD(%)	SLBVD(%)
VALUES	-19,17%	-18,27%	-24,11%	-20,17%	+/- 6,36
S	+/- 4,6	+/- 5,4	+/- 3,8		+/- 8,95
PERCENTAGE	55%	68%	59%	63%	69%

Patient outcomes revealed that 40.2% of the cohort experienced rehospitalization for heart failure. Specifically, 35 patients presented with heart failure decompensation,

accounting for 40.2% of the study population, with 15 cases (42.85%) occurring within the first six months.

Alteration	Notion of rehospitalization
TAPSE	43%
S'VD	48%
INDICE TEI	51%
SGVD	95%
SLVD	89%

Table 5 Profile of patients with notion of rehospitalization

In our study, we observed six deaths, five of which were due to heart failure decompensation, representing 5.74% of the cohort. All five of these patients had an altered strain, with a cutoff of -10.3% for global strain and -8.5% for the free wall. Among these five deaths, all were male, with an average age of 81 years, and three were diabetic. TAPSE and S'VD were reduced in only two patients, while an elevated Tei index was noted in three, raising questions about the correlation.

Table 6: Number of deaths in our patients

	Death from heart failure n=5
Age	81+/-4 ans
Diabetes	3
TAPSE	2
SGVD	5
SLVD	5
S'VD	2
Indice de Tei	4

Discussion :

The right ventricle (RV) was traditionally considered a less critical cardiac structure, with a limited contribution to overall cardiac function. However, over the past two decades, the volume of research affirming the role of RV remodeling in various cardiovascular conditions has grown significantly. The advent of speckle-tracking imaging (STI)

has revolutionized the analysis of myocardial deformation, providing detailed measurements of RV function and mechanics (1).

Clinical data have validated the importance of RV function in heart failure, highlighting that RV dysfunction is associated with increased cardiovascular risk and mortality in these patients, regardless of left ventricular ejection fraction (LVEF). While research on RV strain in patients with reduced LVEF continues to expand, studies on RV mechanics in heart failure with preserved ejection fraction (HFpEF) have emerged more recently (1).

Two-dimensional strain (2D strain) or 2D speckle tracking enables the analysis of myocardial movement by tracking speckles (natural acoustic markers) within the 2D ultrasound image. These markers are statistically evenly distributed within the myocardium. Their size ranges from 20 to 40 pixels (2). Each speckle can be precisely identified and tracked across a series of consecutive images. Available software facilitates the spatial and temporal processing of the image, allowing for the recognition and selection of these elements in the ultrasound image. The geometric displacement of each speckle represents local tissue movement. By tracking these speckles, tissue velocities, strain, and strain rate can be calculated in 2D mode (3).

Table 7: Ultrasound analysis of right ventricular function (3).

<p>Morphological analysis : VD/VG ratio > 0.6 = VD dilatation</p>
<p>Functional analysis: LV dysfunction VD surface shortening fraction < 46 ± 7 Longitudinal contraction TAPSE < 18 mm S-ring peak < 11.5 cm/sec Global 2D speckle tracking SG deformation < -30</p>
<p>RV: right ventricle, LV: left ventricle, TAPSE: systolic excursion of the tricuspid annulus, SG: Strain global.</p>

Right ventricular (RV) dysfunction and pulmonary vascular remodeling are directly influenced by an increase in RV afterload. Pulmonary hypertension is common in patients with heart failure with preserved ejection fraction (HFpEF),

particularly during exertion, and is associated with poor outcomes (2).

Research on RV strain in patients with heart failure with reduced ejection fraction (HFrEF) is steadily increasing. Although tricuspid annular plane systolic excursion (TAPSE) and lateral tricuspid annular systolic velocity (S'RV) may be preserved, impaired RV strain can still be observed (4). Speckle-tracking imaging (STI) is significantly less load-dependent compared to pulsed wave and tissue Doppler imaging. However, two-dimensional strain is not entirely load-independent. Missant et al. studied the relationship between RV contractility and regional deformation, reporting that RV deformation is load-dependent (5). This dependency is clinically significant because RV afterload is minimal at rest but can increase substantially under various pulmonary pathological conditions.

A study on RV strain in HFrEF revealed that global strain is the only parameter significantly correlated with adverse clinical outcomes, such as cardiac mortality or hospitalization for heart failure exacerbation. RV dysfunction was more pronounced in patients with systolic dysfunction, particularly for S'RV and the Tei index, without significant differences in TAPSE or RV strain. These findings suggest that TAPSE and RV strain are critical parameters for assessing RV function, regardless of LVEF (1).

In the same study, increased mortality rates were observed in relation to impaired RV strain in heart failure patients across both groups, with critical thresholds set at -15.3% for strain and 14 mm for TAPSE. However, it is important to note that all deceased patients had severe pulmonary hypertension (mean pulmonary artery pressure [mPAP] > 35 mmHg), raising questions about the study's conclusions. To address this limitation, our study intentionally excluded patients with mPAP greater than 35 mmHg to provide a more focused analysis of the impact of RV longitudinal strain on mortality, without the confounding influence of severe pulmonary hypertension (1).

Another study confirmed that RV dysfunction is associated with an increase in cardiovascular decompensation events and mortality in patients with heart failure, regardless of left ventricular ejection fraction (LVEF). This analysis reported values of 28% for TAPSE and 21% for S'. Regarding strain, 48% of abnormalities were global, and 42% were localized to the lateral RV wall. The study also

demonstrated a significant correlation between RV strain and dyspnea severity, surpassing other parameters, including TAPSE. Furthermore, global strain was shown to be a better predictor of adverse clinical events than longitudinal free wall strain (4).

The prognostic value of right ventricular dysfunction (RVD) in patients with heart failure with preserved ejection fraction (HFpEF) remains controversial. Melenovsky et al. (6) demonstrated that right ventricular dysfunction, assessed by transthoracic echocardiography (defined as a fractional area change [FAC] < 35%), was the main predictive factor for mortality in an overweight population with advanced heart failure (96 patients with HFpEF, an average body mass index of 34 kg/m², and 71% in NYHA functional class III or IV). This was not the case in a population with less advanced HF (as observed in clinical trials such as PARAGON, with 28% of patients in NYHA class III or IV and only 9% of patients with FAC < 35%) (7). In a community-based HFpEF cohort, RVD defined by semi-quantitative assessment was associated with poorer outcomes, even after adjusting for comorbidities (8).

Studies have previously demonstrated that RV longitudinal shortening is more important for RV systolic function than circumferential shortening (9,10). Furthermore, studies have revealed that two-dimensional echocardiography and CMR-derived strain exhibit "reasonable" concordance; however, key issues include high inter-provider variability and the lack of reference values for each technique (11).

Only a few studies have evaluated prognostic markers in patients with acute heart failure (12). A recent study (13) highlights the importance of considering RV function as a risk marker for poor prognosis and suggests that RV function assessment should be part of a comprehensive evaluation of patients with HFpEF. Although other treatments improve the prognosis of patients with HFpEF, such as finerenone, which significantly reduces the total worsening of heart failure and cardiovascular death (14), those at high risk of adverse events should benefit from closer monitoring and intensive management of comorbidities and congestion. The best parameter for evaluating RVD remains to be determined, but our study suggests that RVGLS strain may be promising. It correlates well with CMR-derived RV ejection fraction, is reproducible,

and has prognostic significance compared to clinical and echocardiographic parameters. However, additional efforts are needed to standardize software to implement strain analysis in clinical practice (13).

Another study by Iacoviello et al. concluded that both measurements of RV longitudinal systolic strain, obtained through 2D speckle-tracking analysis, are inextricably associated with all-cause mortality, cardiovascular death, heart transplantation, and/or death due to worsening HF in ambulatory patients with HF. Estimating RV systolic function remains a challenge (1,3). This is due to several factors, including the complex geometry of the RV, echocardiographic imaging limitations caused by its retrosternal position, difficulties in defining the endocardial surface due to myocardial trabeculation, and the load dependency of RV function indices (14).

RV strain is an excellent predictor of disease outcome, and it is a precise, highly feasible, rapid, and reproducible echocardiographic technique that provides important insights into RV mechanics. This is why its assessment should be a critical task in daily echocardiographic examinations, particularly for patients with heart failure (15).

Conclusion :

Right ventricular strain (RV strain) in heart failure with preserved ejection fraction (HFpEF) remains an area with many unanswered questions. This study demonstrated that there is an alteration in right ventricular strain in patients with HFpEF, with prognostic implications for mortality and rehospitalization due to cardiac decompensation.

This raises the question of whether this parameter should be routinely included in the assessment of RV systolic function.

Systematic evaluation of RV function could help identify HFpEF patients at high risk of adverse events, who would benefit from closer monitoring and intensive management of comorbidities and congestion.

Disclaimer (Artificial intelligence)

Option 1:

Author(s) hereby declare that NO generative AI technologies such as Large Language

Models (ChatGPT, COPILOT, etc.) and text-to-image generators have been used during the writing or editing of this manuscript.

Option 2:

Author(s) hereby declare that generative AI technologies such as Large Language Models, etc. have been used during the writing or editing of manuscripts. This explanation will include the name, version, model, and source of the generative AI technology and as well as all input prompts provided to the generative AI technology. Details of the AI usage are given below:

1.No AI

REFERENCES:

1. M. Tadic, E. Pieske-Kraigher, C. Cuspidi et al, *Right ventricular strain in heart failure: Clinical perspective, Arch Cardiovasc Dis*, 2017 Oct;110(10):562-571.doi: 10.1016/j.acvd.2017.05.002. Epub 2017 Jun 29.
2. DALEN H, THORSTENSEN A, AASE SA et al. *Segmental and global longitudinal strain and strain rate based on echocardiography of 1 266 healthy individuals : the HUNT study in Norway. Eur J Echocardiogr*, 2010 ; 11 : 176-183.
3. PERK G, TUNICK PA, KRONZON I et al. *NonDoppler two-dimensional strain imaging by echocardiography – from technical considerations to clinical applications. J Am Soc Echocardiogr*, 2007 ; 20 : 234-243.
4. L. Bosch, Carolyn S.P. Lam, L. Gong, et al , *Right ventricular dysfunction in left-sided heart failure with preserved versus reduced ejection fraction, European Journal of Heart Failure* (2017) doi: 10.1002/ejhf.873
5. C. Missant, S. Rex, P. Claus, L. Mertens, P.F. Wouters, *Load-sensitivity of regional tissue deformation in the right ventricle: isovolumic versus ejection-phase indices of contractility, Heart*, 94 (2008), p. e15
6. Melenovsky V, Hwang SJ, Lin G, Redfield MM, Borlaug BA. *Right heart dysfunction in heart failure with preserved ejection fraction. Eur Heart J* 2014;35:3452-62.
7. Shah AM, Cikes M, Prasad N, Li G, Getchevski S, Claggett B, et al. *Echocardiographic features of patients with heart failure and preserved left ventricular ejection fraction. J Am Coll Cardiol*2019;74:2858-73.
8. Mohammed SF, Hussain I, AbouEzzeddine OF, Takahama H, Kwon SH, Forfia P, et al. *Right ventricular function in heart failure with preserved ejection fraction: a community-based study. Circulation* 2014;130:2310-20.
9. T. Kukulski, L. Hubbert, M. Arnold, B. Wranne, L. Hatle, G.R. Sutherland, *Normal regional right ventricular function and its change with age: a Doppler myocardial imaging study, J Am Soc Echocardiogr*, 13 (2000), pp. 194-204
10. M. Tee, J.A. Noble, D.A. Bluemke, *Imaging techniques for cardiac strain and deformation: comparison of echocardiography, cardiac magnetic resonance and cardiac computed tomography, Expert Rev Cardiovasc Ther*, 11 (2013), pp. 221-231
11. Goliash G, Zotter-Tufaro C, Aschauer S, Duca F, Koell B, Kammerlander AA, et al. *Outcome in heart failure with preserved ejection fraction: the role of myocardial structure and right ventricular performance. PLoS One* 2015;10:e0134479.
12. S. Lejeune, C.Roye, V. Ciocea et al ,*Right Ventricular Global Longitudinal Strain and Outcomes in Heart Failure with Preserved Ejection Fraction, J Am Soc Echocardiogr*. 2020 Aug;33(8):973-984.e2. doi: 10.1016/j.echo.2020.02.016. Epub 2020 May 7.
13. S.D. Solomon, J.J.V. McMurray, M. Vaduganathan et al *Finerenone in Heart Failure with Mildly Reduced or Preserved Ejection Fraction, N Engl J Med*, 2024 Oct 24;391(16):1475-1485.doi: 10.1056/NEJMoa2407107. Epub 2024 Sep 1.
14. M. Iacoviello, G. Citarelli, V. Antoncicchi, et al. *Right ventricular longitudinal strain measures independently predict chronic heart failure mortality, Echocardiography*, 33 (2016), pp. 992-1000
15. S. Guendouz, S. Rappeneau, J. Nahum, et al. *Prognostic significance and normal values of 2D strain to assess right ventricular systolic function in chronic heart failure, Circ J*, 76 (2012), pp. 127-136

UNDER PEER REVIEW